

Robotic Resection of Intraductal Neoplasm of the Pancreas

Marcel A.C. Machado, MD,^{1,2} Fábio F. Makdissi, MD,²
Rodrigo C. Surjan, MD,² and Ricardo Z. Abdalla, MD¹

Abstract

Background: Minimally invasive techniques have been revolutionary and provide clinical evidence of decreased morbidity and comparable efficacy to traditional open surgery. Computer-assisted surgical devices have recently been approved for general surgical use.

Aim: The aim of this study was to report the first known case of pancreatic resection with the use of a computer-assisted, or robotic, surgical device in Latin America.

Patient and Methods: A 37-year-old female with a previous history of radical mastectomy for bilateral breast cancer due to a BRCA2 mutation presented with an acute pancreatitis episode. Radiologic investigation disclosed an intraductal pancreatic neoplasm located in the neck of the pancreas with atrophy of the body and tail. The main pancreatic duct was enlarged. The surgical decision was to perform a laparoscopic subtotal pancreatectomy, using the da Vinci[®] robotic system (Intuitive Surgical, Sunnyvale, CA). Five trocars were used. Pancreatic transection was achieved with vascular endoscopic stapler. The surgical specimen was removed without an additional incision.

Results: Operative time was 240 minutes. Blood loss was minimal, and the patient did not receive a transfusion. The recovery was uneventful, and the patient was discharged on postoperative day 4.

Conclusions: The subtotal laparoscopic pancreatic resection can safely be performed. The da Vinci robotic system allowed for technical refinements of laparoscopic pancreatic resection. Robotic assistance improved the dissection and control of major blood vessels due to three-dimensional visualization of the operative field and instruments with wrist-type end-effectors.

Introduction

LAPAROSCOPIC AND MINIMALLY INVASIVE SURGERY development has been one of the most important advances in operative techniques. A variety of pancreatic lesions, such as acinar-cell tumors, squamous-cell carcinomas, islet-cell tumors, cystic neoplasms, and adenocarcinomas, are most often treated by surgical resection.¹ The rationale for minimally invasive pancreatic resections relies in evidences that lesser perioperative trauma in laparoscopy is advantageous, when compared to the open approach. This reduction results in decreased inflammatory response, preservation of the immune function, and perhaps even a reduction of malignant recurrence.²⁻⁴

Computer-assisted surgical devices have recently been approved for general surgical use. Robotic or computer-

assisted surgery is a new acquisition to the armamentarium of minimally invasive surgical techniques and remains in its infancy but may be particularly useful in advanced laparoscopic procedures, such as pancreatic resections. Robotic pancreatic resection is mentioned rarely in the English literature, with only four articles found dealing with this procedure.⁵⁻⁸ Among them, there are two case reports,^{5,6} two articles from the same group,^{5,7} and only two dealing directly with this procedure and with a brief description of the technique.^{5,6} There is a lack of technical description of this complex procedure. The aim of this article was to describe the technique of a full robotic pancreatic resection in a patient with intraductal neoplasm. To our knowledge, this is the first robotic pancreatic resection in Latin America and the first case of intraductal neoplasm treated by this method, so far, in the English literature.

¹Research and Robotic Training Unit-IEP, Hospital Sírio Libanês, São Paulo, Brazil.

²Laboratory of Medical Investigation, Department of Gastroenterology, University of São Paulo, São Paulo, Brazil.

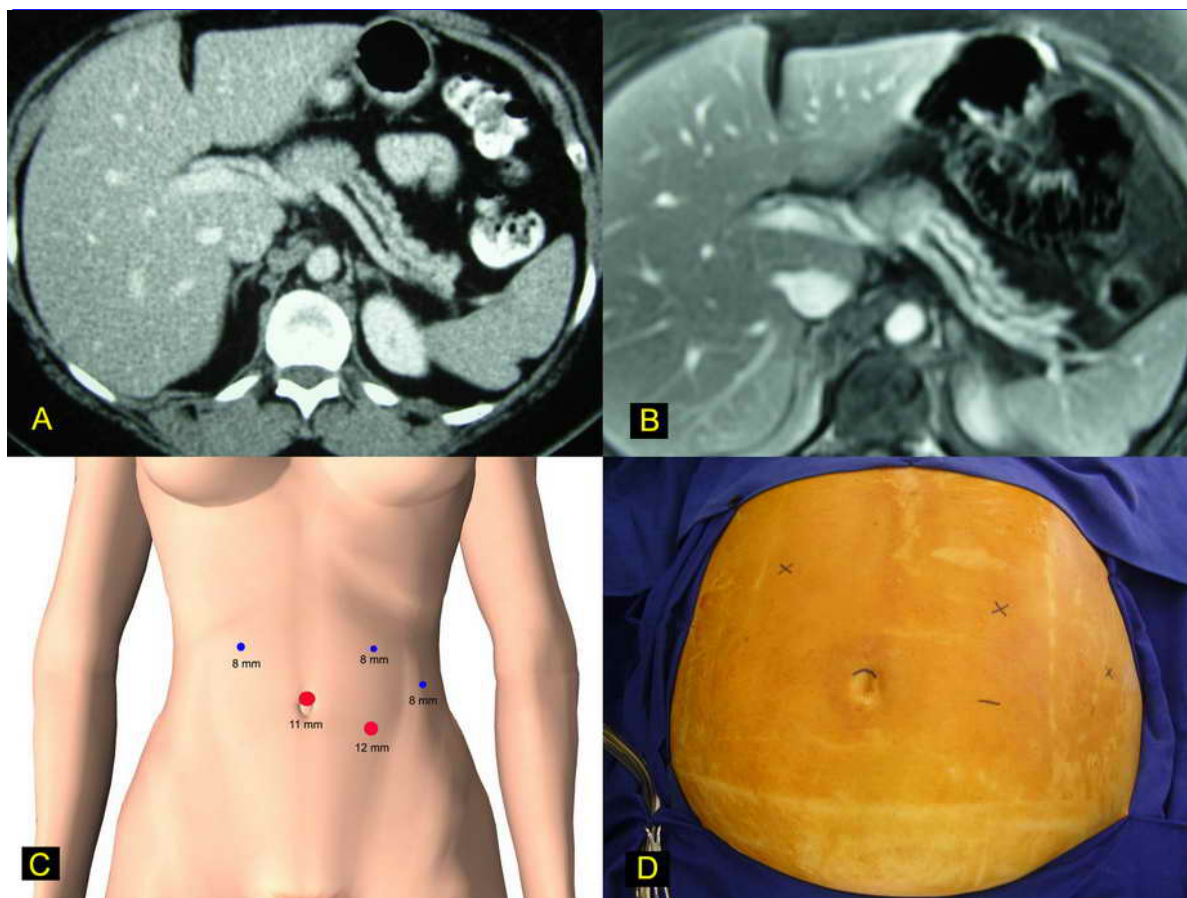


FIG. 1. Robotic pancreatic resection. (A) Preoperative computed tomography scan shows an atrophic distal pancreas with dilatation of the main pancreatic duct. (B) Preoperative magnetic resonance imaging suggests an intraductal neoplasm in the neck of the pancreas with atrophy of the body and tail of the pancreas. (C) Five trocars were used: three 8-mm trocars, one 11-mm trocar, and one 12-mm trocar. (D) The patient was placed in a right semilateral decubitus position.

Patient and Methods

A 37-year-old female with a previous history of radical mastectomy for bilateral breast cancer due to a BRCA2 mutation presented with an acute pancreatitis episode. Radiologic investigation disclosed an intraductal pancreatic neoplasm located in the neck of the pancreas with atrophy of the body and tail (Fig. 1A, B). The main pancreatic duct was enlarged. The surgical decision was to perform a laparoscopic subtotal pancreatectomy, using the da Vinci[®] robotic system (Intuitive Surgical, Sunnyvale, CA). The patient was initially placed in the supine position, and a cushion was placed below the left flank, thus tilting the patient toward the right lateral decubitus position by approximately 30 degrees. An orogastric tube was inserted and removed at the completion of the procedure. Using an open technique, an 11-mm trocar was placed in the supraumbilical position; through this port, the robotic camera was introduced, and four additional ports were placed: three 8-mm and one 12-mm, as shown in Figure 1C–1D. The gastroepiploic ligament and short gastric veins were divided with a Harmonic Scalpel (UltraCision; Ethicon Inc., Cincinnati, OH). This step permitted the location and ligation of the splenic artery in the superior border of the

pancreas. The posterior aspect of the pancreas at the level of the pancreatic neck was carefully dissected in order to disclose the anterior surface of the portal and mesenteric veins. A robotic instrument was inserted behind the pancreatic neck, and the pancreas was encircled with a cardiac tape. This tape was used during the whole procedure, allowing upward traction of the pancreas (Fig. 2A). The next step was to transect the pancreas by using a vascular endoscopic stapler (Fig. 2B). Once this was accomplished, the splenic vein was divided with a vascular stapler and the distal pancreas was mobilized from the retroperitoneum (Fig. 2C). Caution had to be taken to control the inferior mesenteric vein, which runs through the inferior border of the pancreas. The lower pole of the spleen was mobilized through the partial division of the splenocolic ligament (Fig. 2D). Dissection was completed with the mobilization of the splenic upper pole through the division of the splenophrenic ligament (Fig. 3A). The surgical specimen containing the pancreas and spleen was lifted (Fig. 3B) and placed inside a plastic retrieval bag. This bag was brought through the additional 12-mm port, where the spleen was morcellated without contamination of the abdominal cavity with splenic cells. The pancreatic stump was revised for hemostasis (Fig. 3C). The pancreatic specimen was retrieved

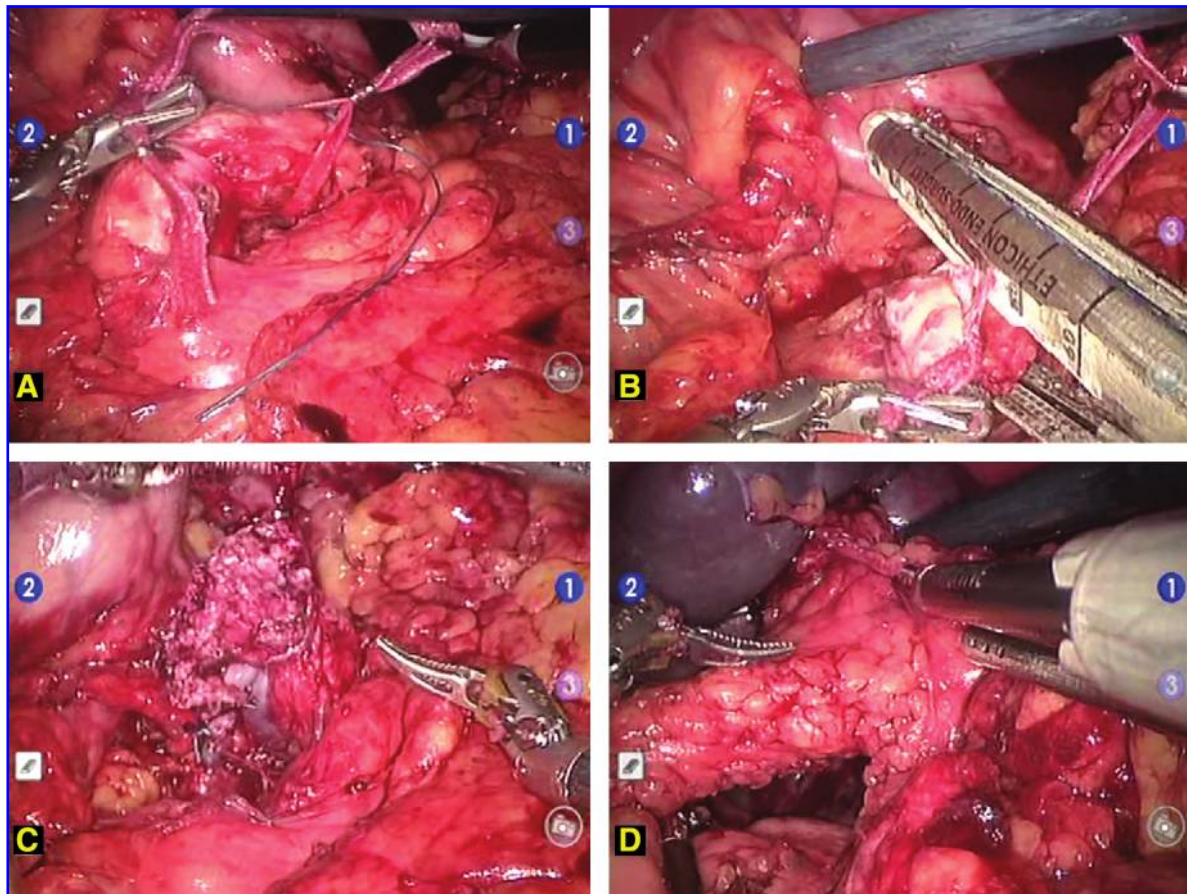


FIG. 2. Robotic pancreatic resection surgical steps. (A) The pancreatic neck is dissected and encircled. (B) Upward traction of tape permits the insertion of a stapler. (C) The pancreas is already transected and upward traction allows full mobilization of the pancreas from the retroperitoneum. (D) Division of the splenocolic ligament and mobilization of the lower splenic pole.

intact for anatomopathologic examination (Fig. 3D). A round 19-F Blake abdominal drain (Ethicon) was left in place, and the procedure was terminated.

Results

Operative time was 240 minutes. Blood loss was minimal, and the patient did not receive a transfusion. The recovery was uneventful, and the patient was discharged on postoperative day 4. There was no pancreatic leakage, and the drain was removed on postoperative day 7. The patient is well and asymptomatic 6 months after the procedure.

Discussion

In 1996, Salky and Edye were the first researchers to advocate the use of laparoscopic surgery to treat pancreatic lesions.⁹ Minimally invasive surgery can reduce surgical trauma, increase safety, and accelerate recovery. Robotic surgery became a reality in 1994 when a camera holder for use in laparoscopic surgery was approved by the U.S. Food and Drug Administration (FDA) and further evolved to a voice-command system that enabled hands-off control of the laparoscope.¹⁰ The da Vinci robotic surgical system made the remote control of laparoscopic instruments a reality. In 1997,

Himpens et al. reported the first laparoscopic cholecystectomy with using this robotic system.¹¹ Three years later, in July 2000, the FDA approved the da Vinci system for use in general surgical procedures. The da Vinci robotic system offers a number of advantages over traditional laparoscopy, including: 1) improvements in ergonomics—the surgeon sits in a console and manipulates hand controls in a comfortable, ergonomic fashion; 2) a fine-motion filter eliminates natural tremors of the hands and allows motion to be scaled up to 5:1; 3) significant increase in motion allowed by multiarticulated robotic instruments; 4) three-dimensional (3D) visualization, and 5) robotic control of the camera, allowing the operating surgeon to control the visualization without movement or fatigue in a stable platform, as the camera cannot move unless when engaged by the surgeon.¹²

However, robotic surgical systems have their limitations. As the initial step of a new technology, it is difficult to handle and is quite large. It necessitates a large operating room, imposes limitations in patient positioning, and port placement must be well planned to prevent interference between operative and camera arms. Another important issue is that proprioception and tactile sensitivity is not yet available in the robotic system, making it dangerous to move instruments outside the visual field. As experience with robotic technology

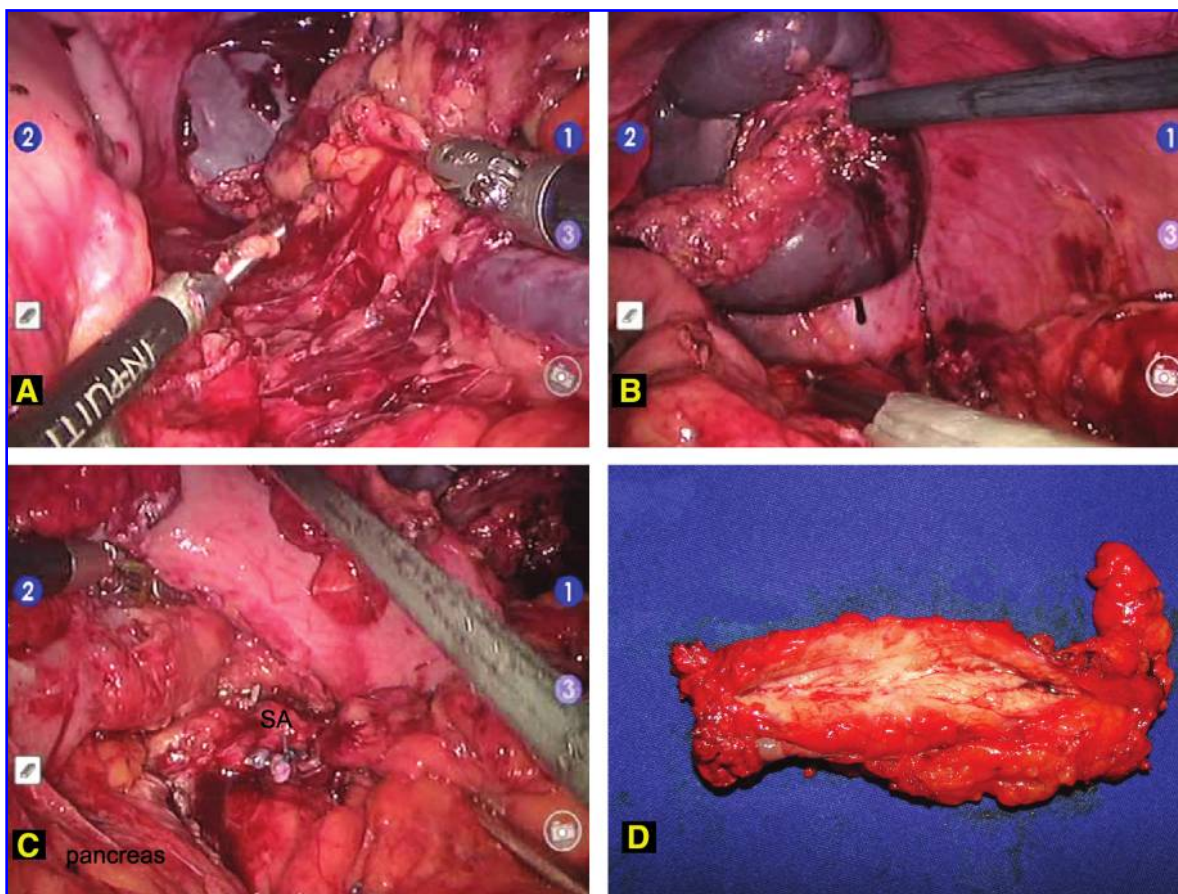


FIG. 3. Robotic pancreatic resection technique. (A) Division of the splenophrenic ligament and mobilization of the upper splenic pole. (B) Dissection was completed, and the surgical specimen was lifted to be placed in a retrieval bag. (C) The pancreatic stump was revised (pancreas) for hemostasia. SA, splenic artery. (D) The pancreatic specimen was retrieved intact for anatomopathologic examination.

has increased and its applications to advanced laparoscopic procedures have become more understood, surgeons are carefully exploring the application of this innovative technology to the diseases of the pancreas. The first robotic pancreatic resection was reported by Melvin et al. in 2003.⁵ Since then, only one article dealing directly with robotic-assisted pancreatic resection has been published in the English literature.⁶ In this article, we report the detailed technique of a totally robotic subtotal pancreatectomy for intraductal neoplasm of the pancreas. Although robotic technology has been applied to numerous surgical procedures, it seems that the best indications of this technology are to advanced laparoscopic procedures, such as pancreatic resections. Pancreatic resections are feasible and secure, and further experience will determine the true extent of benefits provided by this ultimate technology.

Conclusions

We conclude that the subtotal laparoscopic pancreatic resection can safely be performed. The da Vinci robotic system allowed for technical refinements of laparoscopic pancreatic resection. Robotic assistance improved the dissection and control of major blood vessels due to 3D visualization of the operative field and instruments with wrist-type end-effectors.

Disclosure Statement

No competing financial interests exist.

References

1. Park AE, Heniford BT. Therapeutic laparoscopy of the pancreas. *Ann Surg* 2002;236:149–158.
2. Virrimberga FJ, Foley DP, Meyers WC, Callery MP. Laparoscopic surgery and the systemic immune response. *Ann Surg* 1998;227:326–334.
3. Hartley JE, Mehigan BJ, Monson JR. Alterations in the immune system and tumor growth in laparoscopy. *Surg Endosc* 2001;15:305–313.
4. Tang CL, Eu KW, Tai BC, Soh JGS, Machin D, Seow-Choen F. Randomized, clinical trial of the effect of open versus laparoscopically assisted colectomy on systemic immunity in patients with colorectal cancer. *Br J Surg* 2001;88:801–807.
5. Melvin WS, Needleman BJ, Krause KR, Ellison EC. Robotic resection of a pancreatic neuroendocrine tumor. *J Laparosc Adv Surg Tech* 2003;13:33–36.
6. Horgan S, Galvani C, Gorodner V, Bareato U, Panaro F, Oberholzer J, Benedetti E. Robotic distal pancreatectomy and nephrectomy for living donor pancreas-kidney transplantation. *Transplantation* 2007;84:934–936.
7. Hazey JW, Melvin WS. Robot-assisted general surgery. *Semin Laparosc Surg* 2004;11:107–112.

8. Giulianotti PC, Coratti A, Angelini M, Sbrana F, Cecconi S, Balestracci T, Caravaglios G. Robotics in general surgery: Personal experience in a large community hospital. *Arch Surg* 2003;138:777–784.
9. Salky BA, Edey M. Laparoscopic Pancreatectomy. *Surg Clin North Am* 1996;76:539–545.
10. Geis WP, Kim HC, Brennan EJ, Jr, McAfee PC, Wang Y. Robotic arm enhancement to accommodate improved efficiency and decreased resource utilization in complex minimally invasive surgical procedures. *Stud Health Technol Inform* 1996;29:471–481.
11. Himpens J, Leman G, Cadiere GB. Telesurgical laparoscopic cholecystectomy. *Surg Endosc* 1998;12:1091.
12. Taffinder N, Smith SGT, Huber J, Russell RC, Darzi A. The effect of a second-generation 3D endoscope on the laparo-

scopic precision of novices and experienced surgeons. *Surg Endosc* 1999;13:1087–1092.

Address correspondence to:
Marcel A.C. Machado, MD
Laboratory of Medical Investigation
Department of Gastroenterology
University of São Paulo
Rua Evangelista Rodrigues 407
São Paulo, 05463-000
Brazil

E-mail: dr@drmarcel.com.br