CASE RECORDS of the MASSACHUSETTS GENERAL HOSPITAL

Founded by Richard C. Cabot
Nancy Lee Harris, M.D., *Editor*
Jo-Anne O. Shepard, M.D., *Associate Editor*
Sally H. Ebeling, *Assistant Editor*
Eric S. Rosenberg, M.D., *Associate Editor*
Alice M. Cort, M.D., *Associate Editor*
Christine C. Peters, *Assistant Editor*

Case 27-2011: A 17-Year-Old Boy with Abdominal Pain and Weight Loss

Harland S. Winter, M.D., Debra A. Gervais, M.D., and John A. Branda, M.D.

PRESENTATION OF CASE

From the Departments of Pediatric Gastroenterology (H.S.W.), Radiology (D.A.G.), and Pathology (J.A.B.), Massachusetts General Hospital; and the Departments of Pediatrics (H.S.W.), Radiology (D.A.G.), and Pathology (J.A.B.), Harvard Medical School — both in Boston.

N Engl J Med 2011;365:940-50.
Copyright © 2011 Massachusetts Medical Society.

Dr. Nina Mayer (Medicine–Pediatrics): A 17-year-old boy was seen in the pediatric gastroenterology clinic of this hospital because of abdominal pain and weight loss.

The patient had been well until approximately 6 weeks earlier, when intermittent crampy abdominal pain developed. Approximately 3 weeks later, nonbloody diarrhea developed and lasted for a week, associated with one episode of emesis. Thereafter, abdominal pain occurred daily, was predominantly located in the right lower quadrant, radiated to the right flank, and was associated with lower back discomfort, borborygmi, and constipation.

During the fourth week of illness, after the diarrhea had resolved, the patient saw his primary care physician. Serum levels of glucose, alanine aminotransferase, and thyrotropin were normal, as were tests of renal function. Tests for tissue transglutaminase IgA antibodies, hepatitis A virus, hepatitis C virus, and the human immunodeficiency virus (HIV) were negative. Results of tests for serum antibodies to Epstein–Barr virus (EBV) were consistent with past infection; testing was positive for hepatitis B virus surface antibody and negative for hepatitis B surface antigen, indicating immunity or past infection. Other results are shown in Table 1. Culture of a stool specimen and examination of stool specimens for ova and parasites, leukocytes, and occult blood were negative.

Two weeks later, the patient was seen in the pediatric gastroenterology clinic at this hospital. He rated the abdominal pain at 5 on a scale of 0 to 10, with 10 indicating the most severe pain. He reported one bowel movement of hard stool daily, and one episode of blood streaking on the stool after straining, with no mucus. He reported that he had lost 18.2 kg during the previous 2 years. The first 11 to 12 kg was intentional; however, during the 6 weeks before this evaluation, additional weight loss had occurred unintentionally. The body-mass index (the weight in kilograms divided by the square of the height in meters) had reportedly decreased from 27.0 (>95th percentile for his age) to 20.5 (25th to 50th percentile). He reported night sweats with chills but no fever.

The patient had visited relatives in Haiti approximately 4 years earlier for 1 week; he reported no exposure to persons with respiratory or gastrointestinal symptoms while there or recently. Skin tests for tuberculosis were reportedly negative before

The New England Journal of Medicine
Downloaded from nejm.org at UNIVERSITAETSKLINIKUMS on November 9, 2011. For personal use only. No other uses without permission.
Copyright © 2011 Massachusetts Medical Society. All rights reserved.

Table 1. Laboratory Data.*

Variable	Reference Range, Age-Adjusted†	2 Wk before Presentation (4 Wk before Admission)	On Admission, This Hospital
Hematocrit (%)	37.0–49.0	33.8 (ref 36.0–48.0)	30.9
Hemoglobin (g/dl)	13.0–16.0	10.8 (ref 12.0–16.0)	9.8
White-cell count (per mm^3)	4500–13,000	11,300 (ref 4000–10,800)	7700
Differential count (%)			
Neutrophils	40–62	73.4 (ref 43.2–76.7)	78
Lymphocytes	27–40	16.6 (ref 8.0–41.0)	14
Monocytes	4–11	9.4 (ref 4.0–8.0)	7
Eosinophils	0–8	0.3 (ref 2.0–4.0)	1
Basophils	0–3	0.3 (ref 0.0–1.0)	0
Platelet count (per mm^3)	150,000–450,000	588,000 (ref 168,000–400,000)	559,000
Mean corpuscular volume (μm^3)	78–98	76.3 (ref 80.8–86.6)	76
Prothrombin time (sec)	10.8–13.4		15.7
Activated partial-thromboplastin time (sec)	21.0–33.0		28.8
Erythrocyte sedimentation rate (mm/hr)	0–11	60 (ref 0–10)	47
Protein (g/dl)			
Total	6.0–8.3	8.6 (ref 5.9–7.5)	7.3
Albumin	3.3–5.0	2.7 (ref 3.4–4.8)	2.9
Globulin	2.6–4.1		4.4
Alkaline phosphatase (U/liter)	15–350	139 (ref 25–106)	114
Aspartate aminotransferase (U/liter)	10–40	41 (ref 8–34)	40
Alanine aminotransferase (U/liter)	10–55	40 (ref 10–40)	36
IgA (mg/dl)		543 (ref 61–348)	
Lactate dehydrogenase (U/liter)	110–210		265
Iron (μg/dl)	45–160		34
Iron-binding capacity (μg/dl)	228–428		238
Ferritin (ng/ml)	30–300		949
C-reactive protein (mg/liter)	<8.0		66.6

* To convert the values for iron and iron-binding capacity to micromoles per liter, multiply by 0.1791. Ref denotes the reference range used by the primary care physician.

† Reference values are affected by many variables, including the patient population and the laboratory methods used. The ranges used at Massachusetts General Hospital are age-adjusted, for patients who are not pregnant and do not have medical conditions that could affect the results. They may therefore not be appropriate for all patients.

and after that trip. He took no medications, his immunizations were up to date, and he had no allergies. He was born in the United States and had lived in the mid-Atlantic and Northeast states. He was a high-school student and participated in sports; he had been sexually active with three female partners and reportedly always used condoms; he had no history of sexually transmitted infections. His mother had died at 52 years of age from complications of diabetes and hypertension; his father was well at 60 years of age; a brother had been incarcerated; and his older sister, with whom he lived, was healthy.

On examination, the patient appeared well. The weight was 59.9 kg (28th percentile for his age); vital signs were normal. The abdomen was soft, mildly distended with fullness in the right lower quadrant, and mildly tender to deep palpation in

The New England Journal of Medicine
Downloaded from nejm.org at UNIVERSITAETSKLINIKUMS on November 9, 2011. For personal use only. No other uses without permission.
Copyright © 2011 Massachusetts Medical Society. All rights reserved.

the right and left lower quadrants, without rebound or guarding. The external rectal examination was normal; the patient declined an internal rectal examination. The remainder of the examination was normal. A stool specimen was guaiac-negative.

The next day, an upper gastrointestinal radiographic series with a small-bowel follow-through examination showed normal small bowel, abundant stool in the colon, and irregular luminal narrowing in the cecum. The luminal narrowing could have been caused by underdistention or inflammatory changes.

Two weeks later, the patient returned to this hospital for gastrointestinal endoscopic examinations. He reported recent night sweats and chills and no fevers. He was taking polyethylene glycol daily for constipation and magnesium citrate in preparation for endoscopy. On examination, he was well-appearing, thin, and muscular. The vital signs were normal. The abdomen was firm, most notably in the right lower quadrant, with mild tenderness to palpation on the right side and epigastrium, without guarding or rebound. Firm, mobile masses were palpable in the right lower quadrant; the liver and spleen were not palpable. The remainder of the examination was normal. Levels of electrolytes, glucose, bilirubin, lipase, and amylase were normal, as were tests of renal function; other test results are shown in Table 1. Esophagogastroduodenoscopy revealed normal esophageal and gastric mucosa and mild inflammation and friability in the second part of the duodenum, features that were consistent with duodenitis. Colonoscopic examination showed a nonthrombosed external hemorrhoid and a normal-appearing rectum and rectosigmoid colon; the instrument could not be advanced past the sigmoid colon. Radiographs of the abdomen showed a loop of mildly dilated jejunum with no evidence of obstruction and were otherwise normal. Computed tomographic (CT) colonography, performed before and after the intravenous and oral administration of contrast material, revealed soft-tissue peritoneal implants throughout the abdomen, most pronounced along the liver surface and sigmoid colon, a finding suggestive of peritoneal carcinomatosis. Mildly prominent lymph nodes were noted in the mesentery. The colon was filled with stool, limiting evaluation for mucosal lesions.

The patient was admitted to the hospital. A skin test for tuberculosis was performed. During the first 2 days of hospitalization, the temperature rose to 38.9°C. A blood culture was negative. Pathological examination of the biopsy specimens of the esophageal, gastric, and duodenal tissue revealed mild nonspecific lymphocytosis of the esophageal squamous mucosa and the duodenal mucosa. Laxatives were administered, which resulted in the production of guaiac-negative liquid stool and lessening of the abdominal discomfort.

On the third and fourth days, induration at the site of the tuberculin skin test measured 20 mm in diameter. CT of the chest, after the intravenous administration of contrast material, revealed a multilobulated confluent mass (4.5 cm by 1.8 cm by 6.0 cm) in the superior mediastinum. The mass was posterior to the manubrium of the sternum and anterolateral to the trachea and extended inferiorly to the level of the carina, with mass effect on the superior vena cava and azygos vein. It had low attenuation centrally and enhancement peripherally, similar to the peritoneal implants. Multiple small, patchy, nodular air-space opacities up to 8 mm in diameter in both lungs had a predominantly upper-lobe distribution that was most prominent at the apexes. There was a precarinal lymph node (1.2 cm in short-axis dimension) and no hilar or axillary lymphadenopathy. There was layering of a small right pleural effusion. CT scans of the abdomen and pelvis after the intravenous and oral administration of contrast material showed multiple low-density peritoneal implants on the liver surface and in the right abdomen and pelvis. On the fourth day, a repeat test for HIV was negative and examination of induced sputum was negative for acid-fast bacilli. The next day, bronchoscopic examination was normal; examination of bronchoalveolar-lavage fluid was unremarkable.

A diagnostic procedure was performed.

DIFFERENTIAL DIAGNOSIS

Dr. Harland S. Winter: May we review the imaging studies?

Dr. Debra A. Gervais: A single image (Fig. 1A) from an upper gastrointestinal series and a small-bowel study showed a normal terminal ileum and small bowel. The administration of contrast material did not cause normal distention of the cecum, despite the use of paddles to apply compression to the gastrointestinal tract. The cecum

The New England Journal of Medicine
Downloaded from nejm.org at UNIVERSITAETSKLINIKUMS on November 9, 2011. For personal use only. No other uses without permission.
Copyright © 2011 Massachusetts Medical Society. All rights reserved.

Figure 1. Abdominal and Thoracic Imaging Studies.

A single image from a small-bowel study (Panel A) shows that the terminal ileum is normal and that the cecum is not distended with contrast material. There is only a small amount of contrast material in the cecal lumen (arrow). The appendix does not opacify. There is abundant stool in the colon, and the opacified portions of small bowel are unremarkable. CT of the chest after the intravenous administration of contrast material (Panel B) shows a hypodense mediastinal soft-tissue mass behind the sternum and anterolateral to the trachea (arrows). Abdominal CT scans obtained after the intravenous and oral administration of contrast material show the presence of hypodense peritoneal implants throughout the abdomen. Panel C shows multiple implants (arrows) along the liver surface. Hypodense implants are visible in the right lower quadrant (Panels D and E, arrows) and along the sigmoid colon (Panel F, arrows), which is identified by a small amount of contrast material in the lumen.

The New England Journal of Medicine
Downloaded from nejm.org at UNIVERSITAETSKLINIKUMS on November 9, 2011. For personal use only. No other uses without permission.
Copyright © 2011 Massachusetts Medical Society. All rights reserved.

remained collapsed, and only a small amount of contrast material was in the lumen. The terminal ileum was normal. The appendix did not fill with contrast material and was not visualized. There was abundant stool in the colon. The upper portion of the colon was normal.

Dr. Winter: This 17-year-old male adolescent presented with abdominal pain that was transiently associated with diarrhea and vomiting; it became localized in the right lower quadrant, intermittently radiated to the right flank, and became associated with constipation.

ABDOMINAL PAIN AND CONSTIPATION

Tenderness in the right lower quadrant and weight loss are consistent with Crohn's disease, but constipation is somewhat unusual without a stricture. Many adolescents with Crohn's disease have a history of weight loss that precedes the onset of abdominal symptoms by as much as 18 months.[1] Growth retardation, delayed sexual maturation, or both may also be present.[2] This patient, despite a loss of 18 kg over a period of 2 years, did not appear to have delays in growth or sexual maturation. The history of travel to Haiti 4 years earlier is of interest, but the purified protein derivative (PPD) skin test was reportedly negative before and after the visit. If he had chronic infection with tuberculosis, it was most likely not present 4 years earlier. The development of night sweats and chills increases the suspicion of an infectious disease or a malignant tumor.

On the first physical examination, the patient appeared well, with a soft abdomen and right lower quadrant fullness. One would not expect a person with Crohn's disease or cancer and substantial weight loss to be described as appearing well. The fullness in the right lower quadrant raises the possibility of Crohn's disease, perforated appendix, ileal duplication, or infection. Distinguishing tuberculosis from Crohn's disease solely on the basis of clinical information is challenging.

The patient's healthy appearance on the second examination, when he was described as thin, muscular, and afebrile, decreases the suspicion of a malignant tumor. The mobile masses in the lower abdomen, possibly the sigmoid colon, were consistent with the history of constipation and the increased stool seen in the colon on imaging. Laboratory-test results provide limited help in this case. Many patients with celiac disease, especially adolescents, have atypical presentations, including constipation; however, in children over the age of 2 years, negative tests for tissue transglutaminase IgA antibodies, as seen in this case, make celiac disease highly unlikely.

The endoscopic and radiologic findings focus our attention on the right lower quadrant and explain many of the patient's symptoms. The upper endoscopy revealed possible duodenitis; otherwise, the esophagus and stomach were normal. Often, patients who have Crohn's disease or ulcerative colitis will have focal enhancing lesions in the stomach, although these findings are nonspecific. The colonic mucosa up to the sigmoid colon was normal, but the endoscope could not be advanced beyond this point. About 60% of adolescents with Crohn's disease will have ileocolonic disease, but in this patient, endoscopic evaluation of this area was not possible. Perianal disease, which was not described in this patient, is found in 15 to 20% of adolescents with Crohn's disease. In contrast to the linear ulcerations that may be seen in the colon of patients with Crohn's disease, horizontal ulcers are more typical of tuberculosis. Since the right side of this patient's colon was not visualized, information about the absence of ulcerations or the presence of ulcerations and their characteristics was not known. The absence of aphthous lesions, linear ulcerations, and "skip areas" of inflammation on colonoscopy neither supported nor ruled out the diagnosis of Crohn's disease.

May we see the additional radiographic studies?

Dr. Gervais: Abdominal radiographs obtained 2 weeks after the gastrointestinal series showed a single loop of mildly dilated jejunum (a nonspecific finding) and no other abnormality. CT colonography performed before and after the intravenous administration of contrast material showed abundant retained stool within the colon, limiting the ability to evaluate for mucosal lesions. However, throughout the abdomen were hypodense soft-tissue implants, most prominent along the liver surface, right lower quadrant, and sigmoid colon. The appearance of such implants, although nonspecific, is often seen with peritoneal carcinomatosis. Two days later, a CT scan of the chest (Fig. 1B) showed a mediastinal mass extending from the thoracic inlet to the carina; multiple small, patchy, nodular air-space opacities in the upper lobes; a small right pleural effusion; and a single prominent precarinal node without hilar

The New England Journal of Medicine
Downloaded from nejm.org at UNIVERSITAETSKLINIKUMS on November 9, 2011. For personal use only. No other uses without permission.
Copyright © 2011 Massachusetts Medical Society. All rights reserved.

lymphadenopathy. Abdominal and pelvic CT scans (Fig. 1C through 1F) also showed peritoneal implants throughout the abdomen, as well as prominent mesenteric lymph nodes; there was no ascites.

Dr. Winter: On admission to this hospital, the patient was febrile and his stool was guaiac-negative. A patient with mucosal disease from Crohn's disease or infection often has guaiac-positive stool. The peritoneal implants noted on the imaging studies raised the possibility of a malignant tumor, although the patient did not appear to be ill. His PPD skin test was now positive; an HIV test was negative, and bronchoscopy yielded negative results.

MEDIASTINAL MASS AND PERITONEAL IMPLANTS

In a patient with a mediastinal mass and peritoneal implants, cancer and infection are primary considerations. Conditions such as splenosis, leiomyomatosis peritonei, peritoneal gliomatosis, or a ruptured congenital intestinal duplication cyst are not suggested by this patient's history and would not explain the mediastinal mass.

The distribution of peritoneal implants is related to the caudad-to-cephalad circulation of fluid in the peritoneum (Fig. 2). The transverse mesocolon divides the abdomen into superior (supramesocolic) and inferior (inframesocolic) components; the root of the mesentery of the small intestine divides the inframesocolic compartment into left and right inframesocolic spaces. Because of gravity, fluid tends to accumulate in the pouch of Douglas in women and in the retrovesical space in men. Most fluid ascends in the right paracolic gutter into the right subdiaphragmatic space. The falciform ligament prevents passage of fluid from right to left in the subdiaphragmatic space, so fluid descends caudally behind the transverse mesocolon, along the sigmoid, and into the pelvis. Implants from tumors or infection occur in four areas where stasis of fluid occurs — the cul-de-sac of the pelvis, the right paracolic gutter, the ileum, and the sigmoid colon.[3] This patient had evidence of implants in the right paracolic gutter, around the cecum and terminal ileum, near the sigmoid colon, and in the pelvis, locations that were consistent with the intraperitoneal spread of either infection or tumor.

Malignant Tumors

Peritoneal tumors may be primary or secondary (Table 2). Malignant mesothelioma occurs most commonly in the pleura, but these tumors also may present with diffuse peritoneal thickening and multiple nodules. Primary peritoneal carcinoma occurs most commonly in women who have *BRCA1* or *BRCA2* mutations.[4] Mesothelioma can be ruled out in the absence of asbestos exposure.

Peritoneal carcinomatosis may be caused by primary tumors, primarily in the appendix, but also in the stomach, colon, gallbladder, or pancreas. In this patient, the appendix did not visualize well on the imaging studies, so a mucinous adenocarcinoma of the appendix with implants in the peritoneum is a consideration. Ascites was absent, however, and the mediastinal mass is difficult to explain with this diagnosis. Patients with Crohn's disease are at increased risk for intestinal cancer, which could metastasize to the peritoneum and mediastinum, but this usually occurs in patients who are older than this one.

The mediastinal mass could be a lymphoma, but lymphomas rarely produce peritoneal nodules. The patient did have night sweats and a minimally elevated lactate dehydrogenase level, but he did not have splenomegaly or lymphadenopathy outside the mediastinum.

Infections

Peritoneal involvement and inflammation of the terminal ileum resulting in bowel obstruction may occur in histoplasmosis caused by *Histoplasma capsulatum* var. *capsulatum*.[5] Dissemination to the liver, spleen, kidneys, and occasionally the lungs may occur; peritoneal involvement is rare but has been reported.[6] Although the symptoms of intestinal histoplasmosis may be similar to the symptoms of Crohn's disease or tuberculosis, disseminated peritoneal nodules are not typical and an exposure to histoplasmosis was not documented in this case.

ABDOMINAL TUBERCULOSIS

Abdominal tuberculosis is not unusual in communities in which tuberculosis is endemic. In a series of 25 patients from Kathmandu, Nepal, most of the patients had abdominal pain, weight loss, and anorexia; some patients had diarrhea and others had constipation.[7] Only 25% of patients had fever, approximately half had abdominal tenderness, and 25% had an abdominal mass. The diagnosis of abdominal tuberculosis may be challenging to make, since two thirds of patients have a negative Mantoux tuberculin skin test and many do not have obvious pulmonary disease.[8] Colo-

The New England Journal of Medicine
Downloaded from nejm.org at UNIVERSITAETSKLINIKUMS on November 9, 2011. For personal use only. No other uses without permission.
Copyright © 2011 Massachusetts Medical Society. All rights reserved.

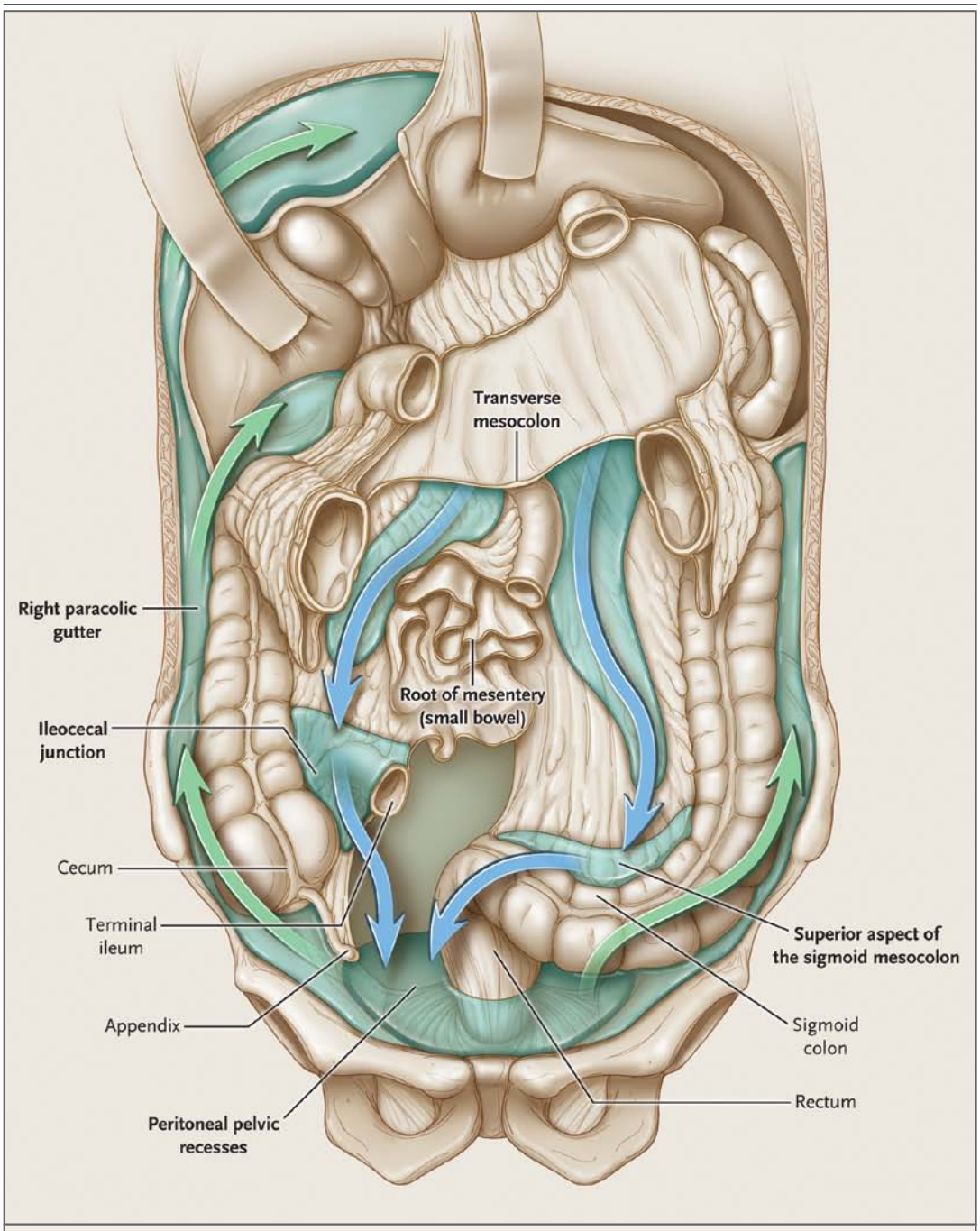

Figure 2. Intraabdominal Spaces Formed by Posterior Peritoneal Reflections.

Shown are the intraabdominal spaces created by the transverse mesocolon, which divides the peritoneal cavity into supramesocolic and inframesocolic compartments. The root of the mesentery of the small bowel divides the inframesocolic compartment into right and left infracolic spaces. The green arrows represent the ascending flow of intraperitoneal fluid, and the blue arrows the descending flow. Ascitic fluid is most likely to collect in the following four areas: the right paracolic gutter, the ileocecal junction, the peritoneal pelvic recesses, and the superior aspect of the sigmoid mesocolon.

noscopy may help distinguish intestinal tuberculosis from Crohn's disease. Anorectal lesions, longitudinal ulcers, aphthous ulcers, and cobblestone-appearing mucosa are more indicative of Crohn's disease, whereas involvement of fewer than four areas of the bowel (usually the termi-

The New England Journal of Medicine
Downloaded from nejm.org at UNIVERSITAETSKLINIKUMS on November 9, 2011. For personal use only. No other uses without permission.
Copyright © 2011 Massachusetts Medical Society. All rights reserved.

nal ileum and cecum) and the presence of a patulous ileocecal valve, transverse ulcers, and scars or pseudopolyps increase the likelihood of a diagnosis of intestinal tuberculosis.[9] Nevertheless, distinguishing Crohn's disease from intestinal tuberculosis may be challenging.[10]

The elevated serum ferritin level seen in this patient is consistent with the response of other acute-phase proteins, such as C-reactive protein, and with an elevated erythrocyte sedimentation rate and a decreased albumin level. One study reported that the elevated serum ferritin level in patients with tuberculosis was an acute-phase response and that the rise in the ferritin level did not reflect bone marrow iron stores.[11] The clinical features of abdominal tuberculosis are nonspecific, and the lack of reliable biomarkers necessitates obtaining a tissue diagnosis.[12] Only half of patients with abdominal tuberculosis have a lesion that can be identified on chest radiography or have active pulmonary disease.

SUMMARY

What should be the diagnostic test in this case? Since infection and cancer are both positron-emission tomography (PET)–avid, combined ^{18}F-fluorodeoxyglucose PET and CT would not help us distinguish between the two. Colonoscopy could be repeated in an attempt to reach the ileum to obtain tissue for microscopy, Ziehl–Neelsen staining, culture, and polymerase-chain-reaction assay for *Mycobacterium tuberculosis.* A biopsy of the mediastinal mass could provide the same diagnostic results. Taking into account the clinical history and the diagnostic-test results, I believe that the diagnostic procedure was a laparoscopy and that the diagnosis of abdominal tuberculosis was confirmed.

Dr. Eric S. Rosenberg (Pathology): I would like to ask Dr. Mark Pasternack, one of several consultants who saw this young man, to tell us what his thinking was at the time of the initial evaluation.

Dr. Mark Pasternack (Pediatric Infectious Disease): This patient appeared well but acknowledged profound and prolonged weight loss. He had a highly abnormal physical examination and very disturbing images. Our differential diagnosis was either peritoneal carcinomatosis with intrathoracic metastasis or tuberculous peritonitis of the so-called dry form without ascites, which is an uncommon presentation of an uncommon complication of tuberculosis. We had to try to obtain tissue, and the patient was sent to the operating room for diagnostic laparoscopy.

CLINICAL DIAGNOSIS

Abdominal tuberculosis or peritoneal carcinomatosis.

DR. HARLAND S. WINTER'S DIAGNOSIS

Abdominal tuberculosis.

PATHOLOGICAL DISCUSSION

Dr. John A. Branda: The diagnostic procedure was video-assisted laparoscopy, performed by Dr. Daniel Ryan. Numerous adhesions were noted between the omentum and the abdominal wall, primarily on the right side. The peritoneal surface, the omentum, and the superior surface of the liver were studded with small white nodules, from which biopsy specimens were obtained. There were similar white plaques in the pelvis, with matted loops of bowel. An intraoperative frozen section was obtained, which showed necrotizing granulomas; additional specimens were obtained and sent for cultures. Microscopical examination of permanent sections revealed necrotizing granulomatous inflammation (Fig. 3). A slide stained by the Ziehl–Neelsen procedure showed very few acid-fast bacilli. *M. tuberculosis* complex was isolated from a mycobacterial culture of the biopsy material. Susceptibility testing, with the use of both the rapid broth-culture method and the standard agar-proportion method, revealed high-level resistance to isoniazid but susceptibility to all other first-line antituberculosis agents. Thus, the diagnosis of tuberculous peritonitis was confirmed.

Tuberculous peritonitis is characterized by the presence of innumerable tubercles on the peritoneal surface. More than 90% of cases are associated with ascites, which results from exudation of fluid from the abnormal peritoneal surfaces. About 10% of patients with tuberculous peritonitis present as this patient did, with the dry form of tuberculous peritonitis, characterized by fibrosis and adhesions and no ascites.[13,14] Acid-fast bacilli may be difficult to detect on tissue sections, and it has been suggested that the characteristic laparoscopic appearance, together with the finding of granulomas, should be considered sufficient for the initiation of therapy, pending culture results.[13]

Dr. Rosenberg: Dr. Mayer, would you tell us what happened with this patient?

The New England Journal of Medicine
Downloaded from nejm.org at UNIVERSITAETSKLINIKUMS on November 9, 2011. For personal use only. No other uses without permission.
Copyright © 2011 Massachusetts Medical Society. All rights reserved.

Table 2. Classification of Tumors and Tumorlike Lesions of the Peritoneum.*

Primary tumors
Mesothelial tumors
Epithelial tumors
Smooth-muscle tumors
Desmoplastic small round-cell tumors
Solitary fibrous tumors
Secondary tumors
Carcinomatosis
Pseudomyxoma
Lymphomas
Sarcomas
Infections
Mycobacterium tuberculosis
Histoplasma capsulatum
Miscellaneous
Endometriosis
Gliomatosis peritonei
Melanosis
Splenosis

* The data are adapted from Levy et al.[3]

Dr. Mayer: We did not have the culture results while the patient was still in the hospital. We started four-drug therapy with isoniazid, ethambutol, rifampin, and pyrazinamide. Within 48 hours after the initiation of therapy he was afebrile. Despite the findings on the chest CT, he had no cough or respiratory problems, and induced sputum samples were negative for acid-fast bacilli, initially on smears and eventually on cultures, so respiratory precautions were discontinued. The Department of Public Health was notified, and the patient was discharged home with appropriate follow-up and monitoring arranged with a tuberculosis doctor. Within a few weeks after discharge, we heard that he had been doing well. Unfortunately, approximately 1 month after discharge, he began to have dyspnea and orthopnea. A chest radiograph showed a large right pleural effusion. He was referred to the emergency department at this hospital, where a CT scan of the chest showed a large right pleural effusion, collapse of the right lower lobe, and hilar lymphadenopathy. He was readmitted to the hospital.

Video-assisted thoracoscopic surgery was performed, and 1.6 liters of straw-colored exudative fluid was removed. Diaphragmatic-biopsy and pleural-biopsy specimens were obtained.

Dr. Branda: Pathological examination of both biopsy specimens showed necrotizing granulomas; no acid-fast bacilli were identified on tissue sections, but a few were identified on smears of the pleural biopsy that were prepared in the microbiology laboratory. Cultures subsequently grew *M. tuberculosis* with the same sensitivity profile as the previous isolate. Cultures of the pleural fluid were negative.

Dr. Mayer: Because of the extensive abdominal disease and progression of pulmonary disease, the team was concerned that the patient may not have been effectively absorbing the oral agents that he had been receiving for the past month. During his first admission, when we counseled him on taking oral antituberculosis medications, we informed him that his urine might turn orange while he was taking rifampin, which is a common side effect. He reported that this never happened, which suggested the possibility that the medications were not being adequately absorbed. Intravenous moxifloxacin and amikacin were started, and rifampin administration was changed from oral to intravenous; oral isoniazid, pyrazinamide, and ethambutol were continued. Before the intravenous administration of rifampin, a specimen of urine was clear and yellow; after the first intravenous dose of rifampin, the patient's urine had the expected orange color.

Testing of serum levels of the drugs that the patient was taking orally just before he was discharged from the hospital the second time showed that isoniazid and ethambutol were not at the target levels, representing further evidence of inadequate absorption. This information, as well as the resistance of his isolate to isoniazid, was shared with his doctor at the Department of Public Health, and the patient was discharged with a peripherally inserted central catheter for drug administration. Discharge medications included intravenous moxifloxacin, amikacin, and rifampin, as well as oral isoniazid, pyrazinamide, and ethambutol.

A Physician: Did any of the patient's family members have a positive PPD skin test, particularly his brother who was incarcerated?

Dr. Mayer: The Department of Public Health

The New England Journal of Medicine
Downloaded from nejm.org at UNIVERSITAETSKLINIKUMS on November 9, 2011. For personal use only. No other uses without permission.
Copyright © 2011 Massachusetts Medical Society. All rights reserved.

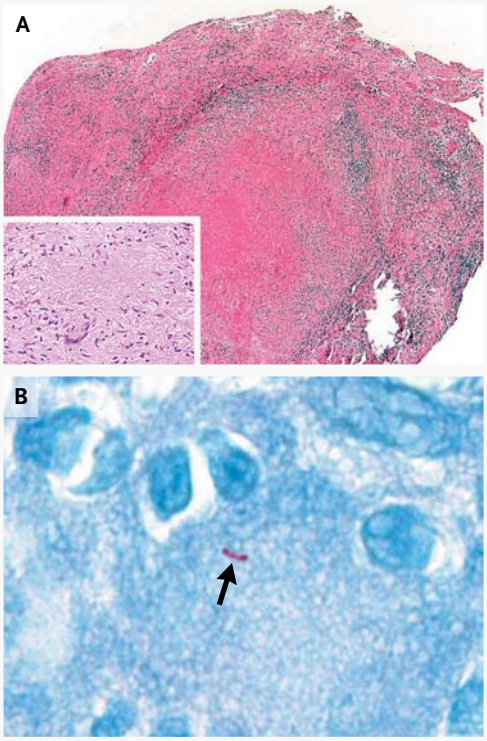

Figure 3. Peritoneal-Implant Biopsy Specimen.
Panel A (hematoxylin and eosin) shows a large granuloma with central necrosis, surrounded by histiocytes and giant cells, which in turn are surrounded by a cuff of lymphocytes and plasma cells (shown at higher magnification in the inset). Panel B (Ziehl–Neelsen stain) shows an acid-fast rod (arrow).

was going to screen the family. We do not have the results or any further follow-up.

Dr. Hasan Bazari (Medicine): What is the pathogenesis of tuberculous peritonitis?

Dr. Pasternack: It is usually a complication of the silent bacillemia that accompanies early-stage tuberculosis. If the regional lymph nodes fail as a barrier to the mycobacteria that drain from the primary pulmonary focus, mycobacteria may be disseminated via the bloodstream and seed systemic sites, which ultimately may progress to clinically significant foci of extrapulmonary tuberculosis. Just as subarachnoid granulomas may rupture and produce tuberculous meningitis, peritoneal granulomas may open and lead to disseminated implants in the abdomen. The ileocecal form of abdominal tuberculosis can be due to primary or secondary infection of the small bowel and would not be associated with myriad peritoneal implants, such as we saw in this patient. I think the peritoneal implants are a complication of systemic infection.

A Physician: How do you explain the high percentage of patients with intraabdominal tuberculosis who have a negative PPD skin test?

Dr. Pasternack: The general rule that I live by is that a PPD skin test at presentation shows anergic reactivity in about half of patients with life-threatening forms of tuberculosis. As patients improve with therapy, they often recover their skin-test reactivity.

ANATOMICAL DIAGNOSIS

Tuberculosis with tuberculous peritonitis.

This case was presented at the Medicine–Pediatrics Conference.

Dr. Winter reports receiving grant support from Nutricia, UCB, Centocor, AstraZeneca, Takeda Pharmaceuticals, and Warner Chilcott; consulting fees from AstraZeneca, Shire, and Centocor; payment for expert testimony from Martin, Magnuson, McCarthy & Kenney, Marshall, Dennehey, Warner, Coleman & Goggin, and Duane Morris; and royalties from UpToDate. Dr. Gervais reports receiving grant support from Covidien (formerly Valleylab). Dr. Branda reports receiving grant support from Diasorin. No other potential conflict of interest relevant to this article was reported.

Disclosure forms provided by the authors are available with the full text of this article at NEJM.org.

We thank Drs. Chadi El Saleeby, Ian Michelow, Nina Mayer, and Mark Pasternack for their assistance with the preparation of the case history.

REFERENCES

1. Kanof ME, Lake AM, Bayless TM. Decreased height velocity in children and adolescents before the diagnosis of Crohn's disease. Gastroenterology 1988;95:1523-7.
2. Heikenen JB, Werlin SL, Brown CW, Balint JP. Presenting symptoms and diagnostic lag in children with inflammatory bowel disease. Inflamm Bowel Dis 1999;5:158-60.
3. Levy AD, Shaw JC, Sobin LH. Secondary tumors and tumorlike lesions of the peritoneal cavity: imaging features with pathologic correlation. Radiographics 2009;29:347-73.
4. Menczer J, Chetrit A, Barda G, et al. Frequency of BRCA mutations in primary peritoneal carcinoma in Israeli Jewish women. Gynecol Oncol 2003;88:58-61.
5. Cappell MS, Mandell W, Grimes MM, Neu HC. Gastrointestinal histoplasmosis. Dig Dis Sci 1988;33:353-60.
6. Arlet JB, Furco-Mazzantini A, Huerre M, Neuville S, Molina JM. African histoplasmosis infection with peritoneal involvement. Eur J Clin Microbiol Infect Dis 2004;23:342-4.
7. Sharma YR, Roy PK, Hasan M. Abdominal tuberculosis — a study of 25 cases. Kathmandu Univ Med J (KUMJ) 2004;2:137-41.
8. Ichikawa T, Takagi H, Mori M. Abdominal tuberculosis in the absence of pulmonary involvement shown by 2-[fluorine 18] fluoro-2-deoxy-D-glucose positron emission tomography. Clin Gastroenterol Hepatol 2009;7:A20.
9. Lee YJ, Yang SK, Byeon JS, et al. Analy-

The New England Journal of Medicine
Downloaded from nejm.org at UNIVERSITAETSKLINIKUMS on November 9, 2011. For personal use only. No other uses without permission.
Copyright © 2011 Massachusetts Medical Society. All rights reserved.

sis of colonoscopic findings in the differential diagnosis between intestinal tuberculosis and Crohn's disease. Endoscopy 2006;38:592-7.
10. Chiappini E, de Martino M, Mangiantini F, Lionetti P. Crohn disease and mycobacterial infection in children: an intriguing relationship. J Pediatr Gastroenterol Nutr 2009;49:550-8.
11. Kotru M, Rusia U, Sikka M, Chaturvedi S, Jain AK. Evaluation of serum ferritin in screening for iron deficiency in tuberculosis. Ann Hematol 2004;83:95-100.
12. Bhargava DK, Tandon HD, Chawla TC, Shriniwas, Tandon BN, Kapur BM. Diagnosis of ileocecal and colonic tuberculosis by colonoscopy. Gastrointest Endosc 1985;31:68-70.
13. Bhargava DK, Shriniwas, Chopra P, Nijhawan S, Dasarathy S, Kushwaha AK. Peritoneal tuberculosis: laparoscopic patterns and its diagnostic accuracy. Am J Gastroenterol 1992;87:109-12.
14. Manohar A, Simjee AE, Haffejee AA, Pettengell KE. Symptoms and investigative findings in 145 patients with tuberculous peritonitis diagnosed by peritoneoscopy and biopsy over a five year period. Gut 1990;31:1130-2.
Copyright © 2011 Massachusetts Medical Society.

LANTERN SLIDES UPDATED: COMPLETE POWERPOINT SLIDE SETS FROM THE CLINICOPATHOLOGICAL CONFERENCES

Any reader of the *Journal* who uses the Case Records of the Massachusetts General Hospital as a teaching exercise or reference material is now eligible to receive a complete set of PowerPoint slides, including digital images, with identifying legends, shown at the live Clinicopathological Conference (CPC) that is the basis of the Case Record. This slide set contains all of the images from the CPC, not only those published in the *Journal*. Radiographic, neurologic, and cardiac studies, gross specimens, and photomicrographs, as well as unpublished text slides, tables, and diagrams, are included. Every year 40 sets are produced, averaging 50-60 slides per set. Each set is supplied on a compact disc and is mailed to coincide with the publication of the Case Record.

The cost of an annual subscription is $600, or individual sets may be purchased for $50 each. Application forms for the current subscription year, which began in January, may be obtained from the Lantern Slides Service, Department of Pathology, Massachusetts General Hospital, Boston, MA 02114 (telephone 617-726-2974) or e-mail Pathphotoslides@partners.org.

The New England Journal of Medicine
Downloaded from nejm.org at UNIVERSITAETSKLINIKUMS on November 9, 2011. For personal use only. No other uses without permission.
Copyright © 2011 Massachusetts Medical Society. All rights reserved.