

INTERVERTEBRAL AND INTRAVERTEBRAL RATIOS IN DOBERMAN PINSCHER DOGS WITH CERVICAL SPONDYLOMYELOPATHY

RONALDO C. DA COSTA, JACQUELINE A. JOHNSON

No screening method is currently available to differentiate dogs with and without cervical spondylomyelopathy. Intravertebral and intervertebral ratios are used in horses and can predict cervical vertebral malformation. Intervertebral ratios could be a useful screening method for canine cervical spondylomyelopathy. Our purpose was to compare cervical intervertebral and intravertebral ratios in normal vs. affected Doberman pinschers. Forty dogs were studied, 27 affected and 13 normal. Cervical radiographs were obtained in all dogs. The minimum intra- and intervertebral sagittal diameter ratios were established for each cervical vertebrae and disc space from C₂ to C₇. Comparisons were made between groups and specific vertebral body and disc levels. The effect of gender, age, and method of measurement (analog or digital radiographs) was also studied. There was no difference in either the intervertebral or intravertebral ratio between normal vs. affected dogs. The ratios decreased progressively along the cervical spine, being smallest at C₆-C₇ and C₇, respectively. Age, gender, and method of measurement had a significant influence on both inter- and intravertebral ratios, with smaller ratios seen as dogs aged and in male dogs. Based on our results, inter- or intravertebral ratios have no value to distinguish between clinically normal Doberman pinschers and Doberman pinschers with cervical spondylomyelopathy. © 2012 *Veterinary Radiology & Ultrasound*.

Key words: cervical instability, dog, myelopathy, spinal cord, wobbler syndrome.

Introduction

CERVICAL SPONDYLOMYELOPATHY, also known as wobbler syndrome, is common in large and giant breed dogs.¹ The Doberman pinscher is the most commonly affected breed,²⁻⁵ with a prevalence in the United States of approximately 5.5%.^{*} Cervical spondylomyelopathy is characterized by stenosis of the cervical vertebral canal combined with static and dynamic spinal cord compression.¹ In Dobermans, the disease is typically associated with caudal cervical intervertebral disc protrusion,²⁻⁵ but disc protrusion by itself, however, does not necessarily lead to clinical signs. It appears that for clinical disease to develop, intervertebral disc protrusion has to be combined with vertebral canal stenosis,^{6,7} as disc protrusion occurs in normal Doberman pinschers without neurological deficits or changes in electrodiagnostic tests.^{6,8-10} The vertebral canal stenosis seen in Doberman pinschers appears to be congenital and affects the entire cervical spine, not only the caudal cervical discs, where spinal cord compression typically occurs.^{6,11} Canine cervical spondylomyelopa-

thy bears some similarities with cervical vertebral malformation (CVM) in horses and with cervical spondylotic myelopathy in humans.¹²⁻¹⁴ In both horses and humans, cervical intravertebral ratios are routinely used in the diagnosis and screening of patients with cervical stenosis.^{13,15}

The cervical vertebral ratio was employed in Doberman pinschers and Great Danes 10 years ago with the hope that it could be used as a breed-specific screening tool.¹⁶ More recently, the use of vertebral body ratio has been implemented.^{17,18} All these studies evaluated the use of the *intravertebral* ratio, which is the height of the vertebral canal normalized against the height of the respective vertebral body in lateral radiographs. *Intervertebral* ratios have also been used most recently in horses.¹⁹ Intervertebral ratios differ from intravertebral ratios because the height of the vertebral canal is expressed against the distance of the vertebral body to the cranial or caudal lamina. Intervertebral ratios have been suggested to be superior to intravertebral ratios in the diagnosis of CVM in horses.¹⁹ The use of intervertebral ratios is interesting because dogs with disc-associated cervical spondylomyelopathy may have narrowing of the intervertebral disc space along with vertebral canal stenosis, which could potentially lead to reduced intervertebral ratios.

There are numerous benefits to having a simple, noninvasive, method to screen dogs for cervical spondylomyelopathy. Should a strong relationship be found between vertebral ratios and cervical spondylomyelopathy, the disease can be diagnosed presumptively and these dogs could be

From the Department of Veterinary Clinical Sciences, College of Veterinary Medicine, The Ohio State University, 601 Vernon Tharp, Columbus, OH, 43210

*Veterinary Medical Database 2010.

Address correspondence and reprint requests to Ronaldo C. da Costa, at the above address. E-mail: dacosta.6@osu.edu

Received December 8, 2011; accepted for publication March 29, 2012.
doi: 10.1111/j.1740-8261.2012.01945.x

Vet Radiol Ultrasound, Vol. 53, No. 5, 2012, pp 518-523.

used in genetic studies. Currently, many aspects of cervical spondylomyelopathy are still poorly understood. A major topic that needs to be addressed is the heritability of the disease. Even though the disease is commonly thought to be genetic, a heritable basis has not been defined.^{20,21} The use of vertebral ratios could become a useful method for phenotypic characterization of the disease.

Our goal was to investigate the value of inter- and intravertebral ratios in Doberman pinscher dogs. Our hypothesis was that the cervical inter- or intravertebral ratios would be significantly different between normal dogs and dogs with cervical spondylomyelopathy and that the intervertebral ratio could be used as a screening method.

Materials and Methods

Forty Doberman pinscher dogs were studied. All dogs were examined by the first author. Twenty-seven were affected with cervical spondylomyelopathy (16 males and 11 females). The mean age was 6.6 years (range 3–12 years). The diagnosis of cervical spondylomyelopathy was defined as MR-imaging findings of spinal cord compression caused by intervertebral disk protrusion, osseous compression, soft-tissue compression, or a combination of these forms, with or without vertebral canal stenosis in a dog with clinical and historical findings suggestive of cervical spondylomyelopathy (CSM).⁴ Imaging was done at either 1.5 T or 3.0 T. All compressive lesions were in the caudal cervical spine: C₅–C₆ in 11 dogs and at C₆–C₇ in 16 dogs. In 25 of 27 dogs, the compression was caused by intervertebral disc protrusion, with three of these dogs also having dorsal compression due to hypertrophy of the ligamentum flavum. The two remaining dogs had osteoarthritic changes of the articular processes causing mild dorsolateral compression.

The remaining 13 Doberman pinschers (nine males and four females) were normal (no historical signs of CSM, and normal neurologic examination). Their mean age was 4.2 years (range 1–7 years). MR imaging was done in six of these dogs and none had spinal cord compression.

Radiographs adequate for measurements were available for all dogs. Only lateral radiographs with the cervical spine in neutral position were used for measurements. The radiograph included the caudal occiput to the cranial thoracic spine, with the thoracic limbs directed caudally. Radiographically, there was spondylosis at C₆–C₇ in seven affected and two normal dogs. Vertebral body tipping was present in nine affected and four normal Doberman dogs. The radiographic landmarks could still be identified in those dogs with spondylosis and tipping. Measurements were made on analog radiographs in 24 dogs and digital radiographs in 16 dogs.

The minimum intra- and intervertebral sagittal diameter ratios were determined for cervical vertebrae C₃–C₇ and

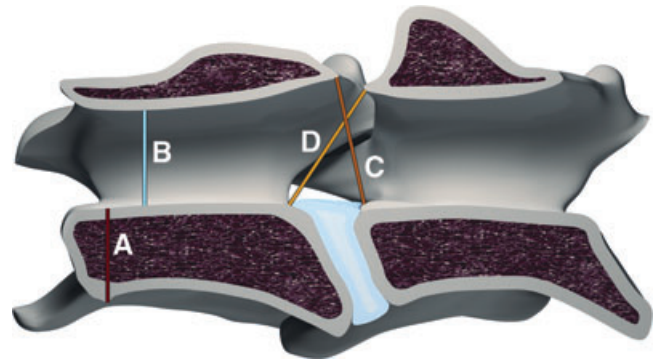


FIG. 1. Location of the radiographic measurements. (A) vertebral body height, (B) minimum intravertebral sagittal diameter (height of the vertebral canal), (C and D) locations for the intervertebral measurements for determination of the minimum intervertebral sagittal diameter.

disc space from C₂ to C₇. All measurements were made independently by both authors twice with at least 1-week interval between measurements. For measurements from analog radiographs, both investigators were unaware of the clinical status, whereas for the digital radiographs only one investigator was unaware of the clinical status (JJ). Measurements from analog images were made using digital calipers,* and in the digital radiographs we used the built in tool on eFilm.^{†,22} The landmarks used for measurements (Figure 1) were identified as

1. Vertebral body height—the maximum height of the cranial aspect of the vertebral body determined by a line drawn perpendicular to the path of the vertebral canal.
2. Minimum intravertebral sagittal diameter—the minimum diameter of the vertebral canal measured in the cranial third of the vertebral body.
3. Minimum intervertebral sagittal diameter¹⁹—we used the minimum of either as follows:
 - (a) A line drawn from the dorsal lamina of the more cranial vertebrae to the dorsocranial aspect of the body of the more caudal vertebrae, or
 - (b) a line drawn from the caudodorsal aspect of the body of the more cranial vertebrae to the cranial dorsal lamina of the more caudal vertebrae.

To account for radiographic magnification, the intra- and intervertebral sagittal diameters were expressed as a ratio against the vertebral body height. For the intervertebral ratio, the height of the more cranial vertebrae was used.

Linear regression was used to test differences in the ratio of the minimum intra- or the intervertebral sagittal diameter to the vertebral body height across dogs with or without cervical spondylomyelopathy. The regression was adjusted for age, gender, and method of measurement

*Mitutoyo CD-6"CS, Aurora, IL.

†eFilm Merge Healthcare 2006.

TABLE 1. Comparison of the Minimum Intervertebral Ratios in Normal and Affected Doberman Pinschers

Intervertebral Level	Normal	Affected	<i>P</i> -value
C ₂₃	0.91 (0.86–0.96)*	0.87 (0.82–0.92)	0.141
C ₃₄	0.80 (0.75–0.85)	0.77 (0.72–0.81)	0.162
C ₄₅	0.80 (0.72–0.88)	0.80 (0.75–0.84)	0.661
C ₅₆	0.77 (0.70–0.84)	0.77 (0.72–0.82)	0.968
C ₆₇	0.74 (0.68–0.80)	0.73 (0.68–0.77)	0.574

*95% confidence interval.

(analog and digital radiographs). Before running the regression analysis, the ratios were natural log-transformed to stabilize the increased variance inherent in the ratio of two random variables. Multivariate linear regression using age, gender, and cervical spondylomyelopathy status was assessed to estimate whether these predictors affected the inter- and intravertebral ratios.

Logistic regression was used to estimate if the log-transformed ratios were predictive of cervical spondylomyelopathy. The area under the receiver operator characteristic (ROC) curve was generated following the logistic regression to estimate how well the ratio discriminates which dog has cervical spondylomyelopathy along with the Hosmer–Lemeshow goodness-of-fit *P*-value. These models were also adjusted for age, gender, and method of measurement. Interobserver and intraobserver agreement was estimated using the proportion of total variance that is between subjects (ρ) using a variance components model based on a random-effects linear regression, more rigorous than other agreement tests such as Bland–Altman plots.^{23,24} If ρ is close to 1.0 then the observations are in agreement, whereas if it is close to 0 then there is little agreement. ρ was estimated for the intravertebral and intervertebral ratios between investigators and within the measurements from a single investigator. The coefficient of variation, represented by a percentage of variation between observers and intraobservers was also determined. All statistical methods were done using Stata.[‡]

Results

The intervertebral sagittal diameter ratios were smaller in most vertebral levels but without any significant statistical difference between cervical spondylomyelopathy-affected and clinically normal dogs ($P = 0.25$; Table 1). The intervertebral ratios decreased progressively along the cervical spine with the smallest ratio being at C₆–C₇ in both groups. The intervertebral ratios were significantly associated with gender ($P < 0.001$) in both groups. Male dogs had a smaller ratio across all intervertebral levels and the effect of male gender was estimated to decrease the intervertebral ratios

TABLE 2. Comparison of the Minimum Intravertebral Ratios in Normal and Affected Doberman Pinschers

Intravertebral Level	Normal	Affected	<i>P</i> -value
C ₃	0.66 (0.60–0.71)*	0.63 (0.60–0.66)	0.256
C ₄	0.64 (0.57–0.71)	0.60 (0.57–0.63)	0.063
C ₅	0.64 (0.56–0.73)	0.65 (0.62–0.68)	0.938
C ₆	0.59 (0.52–0.65)	0.60 (0.56–0.65)	0.424
C ₇	0.57 (0.52–0.62)	0.58 (0.54–0.63)	0.691

*95% confidence interval.

by 11% (multiplier = 0.89, 95% CI: 0.85–0.94) relative to female dogs. Age also proved to be a significant factor ($P = 0.012$) for both groups. For each 1-year increase in age, the intervertebral ratios decreased by 1.5% (multiplier = 0.985, 95% CI: 0.97–0.996). The average effect of making the measurements using digital calipers was to decrease the ratio by 14% (multiplier = 0.86, 95% CI: 0.82–0.91, $P = 0.001$).

There was no significant difference in intravertebral ratios between Doberman pinschers with and without cervical spondylomyelopathy ($P = 0.35$; Table 2). The intravertebral ratios decreased progressively along the cervical spine with the smallest ratio being at C₇. Similar to intervertebral ratios, there was a significant effect of gender ($P < 0.001$) with male dogs having a smaller ratio across all intravertebral levels. The effect of male gender decreased the intravertebral ratios by 10% (multiplier = 0.90, 95% CI: 0.86–0.95) relative to female dogs. Similarly, the age of dogs was also a significant factor. For each 1-year increase in age, the intravertebral ratios decreased by 1.5% (multiplier = 0.985, 95% CI: 0.98–0.99, $P = 0.004$). The average effect of making the measurements using digital calipers was to decrease the ratio by 15% (multiplier = 0.85, 95% CI: 0.81–0.89, $P = 0.001$).

No ratio was significant to predict cervical spondylomyelopathy status (Table 3). Receiver operating characteristic (ROC) curves were developed for all levels; however, the area under the ROC curve proved to yield poor discrimination to predict cervical spondylomyelopathy status (Table 3 and Figure 2).

The intraobserver agreement for the first investigator for the intra- and intervertebral ratios was 0.65 and 0.65, respectively. The intraobserver agreement for the second investigator was 0.41 and 0.51 for the intra- and intervertebral ratios, respectively. The interobserver agreement between investigators for the intravertebral ratios was 0.54, and for the intervertebral ratios it was 0.60. These results indicate fair agreement for most of these parameters.

The intraobserver coefficient of variation for all measurements was 18.92% (17.44% for the first investigator and 20.41% for the second investigator). The intraobserver coefficient of variation was similar for the measurements made using analog radiographs or digital radiographs, 19.78% and 18.07%, respectively.

[‡]Stata 11.1, Stata Corporation, College Station, TX.

TABLE 3. Odds of Cervical Spondylomyelopathy and Area Under the ROC Curve Using Logistic Regression for Both Intra- and Intervertebral Ratios

	OR*	95% CI	<i>P</i> -value	Area under ROC Curve	H-L GOF <i>P</i> -value†
Intravertebral ratio					
C ₃	1.50	0.66	3.41	0.334	0.735
C ₄	1.96	0.89	4.32	0.095	0.795
C ₅	0.95	0.46	1.94	0.888	0.749
C ₆	0.66	0.31	1.41	0.282	0.637
C ₇	1.17	0.63	2.17	0.623	0.638
Intervertebral ratio					
C ₂₃	1.63	0.76	3.53	0.212	0.729
C ₃₄	2.13	0.79	5.70	0.134	0.722
C ₄₅	1.20	0.53	2.72	0.659	0.668
C ₅₆	0.97	0.40	2.35	0.946	0.709
C ₆₇	1.40	0.64	3.05	0.398	0.701

*The odds ratios are adjusted by measurement method (caliper vs. computer), age, and gender and the odds ratio is defined for a 0.1 unit decrease in the intra- or the intervertebral ratio.

† *P*-value based on the Hosmer–Lemeshow goodness-of-fit (H-L GOF) test where *P*-values greater than a significance level of 0.05 indicates a good fit since the null hypothesis is that the model fits the data.

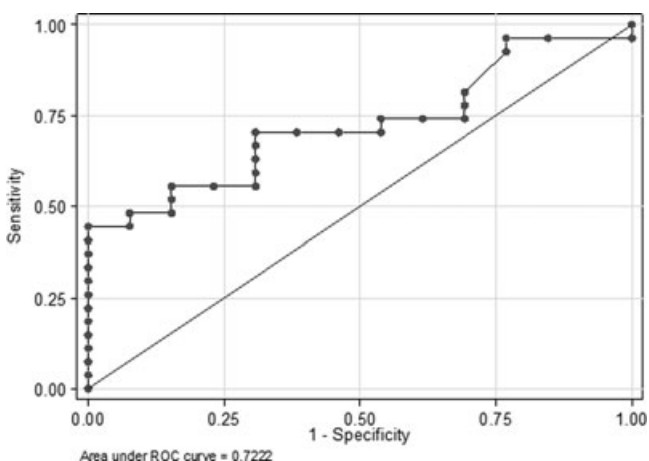


FIG. 2. Receiver–operator characteristic curve of the intervertebral ratios at C₃–C₄. The area under the ROC curve was 0.72.

The interobserver coefficient of variation was in a similar range to the intraobserver measurements, at 20.25%. The coefficient of variation was slightly higher for the measurements made on digital radiographs, 21.98%, compared to 18.52% on analog radiographs.

Discussion

Contrary to our hypothesis, we did not find a significant difference between either the inter- or intravertebral ratio in normal vs. affected Doberman pinschers and therefore the ratios had no value as a predictor of disease. Disparate results were found in previous studies evaluating intravertebral ratios in dogs. In one study, only the C₆ and C₇ ratios were different between Dobermans with and without spinal cord compression.¹⁶ Others found no difference in the intravertebral ratios in Doberman pinschers with and without cervical spondylomyelopathy.¹⁷ Lastly, others found that intravertebral ratios were signif-

icantly different at all levels between C₃ and C₇, but the difference was not adequate for the ratios to be used as a predictor.¹⁸

Differences in the techniques used for determination of intravertebral ratios may explain the variation in these results. We established vertebral body height as the height of the cranial aspect of the vertebral body determined by a line drawn perpendicular to the path of the vertebral canal, as in horses.¹⁹ Others used the maximum height of the cranial 25% of the vertebral body made parallel to the cranial vertebral endplate,¹⁶ which is slightly different from our method. Another method involves measuring vertebral body height at the level of the cranial endplate and the vertebral canal based on the cranial aspect of the vertebral canal.¹⁷ A recent study established the vertebral canal and vertebral body height in the midpoint of the vertebral canal.¹⁸ The midpoint of the vertebral body follows the original description of the Pavlov ratio in humans,²⁵ however, the shape of the human vertebral bodies differs greatly from the one in dogs. As spinal cord compression typically occurs in the cranial aspect of the vertebral canal and the vertebral canal may have a funnel shape in the caudal cervical spine,²⁶ it seems logical to base measurements in the cranial aspect of the vertebrae. Having a consistent measurement method across studies, or making original data available for reassessment by others, is important to allow comparison of work done at different sites.

The imaging method can also influence the findings as significant differences have been found in vertebral canal and vertebral height measurements from analog images, but not from digital images.¹⁶ We also observed that the method of measurement had a significant influence in both inter- and intravertebral ratios. However, independent on the measurement technique used in this study no difference was found between groups.

The inter- and intravertebral ratio was smallest at the C₆–C₇ and C₇ in normal and affected dogs, which agrees

with morphometric findings from an *ex vivo* and an MR-imaging study.^{6,26} Based on actual measurements, the height of the cranial aspect of the vertebral canal of large breed dogs, particularly Doberman pinschers, is significantly smaller than in small breeds, resulting in a funnel-shaped vertebral canal, mainly in the caudal cervical spine.²⁶ Also, based in MR images, Doberman pinschers with cervical spondylomyelopathy have stenosis of the cervical spine throughout the entire cervical spine, not just at the caudal cervical region, where most clinical lesions have been recognized.⁶ This suggests that affected Dobermans may have a relative stenosis throughout the entire cervical vertebral canal, which could predispose to clinical signs from minimally compressive disc or articular process disease. In people, cervical stenosis is a fundamental condition for the development of clinical signs associated with cervical spondylotic myelopathy.^{27–29}

We found that both the intra- and intervertebral ratios were smaller in male Doberman pinschers, independent of clinical status. This has also been observed in people, with males having a smaller intravertebral ratio than females.^{30,31} The clinical significance of this finding is unknown because a gender predisposition has not been identified in Doberman pinschers with cervical spondylomyelopathy.¹ As dogs aged the vertebral canal became significantly smaller (1.5% per year). This was observed previously when using a variation of the intravertebral ratio but not the classical intravertebral ratio.¹⁸ This may explain why Dobermans pinschers do not develop clinical signs of cervical spondylomyelopathy until approximately 6 years of age, even though they are born with congenital vertebral canal stenosis.^{6,11} In people, the ratios are also larger in young people.³²

In people, the Torg–Pavlov ratio is the sagittal diameter of the vertebral canal relative the sagittal diameter of the corresponding vertebral body.²⁵ A ratio of less than 0.82 is associated with cervical vertebral canal stenosis. When used specifically for evaluation of cervical spondylotic myelopathy, the Torg–Pavlov ratio differs significantly different between people with and without the disease.¹⁵ The Torg–Pavlov ratio was adapted for investigation of CVM in horses. Intravertebral sagittal diameter ratios of less than 0.52 for C₃–C₆ and less than 0.56 for C₇ were associated with vertebral foramen narrowing.¹³ When comparing intravertebral with intervertebral sagittal diameter ratios, both were of use in differentiating horses with CVM, especially the intervertebral measurements.¹⁹ We designed our investigation with the expectation that intervertebral ratios would assist in the identification of Doberman pinschers with cervical spondylomyelopathy. Since Doberman pinschers with cervical spondylomyelopathy have vertebral canal stenosis along with intervertebral disc protrusion, the protrusion could decrease the intervertebral space, which could then lead to smaller intervertebral ratios in affected dogs. Unfortunately, our results do not support this hypothesis.

Based on our results of the current study, we conclude that neither the intervertebral nor intravertebral ratio is suitable as a screening method to differentiate Doberman pinschers with and without cervical spondylomyelopathy. As the ratios appear to be breed specific,¹⁶ the results of this study apply only to Doberman pinschers.

ACKNOWLEDGMENTS

The authors acknowledge the assistance of Gary Phillips, Center of Biostatistics, The Ohio State University Medical Center, for the statistical analysis presented in this manuscript.

REFERENCES

1. da Costa RC. Cervical spondylomyelopathy (wobbler syndrome) in dogs. *Vet Clin North Am Small Anim Pract* 2010;40:881–913.
2. Lewis DG. Cervical spondylomyelopathy ('wobbler' syndrome) in the dog: a study based on 224 cases. *J Small Anim Pract* 1989;30:657–665.
3. McKee WM, Butterworth SJ, Scott HW. Management of cervical spondylopathy-associated intervertebral disc protrusions using metal washers in 78 dogs. *J Small Anim Pract* 1999;40:465–472.
4. da Costa RC, Parent JM, Holmberg DL, Sinclair D, Monteith G. Outcome of medical and surgical treatment in dogs with cervical spondylomyelopathy: 104 cases (1988–2004). *J Am Vet Med Assoc* 2008;233:1284–1290.
5. De Decker S, Bhatti SF, Duchateau L, et al. Clinical evaluation of 51 dogs treated conservatively for disc-associated wobbler syndrome. *J Small Anim Pract* 2009;50:136–142.
6. da Costa RC, Parent JM, Partlow G, Dobson H, Holmberg D, LaMarre J. Morphologic and morphometric magnetic resonance imaging features of Doberman pinscher dogs with and without clinical signs of cervical spondylomyelopathy. *Am J Vet Res* 2006;67:1601–1612.
7. da Costa RC. Pathogenesis of cervical spondylomyelopathy: lessons from recent years. *Proceedings of the 25th Annual American College of Veterinary Internal Medicine Forum*, Seattle, WA, 2007;318–320.
8. da Costa RC, Poma R, Parent JM, Partlow G, Monteith G. Correlation of motor evoked potentials with magnetic resonance imaging and neurological findings in Doberman pinscher dogs with and without signs of cervical spondylomyelopathy. *Am J Vet Res* 2006;67:1613–1620.
9. De Decker S, Gielen IM, Duchateau L, et al. Low-field magnetic resonance imaging findings of the caudal portion of the cervical region in clinically normal Doberman pinschers and Foxhounds. *Am J Vet Res* 2010;71:428–434.
10. De Decker S, Van Soens I, Duchateau L, et al. Transcranial magnetic stimulation in Doberman pinschers with clinically relevant and clinically irrelevant spinal cord compression on magnetic resonance imaging. *J Am Vet Med Assoc* 2011;238:81–88.
11. Burbidge HM, Pfeiffer DU, Guilford WG. Presence of cervical vertebral malformation in Dobermann puppies and the effects of diet and growth rate. *Aust Vet J* 1999;77:814–818.
12. de Lahunta A, Glass EN. General sensory systems: general proprioception and general somatic afferent. In: de Lahunta A, Glass EN (eds): *Veterinary neuroanatomy and clinical neurology*, 3rd ed. St. Louis, MO: Saunders, 2009;221–242.
13. Moore BR, Reed SM, Biller DS, Kohn CW, Weisbrode SE. Assessment of vertebral canal diameter and bony malformations of the cervical part of the spine in horses with cervical stenotic myelopathy. *Am J Vet Res* 1994;55:5–13.

14. Sharp NJ, Cofone M, Robertson ID, DeCarlo A, Smith GK, Thrall DE. Cervical spondylomyelopathy in the Doberman dog: a potential model for cervical spondylotic myelopathy in humans. *J Invest Surg* 1989;2:333.
15. Yue WM, Tan SB, Tan MH, Koh DC, Tan CT. The Torg-Pavlov ratio in cervical spondylotic myelopathy: a comparative study between patients with cervical spondylotic myelopathy and a nonspondylotic, nonmyelopathic population. *Spine* 2001;26:1760–1764.
16. Drost WT, Lehenbauer TW, Reeves J. Mensuration of cervical vertebral ratios in Doberman pinschers and Great Danes. *Vet Radiol Ultrasound* 2002;43:124–131.
17. Lautersack O, Schimke E. The wobblers syndrome (cervical spondylomyelopathy) in the Doberman pinscher—an investigation on the vertebral anatomy and biomechanical properties. Part 2. *Kleintierpraxis* 2003;11:666–678 (in German).
18. De Decker S, Saunders JH, Duchateau L, Pey P, Van Ham LM. Radiographic vertebral canal and vertebral body ratios in Doberman pinschers with and without clinical signs of caudal cervical spondylomyelopathy. *Am J Vet Res* 2011;72:958–966.
19. Hahn CN, Handel I, Green SL, Bronsvooort MB, Mayhew IG. Assessment of the utility of using intra- and intervertebral minimum sagittal diameter ratios in the diagnosis of cervical vertebral malformation in horses. *Vet Radiol Ultrasound* 2008;49:1–6.
20. Lewis DG. Radiological assessment of the cervical spine of the Doberman with reference to cervical spondylomyelopathy. *J Small Anim Pract* 1991;32:75–82.
21. Burbidge HM, Pfeiffer DU, Blair HT. Canine wobblers syndrome: a study of the Doberman pinscher in New Zealand. *N Z Vet J* 1994;42:221–228.
22. Prasad SS, O'Malley M, Caplan M, Shackelford IM, Pydisetty RK. MRI measurements of the cervical spine and their correlation to Pavlov's ratio. *Spine* 2003;28:1263–1268.
23. Rabe-Hesketh S, Skrondal A. *Multilevel and longitudinal modeling using Stata*. College Station, TX: Stata Press, 2005.
24. Searle SR, Casella G, McCulloch CE. *Variance components*. New York: Wiley, 1992.
25. Pavlov H, Torg JS, Robie B, Jahre C. Cervical spinal stenosis: determination with vertebral body ratio method. *Radiology* 1987;164:771–775.
26. Breit S, Kunzel W. Osteological features in pure-bred dogs predisposing to cervical spinal cord compression. *J Anat* 2001;199:527–537.
27. Yu YL, du Boulay GH, Stevens JM, Kendall BE. Computed tomography in cervical spondylotic myelopathy and radiculopathy: visualisation of structures, myelographic comparison, cord measurements and clinical utility. *Neuroradiology* 1986;28:221–236.
28. Bernhardt M, Hynes RA, Blume HW, White AA, 3rd. Cervical spondylotic myelopathy. *J Bone Joint Surg Am* 1993;75:119–128.
29. White AA, 3, Panjabi MM. Biomechanical considerations in the surgical management of cervical spondylotic myelopathy. *Spine* 1988;13:856–860.
30. Hukuda S, Kojima Y. Sex discrepancy in the canal/body ratio of the cervical spine implicating the prevalence of cervical myelopathy in men. *Spine* 2002;27:250–253.
31. Lim JK, Wong HK. Variation of the cervical spinal Torg ratio with gender and ethnicity. *Spine J* 2004;4:396–401.
32. Goto S, Umehara J, Aizawa T, Kokubun S. Comparison of cervical spinal canal diameter between younger and elder generations of Japanese. *J Orthop Sci* 2010;15:97–103.