

## Original Article

### Fractal Study on Nuclear Boundary of Cancer Cells in Urinary Smears

Farahnaz Noroozinia <sup>1</sup>, Gholamreza Behjati <sup>2</sup>, Shahram Shahabi <sup>3</sup>,  
Hamidreza Farrokh Islamlo <sup>4</sup>, Zuhair Mohammad Hassan <sup>5</sup>, Behrouz Ilkhanizadeh <sup>1</sup>

1- Dept. of Pathology, Urmia University of Medical Sciences, Urmia, Iran

2- Dept. of Pathology, Isfahan Legal Medicine Organization, Isfahan, Iran

3- Dept. of Immunology, Urmia University of Medical Sciences, Urmia, Iran

4- Dept. of Public Health, Urmia University of Medical Sciences, Urmia, Iran

5- Dept. of Immunology, Tarbiat Modares University, Tehran, Iran

#### ABSTRACT

**Background & Objectives:** Cancer is a serious problem for human being and is becoming a serious problem day-by-day .A prerequisite for any therapeutic modality is early diagnosis. Automated cancer diagnosis by automatic image feature extraction procedures can be used as a feature extraction in the field of fractal dimension. The aim of this survey was to introduce a quantitative and objective mathematical method for pinpointing the differences between malignant and non –malignant epithelial cells in urine cytology by the use of software analysis.

**Materials & Methods:** Forty-one positive urine cytology and 33 negative subjects from Pathology Department of Imam Khomeini Hospital, Urmia, Iran (2003-2007) were selected at random. Digitalized images were prepared by the use of objective 100X (a digital video head) which subsequently were processed by the Beonit™ software version 1.3 (Tru Soft International inc. USA) to measure fractal dimension of nuclear boundaries.

**Results:** Findings revealed statistically significant differences between fractal dimensions of nuclear boundaries of cancerous and non-cancerous smears (P=0.001). Study had selected a cut-off point to (1.732±0.006) to discriminate malignant and non-malignant epithelial cells in urinary smears.

**Conclusion:** Based on diagnostic accuracy measures (sensitivity and specificity), probability of disease measures (predictive value of a positive and negative test results), and likelihood ratio of positive and negative tests, it seems fractal dimension of nuclear cell boundaries for urinary smears can be used as a feature extraction in the field of automated cancer diagnosis.

**Key words:** Automated Cancer Diagnosis, Screening Machine Design, Fractal Dimension

---

Received: 15 May 2010

Accepted: 10 October 2010

Address communications to: Dr Behrouz Ilkhanizadeh , Department of Pathology, Urmia University of Medical Sciences, Urmia, Iran

Email: Ilkhanib@gmail.com

## Introduction

It can be obtained from incidences of cancer around the world and our country, that approximately one out of every two men and three women are infected by cancer during their lifetime (1).

The computational diagnostic tool in which objective judgment is taken by the use of quantitative measures is called automated cancer diagnosis. Automated cancer diagnosis can be divided into three steps based on histopathology:

- 1- Primary preprocessing
- 2- Feature extraction
- 3- Classifying between normal and malignancy (1).

Traditionally diagnostic judgment was based on histological findings and needed biopsy. Urine cytology examination is a non-invasive method in comparison with biopsy method (2).

Based on previous surveys, the mathematician Benoit Mandelbrot formulated the concept of fractal geometry. These applications have been introduced by the mentioned mathematician:

- 1- Molecular Pathology
- 2- Tumor Pathology
- 3- Bone Pathology
- 4- Vascular Pathology
- 5- Neuro Pathology
- 6- Making models for biological process
- 7- Miscellaneous applications in Pathology.

The geometry of herpes simplex corneal ulcers, distinction between heterochromatin and euchromatin in electron micrographs (3).

The ability to qualify the degree of the complexity and irregularity of objects with a measurable value is called fractal dimension. A fractal object has fractal dimensions with complexity, self-similar pattern. The fractal dimensions differ from the topological dimension. It can be noted that box

counting is the most widely method which is used for fractal dimension measurement (3, 4).

Simon *et al.* study revealed colorectal polyps, and particularly tubulovillous adenoma have arborizing patterns with some self-similarity and might be expected to have fractal element to their structure (3). James *et al.* have shown outlines of basic methods of fractal and have discussed the value and limitation of applying the new tool in cancer research (4).

There are several application for fractal geometry in histopathology and cytology in which these applications have been used for the estimation of fractal dimension in cancers, cervix uteri (5), oral (6) and endometrium (7), imaging (digital mammograms (8), prostate image (9) and other conditions (bone architecture) (10).

The aim of this survey was to introduce a quantitative and objective mathematical method for pinpointing the differences between malignant and non-malignant epithelial cells in urine cytology by the use of software analysis. In literature, this type of research is named as process research and method comparison (11, 12).

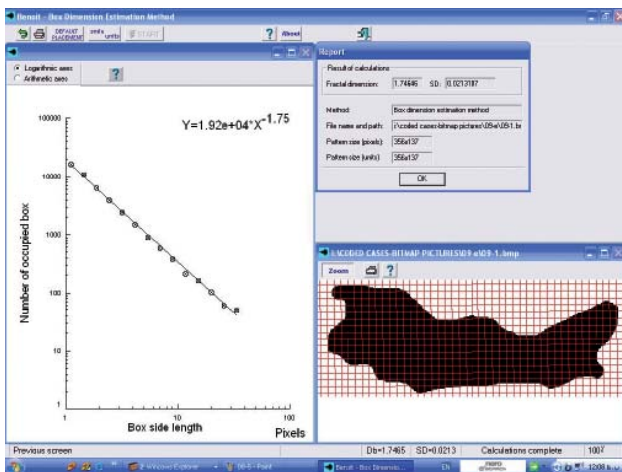
## Material and Methods

All the reviewed urine cytology slides were taken from Pathology Department of Imam Khomeini Hospital, Urmia, Iran (2003-2007). A total of 71 cases of positive cytology were found and among these cases 41 positive smears confirmed by biopsy were reviewed. Among 200 cases, 33 negative subjects were selected randomly and were stained with papa Nicola; the stained slides were evaluated under conventional light microscopy that is equipped with digital camera. Nuclear captured images were photographed from five randomly selected epithelial cells. Figure 1 demonstrates the digitalized image in black and white obtained from Photoshop software 7.



**Fig. 1:** Photoshop software Preprocessed nucleus

All nuclear images of positive and negative cases were coded. The fractal dimensions of nuclear boundaries by using the benoit version 1.3 software were measured. This software calculates fractal dimensions of nuclear boundary of each image by means of box-counting algorithm (Figure 2).

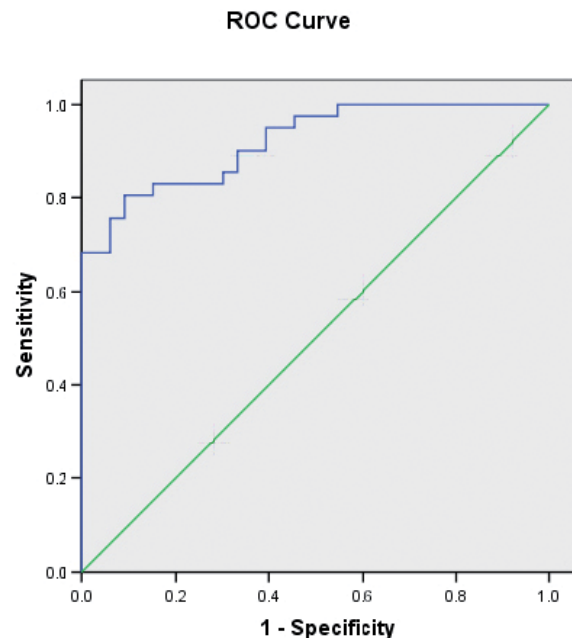


**Fig. 2:** Output of preprocessed picture in benoit software version 1.3

### Data Analysis

All the data were expressed as mean  $\pm$  SD and the analysis were done by SPSS version 14. Normal distribution was tested by kolmogrov-smirnov test and the analysis was taken by parametric tests such

as Z statistics. A receiver operating characteristics, ROC analysis was taken in order to evaluate the fractal dimensions measurement of epithelial cells in urine cytology as a diagnostic and screening test. The core of ROC curves is the idea of a cut-off level and the high and low cut-off level was calculated by ROC curve (Fig. 3).



**Fig. 3:** ROC Curve of cut off point

### Results

No statistical difference in regards to the male/female ratio was found between 37 male and 4 female of the 41 patients with transitional cell carcinoma with the average age of 69.2. Histological grade were 1 case grade I, 12 case grade II, 1 case Grade IV according to Ash classification system and 18 case Grade II, 8 case Grade III According to ISUP/WHO system.

A significant difference was shown by the Z test in comparison with  $1.7207 \pm 0.012$  in benign cell groups with malignant cells with the average of  $1.7502 \pm 0.018$ . The area under the ROC curve was 0.92 ( $P = 0.000$ ) which was  $> 0.9$  and located in excellent area (13). The resulted indices such as the diagnostic accuracy, probability of diseases and likelihood ratio are summarized in Table 1:

**Table 1:** Diagnostic Accuracy, Probability of Diseases, and Likelihood ratio

Index of the fractal dimensions measurement as a diagnostic and screening test	Calculated value (percent)
Sensitivity	82.9
Specificity	84.8
Positive Predictive value of a positive test result	87.1
Positive Predictive value of a negative test result	80.0
Likelihood ratio of a positive test result	5.45
Likelihood ratio of a negative test result	0.20

The diagnostic accuracy of sensitivity and specificity are 82.9 and 84.8 respectively and the indices are above 80%, which are at an acceptable position. Cut- off point with 95% confidence limit was calculated  $1.732 \pm 0.006$  that is useful to distinguish fractal dimensions of nuclear boundaries of the malignant and normal cells of the urine smears.

### Discussion

In this study, fractal analysis was applied in order to quantify nuclear irregularity of malignant urothelial cells in statistical comparison with non-malignant cells. Our study showed that fractal dimensions are higher in malignant cells than in normal cells and also fractal was used as a tool for converting qualitative nuclear border characteristic to quantitative measures in which these mathematical measures is used in screening machine of urine cytology for their base line.

Goutzanis *et al.* studies on nuclear fractal dimension as a prognostic factor in oral squamous cell carcinoma showed a correlation of fractal dimension between nuclear size and other morphometric characteristics, in the next step these factors were compared with clinicopathologic factors(6).

Kikuchi *et al.* studies on fractal analysis in endometrioid endometrial adenocarcinoma revealed mean fractal dimension in endometrioid carcinoma may differ according to histologic grades and concluded fractal geometry as a useful tool for analyzing complex and irregular tumor

growth patterns mathematically (7).

For automated classification of prostatic cancer according to gleason grading system Huang P.W and Lee CH used fractal analysis and by this means they concluded fractal analysis as a powerful discriminating capability in automatic classification for pathological prostate images (9).

Ohris *et al.* have shown significant difference in measuring fractal dimension on cytological smear and compare the fractal dimension of benign and malignant cell as well as cervical lesion according to image cytometer software result. They introduced fractal dimensions as a helpful discriminative technique for benign and malignant cell (11). Dey *et al.* have provided fractal dimensions of endometrial glands borders in simple hyperplasia, complex atypical hyperplasia, and endometrial carcinoma (12). Naeim *et al.* measured three different but structurally interrelated parameters: 1) cellular area 2) nuclear area 3) cell numbers in bone marrow components (14). A significant difference in the fractal dimension of malignant and benign cells was discovered when Dey *et al.* had used box-counting dimensions of breast cytology with an image cytometer used software analysis (15).

### Conclusion

Our study has shown a reliable method for distinguishing between control nuclei and malignant nuclei of urine cytology. This finding revealed the cutoff point of  $1.732 \pm 0.006$  fractal dimension with 95% confidence limit for malignant cell detection. The application of such cutoff point would

contribute to automated screening techniques in urine cytology. We suggest similar studies to test this cutoff point in urine cytology and determination of definite cutoff point.

### Acknowledgements

This study was supported by Research Council of Urmia Medical University. The authors declare that they have no conflicts of interest.

### References:

1. Demir C. and Yener B. Automated cancer diagnosis based on histopathological images: A systematic survey. Rensselaer Polytechnic Institute, TR-05-09, department of Computer Science, 2005.116-.
2. Gray W. Diagnostic Cytopathology. 2nd ed. London: Churchill Livingstone; 2003.
3. Cross SS. Fractals in pathology. *J Pathol* 1997;182(1):1-8.
4. Baish JW, Jain RK. Fractals and cancer. *Cancer Res* 2000;60(14):3683-8.
5. Sedivy R, Windischberger C, Svozil K, Moser E, Breitenacker G. Fractal analysis: an objective method for identifying atypical nuclei in dysplastic lesions of the cervix uteri. *Gynecol Oncol* 1999;75(1):78-83.
6. Goutzani L, Papadogeorgakis N, Pavlopoulos PM, Katti K, Petsinis V, Plochoras I, *et al.* Nuclear fractal dimension as a prognostic factor in oral squamous cell carcinoma. *Oral Oncol* 2008;44(4):345-53.
7. Kikuchi A, Kozuma S, Yasugi T, Taketani Y. Fractal analysis of surface growth patterns in endometrioid endometrial adenocarcinoma. *Gynecol Obstet Invest* 2004;58(2):61-7.
8. Guo Q, Shao J, Ruiz VF. Characterization and classification of tumor lesions using computerized fractal-based texture analysis and support vector machines in digital mammograms. *Int J Comput Assist Radiol Surg* 2009;4(1):11-25.
9. Huang PW, Lee CH. Automatic classification for pathological prostate images based on fractal analysis. *IEEE Trans Med Imaging* 2009;28(7):1037-50.
10. Tomomitsu T, Mimura H, Murase K, Sone T, Fukunaga M. Fractal analysis of bone architecture at distal radius. *Nippon Hoshasen Gijutsu Gakkai Zasshi* 2005;61(12):1592-8.
11. Ohri S, Dey P, Nijhawan R. Fractal dimension in aspiration cytology smears of breast and cervical lesions. *Anal Quant Cytol Histol* 2004;26(2):109-12.
12. Dey P, Rajesh L. Fractal dimension in endometrial carcinoma. *Anal Quant Cytol Histol* 2004;26(2):113-6.
13. Richard A, Mathew M, Pincus R. *Henry's Clinical Diagnosis and Management by Laboratory Methods*. 21st ed. New York: Saunders; 2007.
14. Naeim F, Moatamed F, Sahimi M. Morphogenesis of the bone marrow: fractal structures and diffusion-limited growth. *Blood* 1996;87(12):5027-31.
15. Dey P, Mohanty SK. Fractal dimensions of breast lesions on cytology smears. *Diagn Cytopathol* 2003;29(2):85-6.