


CASE REPORT**BLEACHING OF A NON - VITAL ANTERIOR TOOTH:
INSIDE/OUTSIDE TECHNIQUE**

Cristina Parise Gré DDS, MS *, **Jussara Karina Bernardon DDS, MS, PhD ****, **Luiz Clovis Cardoso Vieira DDS, MS, PhD****, **Hamilton Pires Maia DDS, MS, PhD****

* PhD student. Department of Operative Dentistry, Federal University of Santa Catarina, Florianópolis, Santa Catarina, Brazil. ** Professor, Department of Operative Dentistry, Federal University of Santa Catarina, Florianópolis, Santa Catarina, Brazil.

Address for correspondence: Cristina Parise Gré, Rua Beco dos Surfistas 323, Lagoa da Conceição, Florianópolis, SC 88062-620-Brazil.

Mob: (55-48) 99351354

Email: c_sufi@hotmail.com

Abstract : Discoloration of teeth, especially the anteriors, can result in considerably cosmetic impairment in person. Treatment options for discolored non-vital teeth are bleaching, crowns or veneers. However, this restorative crown or veneer approach has a significant drawback of being an invasive technique. This paper reports the inside/outside bleaching technique, and proposes it as an efficient and acceptable method for use in patients with an unaesthetic non- vital tooth.

Keywords: bleaching, non-vital tooth, tooth discoloration.



Scan this QR code to
access article.

INTRODUCTION

Discoloured teeth, especially in the anterior region, can impact on a person's, self-confidence, physical attractiveness and employability (1). The presence of a single discoloured tooth often creates a weak position, since that tooth stands out, drawing the attention of the observer.

Dissemination of blood components into the dentinal tubules caused by pulp extirpation or traumatically induced internal pulp bleeding are possible reasons for discoloration of non-vital teeth (2). Besides

invasive therapies, such as the placement of veneers or crowning, the dental bleaching is an alternative therapeutic method since it is a fast and low cost procedure, conserves dental hard tissue and provides a high level of satisfaction for patients (3). For a whitening treatment suitable in non-vital teeth, some factors must be considered, such as the etiology of discoloration, the amount of remaining dentin and their degree of discoloration, the quality of endodontic treatment and the absence of internal or external reabsorption.

Different materials can be used for internal bleaching, such as 35% hydrogen peroxide, 37% carbamide peroxide and sodium perborate (4-5). These materials can be used in different bleaching techniques, such as

external night-guard bleaching, walking bleach technique, non-vital power bleaching (6).

An inside/outside bleaching technique was originally described by Settembrini et al(7). In this technique, bleaching takes place within the tooth and on the outside of the tooth simultaneously. Bleaching gel is placed on the internal and external aspects of a non-vital, root filled, discoloured tooth and refreshed regularly.

The aim of this article is to describe the use of the inside/outside bleaching technique as an excellent management option in patients with a discoloured non-vital permanent incisor.

CASE REPORT

A 29-year-old female patient reported to the Federal University of Santa Catarina with a complaint of discolored upper front tooth and desired the discolored tooth be treated [Figure 1].

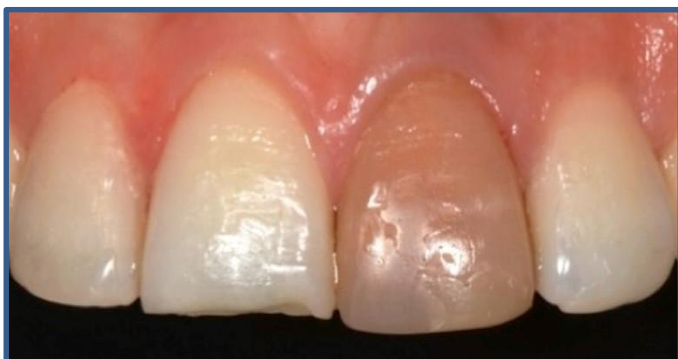

Fig.1: Discolored maxillary left central incisor tooth

On examination, maxillary left central incisor tooth presented a direct composite restoration on the buccal face. Vitality test was negative. Intra oral periapical radiograph with maxillary left central incisor revealed a complete root canal obturation without periapical pathology. Patient was explained about the bleaching procedure and consented for the inside and outside bleaching technique therapy to correct discolored tooth (7) using 37% carbamide peroxide (Powerbleaching 37% BM4 Materiais

Odontológicos, Palhoça, SC, Brazil) and 10% carbamide peroxide (Powerbleaching 10% BM4 Materiais Odontológicos, Palhoça, SC, Brazil). In the second session, after prophylaxis, the patient had the upper arch molded with alginate in order to construct a plastic bleaching tray. For bleaching occurred only on maxillary left central incisor tooth, the tray had the labial surface of the adjacent teeth cropped, therefore the bleaching gel does not come into contact with those teeth. After placing the rubber dam, the obturated material was removed from the tooth up to 3 mm below the cemento-enamel junction using a heated plugger. 1 mm zinc phosphate cement was placed over the gutta-percha as a protective seal (6) [Figure 2].

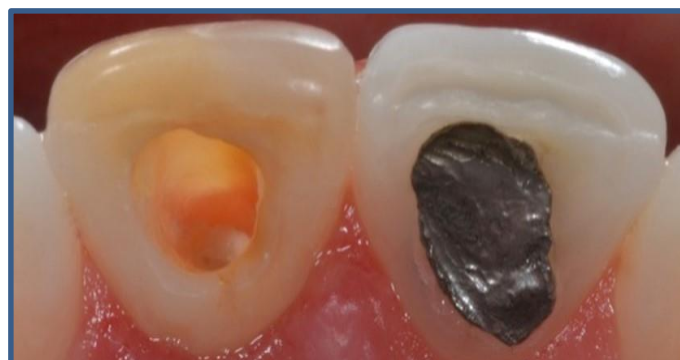

Fig.2: 1mm zinc phosphate cement seal *in situ* overlying gutta percha at CEJ

Pulp chamber was etched for 30 s using 37% phosphoric acid, washed and dried, which removes the smear layer and opens the dentinal tubules.

Following this, 37% carbamide peroxide bleaching agent was placed in the pulp chamber and on the external labial surface of the tooth. After 45 minutes, the tooth was cleansed and the residue bleach inside was removed with water using a high suction unit. The access and the partially empty pulp chamber were not restored. The patient was instructed to perform at-home bleaching as follows: inject bleaching gel (10% carbamide peroxide) into the

canal orifice; fill the tray reservoir with a pea sized amount of gel; insert the tray over the teeth and remove any excess gel. After 2 hours using the tray, the coronary orifice and the buccal surface were properly cleaned by the patient and a cotton ball was inserted into the pulp chamber. Orientations about the bleaching product and eating habits during the treatment period were given to the patient. The use of the tray with the bleaching gel occurred daily for a period of two hours during one week. After treatment [Figure 3], the canal was sealed with glass ionomer and a final composite restoration was bonded into place 10 days later.

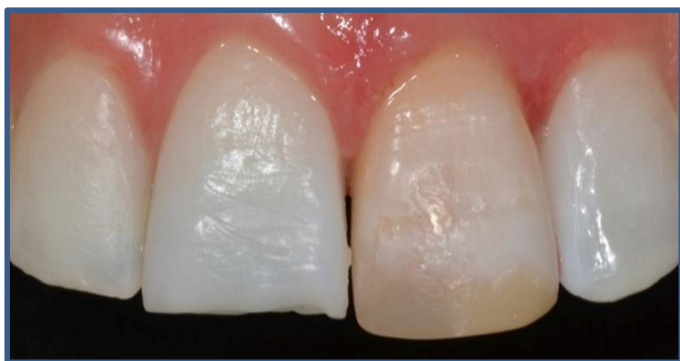

Fig.3: Post bleaching appearance of the discolored teeth

DISCUSSION

Different options are used in the treatment of discolored endodontically treated anterior tooth (6). In the present case report, we opted for the internal / external bleaching technique, in which the whitening gel is applied internally and externally simultaneously, thus allowing a faster treatment, since the oxygen released by carbamide peroxide can move freely both internally and externally (7). Furthermore, maintaining the pulp chamber accessible during bleaching procedure allows a proper penetration of the bleaching material into the discolored tooth (8). This technique demands cooperation of the patient, as they must inject the bleaching material from a needle-tipped syringe into

the pulp chamber of their own anterior tooth however, when properly instructed by the dentist, patients become adept at placing the material in the coronary orifice. We must also consider that the patient's desire to achieve an improved whitened effect causes them to train their own skills and help with treatment (7). In the present case, carbamide peroxide was used as an internal bleaching material due to its proven effectiveness and the low level of diffusion through the periodontal tissue and through the filling material (9,10). 37% carbamide peroxide and hydrogen peroxide in the same concentration are equally effective for internal bleaching (10) thus, the choice of carbamide peroxide makes the procedure safer, since there is less risk of resorption (3).

CONCLUSION

The above clinical case highlights the effectiveness of the inside/outside bleaching technique, in which bleaching takes place within the tooth and on the outside of the tooth simultaneously, producing successful and predictable cosmetic results.

REFERENCES

- 1-Kelleher, MC, Roe, FJ (1999) The safety-in-use of 10% carbamide peroxide (Opalescence) for bleaching teeth under the supervision of a dentist. *Br Dent J* 187 (4): 190-194.
2. Attin T, Paqué F, Ajam F, Lennon AM (2003) Review of the current status of tooth whitening with the walking bleach technique. *Int Endod J* May 36(5):313-29.
3. Badole GP, Warhadpande MM, Bahadure RN, Badole SG (2013) Aesthetic Rehabilitation of Discoloured Nonvital Anterior tooth with Carbamide Peroxide Bleaching: Case Series. *J Clin Diagn Res* 7(12):3073-6.

4. Leonardo RT, Kuga MC, Guiotti FA, Andolfatto C, Faria-Júnior NB, Campos EA, Keine KC, Dantas AA (2014) Fracture resistance of teeth submitted to several internal bleaching protocols. *J Contemp Dent Pract* Mar 1; 15(2):186-9.
5. Joiner A (2006) The bleaching of teeth: a review of the literature. *J Dent* 34:412-9.
6. Leith R, Moore A, O'Connell AC (2009) An effective bleaching technique for non-vital, discoloured teeth in children and adolescents. *J Ir Dent Assoc* Aug-Sep;55(4):184-9.
7. Settembrini L, Gultz J, Kaim J, Scherer W (1997) A technique for bleaching nonvital teeth: inside/outside bleaching *J Am Dent Assoc* Sep; 128(9):1283-4.
8. Howell RA (1980) Bleaching discoloured root-filled teeth. *Br Dent J* 148:159-62.
9. Lee GP, Lee MY, Lum SO, Poh RS, Lim KC (2004) Extraradicular diffusion of hydrogen peroxide and pH changes associated with intracoronal bleaching of discoloured teeth using different bleaching agents. *Int Endod J* Jul;37(7):500-6.
10. MY Lim, SO Lum, RS Poh, GP Lee, KC Lim KC (2004) An in vitro comparison of the bleaching efficacy of 35% carbamide peroxide with established intracoronal bleaching agents. *Int Endod J* 37:483-88.

How to cite this article:

Gré CP, Bernardon JK, Vieira LCC, Maia HP. Bleaching of a non - vital anterior tooth:inside / outside technique. *IJRD* 2015;4(2):40-43.