

Original Article

Benefit of a 360-degree horizontal turn following premedication with simethicone on image quality during gastroendoscopy: a randomized controlled trial

Chunhua Wang¹, Haiyan Liu¹, Xiuming Wang², Xiaochun Shen¹, Yingying Yang¹, Wenjing Sun¹, Qingjun Yan¹, Yan Cao¹, Xueqin Wang¹, Chunhui Lan¹, Dongfeng Chen¹

¹Department of Gastroenterology, Institute of Surgery Research Daping Hospital, Third Military Medical University, Chongqing, China; ²Department of Air Duty of Hospital 463 of PLA, Liaoning, Shenyang, China

Received January 11, 2015; Accepted February 25, 2015; Epub March 15, 2015; Published March 30, 2015

Abstract: Objectives: To investigate whether a 360-degree horizontal turn after oral premedication with simethicone improves the mucosal visibility during gastroendoscopic examination, and to determine the proper time to turn over the patient. Methods: This study involved 993 patients scheduled for gastroendoscopy. Just before gastroendoscopy, after oral premedication with simethicone, patients were randomly assigned to three groups: in Group A, patients waited for 20 min before gastroendoscopy; in Group B, patients were separately waited for 5/10/15/20 min and were then turned 360 degrees just before gastroendoscopy; in Group C, patients were immediately turned 360 degrees and then separately waited for 5/10/15/20 min before examination. The sum of the gastric mucosal visibility scores (MVS) was calculated after the examination. The MVS and proportion of images with higher visibility scores for the mucosal surface. Lower scores indicate better visibility of the mucosal surface. Results: In Groups B and Groups C, when waiting time more than 10 min had lower mean total MVS than Group A. The MVS of four subgroups of Group B were not different from those of Group C. Conclusion: Oral premedication with simethicone and immediately make a body posture change (turning over 360 degrees) then waiting for 10min can increase the image quality during gastroendoscopy and effectively decrease the premedication time.

Keywords: Gastroendoscopy, simethicone, turn over, mucosal visibility score

Introduction

Gastroendoscopy shows great efficacy for detecting and removing early gastric cancer, thus lowering the mortality and morbidity [1]. However, it is widely recognized that gastroendoscopy may have considerable limitations. When visibility is impaired such as the mucus is covered by bubbles, foams, bile and intraluminal fluid, a potential risk of missing early or subtle lesions by endoscopy emerges [2]. Therefore, anti-foam and bubble-bursting agents are widely used in gastrointestinal endoscopic centers [3]. Because oral premedication with simethicone (Dimethylpolysiloxane or activated Dimethicone) is costly, time-consuming (requires a nearly 20-30 min waiting period), and because, moreover, gastrointestinal endoscopic examination is an uncomfort-

able procedure, it is critical to optimize the quality of the image. For this purpose, N-acetylcysteine and pronase are used, but they do not shorten the waiting time and whether they can improve mucosal image quality remains a matter of debate [4, 5].

When simethicone contacts bubbles or foams, it can decrease the surface tension to reduce or eliminate them. To accelerate this process and shorten the preparation time, we aim to develop a new method that is convenient and can improve mucosal visibility at no extra expense. We propose giving the patients a 360-degree horizontal turn after the oral administration of simethicone to accelerate the elimination of foam.

This study aims to determine whether this posture change improves the mucosal image qual-

Simethicone on image quality in gastroendoscopy

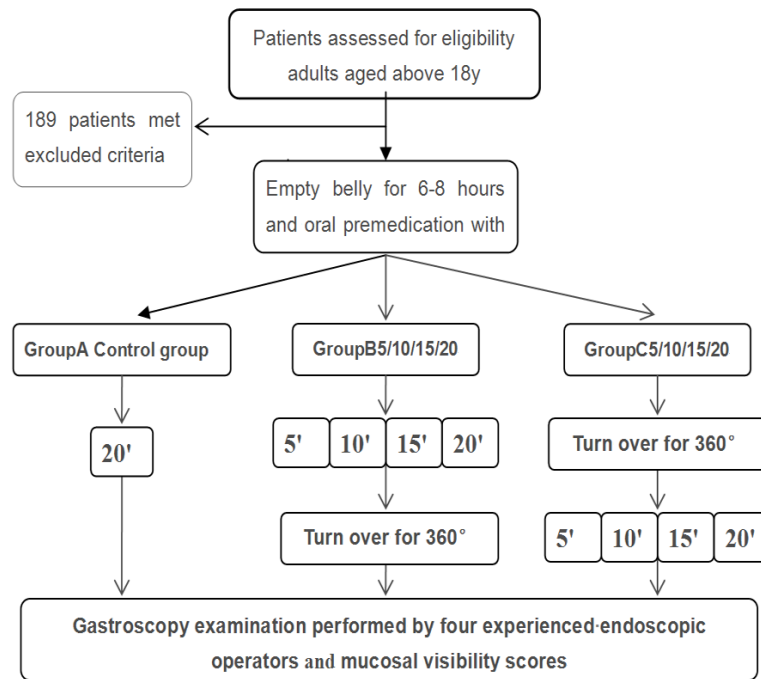


Figure 1. Flow chart of patients' enrollment and gastroscopy examination.

ity, the appropriate waiting period to achieve the goal and whether it enhances the efficiency of preparation.

Methods

Study design

This is a prospective, endoscopic operator-blinded (single-blinded), randomized, controlled study (RCT) with consecutive outpatients undergoing gastroendoscopy at the Endoscopy Center of Daping Hospital (tertiary referral center) of Gastroenterology Department in China. The study protocol and informed consent form were approved by the institutional review board of Daping Hospital, and the study was registered with ClinicalTrials.gov. (ChiCTR-TRC-13003438).

Study population

From July 2013 to August 2013, a total of 1182 outpatients aged above 18 years old were eligible for participation in the study. Exclusion criteria included: (1) history of gastrectomy, esophagectomy; (2) upper gastrointestinal tract stricture; (3) active bleeding in the upper gastrointestinal tract; (4) physical movement

disorder; (5) severe congestive heart failure (New York Heart Association class III or IV); (6) uncontrolled hypertension (systolic blood pressure >170 mm Hg, diastolic blood pressure >100 mm Hg); dysphagia; (7) dehydration; (8) disturbance of electrolytes; gastric outlet obstruction; (9) unable to give informed consent; (10) haemodynamically unstable 189 patients met the excluded criteria, 993 patients attended the program after signing the informed consent.

Gastroendoscopy procedure

And after empty-belly for 6-8 h, gave 100 mg simethicone diluted in 100 ml water to the participants who were finally included, whether posture change after oral premedication

with Simethicone or before gastroendoscopy was unknown, so we established four subgroups of Group B and Group C according the different waiting time. The enrolled patients were assigned into three groups (Using computer-generated random numbers immediately before the examination, and the randomization list was not accessible to the endoscopic operators or assistants).

Group A: The patients took simethicone first and then lay for 20 min before gastroendoscopy.

Group B, each subgroup waited 5 (B5), 10 (B10), 15 (B15), or 20 (B20) min, respectively, in a lying position after taking simethicone and was then turned 360 degrees prior to the examination.

Group C, each subgroup was immediately turned over 360 degrees (either to the left or the right) to change posture after taking simethicone, and then waited 5 (C5), 10 (C10), 15 (C15), or 20 (C20) min for gastroendoscopy, respectively (Figure 1 showed the flowchart of the study).

The turn over time were controlled in 1 min, and the movement was kept in the horizontal posi-

Simethicone on image quality in gastroendoscopy

Table 1. Demographic characteristics of enrolled patients

	Group A (N=113)	Group B5 (N=106)	Group B10 (N=117)	Group B15 (N=103)	Group B20 (N=102)	Group C5 (N=120)	Group C10 (N=116)	Group C15 (N=105)	Group C20 (N=111)
Mean age (SD) (y)	45.6 (14.5)	47.3 (13.4)	48.8 (14.3)	45.6 (12.2)	45.3 (15.7)	45.6 (14.7)	47.4 (13.8)	44.6 (15.4)	46.7 (12.6)
Males (%)	48 (42.5)	47 (44.3)	45 (38.5)	52 (50.5)	49 (48.0)	67 (55.8)	48 (41.4)	47 (44.8)	46 (41.4)
Total score mean (SD)	8.68 (1.76)	8.15 (1.52)	7.96 (1.53)	8.01 (1.60)	7.90 (1.67)	8.07 (1.48)	7.54 (1.40)	7.92 (1.73)	7.46 (1.31)
<60 y [n (%)]	89 (78.8)	88 (83.0)	96 (82.1)	91 (88.3)	84 (82.4)	99 (82.5)	95 (81.9)	85 (81.0)	90 (81.1)
>60 y [n (%)]	24 (21.2)	18 (17.0)	21 (17.9)	12 (11.7)	18 (17.6)	21 (17.5)	21 (18.1)	20 (19.0)	21 (18.9)
Gastric polyp [n (%)]	6 (0.05)	8 (0.08)	5 (0.04)	4 (0.04)	7 (0.07)	6 (0.05)	10 (0.09)	4 (0.04)	10 (0.09)
Early or advanced Gastric cancer [n (%)]	4 (0.04)	2 (0.02)	6 (0.05)	6 (0.06)	2 (0.02)	6 (0.05)	1 (0.01)	7 (0.07)	7 (0.06)
Atrophic gastritis and others [n (%)]	6 (0.05)	10 (0.09)	10 (0.09)	12 (0.12)	11 (0.11)	7 (0.06)	10 (0.09)	12 (0.11)	8 (0.07)

SD, standard deviation; Group A: conventional premedication with simethicone for 20 min before gastroscopy; Group B: premedication with simethicone then waiting for 5, 10, 15, 20 min and turn over 360-degree prior gastroscopy; Group C: premedication with simethicone then turn over 360-degree and waiting for 5, 10, 15, 20 min.

Table 2. Mean MVS at different locations of upper gastrointestinal tract

Mean MVS (SD)	Group A (N=113)	Group B5 (N=106)	Group B10 (N=117)	Group B15 (N=103)	Group B20 (N=102)	Group C5 (N=120)	Group C10 (N=116)	Group C15 (N=105)	Group C20 (N=111)
Esophagus	1.19 (0.42)	1.06 (0.23)	1.03 (0.16)	1.06 (0.27)	1.11 (0.31)	1.03 (0.18)	1.01 (0.09)	1.05 (0.21)	1.08 (0.27)
Fundus	1.86 (0.80)	1.60 (0.73)	1.50 (0.66)*	1.55 (0.72)*	1.53 (0.67)*	1.62 (0.78)	1.42 (0.66)**	1.35 (0.57)**	1.34 (0.63)**
Upper gastric body	1.98 (0.93)	1.95 (0.67)	1.83 (0.65)	1.84 (0.66)	1.72 (0.62)	1.91 (0.69)	1.72 (0.63)	1.84 (0.67)	1.61 (0.62)
Lower gastric body	1.29 (0.48)	1.31 (0.54)	1.25 (0.49)	1.27 (0.45)	1.20 (0.42)	1.33 (0.54)	1.15 (0.38)	1.28 (0.53)	1.12 (0.35)
Antrum	1.24 (0.56)	1.20 (0.47)	1.21 (0.51)	1.18 (0.46)	1.23 (0.56)	1.12 (0.39)	1.21 (0.45)	1.15 (0.43)	1.23 (0.55)
Duodenum	1.09 (0.34)	1.04 (0.19)	1.09 (0.41)	1.12 (0.43)	1.12 (0.38)	1.08 (0.31)	1.03 (0.21)	1.06 (0.23)	1.06 (0.28)

Group B, Group C compared with Group A: *P<0.05, **P<0.01.

tion (around the axis of the body) and partially upright position during the movement was forbidden. Four experienced endoscopists (LHY, SXC, SWJ, YQJ) performed conventional gastroendoscopy (Olympus GIF-H260, Tokyo), and the amount of water that used to flush the mucosa were recorded. All lesions confirmed by biopsy pathology. The endoscopists were unaware of the group differentiation.

After the procedure, two investigators (WXM, YYY) who had not participated in the examination reviewed the endoscopic images and assessed the MVS. The obscurity grade of the mucosal surface depends on the amount of adherent mucus. The six distinct domains of the upper gastroenterological tract, including the esophagus, the fundus, the upper and lower parts of the greater curvature, the antrum of the stomach and the duodenum, were evaluated for mucosal visibility. For each domain, the scoring (known as the visibility score) ranged from 1 to 4 according to the following system [6]: 1, no adherent mucus on the mucosa; 2, a small amount of mucus on the mucosa, with no obscured vision; 3, a large amount of mucus on the mucosa, with less than 50 mL of water to clear; and 4, a large amount of mucus on the mucosa, with more than 50 mL of water to clear. The sum of the visibility scores for all six domains was considered the total MVS for each patient.

Statistical analysis

The demographic characteristics were assessed using a chi-squared (χ^2) test and one-way analysis of variance (ANOVA). The visibility scores of all of the groups were analyzed using ANOVA and Tukey's multiple comparison test. Analyses were performed with SPSS software V.16.0 for Windows. The results were expressed as the mean \pm SD. A *P* value <0.05 was considered statistically significant.

Results

1182 outpatients assessed for inclusion, 189 were excluded. 993 patients enrolled in this study were randomly placed in one of next groups; Group A (*n*=113), control group. Group B (B5 *n*=106; B10 *n*=117; B15 *n*=103; B20 *n*=102), the patients turned 360 degrees just before examination; Group C (C5 *n*=120; C10 *n*=116; C15 *n*=107; C20 *n*=111), the patients

turned over just after took simethicone. There were actually 9 subgroups in total. The demographic data of the patients are shown in **Table 1**. No gender/age differences among these groups, all baseline characteristics were well balanced between these groups (**Table 1**).

Group B: In Group B, the mean of total MVS was 8.15 ± 1.52 , 7.96 ± 1.53 , 8.01 ± 1.60 , and 7.9 ± 1.67 for Groups B5, B10, B15 and B20, respectively. Significant difference in the total MVS was found between Group A (8.68 ± 1.76) and Groups B10, B15, B20, and there were no significant differences between the subgroups of Group B (**Figure 2** total mucosa visibility score of each group). Mucosal lesions detected in every subgroup were higher (B5=19%, B10=18%, B15=19%, B20=19%) than Group A (total 15 cases, 17%), but have not statistics differences (**Table 1**).

Group C: The mean of total MVS in Group C5 was 8.07 ± 1.48 , not significantly lower than that in Group A (8.68 ± 1.76); However, in Groups C10, C15, and C20, the mean of total MVS was 7.54 ± 1.40 , 7.71 ± 1.54 , and 7.46 ± 1.31 , respectively, significantly different from that in Group A ($P<0.05$). However, there were no statistically significant differences between any pair of subgroups in Group C (**Figure 2**). The highest mucosal lesions detected in Group C20, and each subgroup of Group C were higher (C5=16%, C10=18%, C15=22%, C20=22%) than Group A, there is no statistics difference among all the Groups (**Table 1**).

MVS of different parts of the upper gastrointestinal tract for these groups are shown in **Table 2**. The MVS in all patients was 1.07 ± 0.26 at the esophagus, 1.53 ± 0.71 at the gastric fundus, 1.82 ± 0.69 at the upper gastric body, 1.24 ± 0.47 at the lower gastric body, 1.20 ± 0.49 at the antrum, and 1.08 ± 0.32 at the duodenum. The lowest mucosal visibility scores in all groups were observed for the esophagus, and the fundus scored the second highest, the worst mucosal visibility scores in all groups were those for the upper body of the stomach. There were no significant differences between Group A, and the 8 subgroups of Group B, Group C except at the region of gastric fundus, the MVS in Groups B10 (1.50 ± 0.66), B15 (1.55 ± 0.72), B20 (1.53 ± 0.67), C10 (1.42 ± 0.66), C15 (1.35 ± 0.57), and C20 (1.34 ± 0.63) were significantly

Simethicone on image quality in gastroendoscopy

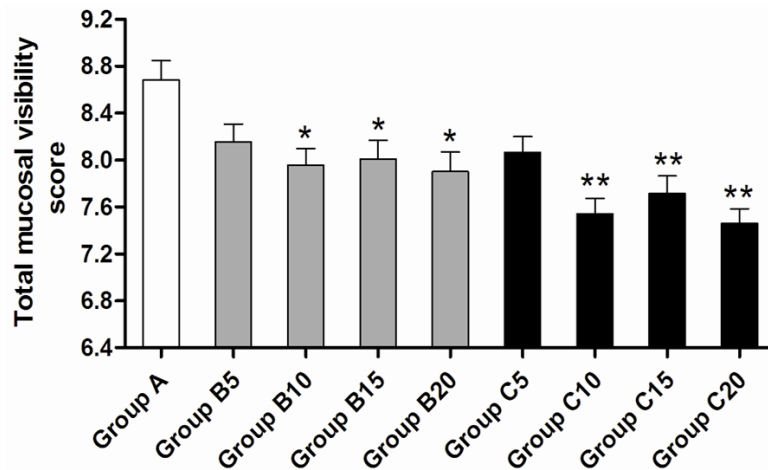


Figure 2. Total mucosa visibility score of each group. Group B, Group C compared with Group A: * $P < 0.05$ ** $P < 0.01$.

different from that in Group A (1.86 ± 0.80) ($P < 0.05$). However, there were no statistically significant differences between any pair of subgroups in Group B and Group C.

Discussion

Foams and bubbles in the upper gastrointestinal tract can affect the detection of small and early lesions. Simethicone and dimethicone are widely used as effective anti-foam agents for pre-endoscopic usage, including colonoscopy and capsule endoscopy [7-9]. Although adequate preparation can eliminate the need to flush the mucus during the procedure, many bubbles still exist during gastroendoscopy after premedication with simethicone.

Doctors constantly strive to improve the gastric mucosal visibility, and most of the methods they have attempted are medicinal interventions with pronase and N-acetylcysteine as the main components. Fujii et al [10] concluded that premedication with pronase improved endoscopic visibility during conventional endoscopy and chromoendoscopy. N-acetylcysteine is both a mucolytic agent and a thiol-containing antioxidant. Chang CC et al [5] found that N-acetylcysteine or pronase combined with simethicone can improve gastric visibility.

In Japan, the patients are usually asked to lie on the back, left side, stomach, and right side, successively, and the process lasts for at least 15 min to enhance mucosal visibility [10, 11]. However, it is somewhat troublesome to change position constantly [12]. In the pre-examination

period, we find that this posture change causes dizziness or slight nausea in some patients, and thus has poor patient compliance. Compared with this process, the slow 360-degree rotation is more acceptable. We assume that performing a 360-degree rotation after taking simethicone can make the medicine coat the mucosal wall evenly to improve its efficacy.

Prior to performing this study we found that turning the patients in the horizontal position immediately after

oral premedication with simethicone and without any waiting time then took gastroendoscopy, this method could achieve the same mucosal visibility level compared with routine gastroendoscopy. However, it was found that various amounts of white foams gathered in the mucus lake, and these did not diminish quickly. We find that the simethicone is turbid in vitro; thus, we heated it and shook it vigorously, but the turbidity remained. Perhaps this is the main reason why the score of Group C was higher than we expected. The mucosal visibility scores for the fundus and the upper part of the stomach were the highest; thus, more effort is needed to make simethicone function in these locations.

Turning the patients over at any time during the period between premedication with simethicone and endoscopy will improve the image visibility. However, turning the patients over immediately after administering the medicine (Group C) led to lower scores than turning them just before the examination (Group B). Although the B10, B15, B20, C10, C15, and C20 subgroups had lower MVSs than Group A, during our test, we deliberately extended the waiting time in some patients, even prolonged the waiting time to as much as 40-50 min prior to gastroendoscopy. However, occasionally foams and bubbles can still be found in the upper gastrointestinal tract. The MVS did not decrease with prolonged waiting time after premedication with simethicone. The group that we infer that a 10-min waiting period will be long enough for simethicone to take effect.

Simethicone on image quality in gastroendoscopy

Our results show that simethicone combined with a 360-degree turn performed even 5 min after oral administration could result in improvements in the standard image quality in conventional gastroendoscopy. In addition, turning the patients immediately after administering simethicone and waiting for over 10 min before performing the gastroendoscopy will make the mucosa much clearer.

One limitation of this method is a low detection rate of early cancer, including dysplasia and cancer. The total detection rate is 18.83%, much lower than that in Japan [13], which is mainly due to a low detection rate of mucosal lesions by the diagnostic technology. But during examination, the highest mucosal lesion detect rate belong to Group C15 and C20, although there is no statistics differences among all the subgroups. Thus, further study is required to solve this problem.

In conclusion, the results of our study showed premedication with simethicone combined with a 360-degree turn, regardless of turning left or turning right, can significantly decrease the duration of gastroendoscopy, and may obtain the same detection quality as with conventional oral premedication with simethicone. This method can greatly improve efficiency within the clinic, without adding other medicine or increasing the cost. Turning patients over after more than 10 min following administration of the medicine may be the appropriate procedure for gastroendoscopy preparation. Endoscopic operators need to carefully observe the upper gastric body and fundus because it has the lower mucosal visibility scores of all groups.

Disclosure of conflict of interest

None.

Address correspondence to: Dongfeng Chen, Department of Gastroenterology, Institute of Surgery Research Daping Hospital, Third Military Medical University, No 10 of Changjiang Subway, Yuzhong District, Chongqing 400000, China. E-mail: chendf-syd1981@sina.com

References

[1] Bóldys H, Marek TA, Wanczura P, Matusik P, Nowak A. Even young patients with no alarm symptoms should undergo endoscopy for earlier diagnosis of gastric cancer. *Endoscopy* 2003; 35: 61-67.

- [2] Bertoni G, Gumina C, Conigliaro R, Ricci E, Staffetti J, Mortilla MG, Pacchione D. Randomized placebo-controlled trial of oral liquid simethicone prior to upper gastrointestinal endoscopy. *Endoscopy* 1992; 24: 268-270.
- [3] Waye JD, Pitman E, Weiss A, Krueger K. The bubble problem in endoscopy. An evaluation of a new aid in endoscopy. A double blind study. *Gastrointest Endosc* 1967; 14: 34-35.
- [4] Asl SM, Sivandzadeh GR. Efficacy of premedication with activated Dimethicone or N-acetylcysteine in improving visibility during upper endoscopy. *World J Gastroenterol* 2011; 17: 4213-4217.
- [5] Chang CC, Chen SH, Lin CP. Premedication with pronase or N-acetylcysteine improves visibility during gastroendoscopy: an endoscopist-blinded, prospective, randomized study. *World J Gastroenterol* 2007; 13: 444-447.
- [6] Kuo CH, Sheu BS, Kao AW, Wu CH, Chuang CH. A defoaming agent should be used with pronase premedication to improve visibility in upper gastrointestinal endoscopy. *Endoscopy* 2001; 34: 531-534.
- [7] Matro R, Tupchong K, Daskalakis C, Gordon V, Katz L, Kastenber D. The effect on colon visualization during colonoscopy of the addition of simethicone to polyethylene glycol-electrolyte solution: a randomized single-blind study. *Clin Transl Gastroenterol* 2012; 3: e26.
- [8] Esaki M, Matsumoto T, Kudo T, Yanaru-Fujisawa R, Nakamura S, Iida M. Bowel preparations for capsule endoscopy: a comparison between simethicone and magnesium citrate. *Gastrointest Endosc* 2009; 69: 94-101.
- [9] Rosa BJ, Barbosa M, Magalhães J, Rebelo A, Moreira MJ, Cotter J. Oral purgative and simethicone before small bowel capsule endoscopy. *World J Gastrointest Endosc* 2013; 5: 67-73.
- [10] Iida K, Okuda J, Kaneko E, Kashima K, Kodama T, et al. Usefulness of premedication with KPD (Pronase) in gastroendoscopy placebo-controlled double blind study in conventional endoscopy. *Clin Rep* 1991; 25: 1781-1792.
- [11] Sanuki M, Tada M, Shiraishi Y, Murakami A, Karita M, et al. Clinical study of KPD (Pronase), as a premedication for endoscopy. *Clin Rep* 1991; 25: 1500-1504.
- [12] Fujii T, Iishi H, Tatsuta M, Hirasawa R, Uedo N, Hifumi K, Omori M. Effectiveness of premedication with pronase for improving visibility during gastroendoscopy: a randomized controlled trial. *Gastrointest Endosc* 1998; 47: 382-387.
- [13] Tamura W, Fukami N. Early gastric cancer and dysplasia. *Gastrointest Endosc Clin N Am* 2013; 23: 77-94.