

High Altitudinal Retinopathy and Neurosyphillis: A Hitherto Uncommon Association

Dr Jayanta Thakuria¹, Dr. Subhra Das², Dr. Dipali C. Deka³,

¹Registrar, Regional Institute of Ophthalmology, Gauhati Medical College & Hospital, Guwahati, Assam

²Associate Professor, Regional Institute of Ophthalmology, Gauhati Medical College & Hospital, Guwahati, Assam

³Professor & HOD, Regional Institute of Ophthalmology, Gauhati Medical College & Hospital, Guwahati, Assam

Abstract: High altitudinal Retinopathy is a condition often seen among mountain climbers or among person who reach high altitude rapidly.

Infectious syphilis is currently showing a resurgence in western world as well as in Indian subcontinent. Presence of ocular involvement is strongly suggestive of involvement of the CNS and is considered synonymous with neurosyphillis.

This is an atypical case of secondary syphilis where the symptoms of sudden loss of vision with retinal vascular changes occurred following ascent to high altitude without proper acclimatization, suggesting possible precipitation of the ocular manifestations by hypoxia associated with high altitude.

Keywords: High altitudinal retinopathy, Neurosyphillis, Optic Neuropathy

I. Introduction

High altitudinal retinopathy is a well described condition that usually occurs following exposure to heights of 4500 meters or more above mean sea level.(1,2,3,4,5,6). Inadequate autoregulatory response of the retinal vasculature is documented as responsible for this. The ocular changes varies from retinal haemorrhage, retinal vascular tortuosity, disc oedema, cotton wool spots, and central retinal vein occlusion(3,4,5).

The presence of ocular involvement, in a patient with syphilis is strongly suggestive of involvement of CNS and to be considered synonymous with Neurosyphillis. Ocular involvement may be silent or may present as anterior uveitis, choroiditis, interstitial keratitis, retinal vasculitis, retinitis, optic neuritis, dacryoadenitis or scleritis(7,8). In this case the presenting ocular symptoms of neurosyphillis were non specific until the precipitation of the same after exposure to hypoxic condition associated with high altitude.

An atypical case report:

A 30 year old heterosexual defense personal was enjoying sound health till Oct 2015 when he was sent for posting at an high altitude outpost at around 5500 meters above mean sea level, in a Himalayan frontier range of the Indo Tibetan border following a brief acclimatization at around 4000 meters for 1 week in the month of September. Within 3 days he complained of rapid onset painless diminution of vision in both eyes (Right eye followed by Left eye) along with mild itching and redness (both eye) for which he consulted the Defense Medical Personal ,who reassured him about the transient nature of the condition and usual visual improvement following descent into plains. But unfortunately, even after two weeks, following his return to plains, his condition did not improved. He started to find disability in distinguishing colours. He sought ocular consultations firstly in his hometown and then in Nepal and was diagnosed to have Bilateral Ischaemic Optic Neuropathy. The MRI brain done on 5 th Nov 2015 revealed Demyelination in left centrum semi ovale region(Fig.1). He was started on systemic corticosteroid (Injection Methylprednisolone Pulse therapy for 5 days followed by oral steroid for 5 weeks) . His vision (as documented) improved significantly from Hand Movement in both eye to 6/24 and 6/18 in Right eye and Left eye respectively.

The patient then attended the Ophthalmology and Neurology services of Gauhati Medical College & Hospital in the first week of February 2016 and a detailed evaluation was made. He revealed the history of the condition. His past history along with his wife's and other family member's details, recent and past drug and the couple's sexual history were elicited. A positive history of an abortion in his wife was noted. The general examination and systemic examination were normal except for a decreased plantar response in the complete neurological assessment. His investigation results were:

Routine examination of blood- TC= 6800, DLC=N62,L36,M0,E2, Hb%= 14.58, ESR= 5mm AEFH

HIV-1 & 2= Non reactive, VDRL = Non reactive

Random blood sugar= 100 mg/dl

Routine examination of urine= Within Normal Limit

USG whole abdomen= Within Normal Limit

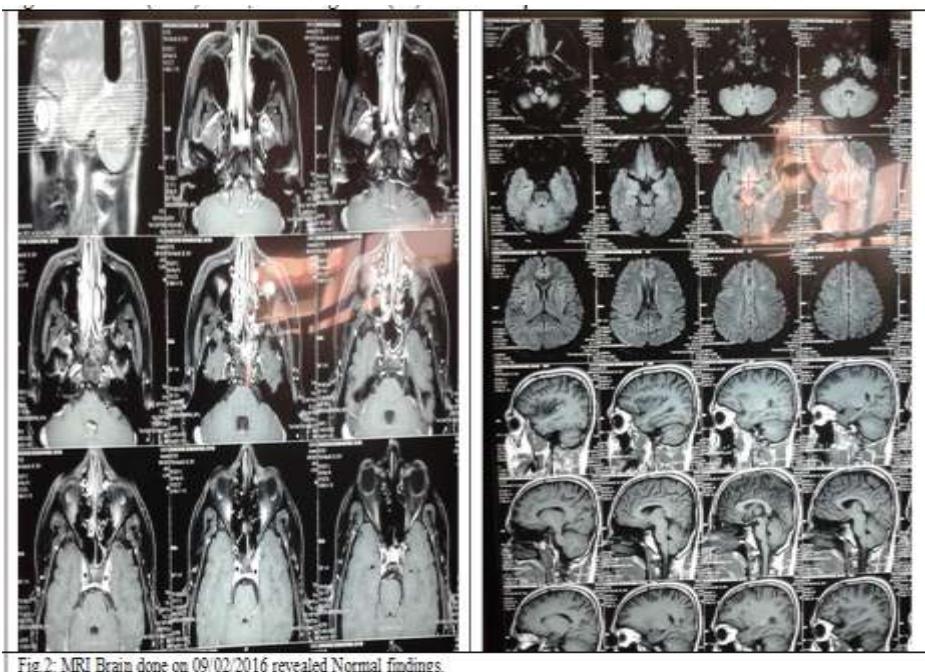
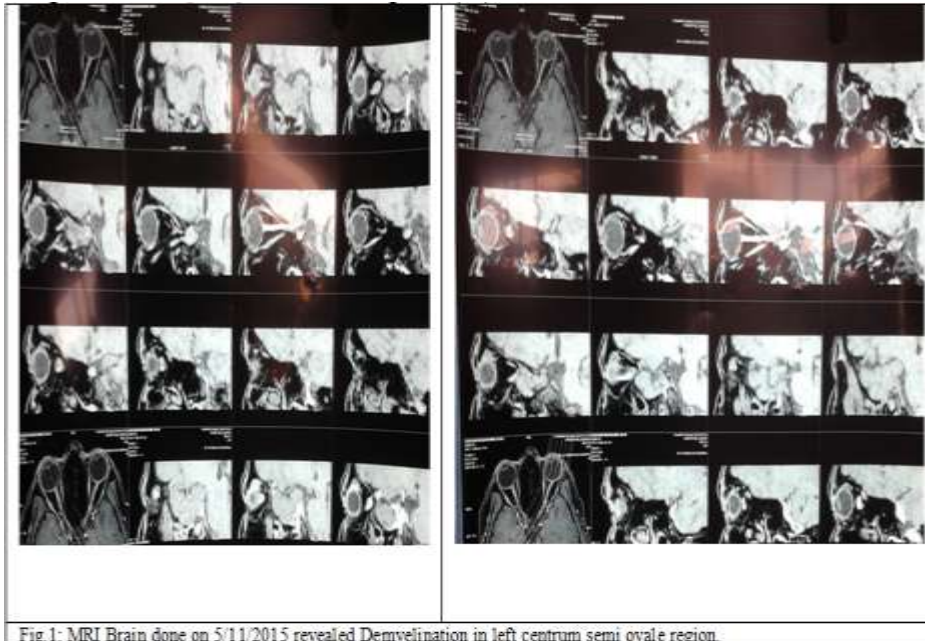Chest X Ray= Within Normal Limit

MRI BRAIN= Within Normal Limit (Fig.2)

VEP reveals= Delayed latency in P2

CSF Analysis: Protein= 23, Sugar=70, DLC=N10, L90, Adenosine Deaminase (ADA)= 1.2, **VDRL= Reactive**,
TPHA= Non reactive,

Oligoclonal Band(OCB) = 1.5, Immunoglobulin (IG) Index= 20.8



Ophthalmological examination: The patient had a vision of 6/18 +3 and 6/18 in the RE and LE respectively at the time of presentation in our Ophthalmology OPD. The anterior segment structures were normal, except for mild Relative Afferent Pupillary Defect (RAPD) in BE. IOP of 16 mm Hg in BE. Color vision was normal. Fundus revealed mild temporal pallor in BE, resolved papilledema, mottled retinal pigment epithelium. Visual fields were outside normal limits. Optical Coherence Tomography (OCT) showed decreased RNFL Thickness in BE with normal foveal thickness(Fig.3).

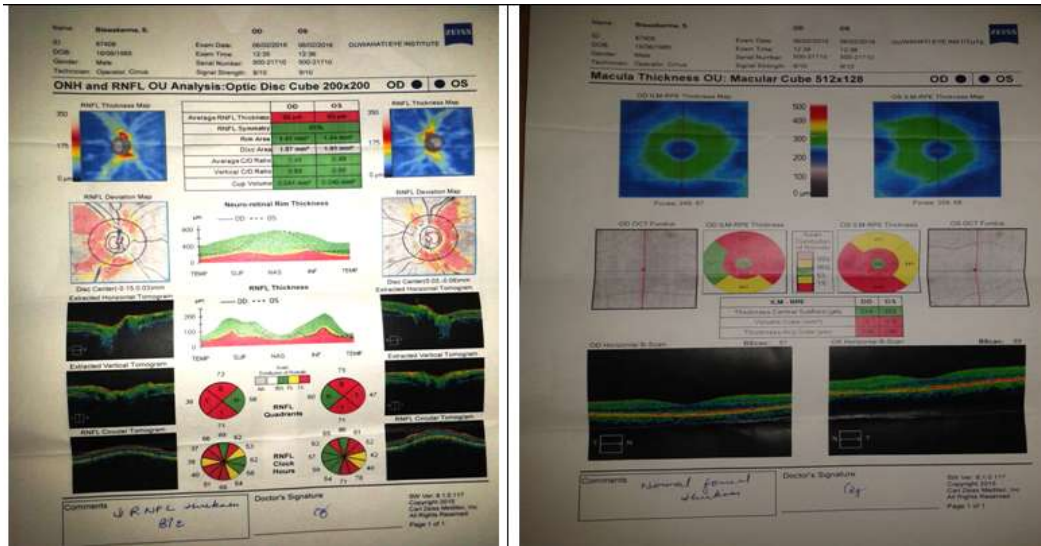


Fig.1: OCT image showing decreased RNFL thickness in Both Eye.

He was started with Injection Penicillin G 12 Lacs units (Penidure) i.m. weekly for 4 weeks
 Injection Ceftriaxone 2gm i.v. BD ANST for 10 days
 Tab Benfothiamine 1 tablet twice daily
 Tab Rabeprazole-Domperidone 1 tablet once daily before breakfast
 After 4 weeks of treatment, in March 2nd week, the visual acuity in the RE had improved to 6/6 and LE to 6/9+4 and the optic nerve head appear normal.

II. Discussion

High altitudinal retinopathy is a well known entity seen in climbers and mountaineers with ocular vascular dysregulation(1,2,3). Autoregulation of retinal vessels may play the contributory role in maintaining normal circulation in eyes that are exposed to chronic hypoxia as may occur at high altitudes(3). An increase in the hematocrit value with increased blood viscosity is also proposed to be another mechanism responsible for the occurrence of various manifestation of altitude related retinal changes.(2,9) Of all the manifestations, ischaemic optic neuropathy has been the least common and rarely described after high altitude exposure. We speculate that vascular dysregulation, precipitated by pre-existing neurosyphilis, under condition of chronic hypoxia, led to sustained vasospasm, leading to reduced blood supply to the optic nerve head, manifesting as anterior ischaemic optic neuropathy.

Neurosyphilis:

Ocular involvement, as mentioned earlier in a patient with syphilis is strongly suggestive of CNS involvement and should be considered synonymous with neurosyphilis. Following entry into the body usually through an abrasion during sexual contact, the spirochaete *Treponema pallidum* undergoes rapid spread via haematogenous and lymphatic routes during the primary infection phase. A primary chancre(a painless infectitious ulcer) usually develops at the site of sexual contact, after an incubation period of around 3weeks (range: 9- 90 days). The primary lesion heals in 2 to 6 weeks. Secondary syphilis occurs 4 to 8 weeks after the chancre, where dissemination of the organism; frequently to the CNS occurs(10).

Ocular complications occurred in 3% of patients of secondary syphilis, in the pre antibiotic era. Among patients with secondary syphilis about 18% may have neurological (including ophthalmological) signs or symptoms(10). Ocular involvement may be silent or may present as anterior uveitis, choroiditis, interstitial keratitis, retinal vasculitis, retinitis, optic neuritis, dacryoadenitis or scleritis(7,8). The optic nerve involvement in syphilis may be unilateral or bilateral and manifest as perineuritis, anterior or retrobulbar neuritis or papilledema.

The serological response in neurosyphilis may often be reduced ,delayed or absent making diagnosis difficult.(11) Lumbar puncture for CSF analysis and culture is occasionally helpful ,as in our case, though its highly specific but not sensitive. The presence of two or more abnormal CSF laboratory variables: CSF leucocyte count, CSF protein concentration and CSF VDRL ; is significantly associated with isolation of *Treponema pallidum* from CSF(10).

Optic neuritis in syphilis is rather rare and not characteristic enough to distinguish it from non syphilitic involvement of similar distribution. In anterior optic neuropathy the optic nerve head appears inflamed, often with cellular activity in posterior vitreous and diffuse neuroretinitis(12). Whereas in retrobulbar neuritis, the optic nerve head often appear normal, but a RAPD and defective color vision suggest poor optic nerve function. Thus, as in our case, the history may not clearly suggest a diagnosis of syphilis so patients with optic neuritis should always be tested for syphilis.

Acknowledgement:

The authors would like to thank the residents and faculties of the Department of Neurology and Radiology of Gauhati Medical College&Hospital, Guwahati for their help and collaboration.

Competing interests: The authors declare that they have no competing interests.

Source of Support: Nil

References

- [1]. Bandyopadhyay S, Singh R, Gupta V, Gupta A. Anterior ischaemic optic neuropathy at high altitude. *Indian J Ophthalmol.* 2002; 50:324-5
- [2]. Lang GE, Kuba GB. High altitude retinopathy. *Am J Ophthalmol* 1997; 123: 418-20
- [3]. Braun U, Braun M, Jonas JB. High altitude retinopathy after Himalayan ascent. *Monatsbl Augenheilkd* 1997; 211: 213-14
- [4]. Mc Faden DM, Houston CS, Sutton JR, Powles AC et al. High altitude retinopathy. *JAMA* 1981; 245: 581-86
- [5]. Butler FK, Harris DJ, Reynolds RD. Altitude retinopathy on Mount Everest, 1989. *Ophthalmol* 1992; 99: 739-46
- [6]. Botella MJ, Martinez CR. High altitude retinal hemorrhages in the expeditions to 8000 meters peaks. A study of 10 cases. *Medclin (Barc)* 1998; 110:457-61.
- [7]. Tamesis RR, Foster CS. Ocular syphilis. *Ophthalmology* 1990;97: 1281-7
- [8]. Margo CE, Hamed LM. Ocular syphilis. *Surv Ophthalmol* 1992; 37: 203-20
- [9]. Mullner EA, Rainer G, Strenn K, Zidek T. High altitude retinopathy and retinal vascular dysregulation. *Eye* 2000; 14: 724-29.
- [10]. Lukehart SA, Hook EW, Baker-Zander SA, et al. Invasion of the central nervous system by *Treponema pallidum*: Implications for diagnosis and treatment. *Ann Intern Med* 1988; 109: 855-62
- [11]. Goh BT, van Voost Vader PC. European guidelines for the management of syphilis. *Int J STD AIDS* 2001; 12: 14-26 (<http://www.iusti.org/guidelines.pdf>), (suppl 3)
- [12]. Walsh FB, Hoyt WF. Infections and parasitic invasions of the nervous system. In: *Clinical neuro-ophthalmology*. 3rd ed. Vol.2. Baltimore: Williams and Wilkins, 1969: 1581-91