

# Predicting Curve Progression in Adolescent Idiopathic Scoliosis - An Outline of Different Indicators of Growth

Iris Busscher and Albert G. Veldhuizen  
*University Medical Center Groningen  
The Netherlands*

## 1. Introduction

Successful treatment of adolescent idiopathic scoliosis (AIS) remains a complex challenge for the orthopaedic surgeon. For a good planning of the conservative or surgical treatment it is essential to understand the prognosis of the deformity. The timing of treatment is mainly dependent on the timing of the progression of the scoliotic curve.

Earlier research has shown that curve progression is primarily related to periods of rapid skeletal growth of the patient during puberty<sup>1,2</sup>. In order to predict the timing of curve progression, it is of great interest to predict the timing of the pubertal growth spurt in the individual patient with adolescent idiopathic scoliosis.

Furthermore, in severe scoliosis, surgical fusion is still the gold standard and for the prevention of complications like the crankshaft phenomenon<sup>3</sup>, the operation, if possible, has to be postponed until the pubertal growth spurt of the patient for the most part has passed.

The pubertal growth spurt is known to take place between 10 and 14 years in 95% of the girls, and between 12 and 16 years in 95% of the boys<sup>4-6</sup>. This range holds for a large population, but is too wide to make an accurate prediction in the individual patient.

Several methods have been studied to predict the timing and magnitude of the pubertal growth spurt in the individual child. Different maturity indicators can be used like skeletal age in different areas, the Risser sign, status of the triradiate cartilage, Tanner stage of sexual maturation, age of the thelarche and menarche, and several body length dimensions. Furthermore, the trend in total body height for an individual child can be used in a mathematical growth model to predict the timing and magnitude of the pubertal growth spurt<sup>7</sup>. These indicators of maturity are all signs that reflect growth or remaining growth of the patient and can be useful in predicting the timing of the pubertal growth spurt in the individual patient.

Researchers have tried to find different ways to predict curve progression in AIS as well, besides relating progression to the pubertal growth spurt. A promising method was shown by Cheung et al<sup>2,8</sup>, who found a relationship between curve progression and altered electromyography ratios of the convex and concave sides of the curve. This will be discussed later.

This chapter provides a concise outline of several indicators of growth and curve progression in order to be able to provide a clear overview of which indicators can be useful in predicting the timing of the pubertal growth spurt and therefore the timing of possible scoliosis progression.

## 2. Skeletal age dimensions

Any skeletal region with consistent physal markers can be determined for skeletal age. The most commonly used markers of skeletal age in patients with idiopathic scoliosis are the hand and wrist, the ossification of the iliac apophysis (Risser sign), the status of the triradiate cartilage, and the ossification of the epiphysis of the elbow.

Determination of skeletal age by hand and wrist X rays is usually done by the method of Greulich and Pyle or Tanner and Whitehouse.

The Greulich and Pyle method as originally described involves a complex comparison of all of the bones in the hand and wrist against reference "normal" radiographs of different ages. In most institutions a modified version of this technique is used, whereby the overall appearance of a given radiograph is compared with the reference radiographs and the nearest match is selected. Although this modified approach is considerably faster than the original it may be less accurate. The Tanner and Whitehouse method relies on the systematic evaluation of the maturity of all the bones in the hand and wrist. The Tanner Whitehouse classification can predict well if the patient is before or after the pubertal growth spurt. The Greulich and Pyle method of assessing skeletal age is easier to use but less precise and the atlas was compiled from radiographs made in the 1930's<sup>9</sup>.

The Risser sign describes the ossification of the iliac apophysis (Figure 1). It continues to be an accepted prognostic sign in the evaluation of growth of patients with idiopathic scoliosis. More controversy is arising since Risser stage 1 occurs after the growth spurt in 85% of patients and the distribution is fairly wide. Its predictive value is therefore low<sup>10,11</sup>. However, some recent studies showed that taking the lateral spinal X-ray in consideration as well, the accuracy of the Risser sign can be improved and it can therefore be helpful for predicting the spinal growth potential<sup>12</sup>.

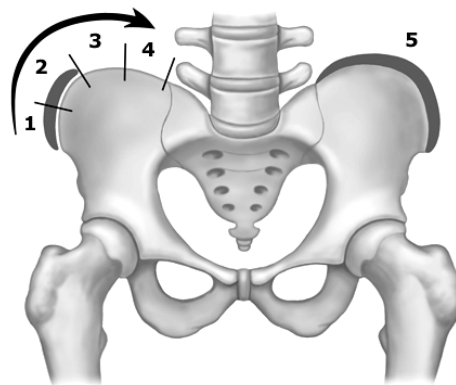


Fig. 1. Risser sign describes the ossification of the iliac apophysis.

Sanders et al.<sup>13,14</sup> found the status of the triradiate cartilage (Figure 2) to be more predictive for the timing of the peak growth velocity of total body height, though it is only predictive whether the patient is before or after the pubertal growth spurt. Once the patient has closed triradiate cartilages, he or she is very likely past the pubertal growth spurt. However, the predictive value of open triradiate cartilages is less clear.

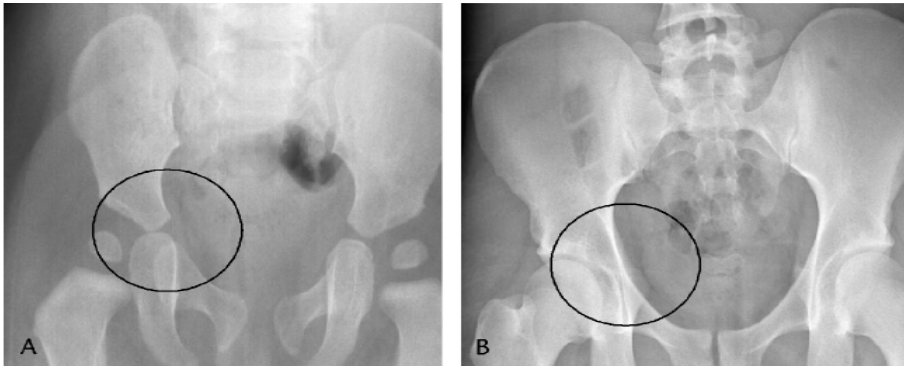


Fig. 2. status of the triradiate cartilage.

A different method for describing skeletal age is the Sauvegrain method (Figure 3), in which skeletal age is determined using a scoring system for four anatomical landmarks of the elbow. At the onset of puberty, the elbow is still largely cartilaginous. Two years later, fusion of the elbow growth centers is complete. This period is critical since it is marked by the pubertal growth spurt. This method was found to be more accurate and detailed than the Greulich and Pyle atlas<sup>15</sup>. Furthermore, it is easier to use and it allows the evaluation of skeletal age in six-month intervals, in contrast to one-year intervals in the most commonly used methods of Greulich and Pyle, and Tanner and Whitehouse.

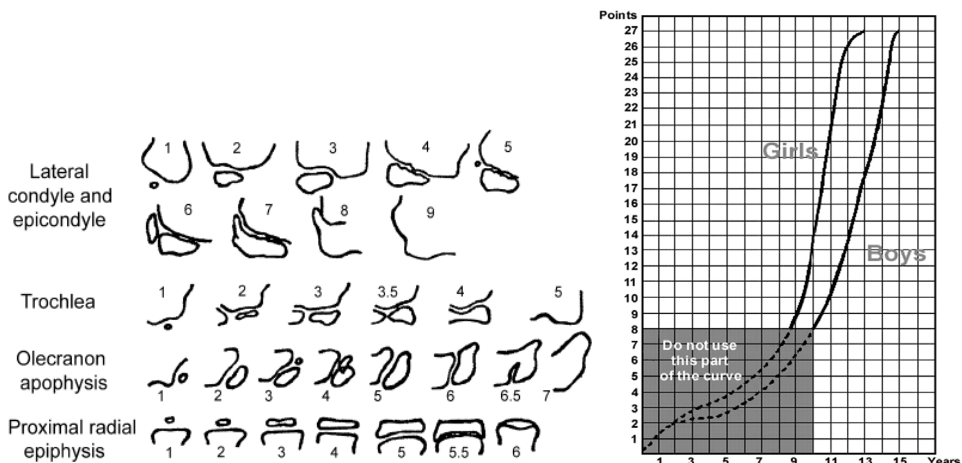


Fig. 3. The Sauvegrain method describes the skeletal age using four anatomical landmarks of the elbow.

### 3. Secondary sexual characteristics

Another hallmark of maturation is the development of secondary sexual characteristics, often classified by Tanner (Figure 4). Thelarche, the first stage of secondary breast development, marks the beginning of puberty and usually takes place 1 year before the pubertal growth spurt<sup>16-19</sup>. Girls typically experience their pubertal growth spurt between stages 2 and 3 of breast development and pubic hair development. The pubertal or Tanner stages are good measurements of maturity. Timing of menarche, the first menstrual period, can be used in girls, but most often takes place 1 year after the growth spurt and is therefore always retrospective.

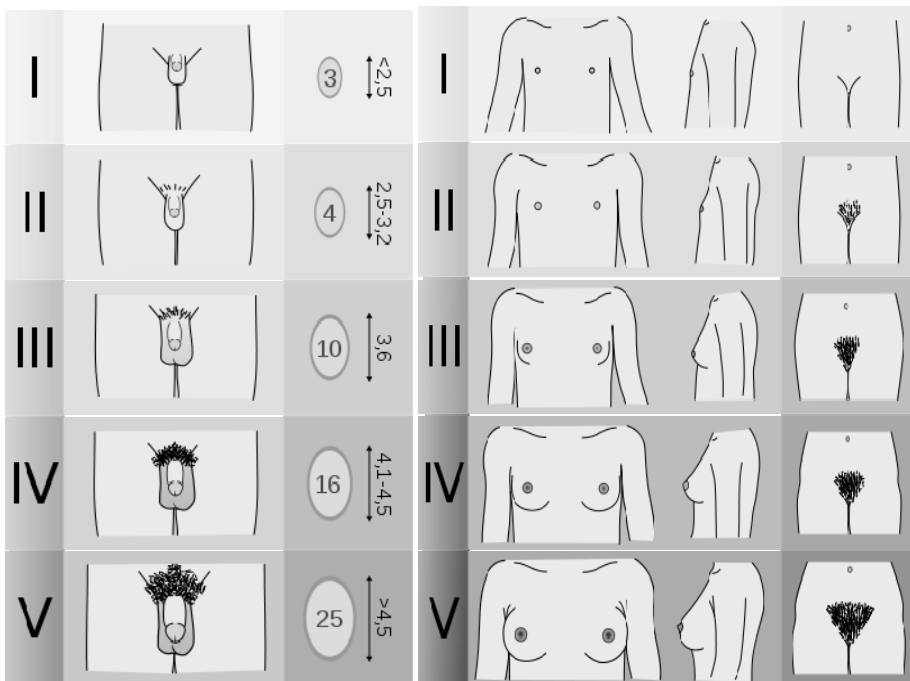


Fig. 4. Tanner stages of sexual maturation.

### 4. Body length dimensions

It is generally accepted that different body length dimensions each have their own typical growth pattern influenced by age- and gender-related factors. Research has been done by Welon and Bielicki<sup>19</sup>, Cameron et al.<sup>21</sup>, Dimeglio<sup>22</sup>, and Rao et al.<sup>23</sup> to the sequences of peak

growth velocities of different length measurements of children from 1-18 years. They all confirm the distal-to-proximal growth maturity gradient as described by Tanner<sup>24</sup>. Body parts that are more distal will have their pubertal growth spurt earlier in adolescence.

However, Busscher et al.<sup>25</sup> showed that this growth gradient theory is not always applicable to the individual child. On average it holds for large groups, but individual variations make it less useful for predictions of the pubertal growth spurt in the individual child.

Furthermore, in order to calculate growth velocities of a body length dimension, access is needed to longitudinal growth data of the patient. Usually patients who visit the outpatient clinic for the first time do not have growth data over the last years and it takes years to gather the data.

However, a different study from Busscher et al.<sup>26</sup> showed that the shoe size can be helpful in predicting the timing of the pubertal growth spurt in children. Since patients and their parents can recall the course of their shoe size for the last year or two, the clinician already has some longitudinal data at the first visit. In particular the fact that the shoe size does not increase any further when the pubertal growth spurt takes place in both boys and girls can be helpful, even in the individual child.

A complete different way of predicting the timing of the pubertal growth spurt was recently shown by using a mathematical growth model<sup>7</sup>. A new model was presented in which a small part of the available growth velocity curve of an individual child was linked to a known generic growth velocity curve. The generic curve was shifted and stretched or shrunk, both along the age-axis (X-axis) and the height velocity axis (Y-axis). In this way, a new complete growth velocity curve for that individual child was obtained and the individual timing of the pubertal growth spurt could be determined. The results were highly promising even when using just few available growth data of an individual patient.

## 5. Electromyography of the paraspinal muscles

As mentioned earlier, Cheung et al.<sup>28</sup> found a relationship between curve progression and altered electromyography ratios of the convex and concave sides of the curve. An electromyography was made of the paraspinal muscles in order to determine the ratios of muscle activity on the convex and concave side of the main scoliotic curve.

For the electromyographic measurements, 12 EMG electrodes were placed symmetrically along the superficial erector spinae muscles at three levels, 30 mm from the midline, and parallel to the spinous processes. The electrode levels correspond to both end vertebrae of the curve (most tilted ones), and the apex vertebra.

The paraspinal activity (EMG) ratio was defined as the EMG activity of the erector spinae muscles between a convex electrode pair divided by the EMG activity between a contralateral concave electrode pair.

Enhanced EMG ratios were observed at three levels of the scoliotic curve (lower end vertebra, apex, and upper end vertebra) at the start of progressive periods. At the start of a non-progressive period, such an enhanced EMG ratio was only observed at the level of the apex vertebra<sup>2</sup>.

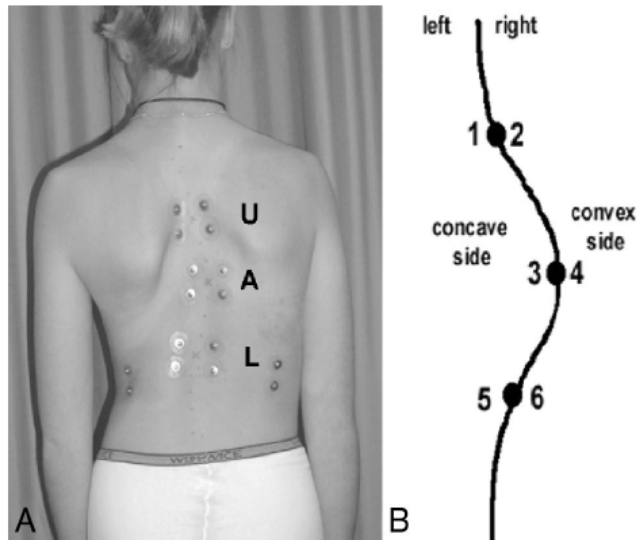


Fig. 5. Measurement of electromyography ratios of the paraspinal muscles of the convex and concave side of the curve.

## 6. Conclusion

This chapter provided an outline of several indicators of growth and curve progression in patients with adolescent idiopathic scoliosis. Some are useful, others are less useful. A problem in finding useful indicators for predicting the timing of the pubertal growth spurt is that several indicators are only useful for large groups of children. On average they can help, but individual variations are large and therefore predictions for the individual child are difficult.

Useful indicators should be easy to use, fast and should not place a large burden on the patient or the clinician. For example, EMG measurement of the paraspinal muscles is a highly promising method but it is fairly time consuming.

A combination of several indicators of growth and curve progression can help the orthopaedic surgeon in planning the treatment of adolescent idiopathic scoliosis in the individual child.

A combination of the Sauvegrain method for skeletal age, the Tanner stages of sexual maturation, the individual course in shoe size, and the use of a new mathematical growth model is most likely to be helpful in predicting the timing of the pubertal growth spurt and the timing of curve progression in the individual patient with adolescent idiopathic scoliosis.


## 7. References

- [1] Wever DJ, Tonseth KA, Veldhuizen AG. Curve progression and spinal growth in brace treated idiopathic scoliosis. *Stud.Health Technol.Inform.* 2002;91:387-92.

- [2] Cheung J, Veldhuizen AG, Halbertsma JP et al. The relation between electromyography and growth velocity of the spine in the evaluation of curve progression in idiopathic scoliosis. *Spine (Phila Pa 1976.)* 2004;29:1011-6.
- [3] Sanders JO, Little DG, Richards BS. Prediction of the crankshaft phenomenon by peak height velocity. *Spine* 1997;22:1352-6.
- [4] Gerver WJ, de Bruin R. Paediatric morphometrics: a reference manual. Second extended edition ed. UPM Maastricht, 2001.
- [5] Gerver WJ, de Bruin R. Growth velocity: a presentation of reference values in Dutch children. *Horm.Res.* 2003;60:181-4.
- [6] Tanner JM, Davies PS. Clinical longitudinal standards for height and height velocity for North American children. *J.Pediatr.* 1985;107:317-29.
- [7] Busscher I, Kingma I, de Bruin R, et al. Prediction of the peak growth velocity in the individual child, validation of a new growth model. *Eur Spine J* 2011; 10.1007/s00586-011-1845-z
- [8] Cheung J, Halbertsma JP, Veldhuizen AG, Sluiter WJ, Maurits NM, Cool JC et al.: A preliminary study on electromyographic analysis of the paraspinal musculature in idiopathic scoliosis. *Eur Spine J* 2005, 14: 130-137.
- [9] Bull RK, Edwards PD, Kemp PM, Fry S, Hughes IA: Bone age assessment: a large scale comparison of the Greulich and Pyle, and Tanner and Whitehouse (TW2) methods. *Arch Dis Child* 1999, 81: 172-173.
- [10] Little DG, Sussman MD: The Risser sign: a critical analysis. *J Pediatr Orthop* 1994, 14: 569-575.
- [11] Shuren N, Kasser JR, Emans JB, Rand F: Reevaluation of the use of the Risser sign in idiopathic scoliosis. *Spine* 1992, 17: 359-361.
- [12] Kotwicki T: Improved accuracy on Risser sign grading with lateral spinal radiography. *Eur Spine J* 2008, 17 (12): 1676-85.
- [13] Sanders JO, Browne RH, Cooney TE, Finegold DN, McConnell SJ, Margraf SA: Correlates of the peak height velocity in girls with idiopathic scoliosis. *Spine* 2006, 31: 2289-2295.
- [14] Sanders JO, Browne RH, McConnell SJ, Margraf SA, Cooney TE, Finegold DN: Maturity assessment and curve progression in girls with idiopathic scoliosis. *J Bone Joint Surg Am* 2007, 89: 64-73.
- [15] Dimeglio A, Charles YP, Daures JP, de Rosa V, Kabore B: Accuracy of the Sauvegrain method in determining skeletal age during puberty. *J Bone Joint Surg Am* 2005, 87: 1689-1696.
- [16] Loncar-Dusek M, Pecina M, Prebeg Z: A longitudinal study of growth velocity and development of secondary gender characteristics versus onset of idiopathic scoliosis. *Clin Orthop Relat Res* 1991, 278-282.
- [17] Little DG, Song KM, Katz D, Herring JA: Relationship of peak height velocity to other maturity indicators in idiopathic scoliosis in girls. *J Bone Joint Surg Am* 2000, 82: 685-693.
- [18] Karlberg J, Kwan CW, Glander L, Albertsson-Wikland K: Pubertal growth assessment. *Horm Res* 2003, 60: 27-35.
- [19] Tanner JM: *Foetus into Man. Physical Growth from Conception to Maturity.* OBP London; 1978.

- [20] Welon Z, Bielicki T: The timing of adolescent growth spurts of 8 body dimensions in boys and girls of the Wroclaw growth study. *Stud Phys Anthropol* 1979, 5: 75-79.
- [21] Cameron N, Tanner JM, Whitehouse RH: A longitudinal analysis of the growth of limb segments in adolescence. *Ann Hum Biol* 1982, 9: 211-220.
- [22] Dimeglio A: Growth in pediatric orthopaedics. *J Pediatr Orthop* 2001, 21: 549-555.
- [23] Rao S, Joshi S, Kanade A: Growth in some physical dimensions in relation to adolescent growth spurt among rural Indian children. *Ann Hum Biol* 2000, 27: 127-138.
- [24] Tanner JM: *Growth at Adolescence*, 2nd Edition edn. Oxford: Blackwell Scientific Publications; 1962.
- [25] Busscher I, Gerver WJM, Kingma I, et al. The growth of different body length dimensions is not predictive for the peak growth velocity of sitting height in the individual child. *Eur Spine J* 2010; 20(5): 791-797
- [26] Busscher I, Kingma I, Wapstra FH, et al. the value of shoe size for prediction of the timing of the pubertal growth spurt. *Scoliosis* 2011; 6(1):1





## **Recent Advances in Scoliosis**

Edited by Dr Theodoros Grivas

ISBN 978-953-51-0595-4

Hard cover, 344 pages

**Publisher** InTech

**Published online** 09, May, 2012

**Published in print edition** May, 2012

This book contains information on recent advances in aetiology and pathogenesis of idiopathic scoliosis, for the assessment of this condition before treatment and during the follow-up, making a note of emerging technology and analytical techniques like virtual anatomy by 3-D MRI/CT, quantitative MRI and Moire Topography. Some new trends in conservative treatment and the long term outcome and complications of surgical treatment are described. Issues like health related quality of life, psychological aspects of scoliosis treatment and the very important "patient's perspective" are also discussed. Finally two chapters tapping the untreated early onset scoliosis and the congenital kyphoscoliosis due to hemivertebra are included. It must be emphasized that knowledgeable authors with their contributions share their experience and enthusiasm with peers interested in scoliosis.

### **How to reference**

In order to correctly reference this scholarly work, feel free to copy and paste the following:

Iris Busscher and Albert G. Veldhuizen (2012). Predicting Curve Progression in Adolescent Idiopathic Scoliosis - An Outline of Different Indicators of Growth, Recent Advances in Scoliosis, Dr Theodoros Grivas (Ed.), ISBN: 978-953-51-0595-4, InTech, Available from: <http://www.intechopen.com/books/recent-advances-in-scoliosis/predicting-curve-progression-in-adolescent-idiopathic-scoliosis-an-overview-of-different-indicators>

# **INTECH**

open science | open minds

### **InTech Europe**

University Campus STeP Ri  
Slavka Krautzeka 83/A  
51000 Rijeka, Croatia  
Phone: +385 (51) 770 447  
Fax: +385 (51) 686 166  
[www.intechopen.com](http://www.intechopen.com)

### **InTech China**

Unit 405, Office Block, Hotel Equatorial Shanghai  
No.65, Yan An Road (West), Shanghai, 200040, China  
中国上海市延安西路65号上海国际贵都大饭店办公楼405单元  
Phone: +86-21-62489820  
Fax: +86-21-62489821

© 2012 The Author(s). Licensee IntechOpen. This is an open access article distributed under the terms of the [Creative Commons Attribution 3.0 License](#), which permits unrestricted use, distribution, and reproduction in any medium, provided the original work is properly cited.