



## SHORT REPORT

# Case Report: Fatal case of disseminated BCG infection in an infant born to a mother taking infliximab for Crohn's Disease

Kuldeep Cheent<sup>a</sup>, Jonathan Nolan<sup>a</sup>, Sohail Shariq<sup>a</sup>, Liina Kiho<sup>b</sup>, Arabinda Pal<sup>a</sup>, Jayantha Arnold<sup>a,\*</sup>

<sup>a</sup> Department of Gastroenterology, Ealing Hospital NHS Trust, Middlesex, UK

<sup>b</sup> Department of Cellular Pathology, The Royal London Hospital, London, UK

Received 7 March 2010; received in revised form 2 May 2010; accepted 3 May 2010

### KEYWORDS

Infliximab;  
Crohn's;  
BCG;  
Pregnancy;  
Vaccination

### Abstract

We present the case of a 28 year old lady with refractory Crohn's Disease treated with infliximab throughout her pregnancy. Her baby was born healthy and received a Bacillus Calmette–Guérin (BCG) vaccine aged 3 months. Soon after this the infant became unwell and died aged 4.5 months. At post-mortem the cause of death was attributed to an unusual complication of the BCG vaccine, known as disseminated BCG.

BCG vaccination is contraindicated in individuals who are receiving immunosuppressive drugs. We recommend physicians should exercise caution before such vaccines are used in infants born to mothers taking anti-TNF therapies or other potentially immunosuppressive IgG1 antibodies.

© 2010 European Crohn's and Colitis Organisation. Published by Elsevier B.V. All rights reserved.

## 1. Case report

This case is of a 28 year old Caucasian lady diagnosed with pan-colitis and erythema nodosum secondary to Crohn's Disease (CD) in 2001. She was treated early on with mesalazine and azathioprine at a dose of 2 mg per kg bodyweight but experienced recurrent flare-ups requiring repeated courses of prednisolone with eventual loss of

response. In 2004, infliximab 5 mg/kg was commenced with initial good symptomatic benefit but subsequent loss of response. Therefore, in 2006 the dose of infliximab was increased to 10 mg/kg every eight weeks.

In 2008 she became pregnant. The pros and cons of continuing infliximab were discussed at length with the patient. Due the severity and corticosteroid refractory nature of her CD, the benefits of maintaining remission with infliximab was felt to outweigh the risks of foetus exposure to the drug. She consented to continue eight-weekly infusions of infliximab 10 mg/kg as monotherapy for CD. Her disease remained in remission during pregnancy and in July 2008 she gave birth to a healthy baby boy. The baby was born at 36 + 3 gestation via spontaneous vaginal delivery

\* Corresponding author. Department of Gastroenterology, Ealing Hospital NHS Trust, Uxbridge Road, Southall, Middlesex, UB1 3HW, UK. Tel.: +44 20 8967 5513; fax: +44 20 8967 5083.

E-mail address: [Jay.arnold@eht.nhs.uk](mailto:Jay.arnold@eht.nhs.uk) (J. Arnold).

with birth weight of 2.8 kg (>25th centile). There were no complications at birth and the baby was discharged home with his mother the next day. The infant was not breast fed. He progressed well until the age of 3 months when he received a Bacillus Calmette–Guérin (BCG) vaccination, after which a lag in weight gain was noticed. At 3.5 months he was seen by the health visitor who confirmed poor weight gain in addition to head lag and skin eczema. A referral was made to the paediatric team. A couple of weeks before this appointment the infant was noted to be irritable and not taking feeds very well. He eventually settled but was found a few hours later floppy and unresponsive. Despite full in-hospital resuscitation the infant died aged 4.5 months.

A post-mortem was carried out on the infant. He was normally developed with no evidence of congenital malformations, identifiable metabolic disorders or signs of neglect, abuse or accidental injury. His weight had fallen to below the 0.4th centile compared to his birth weight which was above the 25th centile. Haemorrhages were noted in the lungs, thymus and heart. Disseminated granulomatous inflammation with multiple non-caseating tuberculoid granulomas in the lungs, liver and dura were noted (Fig. 1). A BCG vaccination mark was present on the left shoulder. The infant had received BCG vaccination aged 3 months from the local health centre. It was shortly after this the infant started to become unwell. Although Ziehl–Neelsen stain for acid fast bacilli and TB PCR methods were equivocal, the nodular masses were felt to be typical of those seen in disseminated mycobacterial infection. There was no history of TB in the family or contacts. In view of the combination of the clinical history (onset after BCG vaccination) and histological findings, the pathologist attributed the cause of death was an unusual complication of the BCG vaccine known as disseminated BCG.

## 2. Discussion

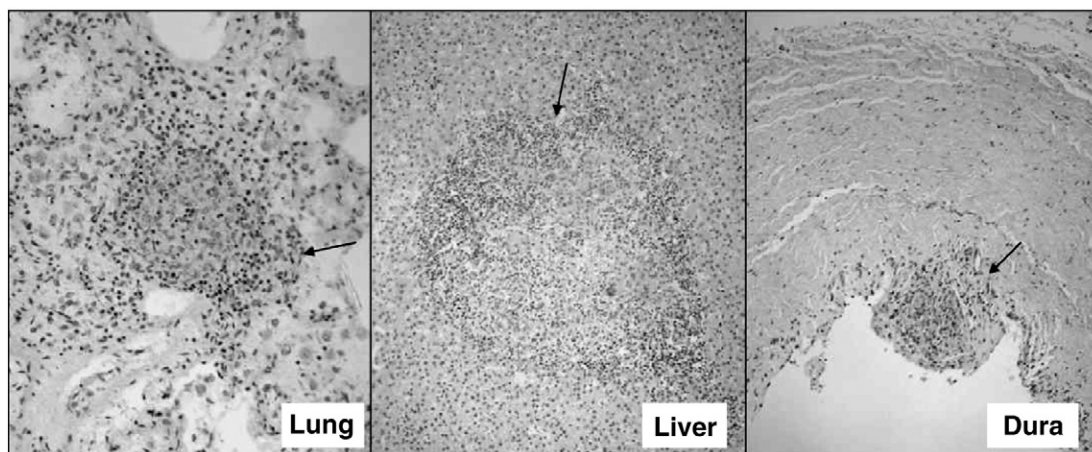
The BCG vaccine contains a live attenuated form of *Mycobacterium bovis*, whose antigenic profile is akin to *Mycobacterium tuberculosis*. Worldwide it is the most widely used vaccine with more than 1 billion recipients. The WHO

recommends vaccination as soon as possible after birth to babies who are more likely to come into contact with someone with TB. The infant was born in a region in England with a high rate of TB and received the vaccine along with several other infants from the local health centre.

In a child with a normal immune system a granulomatous skin reaction develops only at the site of BCG vaccination. If an individual has an underlying immunodeficiency this can lead to dissemination of the bacteria followed by widespread granulomatous inflammation. Disseminated BCG infection has an incidence of 1–20 per 10 million doses of vaccine given, with a mortality of 50–80%.<sup>1–3</sup> The incubation period varies from 1 to 5 months and children are usually reported as healthy prior to vaccination.

The majority of cases of disseminated BCG have been reported in immunocompromised hosts, particularly those infected with HIV. There was no chance to evaluate immunodeficiency, inherited or acquired, in this infant.

There are no previous case reports of disseminated BCG following vaccination of individuals or infants born to mothers taking anti-TNF therapies. However, it is well recognised that TNF-alpha is crucial to granuloma formation and anti-tuberculous immunity. The U.S. Food and Drugs Administration has labelled infliximab as a Category B drug which means that animal studies have not demonstrated foetal risk but there are no controlled studies in pregnant women. There have been over 300 reports of infliximab use during pregnancy, but less than 10% of these women were on treatment throughout the whole pregnancy. Infliximab is an IgG1 antibody that does not cross the placenta in the first trimester, thereby reducing exposure to the foetus during the period of organogenesis. The evidence suggests that the rates of miscarriage, prematurity and congenital malformations in women exposed to infliximab are not different from non-exposed pregnancies.<sup>4–7</sup> However, in the third trimester it readily crosses the placenta, remaining detectable in the infant's serum for up to 7 months after birth. Vasiliauskas et al. reported a case of woman with refractory CD treated with 10 mg/kg infliximab 6–8 weekly throughout pregnancy.<sup>8</sup> The mother breast fed and continued to receive infliximab post-partum. Serial samples revealed a progressive decline in the infant's infliximab levels, suggesting



**Figure 1** Non-caseating tuberculoid granulomas (arrowed) formed of epithelioid histiocytes with occasional Langhans' type giant cells surrounded by a cuff of lymphocytes, in the lungs, liver and dura. There is evidence of early central necrosis.

placental transfer rather than via breast milk. Mahadevan and colleagues have also measured infliximab levels in infants born to mothers receiving 5 mg/kg infliximab 8 weekly throughout pregnancy. In all six cases levels of infliximab at birth were higher in the infant than the mother confirming that it is readily transferred across the placenta.<sup>9</sup> In adults the half-life of infliximab is 8–9.5 days; however in infants it remained detectable for between 2 and 7 months.<sup>8,9</sup> It has been proposed that newborn's reticulo-endothelial system is not sufficiently developed to clear the antibody effectively.<sup>7</sup> Thus, similar to other maternally acquired antibodies, the half-life of infliximab appears prolonged in infants. The effect of infliximab on the development of the infant immune system is unknown. One infant in the above case report had an appropriate response to vaccination at 7 months.<sup>8</sup>

A case series of mothers who stopped infliximab at week 30 found no detectable levels of infliximab in newborn serum.<sup>10</sup> Thus, stopping infliximab in the 3rd trimester may reduce potentially harmful accumulation of the drug in the infant.

Live and attenuated vaccines are contraindicated in individuals on biologics. One case where an adult inadvertently received BCG vaccination whilst on infliximab received chemoprophylaxis with isoniazid for 2 months without signs of infection.<sup>11</sup>

There are currently no guidelines regarding vaccination of newborns with antenatal exposure to biologics. The UK Department of Health BCG information sheet states that a child should not receive the BCG if they are having treatment for cancer or other serious conditions that weaken the immune system. In view of the case presented here, we feel that this information should be modified to include questions as to mother's health and potential immunosuppressive therapy.

Adalimumab, another IgG1 anti-TNF antibody used to treat inflammatory bowel disease, should have the same the same placental transfer rate as infliximab. However, Certolizumab pegol (a Fab' fragment) is thought not to cross the placenta (due to the pegylated molecule), although there is no published data to support this.<sup>12</sup>

The benefits and risks of continuing infliximab or other anti-TNF therapies for inflammatory bowel disease during pregnancy should be discussed at length with the patient. Active disease during pregnancy may be associated with adverse pregnancy outcomes, therefore decisions need to be made on an individual basis.

Our patient became pregnant again, one year after the death of her first child. Following discussions, she requested to stop her infliximab, receiving her last dose when she was 8 weeks pregnant. Her Crohn's Disease began to flare at around week 18, requiring a period of inpatient therapy with intravenous hydrocortisone. Her baby was born 10 weeks early and was remained on the neonatal unit for 5 weeks, but has since been fit and well.

The American Gastroenterological Association position statement suggests continuing anti-TNF to maintain remission seems to outweigh any risks to the infant and mother.<sup>13</sup> In infants born to mothers receiving IgG1-based anti-TNF therapies, we would recommend postponing live vaccination, probably by at least 7 months. If the BCG vaccination is accidentally given to an infant born to a mother on

infliximab, empirical mycobacterial prophylaxis may reduce the chances of disseminated infection. Where possible, infliximab should be stopped in the 3rd trimester. However, this decision must be made on a case by case basis, where active disease could have just as harmful consequences on pregnancy outcome.

### 3. Statement of authorship

KC wrote the manuscript with contributions from JN, SS, AP and JA. The figure and legend were provided by LK. All authors read and approved the final manuscript.

### References

1. Lotte A, Wasz-Hockert O, Poisson N, Engbaek H, Landmann H, Quast U, Andrasofszky B, Lugosi L, Vadasz I, Mihailescu P. Second IUATLD study on complications induced by intradermal BCG-vaccination. *Bull Int Union Tuberc Lung Dis* 1988 June; **63** (2):47–59.
2. Talbot EA, Perkins MD, Silva SF, Frothingham R. Disseminated Bacille Calmette–Guerin disease after vaccination: case report and review. *Clin Infect Dis* 1997 June; **24**(6):1139–46.
3. Hesselning AC, Cotton MF, Fordham von RC, Graham SM, Gie RP, Hussey GD. Consensus statement on the revised World Health Organization recommendations for BCG vaccination in HIV-infected infants. *Int J Tuberc Lung Dis* 2008 December; **12**(12): 1376–9.
4. Katz JA, Antoni C, Keenan GF, Smith DE, Jacobs SJ, Lichtenstein GR. Outcome of pregnancy in women receiving infliximab for the treatment of Crohn's disease and rheumatoid arthritis. *Am J Gastroenterol* 2004 December; **99**(12):2385–92.
5. Mahadevan U, Kane S, Sandborn WJ, Cohen RD, Hanson K, Terdiman JP, Binion DG. Intentional infliximab use during pregnancy for induction or maintenance of remission in Crohn's disease. *Aliment Pharmacol Ther* 2005 March 15; **21**(6):733–8.
6. Lichtenstein GR, Feagan BG, Cohen RD, Salzberg BA, Diamond RH, Chen DM, Pritchard ML, Sandborn WJ. Serious infections and mortality in association with therapies for Crohn's disease: TREAT registry. *Clin Gastroenterol Hepatol* 2006 May; **4**(5):621–30.
7. Dubinsky M, Abraham B, Mahadevan U. Management of the pregnant IBD patient. *Inflamm Bowel Dis* 2008 December; **14** (12):1736–50.
8. Vasilias EA, Church JA, Silverman N, Barry M, Targan SR, Dubinsky MC. Case report: evidence for transplacental transfer of maternally administered infliximab to the newborn. *Clin Gastroenterol Hepatol* 2006 October; **4**(10):1255–8.
9. Mahadevan U, Church JA. Infliximab levels in infants born to women with inflammatory bowel disease. *Gastroenterology* 2007; **132**:A144 Ref Type: Generic.
10. Kane S, Ford J, Cohen R, Wagner C. Absence of infliximab in infants and breast milk from nursing mothers receiving therapy for Crohn's disease before and after delivery. *J Clin Gastroenterol* 2009 January 22.
11. Toussiot E, Wendling D. Bacillus Calmette–Guerin vaccination in a patient treated with infliximab. *J Rheumatol* 2005 December; **32**(12):2500–1.
12. Assche GV, Dignass A, Reinisch W, Janneke van der Woude C, Sturm A, De Vos M, et al. The second European evidence based consensus on the diagnosis and management of Crohn's disease: special situations. *Journal of Crohn's and Colitis* 2010; **4**:63–101.
13. Mahadevan U, Kane S. American gastroenterological association institute medical position statement on the use of gastrointestinal medications in pregnancy. *Gastroenterology* 2006 July; **131** (1):278–82.