

The Presence but not the Location of an Appendicolith Affects the Success of Interval Appendectomy in Children with Ruptured Appendicitis

Iyore A. James, Stephen Druhan, Donna A. Caniano, Gail E. Besner

Nationwide Children's Hospital and The Ohio State University College of Medicine
Columbus, OH 43205, USA

E-mail: iyore.james@osumc.edu

Received July 20, 2010; revised February 25, 2011; accepted February 28, 2011

Abstract

Purpose: To determine whether the presence and/or location of an appendicolith can predict failure of initial non-operative management in children with ruptured appendicitis. **Methods:** A retrospective chart review of pediatric patients presenting with ruptured appendicitis was performed. Patients in whom the intent to treat was with initial non-operative management and interval appendectomy (IA) were selected (n = 117). One patient was excluded due to the presence of both intraluminal and extraluminal appendicoliths. Children who failed initial non-operative management were assigned to the "failure" group (n = 22). Children that improved and underwent elective IA were assigned to the "success" group (n = 94). Age, gender, duration of symptoms, presence of an appendicolith, appendicolith location (intraluminal/extraluminal), presence of a drainable abscess, and complications were reviewed. **Results:** There was an overall 18.8% failure rate for IA. Patients with an appendicolith had a 41.7% failure rate, and patients without an appendicolith had a 13% failure rate ($p = 0.003$). Patients with intraluminal or extraluminal appendicoliths each had a 41.7% failure rate. The presence or absence of a drainable intra-abdominal abscess did not affect the failure rate. Children in the failure group presented to the hospital earlier (6.57 ± 2.59 vs. 10.02 ± 7.21 days; $p = 0.030$). **Conclusions:** The presence of an appendicolith increases the likelihood of failure of initial non-operative management of ruptured appendicitis in children; however, the location of the appendicolith is not a predictor of failure.

Keywords: Ruptured Appendicitis, Failure Non-Operative Management, Appendicolith

1. Introduction

The management of ruptured appendicitis in a child that presents with a relatively indolent course remains a subject of debate [1]. There is a growing consensus for treating these patients non-operatively with intravenous antibiotics and percutaneous drainage of abscess (if amenable), followed by an interval appendectomy in 6-8 weeks [2-5]. However, the routine performance of interval appendectomy remains controversial [6-8].

Failure rates of initial non-operative approaches for ruptured appendicitis range from 6%-26% [9-13]. Several studies on predictors of failure of non-operative management have yielded inconsistent results [10-14]. Although some authors report that the presence of an appendicolith is predictive of failure [10,11] others did

not demonstrate this finding [13,14]. The discrepancy in these reports may be related to the location of the appendicolith, however, there have been no studies of this reported in the literature. The aim of the current study was to determine whether the location of an appendicolith could predict failure of non-operative management in children with ruptured appendicitis.

2. Methods

The study was approved by the Nationwide Children's Hospital Institutional Review Board (Protocol #IRB08-00317). A search of all pediatric patients presenting to our institution with ruptured appendicitis between January 1994 and March 2009 was performed on the Nationwide Children's Internal Decision Support Data System.

A retrospective chart review was conducted for patients in whom the intent to treat was with initial non-operative management and subsequent interval appendectomy (IA). Initial non-operative management consisted of intravenous broad spectrum antibiotic therapy (typically ampicillin, gentamycin and clindamycin or gentamycin and clindamycin alone), with or without percutaneous drainage of intra-abdominal abscess. When amenable, percutaneous drainage of abscess was performed under CT scan or ultrasound guidance by interventional radiologists. Patients were typically monitored for 4-5 days to ensure resolution of symptoms and discharged to home with intravenous antibiotics through a peripherally inserted central venous catheter (PICC). Interval appendectomy was usually performed 4 to 8 weeks later (median 6 weeks). Patients who had persistent or recurrent symptoms or who developed frank peritonitis underwent appendectomy prior to scheduled elective IA, and were included in the “failure” group ($n = 22$). Children that improved upon initiation of therapy and underwent elective IA were included in the “success” group ($n = 94$). Age, gender, duration of symptoms, appendicolith location, presence of a drainable abscess on radiographic imaging (CT scan or ultrasonography), complications, and pathology reports to confirm the presence of an appendicolith, were reviewed.

Statistical analysis was performed using the Student t

test and logistic regression with statistical significance set at $p \leq 0.05$.

3. Results

3.1. Patient Selection

A total of 985 patients were admitted with a primary diagnosis of ruptured appendicitis between January 1994 and March 2009. There were 117 patients in whom the intent to treat was with initial non-operative management and subsequent interval appendectomy (**Figure 1**). One patient in the success group was excluded because both intraluminal and extraluminal appendicoliths were seen on CT scan, leaving 116 patients left to study.

3.2. Patient Demographics

The study group consisted of 75 boys and 41 girls with an age range of 1 to 17 years. The most common presenting symptoms were right lower quadrant pain, fever, diarrhea, nausea and vomiting. Twenty-two out of 116 patients failed elective IA management giving an overall failure rate of 18.8%. There was no statistical difference in the mean age of the success vs. failure groups (10.03 ± 3.90 years vs. 8.59 ± 4.46 years; p -value 0.13). Children in the failure group were ill (mostly abdominal pain) for

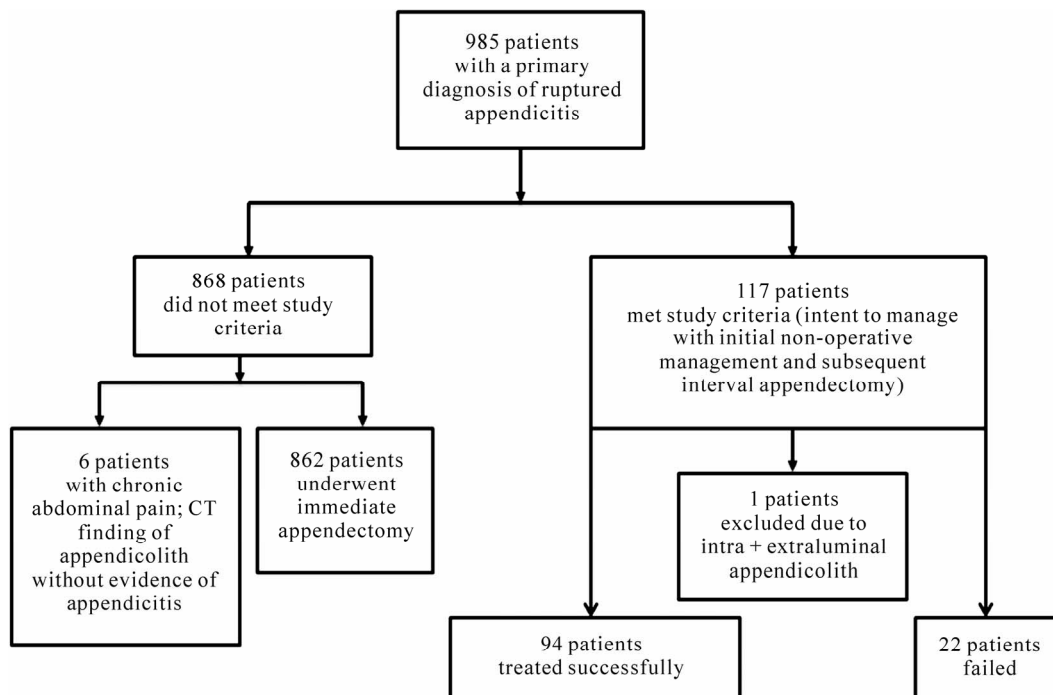


Figure 1. Methodology flowchart. (A review of 985 charts revealed 117 patients in whom the intent was to treat with initial non-operative management and subsequent interval appendectomy (IA). One patient was excluded from the study because both intraluminal and extraluminal appendicoliths were identified on radiographic imaging. Twenty-two patients failed conservative management).

a shorter period of time prior to admission compared to children in the success group (6.57 ± 2.59 days vs. 10.02 ± 7.21 days; p -value 0.03) (Table 1).

3.3. Presence/Location of Appendicolith

All radiology studies (CT scans or ultrasonography) of the 116 patients that met study criteria were retrospectively reviewed by a single certified radiologist. The radiologist identified 8 patients with intraluminal appendicolith and 4 patients with extraluminal appendicolith in the “failure” group, and 12 patients with intraluminal appendicolith and 20 patients with extraluminal appendicolith in the “success” group, for a total of 44 patients with an appendicolith identified. Upon review of the pathology and operative reports of these 116 patients, there were 5 patients with intraluminal appendicolith and 5 patients with extraluminal appendicolith in the “failure” group, and there were 7 patients with intraluminal appendicolith and 7 patients with extraluminal appendicolith in the “success” group, for a total of 24 patients with an appendicolith identified (Table 1). The overall accuracy rate for the radiologist identifying any appendicolith was 79.3% (Table 2), and the overall accuracy rate for the radiologist identifying the location of the appendicolith was 90.5% (Table 3).

Of the 24 patients that had an appendicolith confirmed on pathology and/or operative reports, 10 patients failed IA (41.7 % failure rate). Of the 92 patients without an appendicolith on pathology/operative reports, 12 failed (13% failure rate). Thus, the presence of an appendicolith increases the rate of failure of IA ($p = 0.003$; (1.73, 13.1 95% CI) (Table 1). Patients with either an intraluminal or extraluminal appendicolith had equal failure rates of 41.7% (Figure 2).

3.4. Presence of abscess

There were a total of 66 intra-abdominal abscesses that were amenable to percutaneous drainage by interventional radiology. Of the 66 patients with a drainable intra-abdominal abscess, 14 failed IA (21.2% failure rate). Of the 50 patients without a drainable abscess present, 8 failed IA (16% failure rate). Thus, the presence or absence of a drainable intra-abdominal abscess did not affect the failure rate of IA ($p = 0.48$).

3.5. Complications

There were 4 patients in the failure group that had complications including two patients with wound infection, one patient with *Clostridium difficile* colitis after initiation of antibiotic therapy, and one patient with a sub-hepatic

abscess requiring percutaneous drainage by interventional radiology. There were 3 patients with complications in the success group, including one patient with a pelvic abscess that developed after initial percutaneous drainage of an intra-abdominal abscess requiring a second percutaneous drainage by interventional radiology, a second patient with non-life threatening antibiotic allergy, and a third patient that developed an enterocutaneous fistula after initial placement of a percutaneous drain by interventional radiology that resolved with conservative management.

Table 1. Demographics of 116 patients in whom the intent to treat was with initial non-operative management and subsequent elective interval appendectomy (IA).

	Success 94/116 (81.2%)	Failure 22/11 (18.8%)	p -value	Odds ratio
Age (years)	10.03 \pm 3.90	8.59 \pm 4.46	0.13	
Duration of symptoms (days)	10.02 \pm 7.21	6.57 \pm 2.59	0.03	
Appendicolith (n = 92)			0.003	4.762
No	80/92 (87%)	12/92 (13%)		
Any	14/24 (58.3%)	10/24 (41.7%)	-	-
Extraluminal Appendicolith (n = 12)	7/12 (58.3%)	5/12 (41.7%)	1	1
Intraluminal Appendicolith (n = 12)	7/12 (58.3%)	5/12 (41.7%)	-	-
Drainable Abscess Present (n = 66)	52/66 (78.8%)	14/66 (21.2%)	0.480	0.708
No	42/50 (84%)	8/50 (16%)	-	-
Drainable Abscess (n = 50)				
Complications (n = 7)	3/7 (42.9%)	4/7 (57.1%)	0.018	0.148
No	91/109 (83.5%)	18/109 (16.5%)	-	-
Complications (n = 109)				

Twenty-two of the 116 patients who met eligibility criteria failed this approach, giving an overall failure rate of 18.8%. Values are reported as mean \pm standard deviation. Children in the failure group were ill for a shorter period of time prior to admission compared to children in the success group ($p = 0.03$). Logistic regression was used to test whether the presence and/or the location of an appendicolith affected the success of initial non-operative management. Note that the presence and location of appendicoliths in this table were defined by operative notes and pathology reports. Compared to patients with any appendicolith, patients with no appendicolith had a significantly lower failure rate (13%, $p = 0.003$). There were equal numbers of patients with extraluminal appendicoliths ($n = 12$) and intraluminal appendicoliths ($n = 12$) in the study population. The failure rate of patients with either extraluminal or intraluminal appendicoliths was the same (41.7%, $p = 1$). The incidence of a complication was significantly increased in the “failure” group compared to the “success” group ($p = 0.018$).

Table 2. Accuracy of the radiologist’s ability to diagnose the presence of an appendicolith.

Radiology Findings	Operative/Pathology Findings		Number of patients
	(+)	(-)	
	Appendicolith	Appendicolith	
(+) Appendicolith	22	22	44
(-) Appendicolith	2	70	72
Total	24	92	116

The radiologist’s findings regarding the presence of an appendicolith in patients presenting with ruptured appendicitis in whom the intent was to treat with initial non-operative management and subsequent IA have been correlated with the operative notes/pathology reports. The accuracy of the radiologist’s ability to diagnose the presence of an appendicolith was 79.3%; positive predictive value equals 50%; negative predictive value equals 97.2%.

Table 3. Accuracy of the radiologist’s ability to diagnose the location of an appendicolith.

Radiology Findings	Operative/Pathology Findings	
	Intraluminal Appendicolith	Extraluminal Appendicolith
Intraluminal Appendicolith	7	1
Extraluminal Appendicolith	1	12

The radiologist’s findings regarding the location of an appendicolith have been correlated with the operative notes/pathology reports of the 24 patients noted to have any appendicolith by pathology/operative reports. Three patients had intraluminal appendicoliths identified on pathology that were not identified by the radiologist and thus not included in this table. The accuracy of the radiologist’s diagnosis of the location of an appendicolith was 90.5%; positive predictive value equals 87.5%; negative predictive value equals 92.3%.

4. Discussion

In a hemodynamically stable pediatric patient with ruptured appendicitis and no signs of diffuse peritonitis, conservative management with intravenous antibiotics, percutaneous drainage of abscess (if amenable), and interval appendectomy in 6-8 weeks is the current preferred treatment by many [1,15]. Several authors have reported that the presence of an appendicolith is predictive of failure of initial non-operative management with elective IA, and that in these patients, immediate surgery is recommended [10,11]. However, others have reported no correlation between the presence of an appendicolith and failure of initial non-operative management [13,14]. To clarify this discrepancy, we sought to investigate our experience and to determine whether the location of an appendicolith can influence the success of elective IA management.

Approximately 26% of the 325 (average) cases of acute appendicitis diagnosed annually at our institution

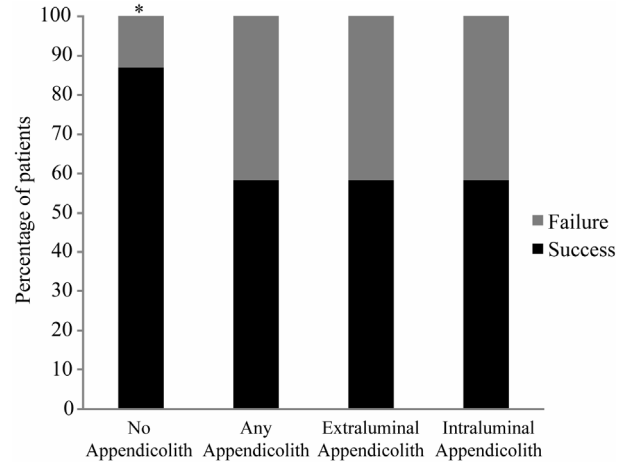


Figure 2. Success of IA based on the presence and location of appendicolith. (There were 24 patients with an appendicolith and 92 patients without an appendicolith identified on either operative or pathology reports. Of the 24 patients with an appendicolith, 10 failed IA (41.7 % failure rate). Of the 92 patients without an appendicolith, 12 failed (13% failure rate). Thus, the presence of an appendicolith increases the rate of failure of IA { $p = 0.003$; (1.73, 13.1 95% CI)} Patients with intraluminal or extraluminal appendicoliths had equal failure rates of 41.7%.)

present with ruptured appendicitis. During the study period, 116 patients (~12% of patients presenting with ruptured appendicitis) were treated with attempted IA. Ninety-four patients were successfully treated with IA whereas 22 patients failed conservative management, representing a failure rate of 18.8%, which is consistent with previous reports [9]. CT scans and ultrasonography exhibit similar accuracy for detecting acute appendicitis [16]. Radiology images (either CT scans or ultrasonography) of all 116 patients were retrospectively reviewed by a certified pediatric radiologist to evaluate the presence and location of an appendicolith. Operative and pathology reports were reviewed to evaluate the accuracy of the radiologist’s report. The overall accuracy of the radiologist identifying the presence and location of an appendicolith were 79.3% and 90.5% respectively.

In our study, a significantly higher proportion of patients that failed conservative management had an appendicolith. We anticipated that the presence of an extraluminal appendicolith might be predictive of failure of IA based on the following: 1) a retained appendicolith harbors intestinal bacteria and serves as a nidus for infection, 2) studies have shown that a retained appendicolith after appendectomy is associated with a high rate of intra-abdominal abscess formation [17,18], and 3) extraluminal retained post-operative appendicoliths require surgical removal to prevent recurrent infections. However, when the failure rate of IA was examined based on the location of the appendicolith, patients with either an

intraluminal or extraluminal appendicolith had a similar failure rate of 41.7%. Since only 20.7% ($n = 24$) of our study population presenting with perforated appendicitis and intent to treat with IA had an appendicolith documented on pathology or operative reports, it is possible that the location of an appendicolith was not predictive of failure due to small sample size. The recorded incidence of appendicolith in children presenting with perforated appendicitis has not been definitively established. In one study by Fraser *et al.*, the incidence of appendicolith based on histopathology reports was 26.3% in children with perforated appendicitis, and this was significantly higher compared to children that had either “uncomplicated appendicitis,” “non-inflamed appendix,” or “incidental appendectomy” [19].

Nadler *et al.* reported that the need for abscess drainage doubles the likelihood of failure of initial non-operative management due to inadequate source control [13]. We did not demonstrate this finding in our study. Statistically significant characteristics of patients that failed conservative treatment were the presence of an appendicolith and duration of symptoms. The fact that significantly more patients in the failure group presented to the hospital earlier in the course of their illness suggests that the severity of their symptoms may have prompted the caregiver to bring the child to the emergency department sooner. We have not verified this assumption in this study because of the lack of a reliable standardized objective marker for assessing the severity of presenting symptoms. In a matched analysis comparing clinical characteristics of patients treated with initial non-operative management versus immediate appendectomy for perforated appendicitis, Henry *et al.* observed that the only statistically significant difference between the two groups was duration of abdominal pain, where patients with pain less than 5 days in duration were more likely to undergo immediate appendectomy [2]. These investigators also demonstrated that patients who failed nonoperative management had a shorter duration of abdominal pain (average 4.4 days) compared to patients that were successfully treated with nonoperative management (average 7.3 days). Their findings are consistent with our results.

Our study demonstrates that the presence of an appendicolith increases the likelihood of failure of initial non-operative management of ruptured appendicitis in children, but the location of the appendicolith is not a predictor of failure of initial non-operative management in these patients. Furthermore, it is apparent that the radiologist at times identifies appendicoliths that are not confirmed on operative/radiology reports. Thus, the presence of an appendicolith on admission CT scan or ultrasonography should not necessarily dissuade the

practitioner from attempting initial non-operative management with IA, whether the appendicolith is reported to be intraluminal or extraluminal. While established predictors for failure of non-operative management may be essential for standardizing care of ruptured appendicitis in pediatric patients, careful clinical judgment continues to be imperative in the management of these patients.

5. References

- [1] C. Chen, C. Botelho, A. Cooper, P. Hibberd and S. K. Parsons, “Current Practice Patterns in the Treatment of Perforated Appendicitis in Children,” *Journal of the American College of Surgeons*, Vol. 196, No. 2, February 2003, pp. 212-221. doi:10.1016/S1072-7515(02)01666-6
- [2] M. C. W. Henry, G. Gollin, S. Islam, K. Sylvester, A. Walker, B. L. Silverman and R. Lawrence Moss, “Matched Analysis of Nonoperative Management Vs Immediate Appendectomy for Perforated Appendicitis,” *Journal of Pediatric Surgery*, Vol. 42, No. 1, January 2007, pp. 19-24. doi:10.1016/j.jpedsurg.2006.09.005
- [3] T. R. Weber, M. A. Keller, R. J. Bower, G. Spinner and K. Vierling, “Is Delayed Operative Treatment Worth the Trouble with Perforated Appendicitis in Children?” *The American Journal of Surgery*, Vol. 186, No. 6, December 2003, pp. 685-689. doi:10.1016/j.amjsurg.2003.08.027
- [4] D. W. Vane and N. Fernandez, “Role of Interval Appendectomy in the Management of Complicated Appendicitis in Children,” *World Journal of Surgery*, Vol. 30, No. 1, January 2006, pp. 51-54. doi:10.1007/s00268-005-7946-2
- [5] M. Samuel, G. Hosie, and K. Holmes, “Prospective Evaluation of Nonsurgical Versus Surgical Management of Appendiceal Mass,” *Journal of Pediatric Surgery*, Vol. 37, No. 6, June 2002, 882-886. doi:10.1053/jpsu.2002.32895
- [6] D. Puapong, S. L. Lee, P. I. Haigh, A. Kaminski, I. L. Liu and H. Applebaum, “Routine Interval Appendectomy in Children Is Not Indicated.” *Journal of Pediatric Surgery*, Vol 42, No. 5, May 2007, pp. 1500-1503. doi:10.1016/j.jpedsurg.2007.04.011
- [7] I. Karaca, Z. Altintoprak, A. Karkiner, G. Temir and E. Mir, “The Management of Appendiceal Mass in Children: Is Interval Appendectomy Necessary?” *Surgery Today*, Vol. 31, No. 8, August 2001, pp. 675-677. doi:10.1007/s005950170068
- [8] S. H. Ein and B. Shandling B, “Is Interval Appendectomy Necessary after Rupture of an Appendiceal Mass?” *Journal of Pediatric Surgery*, Vol. 31, No. 6, June 1996, pp. 849-850. doi:10.1016/S0022-3468(96)90151-7
- [9] R. E. Andersson and M. G. Petzold, “Nonsurgical Treatment of Appendiceal Abscess or Phlegmon: A Systemic Review And Meta-Analysis,” *Annals of Surgery*, Vol. 246, No. 5, November 2007, pp. 741-s748. doi:10.1097/SLA.0b013e31811f3f9f
- [10] S. H. Ein, J. C. Langer and A. Daneman, “Nonoperative Management of Pediatric Ruptured Appendix with In-

- flammatory Mass or Abscess: Presence of an Appendicolith Predicts Recurrent Appendicitis," *Journal of Pediatric Surgery*, Vol. 40, No. 10, October 2005, pp. 1612-1615. doi:10.1016/j.jpedsurg.2005.06.001
- [11] C. J. Aprahamian, D. C. Barnhart and S. E. Bledsoe, "Failure in The Nonoperative Management of Pediatric Ruptured Appendicitis: Predictors and Consequences," *Journal of Pediatric Surgery*, Vol. 42, No. 6, June 2007, pp. 934-938. doi:10.1016/j.jpedsurg.2007.01.024.
- [12] J. Gillick, M. Velayudham and P. Puri, "Conservative Management of Appendix Mass in Children" *British Journal of Surgery*, Vol. 88, No. 11, November 2001, pp. 539-542.
- [13] E. P. Nadler, K. K. Reblock and K. G. Vaughan, "Predictors of Outcome for Children with Perforated Appendicitis Initially Treated with Non-Operative Management," *Surgical Infections*, Vol. 5, No. 4, Winter 2004, pp. 349-356. doi:10.1089/sur.2004.5.349
- [14] T. Levin, C. Whyte, R. Borzykowski, B. Han, N. Blitman and B. Harris, "Nonoperative Management of Perforated Appendicitis in Children: Can CT Predict Outcome?" *Pediatric Radiology*, Vol. 37, No. 3, March 2007, pp. 251-255. doi:10.1007/s00247-006-0384-y
- [15] S. G. Muehlstedt, T. Q. Pham and D. J. Schmeling, "The Management of Pediatric Appendicitis: A Survey of North American Pediatric Surgeons," *Journal of Pediatric Surgery*, Vol. 39, No. 6, June 2004, pp. 875- 859. doi:10.1016/j.jpedsurg.2004.02.035
- [16] P. Poortman P, P. N. M. Lohle, C. M. C Schoemaker, H. J Oostvogel, H. J. Teeppen, K. A. Zwinderman and J. F. Hamming, "Comparison of CT and Sonography in the Diagnosis of Acute Appendicitis: A Blinded Prospective Study," *American Journal of Roentgenology*, Vol. 181, No. 5, November 2003, pp. 1355- 1359.
- [17] T. E. Monfore and F. J. Montegut, "The Case of the Missing Fecalith," *Archives of Surgery*, Vol. 86, No. 4, April 1963, pp. 655- 658.
- [18] M. Mulder, "Retained Fecalith as Late Complication of Appendectomy," *Journal of American Medical Association*, Vol. 225, No. 6, August 1973, pp. 639.
- [19] N. Fraser, C. Gannon and M. D.Stringer, "Appendicular Colic and the Non-Inflamed Appendix: Fact or Fiction?" *European Journal of Pediatric Surgery*, Vol. 14, No. 1, February 2004, pp. 21-24.