

Cite this article as: Matsuura K, Mogi K, Takahara Y. Off-pump waffle procedure using an ultrasonic scalpel for constrictive pericarditis. *Eur J Cardiothorac Surg* 2015; doi:10.1093/ejcts/ezu554.

## Off-pump waffle procedure using an ultrasonic scalpel for constrictive pericarditis<sup>†</sup>

Kaoru Matsuura\*, Kenji Mogi and Yoshiharu Takahara

Department of Cardiovascular Surgery, Funabashi Municipal Medical Center, Funabashi City, Chiba, Japan

\* Corresponding author. Department of Cardiovascular Surgery, Funabashi Municipal Medical Center, 1-21-1 Kanasugi, Funabashi City, Chiba, Japan. Tel: +81-47-4383321; fax: +81-47-4387323; e-mail: km4717jp@yahoo.co.jp (K. Matsuura).

Received 29 October 2014; received in revised form 8 December 2014; accepted 22 December 2014

### Abstract

Radical pericardiectomy alone is not effective in patients with constrictive pericarditis accompanied by epicardial constriction. However, a waffle procedure is very effective in these patients, as we demonstrate in this paper. Firstly, we performed a radical pericardiectomy via a median sternotomy. We used an ultrasonic scalpel for this procedure, and an apical suction device was useful for lifting the heart. This technique is similar to that used in off-pump coronary artery bypass grafting. After the whole heart was dissected from the markedly thickened parietal pericardium, a waffle procedure was performed on the left ventricle first. Multiple longitudinal and transverse incisions were made on the thickened epicardium using an ultrasonic scalpel. After the left ventricle was fully relieved of constriction, the same procedure was performed on the right ventricle. Thereafter, a remarkable improvement of our patient's haemodynamic status was obtained. The whole procedure can be done without cardiopulmonary bypass. We describe tips for performing the waffle procedure without cardiopulmonary bypass using an ultrasonic scalpel and apical suction device, as well as pitfalls to avoid.

**Keywords:** off-pump surgery · pericardium

### INTRODUCTION

Effusive constrictive pericarditis is a chronic inflammation of the pericardium that causes severe cardiac constriction and cardiac diastolic dysfunction with concomitant cardiac tamponade. In cases where medical treatment is not effective, surgical treatment should be considered. Radical pericardiectomy is an effective procedure but some patients need a more aggressive epicardectomy, which is called a waffle procedure [1].

To reduce the trauma associated with this procedure, we performed a waffle procedure using an ultrasonic scalpel for the pericardiectomy and an epicardial incision to minimize bleeding. We used an apical suction device to avoid performing cardiopulmonary bypass. We describe tips for performing the waffle procedure without cardiopulmonary bypass using an ultrasonic scalpel and apical suction device, as well as pitfalls to avoid.

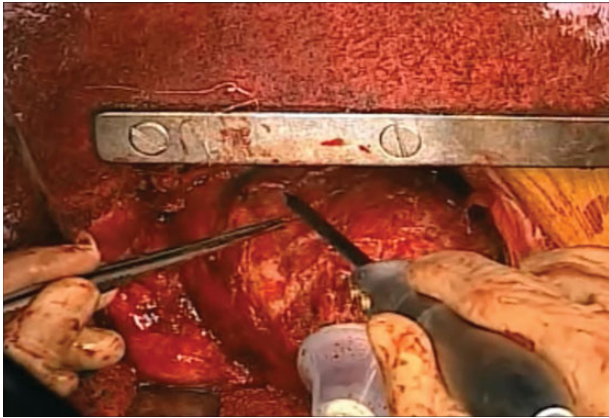
### TECHNIQUE

In the operative room, a pulmonary artery catheter should be inserted and monitored throughout the operation. With our patient under endotracheal anaesthesia, we performed a median

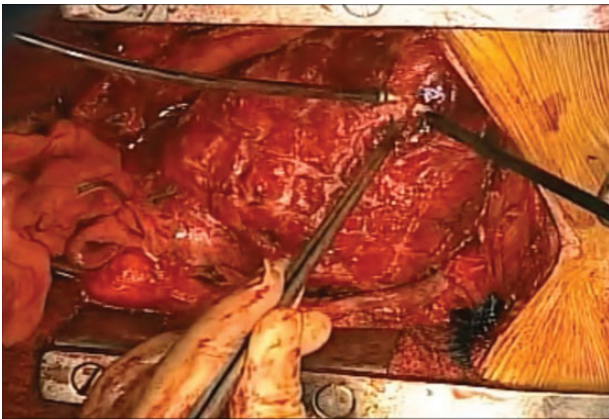
sternotomy and observed that the pericardium was severely thickened. Firstly, the whole heart was dissected out from the parietal pericardium using an ultrasonic scalpel (Harmonic Scalpel; Ethicon Endo-Surgery, Inc., Cincinnati, OH, USA). We had cardiopulmonary bypass on standby in case of haemodynamic deterioration, uncontrolled arrhythmias or unexpected bleeding. Initially, the heart was strongly adhered to the parietal pericardium. After dissecting the anterior portion, pericardial stitches were placed only on the left side. The heart was then lifted gradually using an apical suction device (Estech Atlas; AtriCure, Inc., West Chester, OH, USA). We found that opening the right pleural cavity was helpful, as it created space for the lifted heart. At this point, the surgeon should monitor haemodynamic parameters every time the apex of the heart is lifted. In our case, our patient's pulmonary artery pressure increased, but came down gradually as the heart adapted to the circumstances. When all of the epicardium constricting the heart had been visualized, we initiated the waffle procedure.

The waffle procedure consists of serial longitudinal and transverse epicardial incisions, which have the appearance of square blocks. The waffle procedure should be started on the left ventricle to avoid acute left heart failure. If a waffle incision is made first on the right ventricle, the left ventricle would suffer from massive preload without the relief of diastolic dysfunction, which could cause acute severe left heart failure.

<sup>†</sup>Presented at the 28th Annual Meeting of the European Association for Cardio-Thoracic Surgery, Milan, Italy, 11–15 October 2014.



**Figure 1:** Epicardial incisions are made on the lateral wall of the left ventricle with an ultrasonic scalpel aided by an apical suction device.



**Figure 2:** Epicardial incisions are made on the right ventricle.

We found that the ultrasonic scalpel was very useful for making the epicardial incisions. The first incision was made by carefully using the tip of the ultrasonic scalpel. This incision should penetrate to the muscular level; therefore, some bleeding from the muscle should be observed. If this incision is too shallow, the patient may remain haemodynamically unstable. Once we had made a good, deep epicardial incision, we used the sharp hook edge of the ultrasonic scalpel to extend the incisions longitudinally and transversely (Fig. 1). By using the hook tip, bleeding from the muscle can be minimized.

Once the epicardial incisions on the left ventricle had been partially completed, we repeated the same technique on the right ventricle (Fig. 2 and Video 1). Then, after completing the epicardial incisions on the right ventricle, incisions were made on the remaining part of the left ventricle, to the area where the apical suction device had been attached.

After all the incisions are made, remarkable improvement of the haemodynamic status was obtained. Whole procedure could be done without cardiopulmonary bypass.

## COMMENT

Surgery for constrictive pericarditis has a mortality rate of about 6–19% [2]. Among surgical complications, bleeding is one of the major concerns. To reduce the risk of bleeding, Heimbecker *et al.* reported the use of an atraumatic technique of epicardial incision,



**Video 1:** After radical pericardiectomy, multiple longitudinal and transverse incisions are made on the left ventricular thickened epicardium using an ultrasonic scalpel aided by an apical suction device. After the left ventricle is sufficiently relieved of constriction, the same procedure is performed for the right ventricle.

which they called the waffle procedure [1]. They used a normal surgical scalpel; however, we used an ultrasonic scalpel for the epicardial incisions to minimize bleeding from the epicardium and muscle. This surgery has several advantages for patients with a thickened epicardium, as summarized by Athanasiou *et al.* [3]. Ultrasonic scalpels have been widely used for harvesting the internal thoracic artery or during repeat heart surgery [4]. We found that careful use of this equipment minimized bleeding during both the pericardiectomy and when making the epicardial incisions. Especially for epicardial incisions, the sharp hook of the ultrasonic scalpel is very safe and effective.

To complete this operation without cardiopulmonary bypass, an apical suction device is essential. Fukumoto *et al.* reported on a pericardiectomy without cardiopulmonary bypass using an apical suction device [5]. Other authors have also reported the use of an ultrasonic scalpel for pericardiectomy [5, 6]. To obtain better surgical work space, it is important to place a pericardial stitch on the left side only and to open the right pleural cavity. After lifting the heart during the pericardiectomy of the lateral wall of the left ventricle, the patient may occasionally become haemodynamically unstable. But because the patient has a long-standing disease, and the heart has been severely constricted for a long time, they can usually tolerate this condition well.

It is very important to start epicardial incisions on the left ventricle. Epicardial incisions on the right ventricle would cause a massive preload to the left ventricle, potentially leading to acute left heart failure. Once some epicardial incisions have been made on the left ventricle, pulmonary artery pressure drops gradually. Then it is safe to move on to making incisions on the right ventricle.

**Conflicts of interest:** none declared.

## REFERENCES

- [1] Heimbecker RO, Smith D, Shimizu S, Kestle J. Surgical technique for the management of constrictive epicarditis complicating constrictive pericarditis (the Waffle procedure). *Ann Thorac Surg* 1983;36:605–6.
- [2] Hoit BD. Management of effusive and constrictive pericardial heart disease. *Circulation* 2001;105:2939–42.

- [3] Athanasiou T, Kumar P, Al-Ruzzeh S, Aziz O, Charitou A, Hart J *et al.* Expended use of suction and stabilization devices in cardiothoracic surgery. *Ann Thorac Surg* 2003;76:1126-30.
- [4] Higami T, Kozawa S, Asada T, Shida T, Ogawa K. Skeletonization and harvest of the internal thoracic artery with an ultrasonic scalpel. *Ann Thorac Surg* 2000;70:307-8.
- [5] Fukumoto A, Yamagishi M, Doi K, Ogawa M, Inoue T, Yaku H. Off-pump pericardiectomy using an ultrasonic scalpel and a heart positioner. *Asian Cardiovasc Thorac Ann* 2007;15:e69-71.
- [6] Uchida T, Bando K, Minatoya K, Sasako Y, Kobayashi J, Kitamura S. Pericardiectomy for constrictive pericarditis using the harmonic scalpel. *Ann Thorac Surg* 2001;72:924-5.