

Full Length Research Paper

Histological and histometrical changes of ostrich thyroid gland during summer and winter seasons in Tehran, Iran

A. R. Beyzai* and M. Adibmoradi

Department of Basic Sciences, Faculty of Veterinary Medicine, University of Tehran, Tehran, Iran.

Accepted 27 December, 2010

The seasonal changes of ostrich thyroid structure in Tehran, which has a hot summer and a relatively cold winter, were studied. The study was conducted on thyroid glands of 20 ostriches in two groups (summer and winter group). The samples were collected by autopsy with a maximum of 0.5 cm thickness and were fixed in 10% formalin saline. The samples were embedded in paraffin, sectioned at 5 to 6 μm , stained by Hematoxylin and Eosin method and examined under light microscope. The results showed that the seasons had a significant effect on thyroid parenchyma-stroma ratio. This ratio was significantly increased in winter. The number and diameter of thyroid follicles were increased in winter too. The histometrical results showed that the number of thyroid follicles, active follicles and follicles with vacuolated colloid were significantly increased in winter ($p < 0.01$). The diameters of large follicles and epithelium height of follicles were also increased in winter significantly ($p < 0.01$). However, the results showed that the parenchyma of thyroid glands was significantly increased in winter which is associated with increase in thyroid activity in winter.

Key words: Seasonal changes, histology, thyroid, Ostrich, Iran.

INTRODUCTION

The thyroid gland was first described and named in 1650 (Sisson, 1975). The histology and ultrastructure of avian thyroids (Fujita and Tanizawa, 1966; French and Hodges, 1977) are like those of other vertebrates (classes) (Astier, 1980; Dent, 1986). With triiodothyronine (T_3), thyroxine (T_4) and calcitonin secretion, thyroid has an important role in metabolism and maintenance of calcium. It also influences reproduction and development.

Thyroid hormones are considered as the key controllers of that part of metabolic heat production that is necessary for the maintenance of high and constant body temperature in homeothermic birds and mammals (Danforth and Burger, 1984). They influence both aspects

of development (growth and differentiation/maturation) of birds (McNabb and King, 1993). Thyroid hormones are also important in several (organismal level) processes such as hatching, molt and reproduction in birds. The high perihatch thyroid hormone concentrations appear to be stimulating a variety of developmental and metabolic processes necessary for successful hatching (Decuypere et al., 1991). Changes in temperature appear to be one of the significant environmental factors that have the greatest influence on thyroid function. Environmental cold can act through the HPT (hypothalamic-pituitary-adrenal) axis to increase thyroid hormones release, and can alter the peripheral thyroid hormone balance by increasing extrathyroidal T_4 to T_3 conversion and increasing thyroid hormone turnover (that is, decrease hormone half-lives).

There are several reports on seasonal changes of thyroid hormones in birds. Although these changes are associated with structural changes of the gland, they have not been studied in farmed ostriches in Iran. Regarding the environmental condition of Tehran which has a hot summer and relatively cold winters, the objective

*Corresponding author. E-mail: a.beyzai@m-iau.ac.ir. Tel: +98 914 9979 124.

Abbreviations: T_3 , Triiodothyronine; T_4 , thyroxine; H&E, hematoxylin and eosin staining.

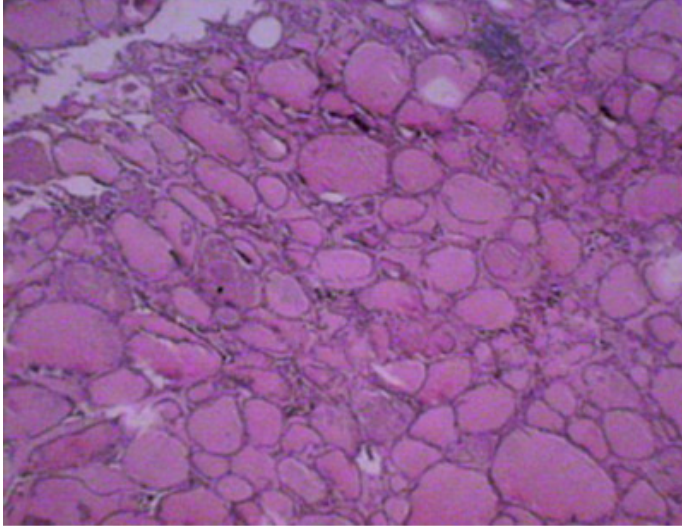


Figure 1. The ratio of stroma (connective tissue) to parenchyma (thyroid follicles) of the thyroid gland in ostrich was significantly increased in summer. H&E ($\times 4$).

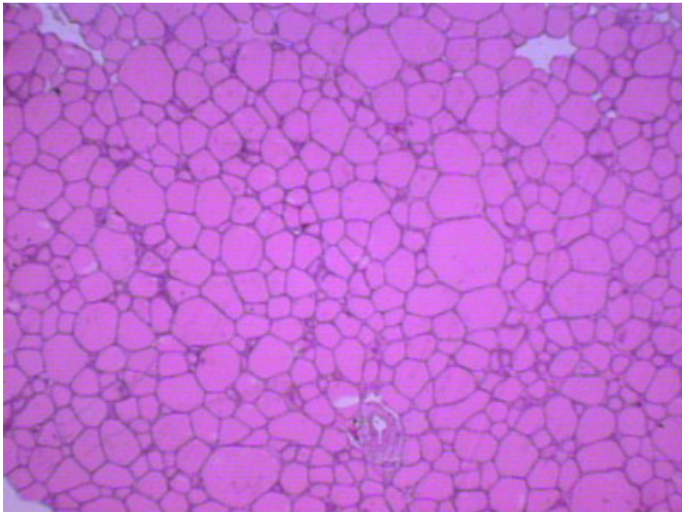


Figure 2. The increase in parenchyma (thyroid follicles) and decrease in stroma (connective tissue) in winter is significant in thyroid of ostrich. H&E ($\times 4$).

of this study was to show the histological and histometrical changes of the thyroid gland of farmed ostriches.

MATERIALS AND METHODS

The study was conducted in Tehran, which is located about 100 km south of Caspian Sea at an altitude of 1190 meter above sea level. Its annual temperature ranges from -7 to 39.4°C . The mean annual rainfall of the area is 316 mm. The studied animals included 20 male, mature ostriches (*Struthio camelus australis*) which were bred under the same environmental condition in summer and winter. Thyroid gland samples were taken from 10 ostriches in summer and 10 in winter in the same farm.

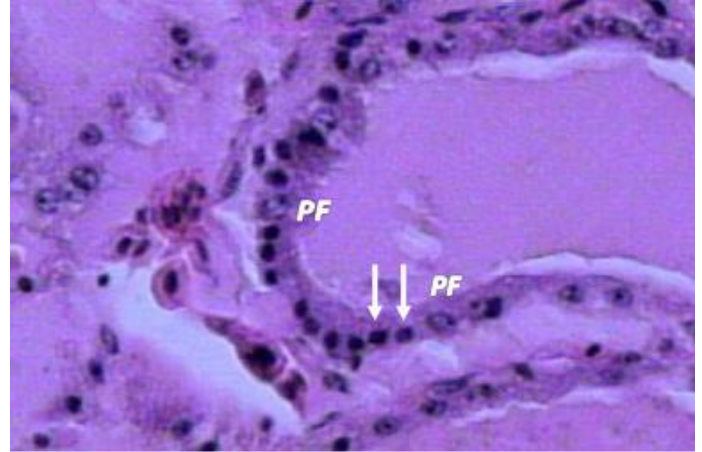


Figure 3. Cuboidal follicular cells (arrows) and parafollicular cells (PF) in the epithelium of a thyroid follicle. H&E ($\times 40$).

The ostriches were bred at normal environmental conditions at least for one month and were taken to slaughter house in order to take the specimens. The thyroid glands were removed using a scalpel. Sampling time was August 5th in summer and February 14th in winter. The samples were collected by autopsy, with maximum 0.5 cm thickness by autopsy and were fixed in 10% formalin saline. The samples were embedded in paraffin, sectioned at 5 to 6 μm , stained by Hematoxylin-Eosin method and examined under light microscope. In order to show the seasonal changes in reticular fibers of the stroma, reticulin stain was used.

In histological study, the capsule of the gland, thyroid follicles, stroma, parenchyma and the ratio of parenchyma to stroma were examined under the light microscope. In histometrical study, total number of follicles, the number of large and small follicles and the number of active and inactive follicles were counted. Also, diameters of large and small follicles and the height of epithelium for active and inactive follicles were carefully measured.

In order to count and measure the above parameters in each season, 20 slides from each of the 10 samples were examined and 5 microscopic fields were randomly examined on each slide. An eyepiece graticule plus a calibration slide with a light microscope (MOTIC BA 200) were used for histometrical studies. The results were analyzed using SPSS 15.0 for Windows Software. T-test was used to compare the mean values. To define the correlation coefficient between the measured parameters, the Pearson correlation coefficient was used.

RESULTS

Microscopic examinations showed that ostrich thyroid gland was surrounded by a thin capsule of dense irregular connective tissue which showed no evidence of seasonal changes. The parenchyma-stroma ratio decreased in summer due to the decrease in parenchyma and increase in thyroid connective tissue (Figure 1). This ratio increased in winter due to increase in parenchyma and decrease in connective tissue (Figure 2). The follicular or main cells were the most dominant type of thyroid follicular cells, which were cuboidal or columnar in active follicles and squamous in inactive follicles (Figures 3 and 4).

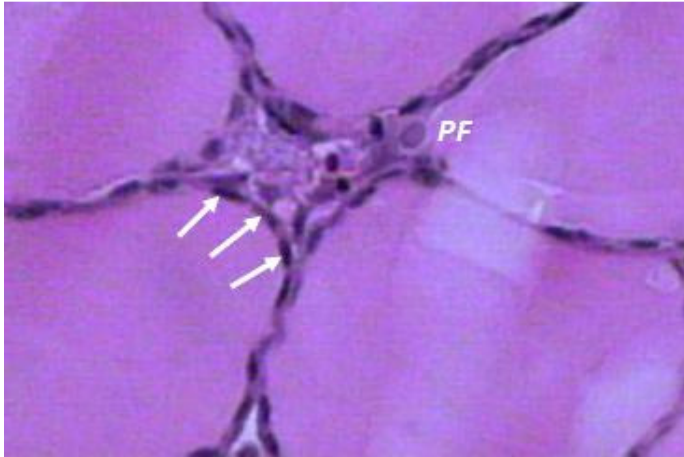


Figure 4. Squamous epithelial cells of an inactive thyroid follicle (arrows) and a parafollicular cell (PF). H&E (×40).

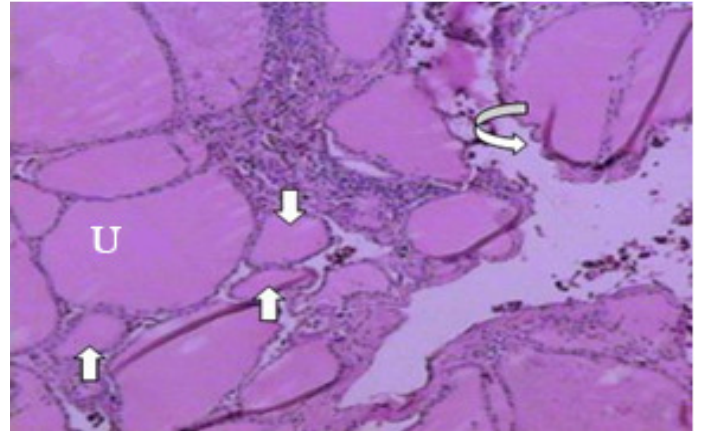


Figure 6. Nonuniform and thin epithelium (bent arrow) of thyroid follicles with decreased diameter (straight arrows) and uniformly stained colloid (U) in the thyroid of ostrich in summer. H&E (×10).

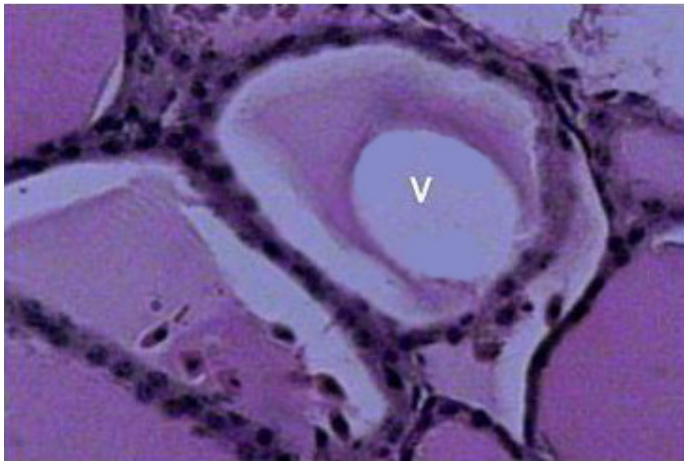


Figure 5. A large vacuole (V) in colloid of an active thyroid follicle in winter. Cuboidal follicular cells are dominant. H&E (×40).

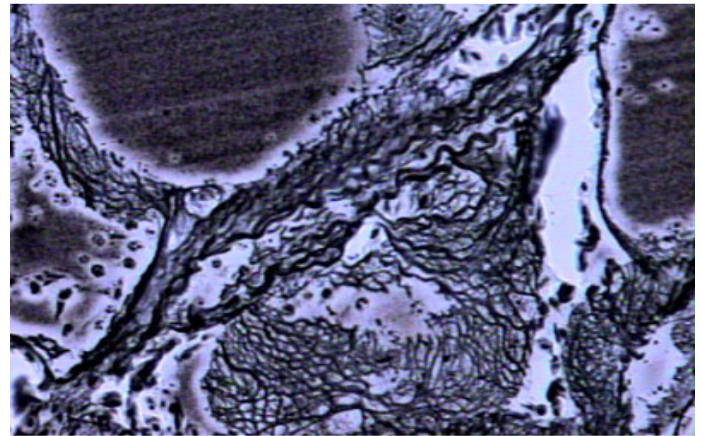


Figure 7. Reticular fibers are dominantly increased in the stroma (interfollicular space) of the thyroid in summer. Reticulin (×40).

No seasonal change was seen for parafollicular cells (C-cells). The results of microscopic examination showed that uniformity or nonuniformity of colloid is dependent on the secretory function of the gland, thus in active follicles in winter, the colloid contains large vacuoles and is nonuniformly stained (Figure 5); however, inactive follicles in summer, contain dense and uniformly stained colloid (Figure 6).

The reticular fibers were dominantly increased in summer in the stroma (Figures 7 and 8). According to Table 1, the determined mean of total follicles under a low power magnification (10×) in winter (122.98 ± 0.35) was significantly increased when compared with summer (53.96 ± 0.15) under the same power magnification ($P < 0.01$).

The mean of large and small follicles were also significantly increased in winter ($P < 0.01$). In this study, the large and small follicles were defined according to their approximate diameters in a microscopic low power field

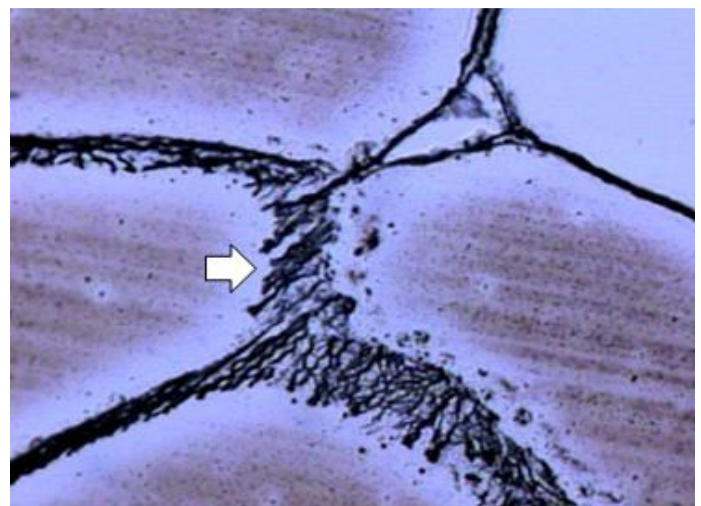


Figure 8. Reticular fibers are decreased in the stroma of the thyroid in winter. Reticulin (×40).

Table 1. Mean and standard error of the mean (SEM) of the measured characteristics in Ostrich thyroid in summer and winter.

Parameter	Mean±SEM		Significance level
	Summer	Winter	
Total follicles (×10)	53.96±0.15	122.98±0.35	0.000**
Large follicles (×10)	42.12±0.14	56.37±0.22	0.000**
Small follicles (×10)	11.72±0.13	66.44±0.23	0.000**
Active follicles (×20)	4.57±0.6	32.99±0.21	0.000**
Inactive follicles (×20)	24.62±0.15	5.35±0.5	0.000**

**Significance level: 0.01.

Table 2. Mean and standard error of the mean (SEM) of diameter and epithelium height of the follicles in ostrich thyroid in summer and winter.

Parameter	Mean±SEM		Significance level
	Summer	Winter	
Diameter of large follicles (×10)	493.2±3.2	275.15±1.6	0.000**
Diameter of small follicles (×10)	90.71±0.54	134.96±0.58	0.000**
Epithelium height of active follicles (×100)	4.959±0.027	6.952±0.052	0.000**
Epithelium height of inactive follicles (×100)	3.157±0.021	2.850±0.021	0.000**

**Significance level: 0.01.

Table 3. Correlation coefficient between the histometrical characteristics in ostrich thyroid in summer and winter.

Parameter	Correlation coefficient	Significance level
Number of large follicles & diameter of follicles	-0.869	0.000**
Number of small follicles & diameter of follicles	0.917	0.000**
Number of active follicles & height of epithelium	0.823	0.000**
Number of inactive follicles & height of epithelium	0.369	0.000**

**Significance level: 0.0.

(10×). Follicles larger than 174.24 µm in diameter arbitrarily were considered “large” and those below this were named “small” follicles. The mean number of active follicles in a low power magnification (20×) was significantly high in winter ($P < 0.01$). The diameters of different follicles in two seasons were measured and compared. To measure the diameters, we used an eyepiece graticule and a calibration slide.

A number of the largest and smallest follicles at a low power magnification (10×) were randomly chosen for measurement. The number of observed follicles in the microscopic fields was the same for the two groups of thyroids. The results are presented in Table 2.

The results showed that the mean diameter of large follicles is significantly increased in summer ($P < 0.01$), whereas the mean diameter of small follicles is significantly high in winter ($P < 0.01$).

The mean thickness of epithelium of active follicles in a high power magnification (100×) was significantly increased in winter (Table 2), whereas the mean thickness of

epithelium of inactive follicles was significantly higher in summer ($P < 0.01$). The significant correlation coefficients between the measured parameters were defined using the Pearson correlation coefficient (Table 3).

DISCUSSION

The histological and histometrical results of this study show that the ratio of parenchyma to stroma is significantly higher in winter, indicating that the ostrich thyroid gland is highly active in winter and inactive in summer in Tehran, Iran. Sheheta et al. (1998) reported that under the same dietary condition, the serum concentration of triiodothyronine (T_3) and thyroxine (T_4) is at highest level in winter and spring and the lowest in summer in Newzealand white rabbits.

Prakash and Rathor (1991) reported that the exposure of livestock in a farm to high environmental temperature, decreased the activity of the thyroid and consequently

thyroid hormones serum level was declined, whereas, the low temperatures caused the thyroid increased activity and the increased serum levels of hormones. The results of the present study shows that the cellular structure of thyroid follicles, their number and diameters, also the number of active and inactive follicles in different seasons change significantly and there is an increase in the number and diameter of active follicles in winter and vice versa in summer, indicating a more active thyroid. Tuckova et al. (1995) reported that in German shepherd and Dachshund dogs, the serum levels of T_3 and T_4 changed with season and they had the lowest levels in summer and the highest level of T_3 in winter and T_4 in autumn.

Birras (1981) reported that thyroid gland was significantly active in young red dears in winter when compared to old dears. The results of the present study shows that mean of total number follicles of ostrich thyroid occurs in winter and vice versa in summer, indicating that thyroid has a higher secretory function in winter. Counting the large and small follicles shows that their mean number is higher in winter ($P < 0.01$). These findings are in line with the reports of Joshi et al. (1975). They reported that the thyroid gland of pigs which were exposed to 18.5°C environmental temperature for 8 h a day contained more active follicles with vacuoles in colloid when compared to those exposed to 32.5°C.

Histometrical results of this study shows that the mean number of active follicles is significantly high in winter ($P < 0.01$) indicating that the thyroid gland is significantly active in winter. This is associated with higher serum levels of T_3 and T_4 in winter. Yousef (1985) reported T_3 and T_4 as two important metabolic factors which cause adaptations in domestic animals against environmental changes. Parkash and Rathor (1991) reported that serum levels of T_3 and T_4 in goats increase significantly from summer to winter. They believe that low environmental temperature may increase thyrotrophic hormone, resulting in increased serum levels of thyroid hormones. Christopherson et al. (1979) reported that cattle raised on open field had higher serum levels of T_4 in winter at the range of -40 to 5°C when compared with the group raised in 15.3°C.

The results of this study show that the mean diameter of large follicles is higher in summer than winter. Whereas, the mean diameter of small follicles is higher in summer indicating that thyroid is more active in winter. Regarding the fact that most of the thyroid follicles, as functional units of the gland, are active during winter, there is less variety in diameter of follicles. However, the variety in follicle diameter is dominant in summer due to inactivity of most of the follicles and the gland itself.

The histometrical results of the present study show that the mean thickness of the epithelium of the active thyroid follicles is higher in winter, whereas the mean thickness of the epithelium of inactive follicles is higher in summer. The increased epithelium height of follicles in winter implies

that the thyroid is more active in winter. These findings are in line with reports of Joshi et al. (1975). They showed that white Yourkshire piglets exposed to constant 18.5°C temperature had more active follicles in their thyroid when compared with those exposed to constant 32.5°C temperature. The first group also demonstrated increased epithelium with cuboidal or columnar cells.

The results of this study show that correlation coefficient between the active follicles and their epithelium height is significant. Follicular cells of active follicles become cuboidal or columnar in winter. Thus, the height of the epithelium of active follicles is associated with increase in active follicles number. No seasonal change was identified for parafollicular cells in this study.

According to Banks (1992) and Roberts (1974), the follicular colloid stained with H&E showed pink or red and it is PAS-positive because of its content of thyroglobulin, an iodinated glycoprotein, which is the storage form of thyroxin. The colloid stains basophilic in active follicles and contains vacuoles, whereas it stains eosinophilic for inactive follicles with no vacuoles or rare ones.

The results of the present study show that colloid color and vacuole existence is not the same in different seasons. The colloid contains more vacuoles in winter and it stains nonuniformly. Whereas, it stains uniformly in summer and usually lacks vacuoles. These findings are associated with the reports of Joshi et al. (1975) and Shehata et al. (1998).

Regarding the whole results of this study and the structural changes of thyroid tissue in summer and winter seasons, we concluded that farmed ostrich's thyroid gland is more active in winter than summer in Tehran, Iran.

ACKNOWLEDGMENTS

We are thankful to Dr. Mohebalipour for statistical analysis and M. Moini and G. qorbani for their assistance with sample taking. The authors also thank Mr. Eskandari for tissue processing procedure.

REFERENCES

- Astier H (1980). Thyroid gland in birds: Structure and function. *In* "Avian Endocrinology" (A. Epple and M. H. Stetson, eds.), Academic Press, New York. pp. 167-189.
- Banks WJ (1992). *Applied Veterinary Histology*. 3rd ed. Philadelphia, pp. 414-416.
- Birras G (1981). Histological and morphometric studies on the thyroid glands of roe deer (*capreolus capreolus*) and red deer (*cervus elaphus*) with special reference to the influence of age and season. Ferdinand Ende verlage, Stuttgart, German federal Republic, No: 7, *in* Vet. CD. p. 139
- Christopherson RJ, Gonyoy HW, Thompson JR (1979). Effects of temperature and feed intake on plasma concentration of thyroid hormones in beef cattle. *Canada, J. Anim. Sci.* 59: 655-669.
- Danforth E Jr, Burger A (1984). The role of thyroid hormones in the control of energy expenditure. *Clin. Endocrinol. Metab.* 13: 581-595.
- Decuypere E, Dewil E, Kuhn ER (1991). The hatching process and the role of hormones. *In* "Avian Incubation" (S. G. Tullett, ed.), Butterworth-Heinemann, London. pp. 239-256.

- Dent JN (1986). The thyroid gland. *In* "Vertebrate Endocrinology: Fundamentals and Biomedical Implications" (P. K. T. Pang and M. P. Schreibman, eds.), Academic Press, New York. 1: 175-206.
- French EI, Hodges RD (1977). Fine structural studies on the thyroid gland of the normal domestic fowl. *Cell Tissue Res.* 178: 397-410.
- Fujita H, Tanizawa Y (1966). Electron microscopic studies on the development of the thyroid gland of chick embryo. *Z. Zellforsch. Mikrosk. Anat.* 125: 132-151.
- Joshi BC, Sanwall PC, Agrawal KP (1975). Effect of cooling large White Yorkshire Piglets during summer season on the histological structure of their adrenal, thyroid and uterus. *Indian J. Anim. Sci.* 47(3): 134-144.
- McNabb FMA, King DB (1993). Thyroid hormone effects on growth, development and metabolism. *In* "The Endocrinology of Growth, Development, and Metabolism of Vertebrates" (M. P. Schreibman, C. G. Scanes, and P. K. T. Pang, eds.), Academic Press, New York. pp. 393-417.
- Prakash P, Rathor VS (1991). Seasonal variation in blood serum profile of triiodothyronine and thyroxin in goat. *Indian J. Anim. Sci.* 61(12): 1311-1312.
- Roberts PF (1974). Variation in the morphometry of the normal human thyroid in growth and gain. *J. Pathol.* 122: 161-197.
- Shehata AS, Sarhan M, El Gendy KM (1998). Digestibility thyroid function and Growth performance of Newzeland white rabbits as affected by season of the year and age. *Egypt. J. Rabbit Sci.* 8(2): 141-156.
- Sisson S, Grossman JD (1975). *The anatomy of the domestic animals.* 5th ed. Saunders, 2: 1965-1966.
- Tuckova M, Fialkovicova M, Baranova D, Bekeova E, Kozak M, Palenik L (1995). Effects of season on thyroid hormone concentrations in the blood serum of German Shepherds and Dachshunds and their health status. *Vet. Med.* 40(8): 249-252.
- Yousef MK (1985). *Stress physiology in livestock.* First ed. CRC prss, Inc. Boca Raton, Florida, 1: 4-17, 56-65, 68-74, 134-141.