

Misericordia University

Misericordia Digital Commons

Medical Imaging Senior Posters

Medical Imaging Department

2020

Diagnosis and Treatment of Peripheral Artery Disease (PAD) In Interventional Radiography

Evan Busher

bushere@misericordia.edu

Follow this and additional works at: https://digitalcommons.misericordia.edu/medimg_seniorposters




Part of the [Medicine and Health Sciences Commons](#)

Recommended Citation

Busher, Evan, "Diagnosis and Treatment of Peripheral Artery Disease (PAD) In Interventional Radiography" (2020). *Medical Imaging Senior Posters*. 10.

https://digitalcommons.misericordia.edu/medimg_seniorposters/10

This Poster is brought to you for free and open access by the Medical Imaging Department at Misericordia Digital Commons. It has been accepted for inclusion in Medical Imaging Senior Posters by an authorized administrator of Misericordia Digital Commons. For more information, please contact jluksa@misericordia.edu, mcech@misericordia.edu.



Diagnosis and Treatment of Peripheral Artery Disease (PAD)

In Interventional Radiography

Student Researcher: Evan Busher Faculty Advisor: Lynn Blazaskie M.S., R.T. (R)

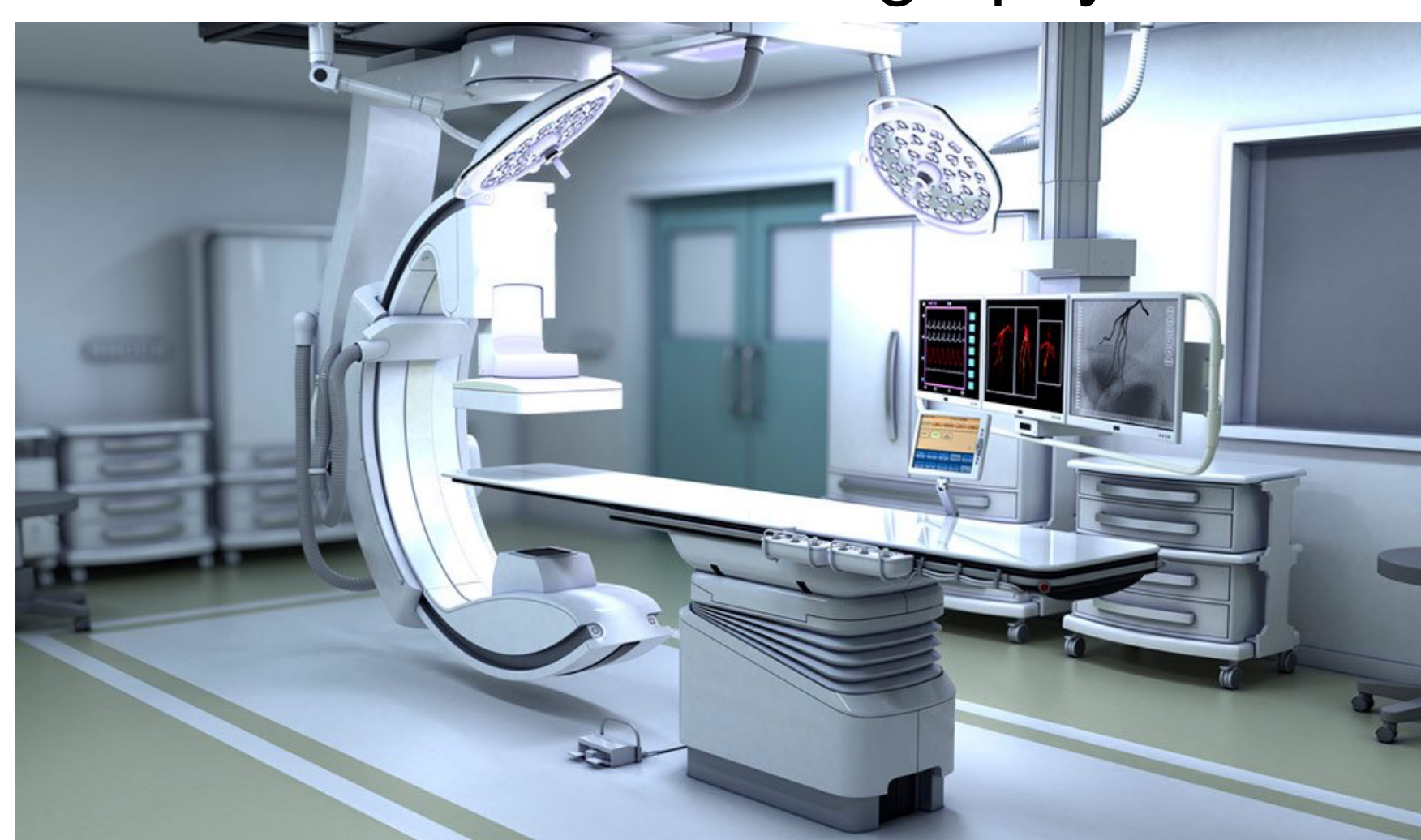Introduction

Peripheral Artery Disease (PAD) is a narrowing of the peripheral arteries which supply the legs, arms, and stomach with blood. This narrowing occurs due to atherosclerosis which is the buildup of plaque on the walls of the blood vessels. Atherosclerosis results in the restriction of blood flow to the desired site which is most often the legs for PAD.

Interventional Radiography

- Utilizes a wide range of techniques which depend on the use of medical imaging modalities such as fluoroscopy, ultrasound, computed tomography, or magnetic resonance imaging
- Minimally invasive alternatives to open surgery and involve the placement of coils, medications, filters, stents, or other devices to treat a particular problem or provide therapy (Long, Rollins, and Smith, 2019).
- Performed after noninvasive evaluation techniques when it is necessary to obtain information about the vascular system or to perform an interventional technique (Long et al., 2019).
- Common procedures include:
 - Angiogram
 - PICC Line
 - Arteriogram
 - Dialysis Catheter
 - Aortogram
 - Port-A-Cath
 - Angioplasty
 - Biopsies

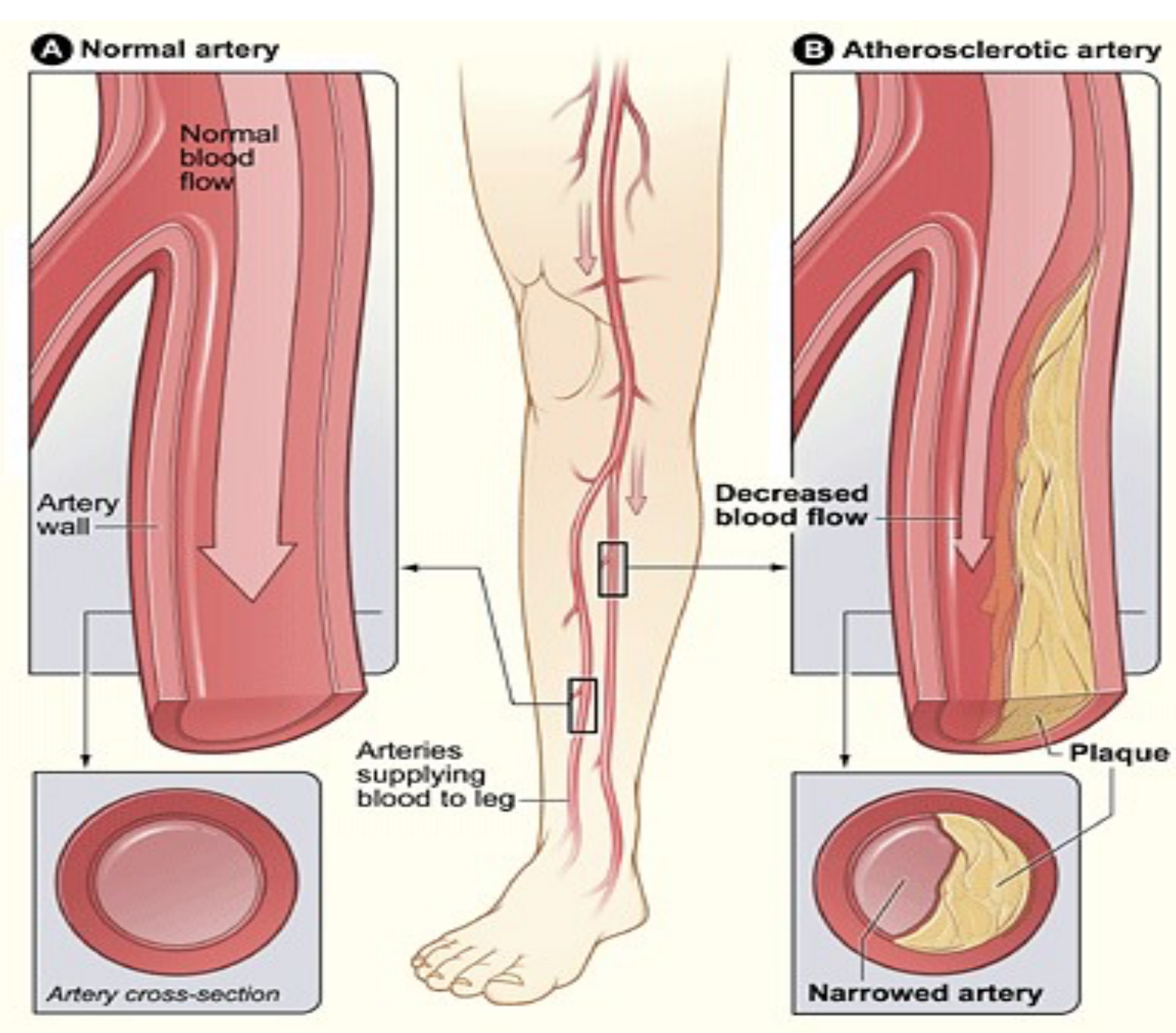
Interventional Radiography Suite



(Digirad, 2020)

Peripheral Artery Disease (PAD)

- Caused by atherosclerosis, or plaque buildup, that reduces the flow of blood in peripheral arteries
- These blood vessels carry blood away from the heart to other parts of the body such as extremities (NHLBI, 2020).
- Plaque is made up of fat, cholesterol, fibrous tissue, and calcium. Plaque may reduce or fully block the flow of oxygen-rich blood through arteries to the body's vital organs and the limbs. (NHLBI, 2020).



A. demonstrates a normal artery with normal blood flow. B. shows an artery with plaque buildup that is partially blocking blood flow. (NHLBI, 2020)

Risk Factors

- hypertension
- hyperlipidemia
- diabetes mellitus
- smoking
- chronic kidney disease (Firnhaber, 2019).

Symptoms

- Intermittent claudication is the hallmark of PAD and is defined as fatigue, discomfort, cramping, or pain in the calf muscles that is consistently induced by exercise and relieved within 10 minutes of rest (Firnhaber, 2019).
- Many will experience intermittent claudication, but some may experience no symptoms

Statistics

- PAD affects 12% to 20% of Americans 60 years and older, increasing to 50% in those 85 years and older (Firnhaber, 2019).
- 80% of patients with PAD were current or former smokers. (Firnhaber, 2019).
- The odds of having PAD are a 10-fold increase with three or more risk factors. (Firnhaber, 2019).

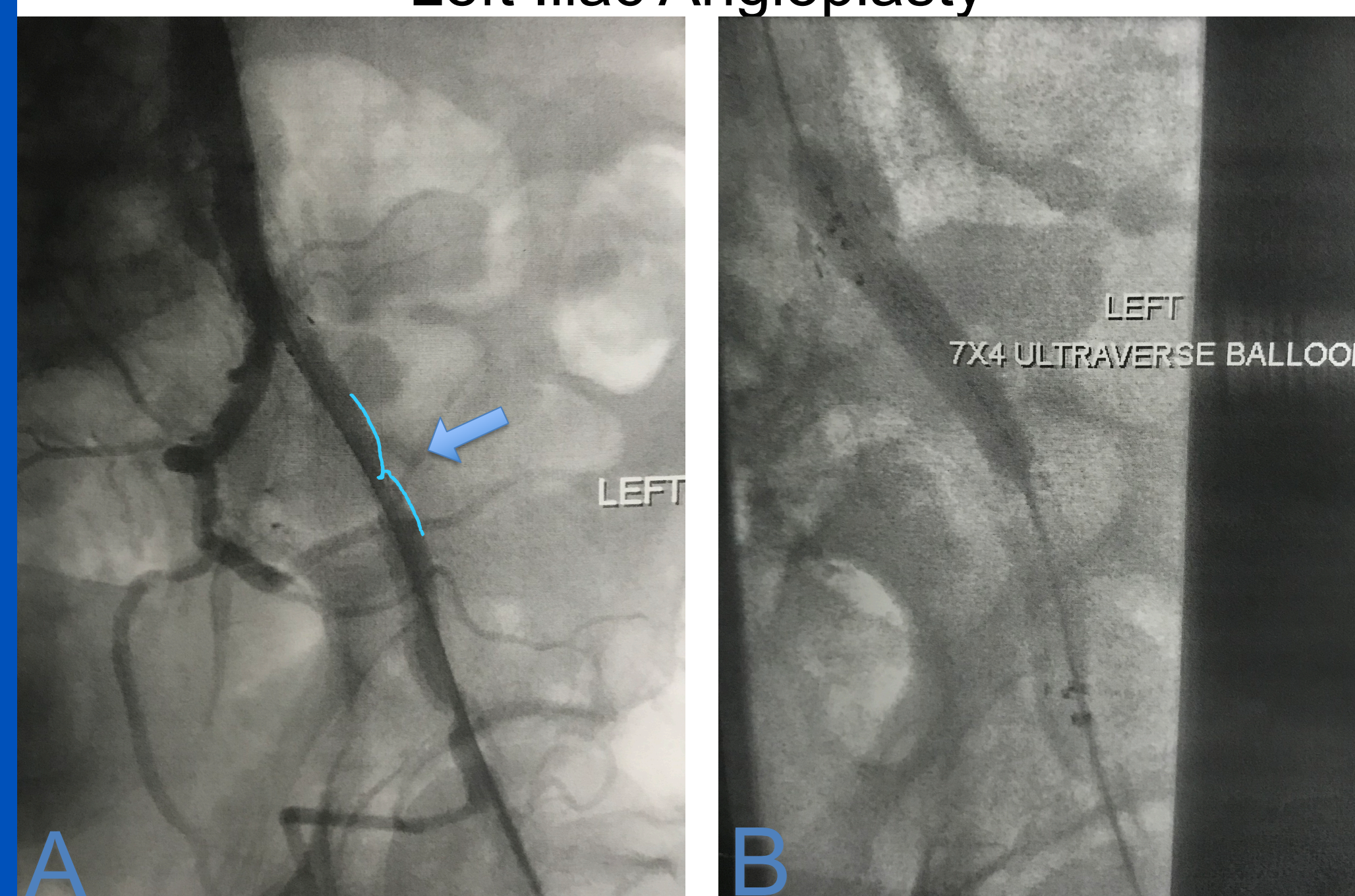
Diagnosis

- Testing involves ankle-brachial index (ABI) to determine if excess pressure builds up in the lower leg (Firnhaber, 2019).

Treatment

- Treatment options for PAD include:
 - physical therapy
 - statins
 - antiplatelet therapy
 - angiotensin blockers
 - Preventative medications (Firnhaber, 2019).
- Endovascular revascularization procedures were deemed appropriate in patients with asymptomatic PAD (Minkovich, Kuiper, Diaiani, 2019).
- A lower extremity angiogram through the femoral or iliac arteries is performed. Contrast is administered to identify areas that are blocked or narrowed.

Left Iliac Angioplasty

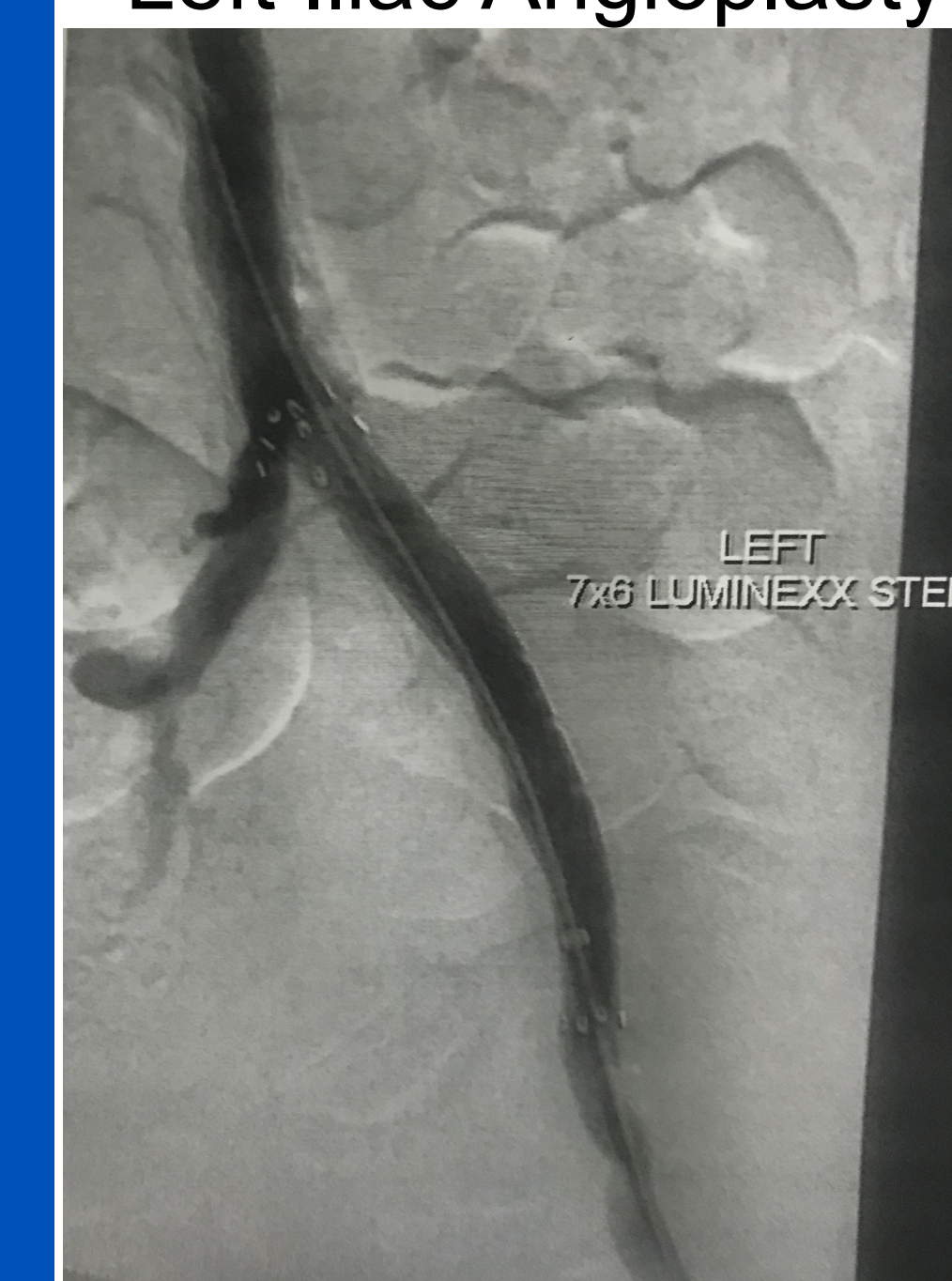

(Wilkes Barre General Hospital, 2020)

A. demonstrates stenosis in the left iliac artery before ballooning. B. demonstrates a balloon catheter fully dilated within the artery. (Wilkes Barre General Hospital, 2020)

- The artery is dilated with a balloon to flatten the plaque against the arterial wall preventing obstruction of blood flow.

Left Iliac Angioplasty



The image to the left shows the iliac artery after a stent has been placed and demonstrates how blood flow has been restored.

(Wilkes Barre General Hospital, 2020)

- A stent is placed to ensure the artery will stay unobstructed

Adverse Effects

- 10% of revascularized patients encounter Major Adverse Limb Events (MALE) and have an endovascular revascularization (Hess et al., 2018).
- The risks of MALE hospitalization include sex, race, insurance, diabetes, renal insufficiency, surgical revascularization, and acute limb ischemia and procedure factors which are singular to each patient (Hess et al., 2018).

Conclusion

Patients with Peripheral Artery Disease (PAD) may experience claudication or no symptoms at all. Symptomatic and asymptomatic patients have a high risk of cardiovascular events due to plaques within their vasculature. Through preventative measures, patients can continue and better their lives without pain, discomfort, and or worse loss of limb due to blocked vessels.