



Year: 2004

Decompressive craniotomy after middle cerebral artery infarction. Retrospective analysis of patients treated in three centres in Switzerland

Fandino, Javier ; Keller, Emanuela ; Barth, Alain ; Landolt, Hans ; Yonekawa, Yasuhiro ; Seiler, Rolf W

Abstract: QUESTIONS UNDER STUDY / PRINCIPLES Several studies have reported an improved outcome in patients presenting with complete middle cerebral artery (MCA) infarction treated by decompressive hemicraniectomy. Although this palliative treatment form has gained popularity in Switzerland since 2000, the results of these series have not been reported. The aim of this study is, firstly, to report factors influencing the outcome of our patients, in order to create awareness of the indications and decision-making processes in our departments, and, secondly, to analyse therapeutic strategies which are open to improvement and standardisation. METHODS This retrospective study included a total of 28 patients (age 51 +/- 12 years) who underwent decompressive craniectomy after MCA between January 2000 and May 2002 at the Departments of Neurosurgery of Aarau (n: 6), Bern (n: 10), and Zurich (n: 12). Demographic characteristics included preoperative clinical condition (NIHSS and GCS), timing of surgery, cause, location, and extension of infarction. Additionally, the time delay from the onset of symptoms to surgery and preoperative signs of herniation and their relation to final outcome was analysed. The final outcome was assessed in terms of mortality and scores such as modified Rankin scale and Barthel index. RESULTS The preoperative clinical condition according to NIHSS was 20.2 +/- 4.7 and GCS was 10.6 +/- 3.6. The mean time in hours to surgery after onset of symptoms was 35 +/- 24. Twelve patients (42.8%) underwent "early" surgery (within 24 hours) and 21 (75%) suffered non-dominant stroke. The follow-up period was 22 +/- 13 months and 17% of the patients died within this period. Outcome did not differ significantly between institutions. The overall mean Barthel index was 47 +/- 25 and modified Rankin scale was 4 +/- 1.3. CONCLUSIONS The outcome in patients undergoing decompressive craniectomy after MCA infarction in Switzerland is less favourable than in other series recently reported. Less favourable preoperative clinical condition, inclusion of dominant hemispheric infarction, poorly defined protocols and late involvement of neurosurgeons on these patients' admission may explain the results.

DOI: <https://doi.org/10.4414/smw.2004.10646>

Posted at the Zurich Open Repository and Archive, University of Zurich

ZORA URL: <https://doi.org/10.5167/uzh-192291>

Journal Article

Published Version



The following work is licensed under a Creative Commons: Attribution-NonCommercial-NoDerivatives 4.0 International (CC BY-NC-ND 4.0) License.

Originally published at:

Fandino, Javier; Keller, Emanuela; Barth, Alain; Landolt, Hans; Yonekawa, Yasuhiro; Seiler, Rolf W (2004). Decompressive craniotomy after middle cerebral artery infarction. Retrospective analysis of patients treated in three centres in Switzerland. *Swiss Medical Weekly*, 134(29-30):423-429.
DOI: <https://doi.org/10.4414/smw.2004.10646>

Decompressive craniectomy after middle cerebral artery infarction

Retrospective analysis of patients treated in three centres in Switzerland

Javier Fandino, Emanuela Keller, Alain Barth, Hans Landolt, Yasuhiro Yonekawa, Rolf W. Seiler

Departments of Neurosurgery, Kantonsspital Aarau, University Hospital Zürich, and University Hospital Bern, Switzerland

Summary

Questions under study/principles: Several studies have reported an improved outcome in patients presenting with complete middle cerebral artery (MCA) infarction treated by decompressive hemi-craniectomy. Although this palliative treatment form has gained popularity in Switzerland since 2000, the results of these series have not been reported. The aim of this study is, firstly, to report factors influencing the outcome of our patients, in order to create awareness of the indications and decision-making processes in our departments, and, secondly, to analyse therapeutic strategies which are open to improvement and standardisation.

Methods: This retrospective study included a total of 28 patients (age 51 ± 12 years) who underwent decompressive craniectomy after MCA between January 2000 and May 2002 at the Departments of Neurosurgery of Aarau (n: 6), Bern (n: 10), and Zurich (n: 12). Demographic characteristics included preoperative clinical condition (NIHSS and GCS), timing of surgery, cause, location, and extension of infarction. Additionally, the time delay from the onset of symptoms to surgery and preoperative signs of herniation and their re-

lation to final outcome was analysed. The final outcome was assessed in terms of mortality and scores such as modified Rankin scale and Barthel index.

Results: The preoperative clinical condition according to NIHSS was 20.2 ± 4.7 and GCS was 10.6 ± 3.6 . The mean time in hours to surgery after onset of symptoms was 35 ± 24 . Twelve patients (42.8%) underwent “early” surgery (within 24 hours) and 21 (75%) suffered non-dominant stroke. The follow-up period was 22 ± 13 months and 17% of the patients died within this period. Outcome did not differ significantly between institutions. The overall mean Barthel index was 47 ± 25 and modified Rankin scale was 4 ± 1.3 .

Conclusions: The outcome in patients undergoing decompressive craniectomy after MCA infarction in Switzerland is less favourable than in other series recently reported. Less favourable preoperative clinical condition, inclusion of dominant hemispheric infarction, poorly defined protocols and late involvement of neurosurgeons on these patients’ admission may explain the results.

Key words: cerebral infarction; brain oedema; craniectomy

Introduction

Stroke is the third cause of death and disability in industrialised countries [1]. In Switzerland, 150 per 100 000 population have a stroke in any year [2]. Moreover, 600–800 per 100 000 persons living in Switzerland have survived a stroke. Since stroke units are actively involved in the management of these patients in our country, the decision to treat has gained relevance in regard to direct and indirect costs as well as survivors’ quality of life. According to a recent study, 23% of stroke patients in Switzerland die and 44% need help or assistance in their daily activities [3].

Complete middle cerebral artery (MCA) infarction is a life-threatening condition and occurs

in up to 10% of all stroke patients [1]. “Malignant” MCA infarction is defined as an infarction of at least two thirds MCA territory upward [6]. These patients present clinically with severe hemispheric stroke syndrome, including hemiplegia, forced eye and head deviation, and progressive deterioration of consciousness within the first 2 days. Thereafter, symptoms of transtentorial herniation occur within 2–4 days of stroke onset. These patients’ prognosis is poor and mortality is as high as 80% [6, 7].

Conventional therapies for complete MCA infarction, such as mechanical ventilation, osmotherapy, hypothermia and barbiturate administra-

tion have a limited role in stroke patients developing intracranial hypertension [8–10]. Surgical decompression or so-called hemicraniectomy appears to reduce mortality in patients presenting with malignant MCA infarction to 20%, particularly in those undergoing the procedure within 24 hours of onset of symptoms [8]. Patients aged over 60 and patients with speech dominance on the infarcted cerebral hemisphere may have a poorer functional outcome [11]. Although this surgical

treatment form has gained popularity in Switzerland since 2000, the results and outcome have not yet been reported. The aim of this study is, firstly, to report factors influencing outcome in our patients, in order to create awareness of the indications and decision-making processes in our departments, and secondly, to analyse therapeutic strategies open to improvement and standardisation.

Clinical material and methods

Between January 2000 and May 2003, 28 patients underwent decompressive craniectomy at the Departments of Neurosurgery of the Kantonsspital Aarau (n: 6) and the University Hospitals of Bern (n: 10) and Zurich (n: 12). Since this study is based on a retrospective analysis of patients in three different institutions, no prospective protocol was applied. The criteria and timing of surgery were, therefore, different in each institution. Data sources included patients' hospital records, rehabilitation summaries, evaluation at outpatient clinics, and personal phone calls to patients or relatives. No exclusion criteria for surgery could be consistently elucidated in this retrospective study. All patients underwent cranial computerised tomography (CCT) immediately prior to surgery. Common criteria for surgery in all institutions included initial CCT findings consistent with a large or malignant MCA infarction (early large parenchymal hypodensity of more than two-thirds of the MCA territory and signs of

local brain swelling such as effacement of the sulci and compression of the lateral ventricle) [6] and deterioration of level of consciousness (LOC). Monitoring of intracranial pressure (ICP) was performed by infrared parenchymal catheter (Camino, Integra Life Science Corporation, Plainsboro, NJ, USA) or intracranial pneumatic transducer (Spiegelberg GmbH & Co, Hamburg, Germany). All patients were monitored and treated medically pre- and postoperatively at a neurocritical intensive care unit (NICU) until LOC improved or systemic life-threatening conditions stabilised. Medical treatment included fluid haemostasis with crystalloid and colloid fluids to ensure adequate cerebral perfusion, and standard antioedema treatment such as osmotherapy. Preoperative clinical evaluation included Glasgow Coma Scale (GCS) [12] and National Institute of Health Stroke Scale (NIHSS) [13].

Diagnostic workup of patients included ultrasound examination of the extracranial and intracranial vessels by

Table 1
Modified Rankin Scale [15, 16].

Activity	Score
Feeding	0 = unable 5 = needs help cutting, spreading butter, etc., or required notified diet 10 = incontinent
Bathing	0 = dependent 5 = independent (or in shower)
Grooming	0 = needs to help with personal care 5 = independent face/hair/teeth/shaving (implements provided)
Dressing	0 = dependent 5 = needs help but can do about half unaided 10 = independent (including buttons, zips, laces, etc.)
Bowels	0 = incontinent (or needs to be given enemas) 5 = occasional accident 10 = continent
Bladder	0 = incontinent, or catheterised and unable to manage alone 5 = occasional accident 10 = continent
Toilet Use	0 = dependent 5 = needs some help, but can do something alone 10 = independent (on and off, dressing, wiping)
Transfers (bed to chair and back)	0 = unable, no sitting balance 5 = major help (one or two people, physical), can sit 10 = minor help (verbal or physical) 15 = independent
Mobility (on level surfaces)	0 = immobile or < 50 yards 5 = wheelchair independent, including corners, >50 yards 10 = walks with help of one person (verbal or physical) > 50 yards 15 = independent (but may use any aid; for example, stick) > 50 yards
Stairs	0 = unable 5 = needs help (verbal, physical, carrying aid) 10 = independent
TOTAL	0–100

Table 2
Barthel Index
[17, 18].

Score	Description
0	No symptoms at all
1	No significant disability despite symptoms; able to carry out all usual duties and activities
2	Slight disability; unable to carry out all previous activities, but able to look after own affairs
3	Moderate disability; requiring some help, but able to walk without assistance
4	Moderate severe disability; unable to walk without assistance and unable to attend to own bodily needs without assistance
5	Severe disability; bedridden, incontinent and requiring constant nursing care and attention
6	Dead

Table 3
Demographic characteristics of 28 patients undergoing decompressive craniectomy after cerebral infarction in Aarau, Bern, and Zurich.
Abbreviations: SD: standard deviation, F/U: follow-up, GCS: Glasgow Coma Score (12), NIHSS: National Institutes of Health Stroke Scale (13), NCCU: Neurocritical care unit.

	Zurich	Bern	Aarau	Total
n (%)	12 (42%)	10 (35%)	6 (21%)	28 (100%)
Gender (male patients)	9 (75%)	8 (80%)	4 (66%)	21 (75%)
Age (mean \pm SD)	52 \pm 13	48 \pm 9	53 \pm 13	51 \pm 12
F/U months (mean \pm SD)	24 \pm 11	21 \pm 15	19 \pm 11	22 \pm 13
GCS (mean \pm SD)	12.4 \pm 3	8.7 \pm 3.8	10 \pm 2	10.6 \pm 3.6
NIHSS (mean \pm SD)	17.2 \pm 4.2	22.5 \pm 4.7	22 \pm 2	20.2 \pm 4.7
Time (hours) to surgery (mean \pm SD)	34 \pm 25	30 \pm 23	46 \pm 22	35 \pm 24
NCCU days (mean \pm SD)	15 \pm 9	5 \pm 2	10 \pm 3	10.5 \pm 8.1
Hospital days (mean \pm SD)	43 \pm 24	15 \pm 8	23 \pm 10	26 \pm 19
Barthel index (mean \pm SD)	46 \pm 25	47 \pm 26	48 \pm 22	47 \pm 25
Modified Rankin scale (mean \pm SD)	3.7 \pm 1.1	4.3 \pm 1.4	4.1 \pm 1.1	4.0 \pm 1.3
Mortality (%)	1 (8.3%)	3 (27%)	1 (16%)	5 (17%)
Timing (% early)	5 (41%)	6 (60%)	2 (33%)	13 (46%)
Nondominant craniectomy (%)	11 (91.6%)	6 (60%)	4 (66%)	21 (75%)

Doppler sonography, magnetic resonance imaging (MR), MR angiography and/or digital subtraction cerebral angiography (DSA), and haematological tests. If documented preoperatively, oral anticoagulation was reverted using vitamin K, fresh frozen plasma, or human prothrombin complex if necessary. Thrombolysis was attempted systemically or intra-arterially according to standard guidelines [10, 14]. Potential risks and benefits of surgical decompression were discussed with the patients or their families. Decompressive craniectomy was defined as "early" if performed within 24 hours of symptom onset and "late" if performed after 24 hours [8]. The surgical technique of decompressive hemicraniectomy has been described elsewhere [8]. At surgery, a bone flap with a diameter of at least 12 centimeters was performed including

the frontal, parietal, temporal, and parts of the occipital squamae. After dura incision, a dural patch was applied to allow adequate brain relaxation. The bone was removed and stored frozen until reimplantation 3–6 months later. Resection of infarcted tissue was considered as an adjuvant surgical procedure only in patients treated in Zurich. Post-operatively patients were kept intubated and mechanically ventilated, and were transferred to the NICU until extubation and stabilisation of the neurological condition. Most patients were transferred to a normal ward until rehabilitation was initiated. Clinical outcome was assessed by the modified Rankin scale (RS) (table 2) [15, 16] and Barthel index (BI) (table 1) [17, 18].

All values are expressed as mean \pm SD. Data shown in table 3 were not intended for statistical analysis.

Results

A total of 28 consecutive patients (7 women and 21 men) who underwent decompressive craniectomy in the three institutions were included in this study (table 3). The mean age of the patients was 51 \pm 12 (range 34 to 72 years). In all patients at least two thirds of the MCA territory infarction was infarcted preoperatively. Additionally, 7 patients (25%) presented with hypodensity in the anterior cerebral artery (ACA) territory documented in CCT prior to surgery. Interestingly, the latter was not considered as a preoperative diagnosis in 4 of the 7 patients. Twenty-one patients (75%) undergoing surgery had a cerebral infarc-

tion in the nondominant hemisphere. As part of preoperative workup Doppler sonography was performed in 19 patients (67.8%), MR angiography in 22 (78%) and DSA in 7 (25%). Two patients (7%) underwent surgery without preoperative neurovascular assessment. Thrombolysis was attempted systemically in 6 patients (21.4%) and intra-arterially in 4 (14.2%). Eighteen patients (64.2%) did not fulfill the criteria for thrombolysis according to standard therapy guidelines [10, 19]. No patient undergoing systemic thrombolysis improved clinically or showed radiological signs of revascularisation. Among the 4 patients who un-

derwent intra-arterial thrombolysis, signs of partial revascularisation in MCA branches could be documented only in 3 cases. Nevertheless, these patients did not improve clinically and remained with an impaired LOC. One patient experienced aggravation of the infarction as a complication of DSA. Only one patient who underwent systemic thrombolysis developed secondary haemorrhagic infarction in the basal ganglia. Stroke aetiology was cardioembolic in 20 patients (71.4%) and internal carotid artery (ICA) dissection with secondary MCA embolisation in 7 (25%). One patient suffered stroke during coronary angiography. Additional possible causes included atlantoaxial rotatory subluxation in one patient and thrombocytosis in one.

The mean time between onset of symptoms and surgery was 35 ± 24 h (range 8 to 93). The differences in demographic characteristics and surgical features between the three institutions are shown in table 3. The immediate preoperative clinical condition assessed in terms of GCS and NIHSS was 10.6 ± 3.6 and 20.2 ± 4.7 respectively. Patients treated in Bern had a lower GCS than those treated in Zurich and Aarau. In terms of NIHSS, patients operated on in Zurich presented a better preoperative clinical condition (17.2 ± 4.2) than those treated in Bern and Aarau (22.5 ± 4.7 and 22 ± 2 respectively), as shown in table 3. Seventeen patients (60.7%) presented radiological or clinical signs of herniation prior to decompression. Early decompression was performed in 13 (46%) of the patients. In 9 patients (32%) additional resection of infarcted cerebral tissue was performed during the same surgical procedure (3 patients), on day 1 (3 patients), on day 2 (1 patient) or after day 2 post surgery in 3 patients. One patient underwent resection of infarcted tissue twice (during

same procedure and on day 11). Three patients (10.7%) underwent enlargement of the initial craniectomy. The mean total postoperative time spent at the NICU was 10.5 ± 8.1 days (range 3–27) and the mean duration of hospitalisation until transfer to a rehabilitation centre was 26 ± 19 days (range 3–72). In Bern the patients remained less long in the NICU since they were transferred to an intermediate care unit immediately after extubation. ICP was monitored in 18 patients (64.2%). Four patients (14.2%) underwent ICP monitoring preoperatively.

Five of 28 patients died despite aggressive medical management and surgical decompression (overall mortality 17%). The cause of death in all cases was intractable intracranial pressure due to infarction progression. Outcome was assessed after a follow-up period of 22 ± 13 months. The mean BI was 47 ± 25 and the RS was 4 ± 1.3 . The patients' outcome was similar in the three centres (table 3). No better outcome was observed in patients operated on within 24 hours of onset of symptoms, though lower mortality was observed in this group. The mean BI in the group of patients operated on "early" was 41 (mortality 7%) and in patients who underwent "late" decompression 54 (mortality 28%). Six patients (21%) were diagnosed with reactive depression. The overall incidence of surgical complications with the procedure was 25%. In 5 patients (17.8%) a postoperative infection was diagnosed (meningitis 3, epidural abscess 1, cerebral abscess 1). In two patients postoperative haematomas were diagnosed (epidural 1, subdural 1) and evacuated. Finally, 5 patients (17.8%) underwent ventriculoperitoneal shunting after communicating hydrocephalus was confirmed as a cause of neurological deterioration.

Discussion

This retrospective analysis of patients undergoing decompressive craniectomy after malignant MCA infarction shows a similar reduction in mortality but a poorer outcome in terms of patients' performance and independence in daily activities [8]. Although a greater reduction in mortality of up to 17% is achieved in patients operated on "early" compared with those operated on "late" (28%), the timing of the procedure did not influence the outcome in terms of BI (table 2). Schwab et al. recently reported higher BI in patients undergoing early craniectomy than in patients operated on after 24 hours (62.6 and 68.8 respectively). However, in the Heidelberg series only patients with nondominant hemispheric infarction were treated surgically. The same authors reported mortality of 13% in patients operated on early compared with 34.4% in those operated on later than 24 hours after symptom onset [8]. Although decompression craniectomy reduces mortality in

patients with complete MCA infarction, no significant improvement in patients' performance and independence in terms of BI could be demonstrated [8]. The mean BI score in patients who survived the natural history of the disease was reported to be 60 [6]. The fact that the mean BI in our series tended to be lower than the reported natural history of the disease (47 ± 25) may be explicable by patient selection criteria and poor preoperative condition. Review of the records of the cases presented in this study shows that preoperative re-evaluation of the clinical condition in terms of NIHSS or GCS was frequently not sufficiently documented and in most of the cases had to be inferred from the surgeons' operation reports or from nurses' evaluations. Inclusion of the neurosurgeon in the stroke team's discussion of the case immediately after the patient's admission could prevent surgical complications such as postoperative haematoma. The decision to treat with aspirin,

Table 4

Clinical studies and case reports of decompressive craniectomy after hemispheric space-occupying cerebral infarction [19].

Author	Year	No. of patients	Survivors	Non-survivors	Independent or moderate disability	Severe disability
Greco [22]	1935	1	–	1	–	–
King [23]	1951	1	–	1	–	–
Schneider and Lemmen [24]	1952	1	–	1	–	–
Scarcella [25]	1956	6	2	4	2	–
Greenwood Group I* [26]	1968	9	6	3	3	3
Greenwood Group II† [26]	1968	6	4	2	3	1
Kjellberg and Prieto [27]	1971	1	–	1	–	–
Ivamoto et al. [28]	1974	1	1	–	1	–
Rengachary et al. [29]	1981	3	3	–	1	2
Young et al. [30]	1982	1	1	–	1	–
Saito et al. [31]	1987	7	4	3	–	4
Ojemann et al. [32]	1988	2	2	–	2	–
Kondziolka and Fazl [33]	1988	5	5	–	5	–
Delashaw et al. [34]	1990	9	8	1	4	4
Steiger [35]	1991	8	6	2	4	2
Tsuruno et al. [36]	1993	14	9	5	6	3
Kalia et al. [37]	1993	4	4	–	4	–
Rieke et al. [38]	1995	32	21	11	16	5
Schwab et al.‡ [8]	1998	63	47	16	47	–
Georgiadis et al. [9]	2002	17	15	2	N/A	N/A
Present series°	2003	28	23	5	9	14
Total		219	161	58	108	38
			(73.5%)	(26.4%)	(74.2%)	(18.8%)

* In these cases, cerebral infarction was diagnosed before surgery;

† In these cases, a mass lesion was diagnosed preoperatively and infarction was unlikely or unsuspected. However, cerebral infarction demonstrated in pathology. In this group, two cases must be excluded because the infarction included the posterior circulation (cases 1 and 3);

‡ In this study early and late surgery were compared (mean Barthel index: early surgery 68.8, late surgery: 62.6, $p = 006$, mortality: early surgery: 16%, late surgery: 34.4%);

° mean follow-up: 22 ±13

N/A: not available

which is often taken immediately after admission in patients with signs of a malignant MCA infarction, should be avoided or discussed prior to surgery. In the series analysed in this study, optimisation of coagulation and interruption of treatment with aspirin was instituted late, after the decision for surgery. Thus the incidence of complications due to these preventable factors should not be underestimated.

Indications for surgery in the management of occlusive cerebrovascular disease have continued to evolve since the first reported series of decompressive craniectomy for massive intractable cerebral swelling and herniation in 1935. Table 4 summarises the worldwide case reports and clinical studies in hemispheric space-occupying cerebral infarction. A total of 219 patients who underwent this procedure have been reported. Only two open studies have compared surgical therapy with the natural history of the disease [8] or other forms of therapy such as hypothermia [9]. Our series is retrospective and included three centres in Switzerland in which no standardised protocols exist. Despite the fact that stroke teams exist and are well defined in Switzerland, neurosurgeons are frequently not involved on the patients' admission

and thereafter take no part in the discussion of alternative procedures such as ICP monitoring or early surgical decompression.

The high incidence of surgical complications in this series (up to 25%) deserves analysis. All 5 patients (17.8%) who developed an infection, viz. meningitis, cerebritis or epidural abscess, underwent resection of infarcted tissue in a second procedure or were treated by additional barbiturate coma (n: 1). From the surgical viewpoint sufficient osseous decompression with a generous dural patch obviates the need for further decompression or resection of necrotised space-occupying tissue and the consequent increased infection risk. The technical aspects of "a simple craniectomy" should not be underestimated in the neurosurgical team and must be under the control of an experienced neurosurgeon.

Finally, the incidence of hydrocephalus in stroke patients who undergo decompressive craniectomy has not been discussed in the literature. In our series, 17.8% of the patients developed hydrocephalus and required a ventriculoperitoneal shunt. This high incidence of hydrocephalus, which is similar to the rates of shunt dependence after subarachnoid haemorrhage [20, 21], must be considered in these patients' follow-up and ruled

out if neurological improvement is observed to stagnate.

In conclusion, the outcome of patients undergoing decompressive craniectomy after MCA infarction in Switzerland is less favourable than that in other series recently reported. A less favourable preoperative clinical condition, the inclusion of

dominant hemispheric infarctions, poorly defined protocols and late involvement of neurosurgeons on admission of these patients may account for these results. Analysis of the results presented makes it possible to propose a standardised protocol for the treatment of these patients and the design of a controlled study within our institutions.

Protocol proposal for surgical treatment after complete middle cerebral infarction

1. CT or MRI evidence of complete MCA infarction consisting of an early, large parenchymal hypodensity of at least 50% of the MCA territory with signs of brain swelling and space-occupying lesion.
2. Age < 60 years.
3. Surgery within the first 24 hours of stroke onset or less than 48 hours if no occurrence of signs of herniation.
4. Monitoring of intracranial pressure (ICP) should be considered in sedated patients or cases in which neurological assessment is difficult. Elevation of ICP above 20 mm Hg should be considered a criterion for decompressive craniectomy.
5. Early involvement of the neurosurgeon as an active member of the stroke team, in order to discuss the indication, prepare an optimal environment for surgery, discuss the surgical risks, and obtain informed consent from the patient's relatives. The neurosurgical team and intensive care specialists must bear in mind the possibility of emergency craniotomy to prevent delays due to scheduled surgeries.
6. The wish of the family for active treatment and postoperative care of a possibly disabled patient.
7. No contraindication for surgery such as anti-coagulation, recent myocardial infarction, or preoperative high dose aspirin. Assessment by anaesthesiologists is mandatory.

Correspondence:

Javier Fandino, MD

Department of Neurosurgery

University Hospital Bern

3010 Bern

Switzerland

References

- 1 World Health O. The World Health Report 2002. Geneva: World Health Organization, 2002.
- 2 Mattle H, Hennerici M. Zerebrale Ischämien. *Ther Umschau* 2003;60:497–498.
- 3 Mattle H, Eicher Vella E, Bassetti C, Sandercock P. International Stroke Trial Switzerland – Einige epidemiologische Daten. *Schweiz. Med. Wschr* 1999;129:1964–9.
- 4 Moulin D, Lo R, Chiang J, Barnett H. Prognosis in middle cerebral artery occlusion. *Stroke* 1985;16:282–284.
- 5 Silver F, Norris J, Lewis A, Hachinski V. Early mortality following stroke: a prospective review. *Stroke* 1984;15.
- 6 Hacke W, Schwab S, Horn M, Spranger M, De Georgia M, von Kummer R. Malignant middle cerebral artery territory infarction: clinical course and prognostic signs. *Arch Neurol* 1996; 53:309–315.
- 7 Ropper A, Shafran B. Brain edema after stroke: clinical syndrome and intracranial pressure. *Arch Neurol* 1984;41:26–29.
- 8 Schwab S, Steiner T, Aschoff A, et al. Early hemicraniectomy in patients with complete middle cerebral artery infarction. *Stroke* 1998;29:1888–93.
- 9 Georgiadis D, Schwarz S, Aschoff A, Schwab S. Hemicraniectomy and moderate hypothermia in patients with severe ischemic stroke. *Stroke* 2002;33:1584–1588.
- 10 Georgiadis D, Michel P, Bogousslavsky J, Baumgartner R. Behandlung des akuten Hirninfarktes. *Ther Umschau* 2003;60: 509–520.
- 11 Holtkamp M, Buchheim K, Unterberg A, et al. Hemicraniectomy in elderly patients with space occupying media infarction: improved survival but poor functional outcome. *J Neurol Neurosurg Psychiatry* 2001;70:226–8.
- 12 Jennet B, Teasdale G. Aspects of outcome after severe head injury. *Lancet* 1977;23:878–881.
- 13 Brott T, Adams H, Olinger C, et al. Measurement of acute cerebral infarction: a clinical examination scale. *Stroke* 1989;20: 864–870.
- 14 Arnold M, Schroth G, Nedeltchev K, et al. Intra-arterial thrombolysis in 100 patients with acute stroke due to middle cerebral artery occlusion. *Stroke* 2002;33:1828–1833.
- 15 Bonita R, Beaglehole R. Modification of Rankin Scale: recovery of motor function after stroke. *Stroke* 1988;19:1497–1500.
- 16 Rankin J. Cerebral vascular accidents in patients over the age of 60. *Scott Med J* 1957;2:200–15.
- 17 Lowen S, Anderson B. Predictors of stroke outcome using objective measurement scales. *Stroke* 1990;21:78–81.
- 18 Mahoney F, Barthel D. Functional evaluation: the Barthel index. *Maryland State Med J* 1965;14:56–61.
- 19 Steiner T, Ringleb P, Hacke W. Treatment options for large hemispheric stroke. *Neurology* 2001;57:S61–S68.
- 20 Auer L, Mokry M. Disturbed cerebrospinal fluid circulation after subarachnoid hemorrhage and acute aneurysm surgery. *Neurosurgery* 1990;26:804–809.
- 21 Yasargil M, Yonekawa Y, Zumstein B, Stahl H. Hydrocephalus following spontaneous subarachnoid hemorrhage. Clinical features and treatment. *J Neurosurg* 1973;39:474–9.
- 22 Greco T. Le trombosi post-traumatiche della carotide. *Arch Ital Chir* 1935;39:757–784.
- 23 King A. Massive cerebral infarction producing ventriculographic changes suggesting a brain tumor. *J Neurosurg* 1951;8: 536–539.
- 24 Schneider R, Lemmen L. Traumatic internal carotid artery thrombosis secondary to non-penetrating injuries of the neck: a problem in the differential diagnosis of craniocerebral trauma. *J Neurosurg* 1952;9:495–507.

- 25 Scarcella G. Encephalomalacia simulating the clinical and radiological aspects of brain tumors: a report of six cases. *J Neurosurg* 1956;13:366-380.
- 26 Greenwood J. Acute brain infarctions with high intracranial pressure: surgical indications. *Johns Hopkins Med J* 1968;122:254-260.
- 27 Kjellberg R, Prieto A. Bifrontal decompressive craniectomy for massive cerebral edema. *Neurosurgery* 1971;34:488-493.
- 28 Ivamoto H, Numoto M, Donaghy R. Surgical decompression for cerebral and cerebellar infarcts. *Stroke* 1974;5:365-370.
- 29 Rengachary S, Batnitzky S, Morantz R, Arjunan K, Jeffries B. Hemicraniectomy for acute massive cerebral infarction. *Neurosurgery* 1981;8:321-328.
- 30 Young P, Smith K, Dunn R. Surgical decompression after cerebral hemispheric stroke: indication and patient selection. *South Med J* 1982;75:473-475.
- 31 Saito I, Segawa H, Shiokawa Y, Taniguchi M, Tsutsumi K. Middle cerebral artery occlusion: correlation of computed tomography and angiography with clinical outcome. *Stroke* 1987;18:863-868.
- 32 Ojemann R, Heros R, Crowell RM. *Surgical management of cerebrovascular disease*. Baltimore: Williams & Wilkins, 1988.
- 33 Kondziolka D, Fazl M. Functional recovery after decompressive craniectomy for cerebral infarction. *Neurosurgery* 1988;23:143-7.
- 34 Delashaw J, Broaddus W, Kassell N, et al. Treatment of right hemispheric cerebral infarction by hemicraniectomy. *Stroke* 1990;21:874-881.
- 35 Steiger HJ. Outcome of acute supratentorial cerebral infarction in patients under 60. Development of a prognostic grading system. *Acta Neurochir (Wien)* 1991;111:73-9.
- 36 Tsuruno T, Takeda M, Imaizumi T, Tannoka A. Internal decompression with hippocampectomy for massive cerebral infarction. *No Shinkei Geka* 1993;21:823-827.
- 37 Kalia K, Yonas H. An aggressive approach to massive middle cerebral artery infarct. *Arch Neurol* 1993;50:1293-1297.
- 38 Rieke K, Schwab S, Krieger D, et al. Decompressive surgery in space-occupying hemispheric infarction: results of an open, prospective trial. *Crit Care Med* 1995;23:1576-1587.

The many reasons why you should choose SMW to publish your research

What Swiss Medical Weekly has to offer:

- SMW's impact factor has been steadily rising, to the current 1.537
- Open access to the publication via the Internet, therefore wide audience and impact
- Rapid listing in Medline
- LinkOut-button from PubMed with link to the full text website <http://www.smw.ch> (direct link from each SMW record in PubMed)
- No-nonsense submission – you submit a single copy of your manuscript by e-mail attachment
- Peer review based on a broad spectrum of international academic referees
- Assistance of our professional statistician for every article with statistical analyses
- Fast peer review, by e-mail exchange with the referees
- Prompt decisions based on weekly conferences of the Editorial Board
- Prompt notification on the status of your manuscript by e-mail
- Professional English copy editing
- No page charges and attractive colour offprints at no extra cost

Editorial Board

Prof. Jean-Michel Dayer, Geneva
 Prof. Peter Gehr, Berne
 Prof. André P. Perruchoud, Basel
 Prof. Andreas Schaffner, Zurich
 (Editor in chief)
 Prof. Werner Straub, Berne
 Prof. Ludwig von Segesser, Lausanne

International Advisory Committee

Prof. K. E. Juhani Airaksinen, Turku, Finland
 Prof. Anthony Bayes de Luna, Barcelona, Spain
 Prof. Hubert E. Blum, Freiburg, Germany
 Prof. Walter E. Haefeli, Heidelberg, Germany
 Prof. Nino Kuenzli, Los Angeles, USA
 Prof. René Lutter, Amsterdam,
 The Netherlands
 Prof. Claude Martin, Marseille, France
 Prof. Josef Patsch, Innsbruck, Austria
 Prof. Luigi Tavazzi, Pavia, Italy

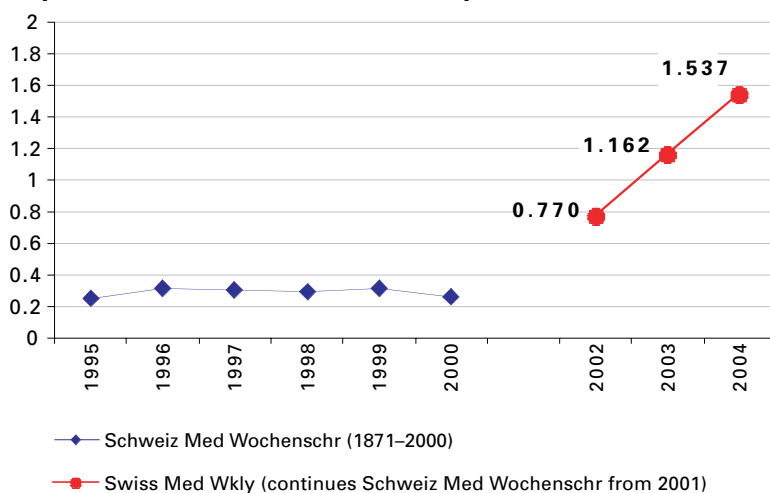
We evaluate manuscripts of broad clinical interest from all specialities, including experimental medicine and clinical investigation.

We look forward to receiving your paper!

Guidelines for authors:

http://www.smw.ch/set_authors.html

Impact factor Swiss Medical Weekly



All manuscripts should be sent in electronic form, to:

EMH Swiss Medical Publishers Ltd.
 SMW Editorial Secretariat
 Farnsburgerstrasse 8
 CH-4132 Muttenz

Manuscripts: submission@smw.ch
 Letters to the editor: letters@smw.ch
 Editorial Board: red@smw.ch
 Internet: <http://www.smw.ch>