

Original Research Article

Protective effect of *Pisonia aculeata* on Rifampicin and Isoniazid induced hepatotoxicity in rats

C. Anbarasu^{1*}, B. Rajkapoor², J. Kalpana³

*Corresponding author:

C. Anbarasu

¹Department of Pharmacology, Karpagam university, Eachanari Post-641 021, Coimbatore, Tamil Nadu, India.

anbukings@gmail.com

²Department of

Pharmacology, Dayananda Sagar College of Pharmacy, Bangalore- 560 078, India.

³Department of Chemistry, The Oxford College of Pharmacy, Bangalore- 560 068, India.

Abstract

Pisonia aculeata is traditionally used in treatment of liver disorder and thought to have a protective effect which may be beneficial to reduce symptoms of hepatotoxicity. The current study aimed to evaluate the scientific merit of these anecdotal claims in an in vivo model. Methanolic extract of leaves of *Pisonia aculeata* (250 and 500 mg/kg, p.o.) showed a remarkable hepatoprotective and antioxidant activity against Rifampicin and Isoniazid induced hepatotoxicity as judged from the serum marker enzymes and antioxidant levels in liver tissues. Acetaminophen induced a significant rise in aspartate amino transferase (AST), alanine amino transferase (ALT), alkaline phosphatase (ALP), total bilirubin, gamma glutamate transpeptidase (GGTP), lipid peroxidase (LPO) with a reduction of total protein, superoxide dismutase (SOD), catalase, glutathione peroxidase (GPx), reduced glutathione (GSH), Glutathione reductase (GR), Vitamin C and E. Treatment of rats with different doses of plant extract (200 and 300 mg/kg) significantly ($P < 0.001$) altered serum marker enzymes and antioxidant levels to near normal against acetaminophen treated rats. Also the extract was effectively altered the drug metabolizing enzymes such as Cytochrome P450, NADPH Cytochrome C reductase and glutathione S transferase. The activity of the extract at dose of 500 mg/kg was comparable to the standard drug, silymarin (50 mg/kg, p.o.). Histopathological changes of liver sample were compared with respective control. Results indicate the hepatoprotective and antioxidant properties of *Pisonia aculeata* against rifampicin and isoniazid -induced hepatotoxicity in rats.

Keywords: *Pisonia aculeata*; Rifampicin; Isoniazid; Biochemical parameters; Antioxidants; Lipid peroxidation; Histopathology.

Introduction

Herbal medicines have recently attracted much attention as alternative medicines useful for treating or preventing life style related disorders and relatively very little knowledge is available about their mode of action. There has been a growing interest in the analysis of plant products which has

stimulated intense research on their potential health benefits (1). Liver, the key organ of metabolism and excretion has an immense task of detoxification of xenobiotics, environmental pollutants and chemotherapeutic agents. Hence, this organ is subjected to variety of diseases and

disorders. Several hundred plants have been examined for use in a wide variety of liver disorders. Antioxidants play an important role in inhibiting and scavenging free radicals and thus providing protection against infections and degenerative diseases (2).

Pisonia aculeata (Nyctaginaceae) is nearly pantropical, found throughout the new world tropics and is considered introduced in Africa, Asia, and the Phillipines (3). *Pisonia aculeata* is a large scandent shrub distributed throughout India. The leaves and bark are used by the tribes and native medical practitioners to treat various ailments including liver disorders, inflammation, swelling, cough and tumours (4). Preliminary phytochemical screening of the extracts reveals the presence of alkaloids, phenolic compounds, tannins, saponins and flavonoids. Hence, the present study is aimed to evaluate the hepatoprotective and antioxidant activity of methanol extract of the leaves of *Pisonia aculeata* against rifampicin and isoniazid (RCIN and INH) induced hepatotoxicity in rats.

Materials and Methods

Plant material and extraction:

The plants *Pisonia aculeata* were collected in the month of July 2010 from the Tirunelveli Dist, Tamilnadu, India. The plant material was taxonomically identified by the Botanical Survey of India, Coimbatore, Tamilnadu. A voucher specimen has been kept in our laboratory for future reference. The plants were dried in the shade and pulverized. The powder was treated with petroleum ether for dewaxing as well as to remove chlorophyll. The powder was then packed into Soxhlet apparatus and subjected to hot continuous percolation using methanol (95% v/v) as solvent. The extract was concentrated under vacuum and dried in a vacuum desiccator (yield 4.1

%w/w) and then suspended in 5% gum acacia for hepatoprotective studies.

Animals:

Male Wistar rats (125-150 g) and Swiss albino mice (20-25 g) were procured from Sri Venkateswara Enterprises, Bangalore, India. They were housed in microloan boxes with standard laboratory diet and water ad libitum. The study was conducted after obtaining Institutional animal ethical committee clearance.

Chemicals:

Rifampicin and isoniazid were purchased from Lupin Ltd., Mumbai, India. 1-chloro-2,4-dinitro benzoic acid (CDNB), 5,5-dithio-bis-2-nitro benzoic acid (DTNB) and reduced glutathione (GSH) were supplied by Sisco Research Laboratories Pvt. Ltd., Mumbai, India. Thiobarbituric acid was purchased from E-Merck, India. All other chemicals used were of analytical grade.

Acute toxicity:

The acute toxicity of the MPA was evaluated in mice using the up and down procedure (OECD, 2001). Mice received alcohol extract at various doses (500-2000 mg/kg) orally by gavage. The animals were observed for toxic symptoms continuously for the first 4 h after dosing. Finally, the number of survivors was noted after 24 h.

Experimental design:

Rats were divided into five groups, each group consisting of six animals.

Group I: Controls received the vehicle viz. normal saline (2 ml/kg).

Group II: Received RCIN and INH (100 +50 mg/kg p.o.)^[5] at every 72 h for 21 days.

Group III: Received silymarin 50 mg/kg p.o. for 21 days and simultaneously administered RCIN and INH (100 +50 mg/kg p.o.) every 72 h.

Group IV: Received MPA 250 mg/kg p.o for 21 days and simultaneously administered a RCIN and INH (100 +50 mg/kg p.o.) every 72 h.

Group V: Received MPA 500 mg/kg p.o. for 21 days and simultaneously administered RCIN and INH (100 +50 mg/kg p.o.) every 72 h.

At the end of all experimental methods, all the animals were sacrificed by cervical decapitation. Blood samples were collected, allowed to clot. Serum was separated by centrifuging at 2500 rpm for 15 min and analyzed for various biochemical parameters.

Assessment of liver function:

Biochemical parameters i.e., aspartate amino transferase (AST) (6) alanine amino transferase (ALT) (6), alkaline phosphatase (ALP) (7), γ -glutamate transpeptidase (GGTP) (8), total bilirubin (9) and total protein (10) were analyzed according to the reported methods. The liver was removed, weighed and morphological changes were observed. A 10% of liver homogenate was used for antioxidant studies such as lipid peroxidation (LPO) (11), superoxide dismutase (SOD) (12), catalase (13),

glutathione peroxidase (GPx) (14). Another portion of liver homogenate was centrifuged at 100,000 X g for 60 min at 4^o C for microsomal separation and was used to assay for cytochrome P450 (15), cytochrome c reductase (16) and glutathione S-transferase (GST) (17). were analyzed according to the reported methods. The liver was removed, weighed and morphological changes were observed. A portion of liver was fixed in 10% formalin for histopathological studies.

Histopathological studies:

Liver slices fixed for 12 hrs in Bouin's solution were processed for paraffin embedding following standard micro techniques (18). 5 μ m sections of liver grained with alum haematoxylin and eosin were observed microscopically for histopathological changes.

Statistical analysis:

The values were expressed as mean \pm SEM. Statistical analysis was performed by one way analysis of variance (ANOVA) followed by Tukey multiple comparison test and data on liver weight variations were analyzed using Student's 't' test. P values < 0.05 were considered as significant.

Table 1. Effect of MPA on Biochemical Parameters in RCIN and INH -induced hepatotoxicity rats.

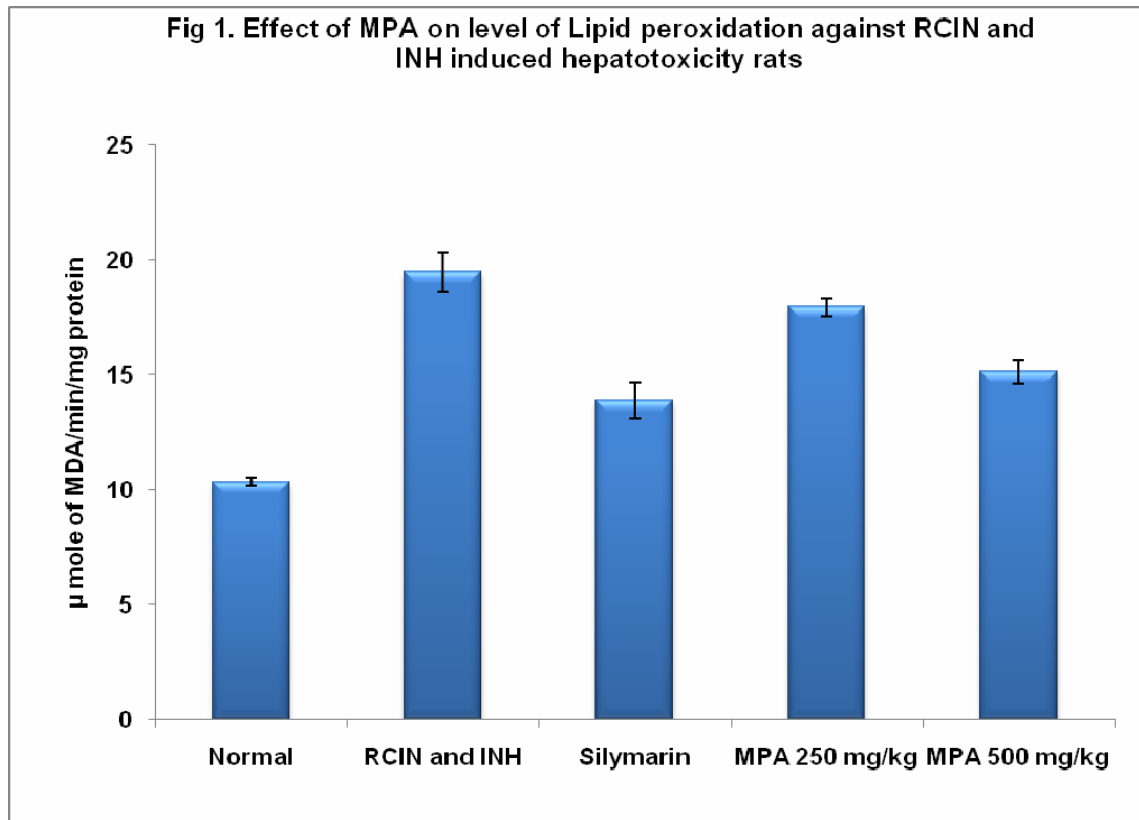
Treatment	Dose (mg/kg)	AST U/L	ALT U/L	ALP U/L	Total bilirubin mg%	Total protein mg%	GGTP U/L
Normal (normal saline)	2 ml/kg	132.7 \pm 1.18	76.25 \pm 1.78	196.5 \pm 2.45	0.8 \pm 0.05	8.13 \pm 0.46	75.34 \pm 1.05
RCIN and INH	50+100	210.3 \pm 2.85 ^a	165.4 \pm 1.15 ^a	376.8 \pm 3.42 ^a	1.24 \pm 0.06 ^a	6.45 \pm 0.18 ^b	189.5 \pm 2.67 ^a
Silymarin	50	152.4 \pm 1.26 ^{a,c}	101.3 \pm 1.38 ^{a,c}	223.5 \pm 2.06 ^{a,c}	0.93 \pm 0.04 ^d	7.8 \pm 0.25 ^e	102.6 \pm 1.21 ^{a,c}
MPA	250	183.5 \pm 1.52 ^{a,c}	140.9 \pm 1.65 ^{a,c}	316.24 \pm 2.34 ^{a,c}	1.14 \pm 0.07 ^b	7.1 \pm 0.14	149.3 \pm 1.14 ^{a,c}
	500	165.7 \pm 1.34 ^{a,c}	126.5 \pm 1.23 ^{a,c}	258.9 \pm 2.45 ^{a,c}	1.06 \pm 0.05 ^b	7.5 \pm 0.16	116.4 \pm 1.34 ^{a,c}

N= 6; Values are expressed as mean \pm SEM

^aP<0.001; ^bP<0.01 Vs Normal

^cP<0.001; ^dP<0.01; ^eP<0.05 Vs RCIN and INH

Data were analysed by one way ANOVA followed by Tukey multiple comparison test



N=6; Values are expressed as mean ± SEM

^aP<0.001; ^bP<0.01 Vs control

^cP<0.01; ^dP<0.05 Vs **RCIN and INH**

Data were analysed by one way ANOVA followed by Tukey multiple comparison analysis.

Results

The effect of MPA on serum marker enzymes are presented in table 1. The levels of serum AST, ALT, ALP, total bilirubin, GGTP were markedly elevated and that of protein decreased in RCIN and INH treated animals, indicating liver damage. Administration of MPA at the doses of 250 and 500 mg/kg remarkably prevented RCIN and INH -induced hepatotoxicity in a dose dependent manner.

Analysis of LPO levels by paracetamol acid reaction showed a significant (P<0.001) increase in the INH and RCIN treated rats. Treatment with MPA (250 mg/kg and 500 mg/kg) significantly (P<0.001) prevented the increase in LPO level which was brought to

near normal. The effect of MPA was comparable with that of standard drug silymarin (Fig 1).

RCIN and INH treatment caused a significant (P<0.001) decrease in the level of SOD, catalase, GPx, GR, GSH, Vit C and Vit E in liver tissue when compared with control group (table 2). The treatment of MPA at the doses of 250 and 500 mg/kg resulted in a significant increase of enzymic and non enzymic antioxidants when compared to RCIN and INH treated rats. The liver of silymarin treated animals also showed a significant increase in antioxidant enzymes levels compared to INH and RCIN treated rats.

Table 2. Effect of MPA on enzymic and non-enzymic antioxidants level in RCIN and INH -induced hepatotoxicity rats.

Treatment	Dose (mg/kg)	SOD	CAT	GPx	GR	GSH	Vit -C	Vit -E
Normal (normal saline)	2 ml/kg	46.7 ± 1.12	78 ± 3.10	28.45 ± 1.16	3.46 ± 0.14	2.04±0.06	1.75±0.005	0.65±0.003
RCIN and INH	50+100	24.8±1.26 ^a	36±1.14 ^a	14.52±0.85 ^a	1.73±0.08 ^a	1.02±0.09 ^a	0.89±0.007 ^a	0.34±0.004 ^a
Silymarin	50	41.6±1.45 ^c	72±2.06 ^c	25.64±1.12 ^c	3.08±0.27 ^c	1.91±0.04 ^c	1.59±0.008 ^{a,c}	0.57±0.005 ^{a,c}
MPA	250	30.4±1.18 ^{a,d}	46±1.27 ^{a,c}	18.93±0.93 ^{a,d}	2.23± 0.15 ^a	1.34±0.07 ^{a,d}	1.18±0.005 ^{a,c}	0.42±0.008 ^{a,c}
	500	38.7±1.28 ^{b,c}	63±1.35 ^{a,c}	22.67±1.06 ^{b,c}	2.89± 0.16 ^c	1.82±0.05 ^c	1.37±0.006 ^{a,c}	0.51±0.006 ^{a,c}

N=6; Each value is expressed as mean ± S.E.M.

^aP<0.001; ^bP<0.01 Vs Control

^cP<0.001; ^dP<0.05 ; ^eP<0.01 Vs RCIN and INH

Data were analysed by one way ANOVA followed by Tukey Kramer multiple comparison test

Units: SOD-1U=amount of enzyme that inhibits the antioxidants of pyrogallol by 50%; CAT- μmoles of H₂O₂ consumed/min/mg protein; GPx-μmoles of GSH oxidized/min/mg protein; GSH-μg/mg protein; GR-nmoles of NADPH oxidized/min/mg protein; Vitamin C and Vitamin E- μg/mg protein

Table 3. Effect of MPA on phase I and phase II enzymes in RCIN and INH induced hepatotoxicity in rats.

Treatment	Dose (mg/kg)	Cyt p450	NADPH cyto C reductase	GST
Normal (normal saline)	2 ml/kg	2.36 ± 0.04	96.53 ± 1.17	2.07 ± 0.06
RCIN and INH	50 + 100	5.27 ± 0.06 ^a	165.23 ± 2.35 ^a	4.36 ± 0.12 ^a
Silymarin	50	2.73 ± 0.05 ^{b,c}	113.45 ± 1.42 ^{a,c}	2.47±0.08 ^{b,c}
MPA	250	4.18 ± 0.08 ^{a,c}	142.53 ± 1.78 ^{a,c}	3.94±0.05 ^{a,d}
	500	2.95 ± 0.07 ^{a,c}	120.86 ± 2.69 ^{a,c}	2.86±0.09 ^{a,c}

N=6 animals in each group; Each value is expressed as mean ± SEM.

^aP<0.001; ^bP<0.01 Vs Control

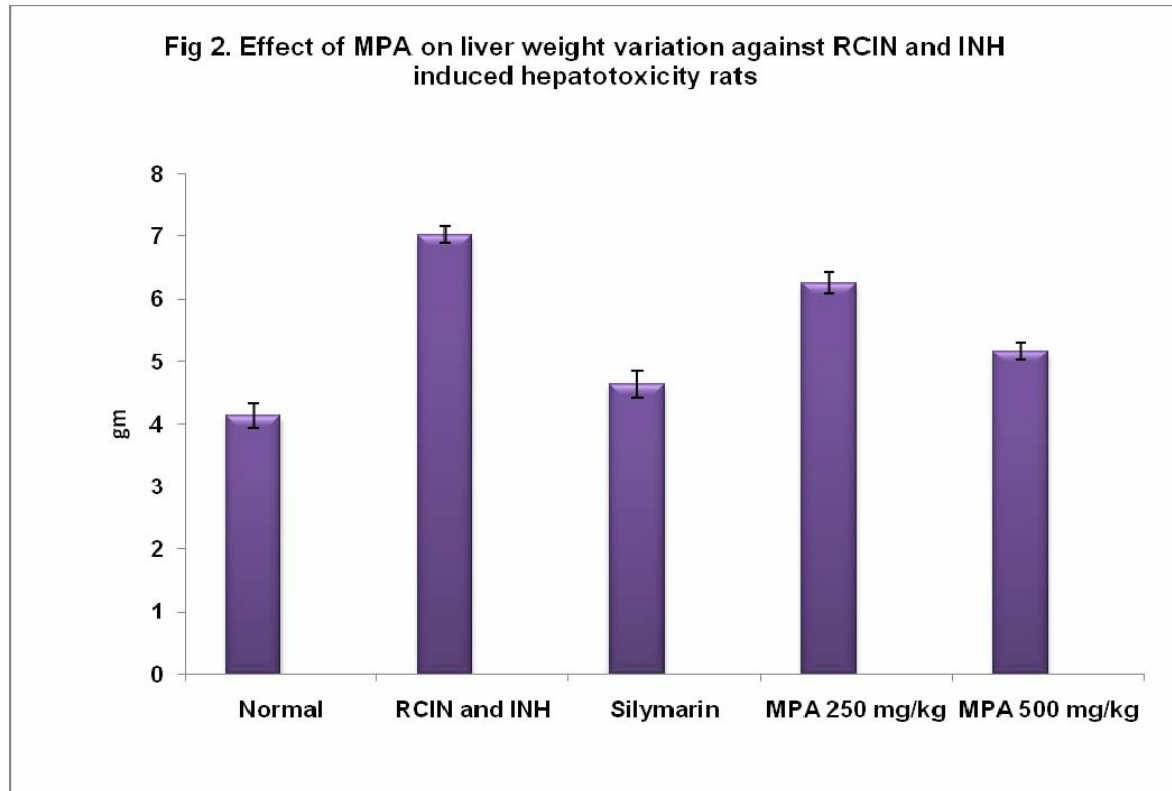
^cP<0.001; ^dP<0.05 Vs RCIN and INH

Data were analysed by one way ANOVA followed by Tukey Kramer multiple comparison test

Table 3. depicts the effect of *P. aculeata* on phase-I & II enzymes in liver of control and experimental animals. There found to be a significant (P<0.001) increase in the activities of Cyt P450, NADPH Cyt C reductase and GST in group RCIN and INH intoxicated animals when compared with control animals. *P. aculeata* extract treatment (250 and 500 mg/kg) resulted in a significant (P<0.001) decreases in phase-I and phase II enzyme levels. These enzyme activities was completely restored to the normal level by treatment with the *P. aculeata* extract at 500 mg/kg. As a positive hepatoprotective control, silymarin (50 mg/kg) also significantly restored Cyt P450,, NADPH Cyt C reductase and GST

enzyme activities to the normal level under the same conditions

Morphological observations showed an increased size and enlargement of the liver in RCIN and INH treated groups. These changes were reversed by treatment with silymarin and also MPA at the doses tested (Fig 2). Histopathological studies, showed RCIN and INH to produced extensive vascular degenerative changes and centrilobular necrosis in hepatocytes. Treatment with different doses of MPA produced mild degenerative changes and absence of centrilobular necrosis when compared with control. All these results indicate a hepatoprotective potential of the extract.



N=6; Values are expressed as mean \pm SEM

^aP < 0.001; ^bP < 0.01 Vs Normal

^cP < 0.001 Vs **RCIN and INH**

Data were analysed by one way ANOVA followed by Tukey multiple comparison test.

Discussion

Drug-induced hepatotoxicity is a potentially serious adverse effect of the currently used anti-tubercular chemotherapeutic regimens containing RCIN and INH. The conversion of monoacetyl hydrazine, a metabolite of INH, to a toxic metabolite via cytochrome P₄₅₀ leads to hepatotoxicity. RCIN induces cytochrome P₄₅₀ enzyme resulting an increased production of toxic metabolites from acetyl hydrazine (AcHz). RCIN can also increase the metabolism of INH to isonicotinic acid and hydrazine, both of which are hepatotoxic.

The plasma half life of AcHz (metabolite of INH) is shortened by RCIN and AcHz is quickly converted to its active metabolites by increasing the oxidative elimination rate of AcHz, which is related to the higher incidence of liver necrosis caused by RCIN

and INH combination (19). In addition to these mechanisms; oxidative stress induced hepatic injury is one of the important mechanisms in hepatotoxicity produced by anti-tubercular drugs (20,21). Earlier it has been well documented that both ALT and AST are considered among the most sensitive markers to assess hepatocellular damage leading to liver cell necrosis (22-23).

ALP, which is secreted from the lysosomes, is also a marker enzyme for assessing liver damage. Slight to moderate increases in ALP (1-2 times normal) occurred in liver disorders (24). γ GT has been claimed to be an extremely sensitive test and marker of hepatic damage. Estimating the activities of serum marker enzymes, like AST, ALT, ALP, total bilirubin, γ GT, can make assessment of liver function. When liver cell

plasma membrane is damaged, a variety of enzymes normally located in the cytosol are released in to the blood stream. Their estimation in the serum is a useful quantitative marker of the extent and type of hepatocellular damage.

The enhanced activities of these serum marker enzymes observed in RCIN and INH treated rats in our study correspond to the extensive liver damage induced by RCIN and INH. Results indicate that MPA administration could blunt RCIN and INH -induced increase in activities of different marker enzymes of hepatocellular injury, viz. AST, ALT, ALP, total bilirubin, γ GT and total protein, (Table 1) suggesting that MPA possibly has a protective influence against RCIN and INH induced hepatocellular injury and degenerative changes. Antitubercular drugs mediated oxidative damage is generally attributed to the formation of free radicals, which act as stimulator of lipid peroxidation and source for destruction and damage to the cell membrane (25).

The combination of RCIN and INH was reported to result in higher rate of inhibition of biliary secretion and an increase in liver cell lipid peroxidation, and cytochrome P-450 was thought to be involved in the synergistic effect of RCIN and INH (26). However, its role in INH-induced hepatotoxicity is unclarified, as INH itself is an inducer of CYP2E1 (27). In previous report suggested that, there did not seem to be clear evidence that INH proves much more injuries than RIF and, in this connection, they consider that it is the combination of these two drugs that confer the additive, or even synergistic, potential of liver toxicity than either agent alone, as conjectured (28-29). In our study, RCIN and INH treatment produced the elevation in the levels of LPO. Treatment of the rats with MPA significantly reduced the elevated levels of LPO.

Alterations of various cellular defense mechanisms consisting of enzymatic and non-enzymatic antioxidant components [superoxide dismutase (SOD), catalase, glutathione peroxidase (GPx), reduced glutathione, Glutathione reductase, Vitamin C and E have been reported in RCIN and INH -induced hepatotoxicity (Table 3). The RCIN and INH administered animals exhibited significantly ($p < 0.001$) low levels of hepatic enzymatic and non-enzymatic antioxidant components, and significantly increased with co-administration of MPA (250 and 500 mg/kg) at the all the doses and in silymarin treatment group after 21 days. On the day of 21st enzymatic and non-enzymatic antioxidant components levels significantly increased with co administration of MPA at the higher dose (500 mg/kg) and in silymarin treated group.

The inhibitory effect of RCIN and INH on cytochrome P₄₅₀ and Cyt c reductase levels was also compensated by the extract through maintenance of its normal level. The role of the MPA in the protection of RCIN and INH amediated loss in cytochrome P₄₅₀ content may be considered as an indication of improved protein synthesis in hepatic tissue (30,31). The function of GST is divided into catalysis and binding. GST is a soluble protein, plays an important role in the detoxification and excretion of xenobiotics (32,33). GST catalyzes the conjugation of the thiol functional groups of glutathione to electrophylic xenobiotics and results in increasing solubility. The xenobiotic-GSH conjugate is then either eliminated or converted to mercapturic acid.

Another function of GST is the binding between GST and endogenous and exogenous substances. Since GST increases solubility of hydrophobic substances, it plays an important role in storage and excretion of xenobiotics. MPA which decrease the activity of GST, which

metabolizes toxic compounds to non-toxic compounds, means they have an increasing protective activity of the liver. In RCIN and INH intoxicated rats, the activity of GST increased drastically compared to that of normal group. The activity of GST recovered significantly ($P < 0.001$) at 250 and 500 mg/kg of MPA compared to that of RCIN and INH group. In contrast, the GST activity at 500 mg/kg is almost similar to the activity shown by silymarin, a potent hepatoprotective agent.

Histopathological studies, treatment with different doses of MPA produced mild portal triaditis and absence of necrosis when compared with control. Treatment with silymarin also shows mild portal triaditis and absence of necrosis and vacuoles. All these results indicate a hepatoprotective potential of the extract. The results of the present study suggested that MPA possess hepatoprotective activity against the hepatotoxicity induced by the combination of two antitubercular drugs.

References

1. Pushpangadan P, Kumar B, Vijayakumar M and Govindarajan R. Ethnopharmacological approaches to wound healing exploring medicinal plants. *J Ethnopharmacol.* 2007;114:103-113.
2. Subramaniam A, Evans DA, Rajasekharan S and Pushpangadam P. Effect of *Trichopus zeylanicus* Gaertn (active fraction) on phagocytosis by peritoneal macrophages and humoral immune in response in mice. *Indian J Pharmacol.* 2000;32:221-225.
3. Howard RA. Flora of the Lesser Antilles, Leeward and Windward Islands. Dicotyledoneae, Part 1, 1988;673.
4. Liogier HA. Descriptive flora of Puerto Rico and adjacent islands. 1985;1:352.
5. Bhupinder Singh K, Sarita A, Nita K, Usha G. Effect of cimetidine on hepatotoxicity induced by isoniazid-rifampicin combination in rabbits. *Indian Journal of Gastroenterology.* 2007;26:18-21.
6. Reitman S and Frankel A. Colorimetric method for determination of serum glutamate oxaloacetate and glutamic pyruvate transaminase. *American J Clin Pathol.* 1957;28:56-58.
7. Kind PR, and King EJ. Estimation of plasma phosphates by determination of hydrolyzed phenol with antipyrin. *J Clin Pathol.* 1954;7:322-326.
8. Szaszi G. A kinetic photometric method for serum gamma glutamyl transpeptidase. *Clin Chem.* 1969;15:124-126.
9. Mallay HT, and Evelyn KA. Estimation of serum bilirubin level with the photoelectric colorimeter. *J Biol Chem.* 1937;119:481-484.
10. Lowry OH, Rosenbrough NJ, Farr AL, and Randall RJ. Protein measurement with Folin-Phenol reagent. *J Biol Chem.* 1951;193:265-275.
11. Devasagayam TPA and Tarachand U. Decreased lipid peroxidation in the rat kidney during gestation. *Biochem Biophys Res Commun.* 1987;56:836-842.
12. Marklund S and Marklund G. Involvement of superoxide anion radical in the auto oxidation of pyrogallol and a convenient assay for superoxide dismutase. *Eur J Biochem.* 1974;47:469-474.
13. Sinha AK. Colorimetric assay of catalase. *Analytical Biochem.* 1972;47:389-394.
14. Rotruck JT, Pope AL, Ganther HL and Swanson AB. Selenium: Biochemical role as a component of glutathione peroxidase. *Science.* 1973;179:588-590.
15. Omura T, Sato R. The carbon monoxide-binding pigment of liver microsomes. I. Evidence for its hemoprotein nature. *J. Biol. Chem.* 1964;239:2370-8.
16. Williams Jr CH, Kamin H. Microsomal triphosphopyridine nucleotide-

- cytochrome c reductase of liver. *J. Biol. Chem.* 1962;**237**:587-95.
17. Habig WH, Pabst MJ, and Jakoby WB. Glutathione S-transferase, the first enzymatic step in mercapturic acid formation. *J. Biol. Chem.* 1974;249:7130-7139.
 18. Galigher AE and Kozloff EN. *Essential Practical Micro technique*, 2nd edn, Lea and Febiger, Philadelphia. 1971;p.77.
 19. Hussain Z, Kar P, Husain SA. *Indian J Experimental Biol.* 2003;41:226.
 20. Mitra SK, Venkataranganna MV, Sundaram R, Gopumadhavan S. Protective effect of HD-03, a herbal formulation, against various hepatotoxic agents in rats. *J Ethnopharmacol.* 1998;63:18-186.
 21. Sodhi CP, Rana SF, Attri S, Mehta S, Yaiphei K, Mehta SK. Oxidative-hepatic injury of isoniazid-rifampicin in young rats subjected to protein and energy malnutrition. *Drug Chem Toxicol.* 1998;21:305-317.
 22. Nemesanszky E, Enzyme test in hepatobiliary disease. In *Enzyme Test in Diagnosis* (eds Moss DW and Rosalki SB), Arnold, London. 23-59.
 23. Amacher DE, Serum transaminase elevations as indicators of hepatic injury following the administration of drugs *Regul Toxicol Pharmacol.* 1998;27:119-130.
 24. Isselbacher KJ, Braunwald E, Wilson JD, Martin JB, Fauci AS, Kasper DL. *Harrison's principles of internal medicine*, 13th edn. McGraw-Hill, New York. 1994;1444.
 25. Georgieva N, Gadjeva V, Tolekova A. New isonicotinoylhydrazones with ssa protect against oxidativehepatic injury of isoniazid. *TJS* 2004;2:37-43.
 26. Ramaiah SK, Apte U, Mehendale HIM. Cytochrome P4502E1 induction increases thioacetamide liver injury in diet-restricted rats. *Drug Metab Dispos.* 2001;29:1088-95.
 27. Shakun NP, Shmanko VV. Synergistic effect of rifampicin on hepatotoxicity of isoniazid. *Antibiot Med Biotekhnol.* 1985;30:185-9.
 28. Steele MA, Burk RF and Des PRM. Toxic hepatitis with isoniazid and rifampicin: a meta-analysis. *Chest.* 1991;99:465-471.
 29. Wu JW, Leev SD, Yeh PF. Isoniazid-Rifampicin induced hepatitis in hepatitis B carriers. *Gastroentology.* 1990;98:502-4.
 30. Dwivedi Y, Rastogi R, Garg NK, and Dhawan BN. Prevention of paracetamol-induced hepatic damage in rats by picroliv, the standardized active fraction from *Picrorhiza kurroa*. *Phytotherapy Research.* 1991;5:115-119.
 31. Mandal PK, Bishayee A and Chatterjee M. Stimulation of tissue repair by *Mikania cordata* root extract in carbon tetrachloride-induced liver injury in mice. *Phytotherapy Research.* 1993;7:103-105.
 32. Boyer TD, Vessey DA., Holcomb C, Saley N. Studies of the relationship between the catalytic activity and binding of non-substrate ligands by the glutathione S-transferase. *Biochem J.* 1984;217:179-185.
 33. Masukawa T, Iwata H. Possible regulation mechanism of microsomal glutathione S-transferase activity in rat liver. *Biochem Pharmacol.* 1986;35:435-438.