



UNIVERSIDADE ESTADUAL DE CAMPINAS
FACULDADE DE ODONTOLOGIA DE PIRACICABA

MARIA EDUARDA PÉREZ DE OLIVEIRA

**APLICAÇÃO DA CITOPATOLOGIA NO DIAGNÓSTICO DE LESÕES ORAIS E
MAXILOFACIAIS: UMA ANÁLISE RETROSPECTIVA DE 18 ANOS**

OVERVIEW OF CYTOPATHOLOGY IN THE ORAL AND MAXILLOFACIAL REGION:
18-YEAR EXPERIENCE

Piracicaba
2020

MARIA EDUARDA PÉREZ DE OLIVEIRA

APLICAÇÃO DA CITOLOGIA NO DIAGNÓSTICO DE LESÕES ORAIS E
MAXILOFACIAIS: UMA ANÁLISE RETROSPECTIVA DE 18 ANOS

OVERVIEW OF CYTOPATHOLOGY IN THE ORAL AND MAXILLOFACIAL REGION:
18-YEAR EXPERIENCE

Dissertação apresentada à Faculdade de Odontologia de Piracicaba da Universidade Estadual de Campinas como parte dos requisitos exigidos para a obtenção do título de Mestra em Estomatopatologia, na Área de Patologia.

Dissertation presented to the Piracicaba Dental School of the State University of Campinas in partial fulfillment of the requirements for the degree of Master in Stomatopathology, in Pathology area.

Orientador: Prof. Dr. Pablo Agustin Vargas

Co-orientadora: Dra. Vivian Petersen Wagner

Este trabalho corresponde à versão final da dissertação defendida pela aluna Maria Eduarda Pérez de Oliveira, e orientada pelo Prof. Dr. Pablo Agustin Vargas.

Piracicaba

Ficha catalográfica
Universidade Estadual de Campinas
Biblioteca da Faculdade de Odontologia de Piracicaba
Marilene Girello - CRB 8/6159

OL4a Oliveira, Maria Eduarda Pérez de, 1994-
Aplicação da citopatologia no diagnóstico da lesões orais e maxilofaciais :
uma análise retrospectiva de 18 anos / Maria Eduarda Pérez de Oliveira. –
Piracicaba, SP : [s.n.], 2020.

Orientador: Pablo Agustin Vargas.
Coorientador: Vivian Petersen Wagner.
Dissertação (mestrado) – Universidade Estadual de Campinas, Faculdade
de Odontologia de Piracicaba.

1. Patologia. 2. Citologia esfoliativa. 3. Biópsia por agulha fina. 4. Boca. 5.
Neoplasias de cabeça e pescoço. I. Vargas, Pablo Agustin, 1973-. II. Wagner,
Vivian Petersen. III. Universidade Estadual de Campinas. Faculdade de
Odontologia de Piracicaba. IV. Título.

Informações para Biblioteca Digital

Título em outro idioma: Overview of cytopathology in the oral and maxillofacial region :
18-year experience

Palavras-chave em inglês:

Pathology

Exfoliative cytology

Biopsy, fine-needle

Mouth

Head and neck neoplasms

Área de concentração: Patologia

Titulação: Mestra em Estomatopatologia

Banca examinadora:

Pablo Agustin Vargas [Orientador]

Fábio de Abreu Alves

Márcio Ajudarte Lopes

Data de defesa: 18-02-2020

Programa de Pós-Graduação: Estomatopatologia

Identificação e informações acadêmicas do(a) aluno(a)

- ORCID do autor: <https://orcid.org/0000-0003-3265-2671>

- Currículo Lattes do autor: <http://lattes.cnpq.br/2117441501660769>



UNIVERSIDADE ESTADUAL DE CAMPINAS
Faculdade de Odontologia de Piracicaba

A Comissão Julgadora dos trabalhos de Defesa de Dissertação de Mestrado, em sessão pública realizada em 18 de fevereiro de 2020, considerou a candidata MARIA EDUARDA PÉREZ DE OLIVEIRA aprovada.

PROF. DR. PABLO AGUSTIN VARGAS

PROF. DR. FÁBIO DE ABREU ALVES

PROF. DR. MÁRCIO AJUDARTE LOPES

A Ata da defesa, assinada pelos membros da Comissão Examinadora, consta no SIGA/Sistema de Fluxo de Dissertação/Tese e na Secretaria do Programa da Unidade.

DEDICATÓRIA

Dedico este trabalho a minha Vovó Sineide (*in memoriam*) que é o meu mais fiel anjo da guarda e meu maior exemplo de perseverança, coragem e amor ao próximo.

AGRADECIMENTOS

À Universidade Estadual de Campinas, na pessoa do Magnífico Reitor, Prof. Dr. Marcelo Knobel.

À Faculdade de Odontologia de Piracicaba, na pessoa de seu Diretor, Prof. Dr. Francisco Haiter Neto e seu Diretor Associado, Prof. Dr. Flávio Henrique Baggio Aguiar.

À Profa. Dra. Karina Gonzales Silvério Ruiz, Coordenadora Geral da Pós-Graduação da Faculdade de Odontologia de Piracicaba.

Ao Coordenador do Programa de Pós-Graduação em Estomatopatologia, Prof. Dr. Márcio Ajudarte Lopes.

O presente trabalho foi realizado com apoio da Coordenação de Aperfeiçoamento de Pessoal de Nível Superior – Brasil (CAPES) - Código de Financiamento 001.

Ao meu orientador, Prof. Dr. Pablo Agustin Vargas, pelos ensinamentos e oportunidades proporcionadas.

À minha co-orientadora, Dra. Vivian Petersen Wagner, pelo apoio à elaboração desse trabalho e pelo carinho me dado nessa trajetória.

A todos os amigos da pós-graduação, pela convivência e parceria. A rede de apoio que conseguimos criar é, sem dúvidas, essencial para nosso crescimento pessoal e profissional. Serei eternamente grata por tudo.

Aos meus pais, Fernanda e Eduardo, por me proporcionar suporte e amor que são fundamentais para que eu possa ir em busca dos meus objetivos. Agradeço toda confiança depositada em mim.

À minha irmã, Maria Amanda, por me mostrar o real significado da irmandade e por ser uma inspiração e uma fortaleza para mim.

Ao meu noivo e grande amigo, Matheus, por seu apoio e incentivo incondicionais, sempre acreditando no meu potencial.

Aos meus verdadeiros amigos que, mesmo distantes fisicamente, sei que estarão sempre torcendo pelo meu sucesso. Cativo cada um de vocês dentro do meu coração.

RESUMO

O objetivo desse estudo foi realizar um levantamento dos casos submetidos para o diagnóstico citopatológico para demonstrar as diversas aplicações desse exame complementar na região oral e maxilofacial. Uma análise retrospectiva foi realizada no Laboratório de Patologia Oral da Faculdade de Odontologia de Piracicaba num período de 18 anos. Informações clínicas e citológicas foram coletadas. Associações entre as variáveis clínicas e citológicas foram realizadas através do teste do qui-quadrado de Pearson ou teste de Fisher, com um nível de significância de 5%. Quando disponível, o diagnóstico histopatológico foi comparado com o diagnóstico citológico para identificar a porcentagem de concordância entre esses exames e foram calculadas a especificidade, sensibilidade e acurácia da citopatologia em identificar neoplasias malignas. 1.082 casos foram identificados compreendendo 65 diferentes diagnósticos. A citologia esfoliativa (CE) foi realizada em 312 casos (29,1%) e a punção aspirativa por agulha fina (PAAF) em 770 casos (70,9%). CE foi empregada principalmente para diagnóstico de lesões infecciosas e PAAF para diagnósticos do grupo de neoplasias, lesões císticas, reacionais e de patologia variada. Cell Block (CB) foi realizado em 555 casos (51,3%) derivados da PAAF. Colorações de Panótico, Papanicolaou e hematoxilina-eosina foram realizadas na PAAF e Ácido periódico de Schiff na EC. Em 211 casos (19,5%) o diagnóstico histopatológico estava disponível e a porcentagem de concordância com o diagnóstico citopatológico foi de 40,3%. Sensibilidade, especificidade, valor preditivo positivo, valor preditivo negativo e acurácia da citologia em identificar neoplasias malignas foi 84,6%, 100%, 77,8% e 90,0%, respectivamente. Em conclusão, a Citopatologia forneceu diferentes diagnósticos de lesões da região de cabeça e pescoço. A CE foi realizada principalmente para o diagnóstico de lesões infecciosas e a PAAF para o diagnóstico de tumores de glândula salivar, lesões odontogênicas, lesões reacionais e rastreamento de metástases cervicais.

Palavras-chave: Patologia; Citologia esfoliativa; Biópsia por agulha fina; Boca; Neoplasias de cabeça e pescoço

ABSTRACT

The aim of this study was to perform a survey of oral and maxillofacial specimens submitted for cytologic diagnosis to verify the importance of this complementary exam. A retrospective analysis of our institutional cytopathology database was performed over an 18-year period. Clinical information and cytological data were collected. Associations between independent variables and outcomes were assessed using the Pearson chi-square test or Fisher's test, with a 5% significance level. When available, the histologic diagnosis was compared with cytologic diagnosis to identify the percentage of agreement and the specificity, sensitivity and accuracy of cytology in identifying malignant neoplasms. A total of 1,082 cases were identified that comprised 65 different cytological diagnoses. Exfoliative cytology (EC) was performed in 312 cases (29.1%) and fine-needle aspiration cytology (FNAC) in 770 cases (70.9%). EC was mainly employed to diagnose oral infectious diseases and FNAC to diagnose neoplasms, cystic, reactive and miscellaneous lesions. Cell block was performed in 555 FNAC cases (51.3%). Papanicolaou, Papanicolaou and hematoxylin-eosin staining was performed in FNAC and periodic acid-Schiff in EC. In 211 cases (19.5%), the histologic diagnosis was available and the percentage agreement with the cytologic diagnosis was 40.3%. Sensitivity, specificity, positive predictive value, negative predictive value and accuracy to identify malignant neoplasms were 84.6%, 100%, 100%, 77.8% and 90.0%, respectively. In summary, the cytology provided several different diagnoses of lesions of the oral and maxillofacial region. EC was mainly performed for diagnosis of infectious diseases and FNAC for diagnosis of salivary gland tumours, odontogenic lesions, reactional lesions and cervical metastasis.

Keywords: Pathology; Exfoliative cytology; Biopsy, fine-needle; Mouth; Head and neck neoplasms

SUMÁRIO

1 INTRODUÇÃO	10
2 ARTIGO: Overview of cytopathology in the oral and maxillofacial region: 18-year experience	12
3 CONCLUSÃO	36
REFERÊNCIAS	37
ANEXOS	39
Anexo 1 - Verificação de originalidade e prevenção de plágio	39
Anexo 2 - Certificado do Comitê de Ética em Pesquisa.....	40
Anexo 3 - Comprovante de submissão do artigo à revista Cytopathology.....	41

1 INTRODUÇÃO

Muitas lesões orais podem se apresentar com características clínicas semelhantes, necessitando da realização de exames complementares, os quais irão auxiliar no diagnóstico definitivo. É bem estabelecido que o exame histopatológico é o padrão ouro para diagnóstico de lesões. Entretanto, a histopatologia requer uma técnica laboratorial mais elaborada e conseqüentemente mais tempo é consumido e, em algumas ocasiões informações relevantes sobre uma determinada lesão são requeridas o mais rápido possível. Como forma de superar essa limitação, métodos mais simples e mais rápidos, como a citopatologia, podem ser úteis e contribuir para um correto manejo terapêutico (Dolens et al., 2012; Kazanowska et al., 2014).

A citopatologia consiste no estudo microscópico de amostras de células coletadas de superfícies mucosas através de esfregaços realizados pela citologia esfoliativa (CE), ou de localizações internas através de punção aspirativa por agulha fina (PAAF). Essas amostras são fixadas em uma lâmina de vidro e enviadas para um laboratório onde são coradas e analisadas microscopicamente para avaliar o grau de anormalidade das células. Esse exame oferece muitas vantagens, entre elas, um exame complementar barato, simples, minimamente invasivo e conseqüentemente mais confortável para o paciente (Ghandi et al., 2011; Dolens et al., 2012) A CE é popular como uma ferramenta diagnóstica para câncer do cérvix uterino. A utilidade deste método na cavidade oral tem sido descrita para diagnóstico de lesões infecciosas, como candidíase e paracoccidiodomicose (Silva et al., 2010; Loss et al., 2011). O exame da citopatologia realizada pela PAAF é amplamente utilizado em diversas situações clínicas como na investigação de tumores em linfonodos, fígado, tireoide, mama, glândulas salivares maiores, rastreamento de lesões precursoras de carcinoma de colo de útero, acompanhamento de pacientes com carcinoma de pulmão, entre outras (Al-Abbadi, 2011; Díaz et al., 2014; Houcine et al., 2018; Xavier-Júnior et al., 2019).

A PAAF é realizada primariamente em massas palpáveis e lesões profundas que possuem uma dificuldade de acesso. É um exame que auxilia na implementação da terapia adequada por ser utilizado como um recurso pré-operatório das lesões. Esse exame é muito realizado na região de cabeça e pescoço. Em lesões de boca esse exame permanece pouco utilizado pelos profissionais. Entretanto, já foi descrito na literatura a relevância da PAAF na identificação de lesões bucais (Ghandi et al., 2011; Santos et al., 2011).

Existem controvérsias na literatura em relação ao real valor da citopatologia como recurso auxiliar de diagnóstico para patologias da cavidade bucal. A baixa sensibilidade desse exame na cavidade bucal está relacionada a vários fatores incluindo uma amostra inadequada, erros de procedimentos e interpretação subjetiva dos achados (Kazanowska et al., 2014). Apesar disso, quando bem indicada, realizada e interpretada, a literatura demonstra o valor da citopatologia na investigação de diversas lesões de boca, como tumores intra-bucais de glândula salivar (Fregnani et al., 2006), queratocisto odontogênico (Vargas et al., 2007), hemangioma, reações de corpo estranho a material de preenchimento (Faria et al., 2014) e lesão central de células gigantes (Fonseca et al., 2013). Com isso, é possível perceber que o uso da citopatologia em lesões de boca possui diversas indicações e acredita-se que a baixa frequência de uso deste exame está associada principalmente com a falta de treinamento dos cirurgiões-dentistas para a realização desse exame complementar. Um estudo realizado por Silva et al. (2014), avaliou o conhecimento dos cirurgiões-dentistas acerca da citologia esfoliativa e observou a necessidade de maior conhecimento desses profissionais sobre o uso desse exame na prática clínica.

Estudos retrospectivos sobre o exame histopatológico na região oral e maxilofacial (Franklin e Jones, 2006; Kelloway et al., 2014) têm sido descritos, porém, nenhum estudo foi conduzido nesse sentido na citopatologia oral e maxilofacial. Dessa forma, o objetivo do presente estudo foi realizar um levantamento dos casos submetidos para diagnóstico citopatológico no laboratório de Patologia Oral da Faculdade de Odontologia de Piracicaba, Universidade Estadual de Campinas, no período de 2001 a 2018, a fim de proporcionar uma análise detalhada sobre a aplicabilidade na prática clínica da citopatologia na região oral e maxilofacial. Adicionalmente, a especificidade, a sensibilidade e a acurácia dos exames citopatológicos para identificação neoplasias malignas foram avaliadas, comparando-as com o exame histopatológico (padrão ouro).

2 ARTIGO: Overview of cytopathology in the oral and maxillofacial region: 18-year experience

Artigo submetido no periódico *Cytopathology*

(Anexo 2)

Maria Eduarda PÉREZ-DE-OLIVEIRA¹, Vivian Petersen WAGNER¹, Gleyson Kleber do AMARAL-SILVA¹, Amanda Almeida LEITE¹, Márcio Ajudarte LOPES¹, Alan Roger SANTOS-SILVA¹, Jacks JORGE JÚNIOR¹, Oslei Paes de ALMEIDA¹, Pablo Agustin VARGAS¹

1 - Department of Oral Diagnosis, Oral Pathology and Semiology Area, Piracicaba Dental School, State University of Campinas (UNICAMP), Piracicaba, São Paulo, Brazil.

Running title: Oral and maxillofacial cytopathology

Corresponding author:

Pablo Agustin Vargas, DDS, PhD, FRCPath

Departamento de Diagnóstico Oral, Área de Patologia Oral

Faculdade de Odontologia de Piracicaba, Universidade Estadual de Campinas

Av. Limeira, 901, CEP: 13.414-903, Piracicaba, São Paulo (SP), Brasil

Telephone number: +55 19 2106 5319

E-mail: pavargas@unicamp.br

Funding sources: This study was sponsored by the Coordenação de Aperfeiçoamento de Pessoal de Nível Superior - Brasil (CAPES) – Finance Code 001. Pablo A. Vargas, Márcio A. Lopes, and Alan R. Santos-Silva are research fellows funded by the Conselho Nacional de Desenvolvimento Científico e Tecnológico (CNPq).

Conflict of interest: The authors declare no potential conflicts of interest.

Abstract

Objective: The aim of this study was to perform a survey of oral and maxillofacial specimens submitted for cytologic diagnosis to verify the importance of this complementary exam.

Methods: A retrospective analysis of our institutional cytopathology database was performed over an 18-year period. Clinical information and cytological data were collected. Associations between independent variables and outcomes were assessed using the Pearson chi-square test or Fisher's test, with a 5% significance level. When available, the histologic diagnosis was compared with cytologic diagnosis to identify the percentage of agreement and the specificity, sensitivity and accuracy of cytology in identifying malignant neoplasms.

Results: A total of 1,082 cases were identified that comprised 65 different cytological diagnoses. Exfoliative cytology (EC) was performed in 312 cases (29.1%) and fine-needle aspiration cytology (FNAC) in 770 cases (70.9%). EC was mainly employed to diagnose oral infectious diseases and FNAC to diagnose neoplasms, cystic, reactive and miscellaneous lesions. Cell block was performed in 555 FNAC cases (51.3%). Papanicolaou and hematoxylin-eosin staining was performed in FNAC and periodic acid-Schiff in EC. In 211 cases (19.5%), the histologic diagnosis was available and the percentage agreement with the cytologic diagnosis was 40.3%. Sensitivity, specificity, positive predictive value, negative predictive value and accuracy to identify malignant neoplasms were 84.6%, 100%, 100%, 77.8% and 90.0%, respectively.

Conclusions: EC was mainly performed for diagnosis of infectious diseases and FNAC for diagnosis of salivary gland tumours, odontogenic lesions, reactional lesions and cervical metastasis.

Keywords: cytopathology, exfoliative cytology, fine-needle aspiration cytology, oral cavity, head and neck.

Introduction

Oral diseases can share many clinical aspects, and complementary tests may be needed to achieve a diagnosis. Cytology represents a diagnostic tool based on a microscopic evaluation of the cell samples collected from mucosal surface via exfoliative cytology (EC) or internal sites via fine-needle aspiration cytology (FNAC).¹ This complementary exam is widely used in many clinical routines, such as investigation of masses in lymph nodes, liver, thyroid and breast, as well as screening of precursor lesions of cervical carcinoma and follow-up of patients with lung carcinoma.^{2,3} In oral diagnosis, the use of cytology exam remains controversial. Previous reports demonstrated that cytopathology can be a useful tool in head and neck lesions.^{3,4} Most reports have focused on the thyroid,⁵ major salivary gland⁶ and cervical lymph node masses,⁷ in which, when well indicated, performed and interpreted, cytopathology can achieve a high accuracy to allow for correct therapeutic management. Single reports in the literature suggest that cytopathology applications can go beyond the above-mentioned scenarios. This technique is useful for the investigation of odontogenic keratocyst,⁸ haemangioma,⁹ dermal cosmetic fillers reaction¹⁰ and central giant cell lesion.^{11,12}

Cytology is a simple, rapid, accurate and minimally invasive technique that is well tolerated by patients.¹ It appears that the low frequency of oral cytopathology investigations is mainly related to the lack of the knowledge of professionals about performing its technique and the various diagnostic possibilities that this exam can provide.

The aim of this study was to perform a survey of oral and maxillofacial specimens submitted for cytological diagnosis over an 18-year period in a reference centre for Oral Pathology and Medicine in Southeast Brazil.

Methods

This study was approved by the local research Ethics Committee, under protocol no. 86606318.9.0000.5418. All cytological specimens submitted between 2001 and 2018 for diagnosis in the Oral Pathology Laboratory, Campinas State University, Piracicaba Dental School, Piracicaba, São Paulo, Brazil, were retrieved. Relevant data, such as gender and age of the patients and clinical features of the lesions, were obtained from the clinical charts. Cytological data, such as technique (exfoliative cytology [EC] from samples collected by surfaces or fine-needle aspiration cytology [FNAC] from samples collected by swellings), type of stain (Papanicolaou, Panoptic, periodic acid-Schiff [PAS], hematoxylin-eosin [HE], Ziehl-Neelsen or mucicarmine), method of analysis (cytological smear or cell block [CB]) and immunohistochemistry reactions, were also collected. Additionally, when available, the histopathological diagnosis was correlated with the cytological diagnosis. For malignant neoplasms, the specificity, sensitivity and accuracy of cytology was calculated.

Statistical analysis

Analysis was performed using SPSS software (IBM Corporation, Armonk, NY), version 20. Initially, a descriptive analysis of clinicocytological features was performed. The existence of associations between independent variables and outcomes was assessed using the Pearson chi-square test or Fisher's test. For all tests, a 5% significance level was used. For cases with an available histologic diagnosis, sensitivity, specificity, positive predictive value (PPV), negative predictive values (NPV) and accuracy of cytological exam in the neoplasms' category were calculated. The lesions were categorised as follow: (i) true positive (TP) when malignancy was present in both cytologic and histologic diagnosis; (ii) true negative (TN) when malignancy was absent in both cytologic and histologic diagnosis; (iii) false positive (FP) when malignancy

was present in cytologic diagnosis but absent in the histology diagnosis; (iv) false negative (FN) when malignancy was absent in cytologic diagnosis but present in the histology diagnosis. PPV refers to the probability that a positive result indicates the presence of a lesion; NPV is the probability that a negative results indicates the absence of any lesion; accuracy is the proportion of true results, either true positive or true negative, in a population, measuring the degree of veracity of a diagnostic test on a condition.¹³

Results

During the 18-year period, 1,082 specimens were received for cytological diagnosis. The clinical and demographic data are summarised in **Table 1**. Males slightly outnumbered females, with a male:female ratio of 1.25:1. The ages ranged from 5 months to 93 years, with a mean age of 46.29 years. Clinically, a nodule (n = 559; 57.1%) was the most common lesion presentation, followed by plaque/papule/macule/crust (n = 163; 16.7%). The EC was performed in cases that presented as plaque/papule/macule/crust or ulcer/erosion. The FNAC was performed in cases that presented as nodule or intraosseous lesion. Lesion sizes ranged from 0.1 to 11.0 cm, with a mean of 2.6 cm. The time of complaint ranged from few days to 408 months, with a mean of 22.67 months. The intraoral/lips region (n = 448; 41.8%) was the most commonly affected site, followed by the major salivary glands (n = 261; 24.4%).

Table 1 – Clinical and demographic features of cases submitted for oral and maxillofacial cytology.

Variables	Number of cases (%)
Sex (n = 1,081)	
Male	601 (55.6)
Female	480 (44.4)
Age (n = 1,050)	
Range	5 months – 93 years
Mean	46.29 years
Clinical appearance (n = 979)	
Nodule	559 (57.1)
Plaque/papule/macule/crust	163 (16.7)
Intraosseous lesion	151 (15.4)
Ulcer/erosion	106 (10.8)
Size (n = 586)	
Range	0.1 cm – 11.0 cm
Mean	2.6 cm
Duration of complaints (n = 646)	
Range	5 days – 408 months
Mean	22.67 months
Site (n = 1,071)	
Intraoral/lips region	448 (41.8)
Major salivary glands	261 (24.4)
Gnathic bones	186 (17.4)
Cervical region	147 (13.7)
Facial region	29 (2.7)

In 770 cases (71.2%), the technique used to obtain the cell samples was FNAC, and in 312 cases (28.8%) it was EC. **Figure 1** demonstrates clinical features of cases that performed EC and FNAC. FNAC was performed in lesions from gnathic bones, cervical region, major salivary glands and facial region (means skin and extraoral soft tissue of the face rather than oral cavity region) and with diagnoses of neoplasms, cystic, reactional and miscellaneous lesions (include reactive lymph nodes, central giant cell lesions, cherubism, and lymphoproliferative process). EC was associated with lesions that occurred in the intraoral/lip region and for diagnosis of infectious diseases. Cytological smears were performed in all cases. Additionally, CB was performed in 555 cases (50.6%) from FNAC specimens. CB was performed for diagnosis of neoplasms (n = 144; 25.9%), cystic lesions (n = 104; 18.7%), infectious diseases (n = 31; 5.6%), miscellaneous pathologies (n = 27; 4.9%) and descriptive cases (n = 242; 43.6%). Panoptic and Papanicolaou staining were routinely performed in all cytological smears from FNAC cases. Additional stains were used in some cases; HE was the most common (n = 574; 53.0%), followed by PAS (n = 368 – 34.0%). HE stain was significantly performed in CB from FNAC cases and PAS in EC cases ($P < 0.001$) (**Table 2**). Immunohistochemical analysis was performed in 14 CB cases, in which AE1/AE3 was performed in 5 cases (0.5%), CD20 in 2 cases (0.2%), CD45 in 2 cases (0.2%), CD3 in 2 cases (0.2%), CD68 in 1 case (0.1%), CD99 in 1 case (0.1%) and FLI1 in 1 case (0.1%).

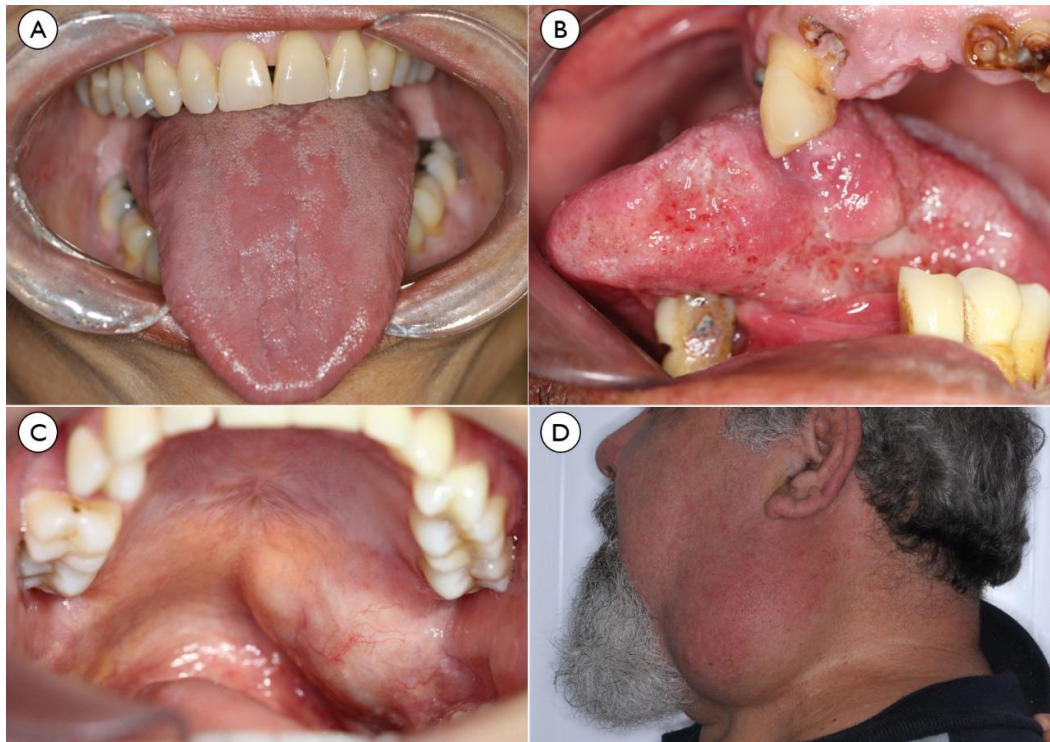


Figure 1 – Clinical features for application of oral and maxillofacial cytology. **(A)** Candidiasis. Exfoliative cytology (EC) was performed in central papillary atrophy in the dorsal tongue. **(B)** Paracoccidioidomycosis. EC was performed in an erythematous ulcer with moriform aspect in the lateral tongue. **(C)** Adenoid cystic carcinoma. Fine-needle aspiration cytology (FNAC) was carried out in the painful nodule with smooth surface and normochromic, with difficult oral access located in the soft palate. **(D)** Warthin tumor. FNAC was performed in a well circumscribed and asymptomatic nodular mass in the left parotid gland.

Table 2 – Association analysis between site, diagnostic category, and stains with methods to obtain the cell samples.

Variable	Method		P-value
	EC N (%)	FNAC N (%)	
Site (n = 1,071)			
Intraoral/lips region	309 (99.0)	139 (18.3)	< 0.001
Major salivary glands	0 (0.0)	261 (34.4)	
Gnathic bones	0 (0.0)	186 (24.5)	
Cervical region	1 (0.3)	146 (19.2)	
Facial region	2 (0.7)	27 (3.6)	
Diagnostic category (n = 1,082)			
Neoplasms	0 (0.0)	232 (30.1)	< 0.001
Cystic lesions	0 (0.0)	121 (15.7)	
Infectious diseases	163 (52.2)	34 (4.4)	
Reactional lesions	5 (1.6)	12 (1.6)	
Miscellaneous lesions	0 (0.0)	40 (5.2)	
Descriptive cases	144 (46.2)	331 (43.0)	
Stain (n = 1,082)			
Panoptic	0 (0.0)	770 (100.0)	< 0.001
Papanicolaou	0 (0.0)	770 (100.0)	< 0.001
HE	42 (13.5)	532 (69.1)	< 0.001
PAS	289 (92.6)	79 (10.3)	< 0.001
Ziehl-Neelsen	0 (0.0)	7 (0.9)	0.089
Mucicarmine	0 (0.0)	2 (0.3)	0.364
Grocott-Gromori	0 (0.0)	2 (0.3)	0.364

HE – hematoxylin-eosin; PAS – Periodic Acid-Schiff; EC – exfoliative cytology;
 FNAC – fine-needle aspiration cytology

In total, there were 65 different final cytologic diagnoses. **Table 3** shows the diagnostic categories for all cytological results and the most common diagnoses for each category. The most common diagnostic category was infectious diseases (n = 197; 18.2%), in which candidiasis was diagnosed in 129 cases (65.5%) and paracoccidioidomycosis in 35 cases (17.8%). The second most common category was cystic lesions (n = 121; 11.2%), with odontogenic keratocyst (n = 30; 24.8%) as the most frequent. Other recurrent diagnoses included pleomorphic adenoma (n = 64; 5.9%), metastatic squamous cell carcinoma (n = 56; 5.2%) and lipoma (n = 38 – 3.5%). **Figures 2 and 3** demonstrate cytological aspects of interesting cytologic diagnoses. In 475 samples (43.9%), a descriptive diagnosis was obtained. Descriptive diagnosis means when cytological smear showed a hemorrhagic component, scarce inflammatory cells, or nucleated epithelial cells leading a non-specific diagnosis.

Table 3 – Diagnostic categories for all specimens submitted for cytopathological diagnosis and most common diagnoses for each diagnostic category (2001-2018).

Diagnoses cases	Number of cases	% of group	% total
Benign epithelial neoplasia	91	100%	8.4%
Pleomorphic adenoma	64	70.3%	5.9%
Warthin tumor	14	15.4%	1.3%
Epithelial salivary gland neoplasm with basaloid cells	5	5.5%	0.5%
Benign salivary gland neoplasm	3	3.3%	0.3%
Malignant epithelial neoplasia	74	100%	6.8%
Metastatic squamous cell carcinoma	56	75.7%	5.2%
Mucoepidermoid carcinoma	9	12.2%	0.8%
Benign mesenchymal neoplasia	53	100%	4.9%
Lipoma	38	71.7%	3.5%
Hemangioma	10	18.9%	0.9%
Malignant mesenchymal neoplasia	2	100%	0.2%
Ewing sarcoma	1	50.0%	0.1%
Synovial sarcoma	1	50.0%	0.1%
Malignant lymphoid neoplasia	4	100%	0.4%
Hodgkin lymphoma	3	75.0%	0.3%
Non-Hodgkin lymphoma	1	25.0%	0.1%
Undifferentiated malignant neoplasia	8	100%	0.7%
Undifferentiated malignant neoplasm	8	100%	0.7%
Infectious diseases	197	100%	18.2%
Candidiasis	129	65.5%	11.9%
Paracoccidioidomycosis	35	17.8%	3.1%
Abscess	17	8.6%	1.6%
Lymphadenitis granulomatous	5	2.5%	0.5%
Cystic lesions	121	100%	11.2%
Odontogenic keratocyst	30	24.8%	2.8%
Epidermoid cyst	21	17.4%	1.9%
Salivary cystic lesion	19	15.7%	1.8%
Radicular cyst	9	7.4%	0.8%
Reactional lesions	17	100%	1.6%
Ranula	5	29.4%	0.5%
Mucocele	4	23.5%	0.4%
Non-specific chronic ulcer	3	17.6%	0.3%
Peripheral giant cell lesion	2	11.8%	0.2%
Miscellaneous lesions	40	100%	3.7%
Reactive lymph node	30	75.0%	2.8%
Central giant cell lesion	5	12.5%	0.5%
Descriptive	475	100%	43.9%
Total	1082		100%

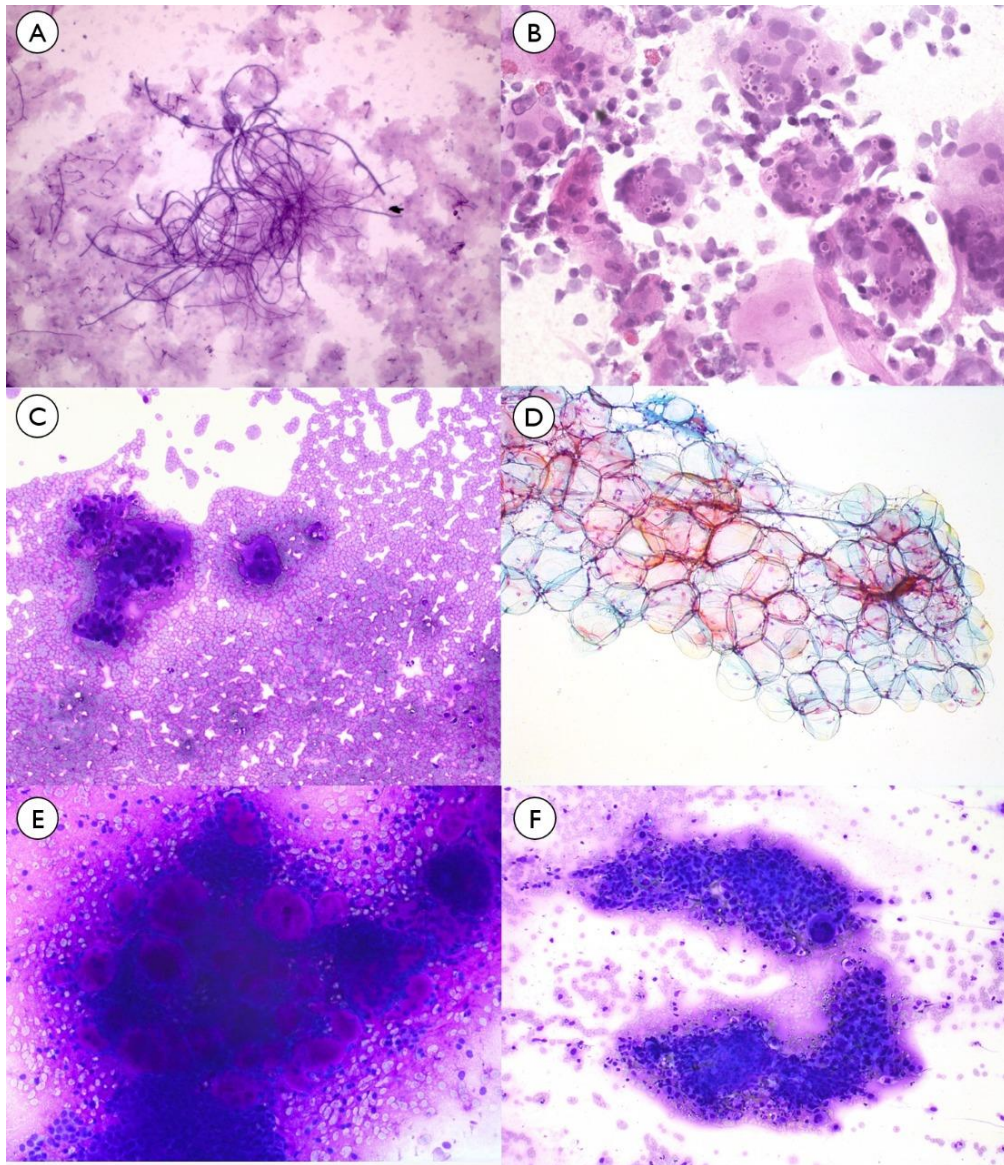


Figure 2 – Cytological features of cytological smears. **(A)** Candidiasis. *Candida sp* hyphae and nucleated epithelial cells (Periodic Acid-Schiff stain, 400x) **(B)** Paracoccidioidomycosis. Numerous oval to round fungal microorganisms within multinucleated giant cells (Hematoxylin-eosin stain, 400x). **(C)** Central giant cell lesion. Multinucleated giant cells immersed in a hemorrhagic background with scattered neutrophils (Panoptic stain, 100x). **(D)** Lipoma. Fatty tissue fragment with cells containing a single fat vacuole and small peripheral nucleus (Papanicolaou stain, 100x) **(E)** Adenoid cystic carcinoma. Hyaline globules admixed with small round to oval cells with hyperchromatic nuclei (Panoptic stain, 100x). **(F)** Metastatic squamous cell carcinoma. Numerous squamous cells, some of them with high pleomorphism (Panoptic stain, 100x).

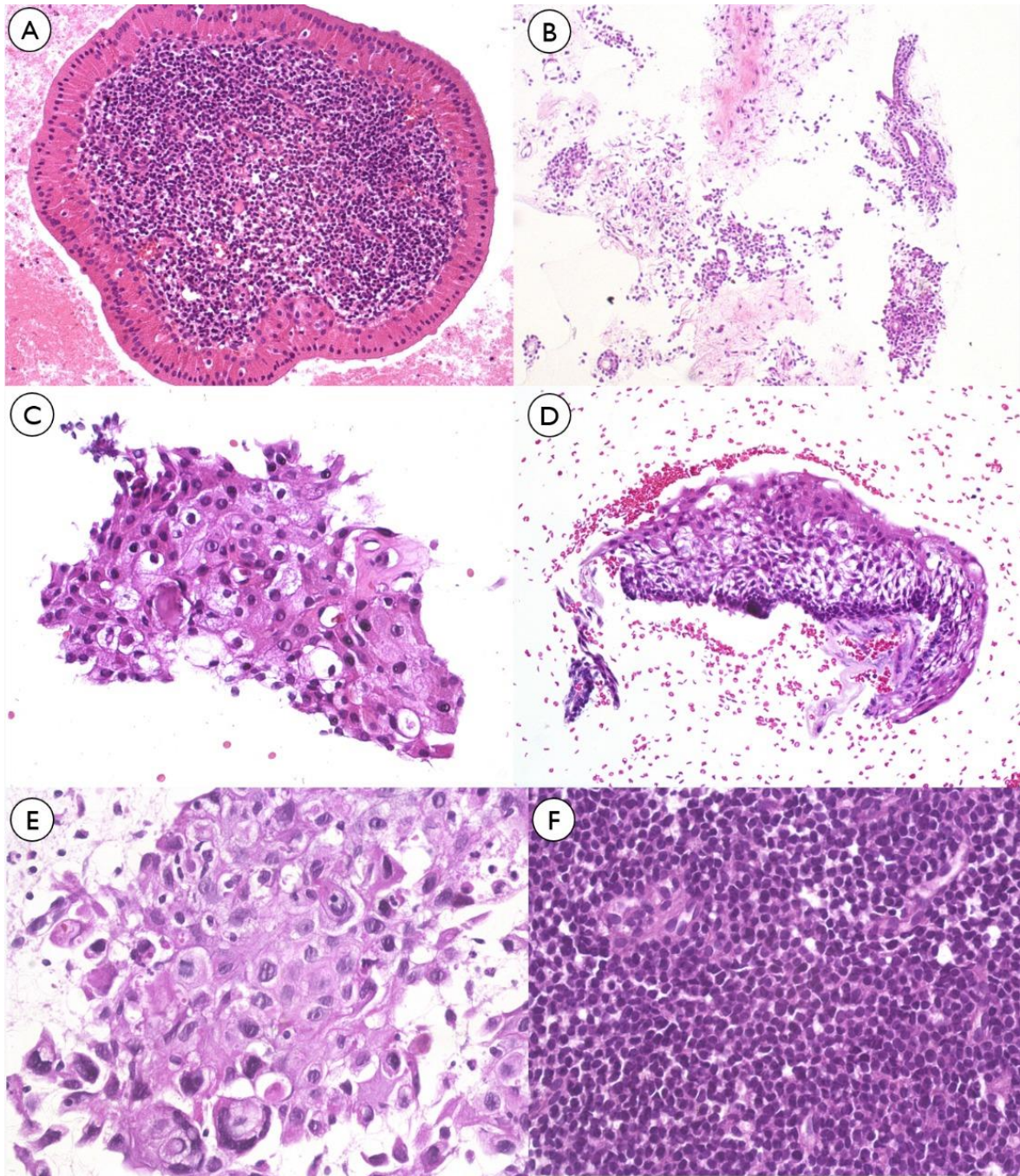


Figure 3 – Cytological features of cell block preparations. **(A)** Warthin tumor. Bi-layered of oncocytic epithelium cells enclosing a dense lymphocytic infiltrate (Hematoxylin-eosin [HE] stain, 200x). **(B)** Pleomorphic adenoma. Myoepithelial cells mixed with myxoid stroma and ducts (HE stain, 100x). **(C)** Mucoepidermoid carcinoma. Epidermoid, intermediate, and mucous cells (HE stain, 200x). **(D)** Ameloblastoma. Peripheral hyperchromatic palisading and central reticulum stellate pattern in a hemorrhagic background (HE stain, 200x). **(E)** Metastatic squamous cell carcinoma. Numerous squamous cells with high pleomorphism (HE stain, 400x). **(F)** Ewing sarcoma. Sheet of small, round, and uniform cells with scant cytoplasm (HE stain, 400x).

The cytohistologic correlations are summarised in **Table 4**. Of 1,082 specimens submitted to cytological diagnosis, 211 (19.5%) performed a biopsy in our centre, in which 85 cases (40.3%) were correlated to final histologic diagnosis. Within each diagnostic category, there was a higher agreement observed for infectious diseases (81.8%). Analysis of the malignant nature of neoplastic lesions revealed 11 TP, 7 TN, 2 FN, and 0 FP cases. Sensitivity, specificity, PPV, NPV and accuracy of the cytological exam for malignant neoplasms diagnosis were 84.6%, 100%, 100%, 77.8% and 90.0%, respectively.

Table 4 – Cytohistologic diagnosis correlation of 211 cases.

Diagnostic category	Method		Result		Total
	EC N (%)	FNAC N (%)	Agreed diagnosis between cytopathology and biopsy N (%)	Disagreed diagnosis between cytopathology and biopsy N (%)	
Infectious disease	33 (100.0)	0 (0.0)	27 (81.8)	6 (18.1)	33
Cystic lesions	0 (0.0)	30 (100.0)	19 (63.3)	11 (36.7)	30
Neoplasms	21 (100.0)	0 (0.0)	16 (76.2)	5 (23.8)	21
Reactional lesions	1 (33.3)	2 (66.7)	3 (100.0)	0 (0.0)	3
Miscellaneous lesions	0 (0.0)	1 (100.0)	1 (100.0)	0 (0.0)	1
Descriptive cases	23 (18.7)	100 (81.3)	19 (15.4)	104 (84.5)	123
Total	78 (37.0)	133 (63.0)	85 (40.3)	126 (59.7)	211 (100%)

EC – exfoliative cytology; FNAC – fine-needle aspiration cytology

Discussion

It is well recognised that histopathological exam is the gold standard for tissue diagnosis.¹⁴ However, simple and fast methods like cytology can be useful and contribute to correct therapeutic management. The use of cytopathology in the head and neck region has been proposed; however, in the oral cavity it remains controversial.³ Silva et al.¹⁵ highlighted the need to increase dentists' knowledge of EC and its use in diagnostic practices. The broad diagnoses of histopathological exam in oral and maxillofacial region have been previously investigated^{14,16}; however, no study was conducted to determine the uses of EC and FNAC in this region. Thus, we performed a retrospective analysis of cytological exams evaluated in our oral and maxillofacial diagnosis centre at Piracicaba Dental School in order to describe the wide range of cytology for tissue diagnosis in the head and neck region and oral cavity. To the best of our knowledge, this study comprises the largest cohort of oral and maxillofacial cytology ever described. This representative sample uncovered many crucial aspects of this diagnostic tool.

EC examines cells from the mucosal surface; it is a simple, pain-free, non-invasive, non-aggressive and rapid technique. The method is well tolerated by patients and is less stressful when compared to biopsy; thus, it can be widely used in screening programmes.¹⁷ EC is a popular diagnostic tool for screening uterine cervix cancer.¹⁸ The usefulness of oral EC has been mainly described in diagnosis of infectious diseases,¹⁹ such as candidiasis²⁰ and paracoccidioidomycosis.²¹ Consistent with these studies, the most common category diagnosed by EC in the present study was infectious diseases (163 cases), in which candidiasis (n = 129) and paracoccidioidomycosis (n = 35) were the most common lesions. Other infectious and reactional lesions, such as herpes and traumatic ulcers, were also identified in our survey. There is no consensus among

authors about the role of EC for screening premalignant lesions and oral cancer. A systematic review performed by Alsarraf et al.²² observed the need for well-designed clinical studies to assess the accuracy of oral brush cytology for the diagnosis and prediction of potentially malignant lesions and oral cancer. We did not perform EC for diagnosing oral pre-malignant lesions or oral cancer in our routine. Interestingly, we observed an association between EC and lesions from intraoral/lips region ($P < 0.001$). Overall, our results support that EC can assist the diagnosis of intraoral infectious diseases.

FNAC is performed in nodular swellings, mainly in those with difficult access. This method represents an important tool that allows for diagnosis and contribution to therapeutic management. It is a safe, simple, economical and well-tolerated outpatient procedure, with minimal pain or discomfort, that does not require local or general anaesthesia.²³ Moreover, FNAC is widely accepted by patients, a finding corroborated by our findings that demonstrated a wide range of patient's age, including children. FNAC is very popular among general pathologists, but among oral pathologists, it has not yet gained much popularity. Many professionals support that the oral cavity has easy access to open biopsy procedures and FNAC would not be needed in this site. Nevertheless, the lack of knowledge of diagnostic possibilities of FNAC in the oral cavity and experienced oral cytopathologists contributes to the underuse of this method.²⁴ In our analysis, we found 139 FNAC cases from intraoral/lips region, and this method led to the diagnosis of wide range of lesions, including mucocele, lipoma, haemangioma, giant cell lesion, minor salivary gland tumours and foreign body reaction, among others. Some of these cases have been previously published by our group.^{10,12} It is important to stress that a previous cytological diagnosis in many of these cases can contribute to the therapeutic management. For example, the confirmation of a

vascular or infectious lesion can obviate the need of a biopsy, and the patient can then receive sclerosing agents or antifungal drugs, respectively.

An advantage of FNAC is differentiating malignant swellings from benign non-tumoural processes.²⁵ Herein, we found 30 cases of reactive lymph nodes diagnosed by FNAC, which eliminated the hypothesis of lymphomas or metastasis. Regarding the use of FNAC for intraosseous lesions, the needle easily passes through the thinned bone cortices and can then contribute to the diagnosis of a variety of odontogenic and non-odontogenic lesions.^{8,26} In our cytological archive, several different intraosseous lesions were diagnosed by FNAC, including ameloblastoma, odontogenic keratocyst, periapical/inflammatory cyst, central giant cell lesion, simple bone cyst and Ewing sarcoma, among others. This wide range of diagnosis include reactive lesions, developmental and inflammatory odontogenic cysts and benign and malignant tumours, and highlight the enormous benefits of FNAC by allowing for better preoperative planning. Moreover, FNAC can be performed in inoperable lesions and cases with difficult access due to anatomical aspects or patients' limitations.²³

The most common stains used in cytology are Romanowsky-type stains (Panoptic) and Papanicolaou. Panoptic staining is used in air-dried smears and Papanicolaou in slides fixed in 95% alcohol. HE staining can also be used, mainly in CB preparations,²⁷ In our study, all cytological smears from FNAC were stained with Panoptic and Papanicolaou because these stains are used routinely in cytology. HE stain was the third most common stain, performed in 574 cases (53.0%). Santos et al.²⁷ evaluated the different stain techniques in FNAC; they found that HE stain showed better accuracy to provide a definitive diagnosis, followed by Papanicolaou and Panoptic stains. Slides fixed in alcohol and formalin, such as those used for Papanicolaou and HE staining, presented better preservation of cell morphologies.

Additional stains were performed in our study in both EC and FNAC specimens in order to guide the cytological diagnosis, such as PAS (n = 368; 34.0%), Ziehl-Neelsen (n = 7; 0.6%), mucicarmine (n = 2; 0.2%) and Grocott-Gomori methenamine silver stain (n = 2; 0.2%). Associating EC and FNAC with stains, there was a positive correlation between PAS with EC ($P > 0.001$) and between HE with CB preparations from FNAC ($P < 0.001$).

In our routine, 548 FNAC cases performed CB. This technique is simple and can be performed in the remaining sample after cytological smear slide preparation. CB combines the advantages of histology and cytology and leads to recognition of patterns viewed in histological slides.^{28,29} Anderson et al.³⁰ found in head and neck cytology that CB provided additional diagnostic information in 31% of cases and was essential for making the correct diagnosis in 12% of cases. Carter et al.²⁸ observed a reduction in FN and increase in TP diagnoses. Thus, routine CB preparation on FNAC can contribute for final cytologic diagnosis in FNAC cases. Additionally, we found 14 cases, derived from CB preparations, that performed immunohistochemistry to support the final cytologic diagnosis. Most reports of the use of immunohistochemical is on frozen or paraffin-embedded tumour tissues. However, the application of immunohistochemistry in cytology has been reported in some studies.^{29,31} Brifford et al.³² evaluated immunohistochemistry on CB from FNAC of primary breast carcinomas and found that CB preparations immunostaining had good quality and was free of artifacts, such as excessive background; it was useful for marker detection. Thus, immunohistochemical markers are useful in FNAC from CB preparations because the samples have a representative material of the lesions for analysis.³²

In the present study we determined the sensitivity, specificity, PPV, NPV and accuracy of cytological exam for the diagnosis of malignant neoplasms were 84.6%,

100%, 100%, 77.8% and 90.0%, respectively. These results support that cytological exam can help to distinguish benign from malignant processes in both head and neck and the oral cavity region. A study performed by Ghandi et al.⁴ also reported high specificity (95.45%) and sensitivity (93.75%) of FNAC for oral lesions. Díaz et al.³³ analysed FNAC for diagnosing salivary gland tumours and observed sensitivity, specificity, PPV, NPV and diagnostic accuracy of 94%, 100%, 100%, 100% and 99%, respectively. In cytohistologic correlation of 211 cases, we found 85 (40.3%) cases of cytological exam that achieved the same diagnosis in histological exam. Yet, is important to stress that this percentage occurred mostly because of the number of descriptive cases in cytology that did not correlate with a final histological diagnosis. If we exclude the 123 descriptive cases, the agreement percentage reaches 75%. It is also important to highlight that 81.3% of descriptive cases were from FNAC, which in some cases depends on correlation of cytological findings and clinical information.³⁴ Infectious diseases and neoplasms reached a strong concordance between cytologic and histologic diagnosis. Cystic lesions represented the diagnostic category with the least concordance in cytohistologic correlation, perhaps due to the paucity of specific lesion cells. Cystic lesions of salivary glands had sensitivity of 41.6% in a study performed by Alison et al.,³⁵ and this value was related to a broad differential diagnosis and low cellularity of the cystic lesions. However, Baykul et al.³⁶ found that the accuracy of FNAC diagnosis in oral and maxillofacial cystic lesions was as successful as in the solid lesions. Additionally, it is important to highlight that among the 123 descriptive cytological diagnoses, 19 cases (15.4%) remained descriptive in the final histologic diagnosis. This finding emphasises that both techniques have limitations and depend of various factors, including adequate sample and procedural techniques.

In summary, EC and FNAC are useful diagnostic tools for diagnosing infectious diseases and salivary gland tumours, odontogenic lesions, reactive lesions and cervical metastatic neoplasms. Further studies in this field are needed to increase its applicability worldwide.

References

1. Dolens ES, Nakai FVD, Parizi JLS, Nai GA. Cytopathology: A Useful Technique for Diagnosing Oral Lesions?: A Systematic Literature Review. *Diagn Cytopathol* 2012;41(6):505-514.
2. Al-Abadi MA. Basics of cytology. *Avicenna J Med* 2011;1(1):18–28.
3. Santos APC, Sugaya NN, Pinto Júnior DS, Lemos Júnior CA. Fine needle aspiration biopsy in the oral cavity and head and neck region. *Braz Oral Res* 2011;25(2):186-191.
4. Gandhi S, Lata J, Gandhi N. Fine needle aspiration cytology: a diagnostic aid for oral lesions. *J Oral Maxillofac Surg* 2011;69(6):1668-1677.
5. Xavier-Júnior JCC, Camilo-Júnior DJ, D'Ávilla SCGP, Mattar NJ. Fine-needle aspiration of the Warthin-like variant of papillary thyroid carcinoma: A report of three cases. *Diagn Cytopathol* 2019 Sep 12. doi: 10.1002/dc.24292.
6. Fregnani ER, Gerhard R, da Cruz Perez DE, Lopes MA, Jorge J, Vargas PA. Cytological features of intraoral tumour. *Cytopathology*. 2006;17(4):205-9.
7. Houcine Y, Romdhane E, Blel A, et al. Evaluation of fine needle aspiration cytology in the diagnosis of cervical lymph node lymphomas. *J Craniomaxillofac Surg* 2018;46(7):1117-1120.
8. Vargas PA, da Cruz Perez DE, Mata GM, de Almeida OP, Jones AV, Gerhard R. Fine needle aspiration cytology as an additional tool in the diagnosis of odontogenic keratocyst. *Cytopathology* 2007;18(6):361-366.
9. González-Arriagada WA, Santos-Silva AR, Vargas PA, Lopes MA. Diagnostic approach to intramasseteric nodules. *Oral Surg Oral Med Oral Pathol Oral Radiol* 2017;123(1):16-21.
10. Faria KM, Fonseca FP, Silva WG, et al. Fine needle aspiration cytology in the diagnosis of perioral adverse reactions to cosmetic dermal fillers. *Oral Surg Oral Med Oral Pathol Oral Radiol* 2014;117(5):393-395.
11. Vargas PA, Prado FO, Fregnani ER, et al. Fine needle aspiration biopsy in central giant cell lesion: a report of 3 cases. *Acta Cytol* 2006;50(4):449-454.

12. Fonseca FP, Ribeiro AC, Santos-Silva AR, Vargas PA. Fine needle aspiration cytology and intralesional steroid injection in a central giant cell granuloma affecting the gingiva: a new clinical approach. *Braz Dent J* 2013;24(4):420-427.
13. Florkowski CM. Sensitivity, specificity, receiver-operating characteristic (ROC) curves and likelihood ratios: communicating the performance of diagnostic tests. *Clin Biochem Rev* 2008;29(1):83–87.
14. Franklin CD, Jones AV. A survey of oral and maxillofacial pathology specimens submitted by general dental practitioners over a 30-year period. *Br Dent J* 2006;200(8):447-450.
15. Silva WA, Lima AP, Vasconcellos LMR, Anbinder AL. (2014). Evaluation of dentists' knowledge of the use of oral exfoliative cytology in clinical practice. *Braz Oral Res* 2014;28(1): 1-7.
16. Kelloway E, Ha WN, Dost F, Farah CS. A retrospective analysis of oral and maxillofacial pathology in an Australian adult population. *Aust Dent J* 2014;59(2):215-220.
17. Kazanowska K, Hálon A, Radwan-Oczko M. The Role and Application of Exfoliative Cytology in the Diagnosis of Oral Mucosa Pathology – Contemporary Knowledge with Review of the Literature. *Adv Clin Exp Med* 2014;23(2):299–305.
18. Gupta P, Gupta N, Dey P. Morphometric analysis of endometrial cells in liquid-based cervical cytology samples. *Cytopathology* 2017;28(2):140-148.
19. Silva AR, Vargas PA, Ribeiro AC, Martinez-Mata G, Coletta RD, Lopes MA. Fine-needle aspiration cytology in the diagnosis of cervical tuberculosis and paracoccidioidomycosis. *Cytopathology* 2010;21(1):66-68.
20. Loss R, Sandrin R, França BH, et al. Cytological analysis of the epithelial cells in patients with oral candidiasis. *Mycoses* 2011;54(4):130-135.

21. Talhari C, de Souza JV, Parreira VJ, Reinel D, Talhari S. Oral exfoliative cytology as a rapid diagnostic tool for paracoccidioidomycosis. *Mycoses* 2008;51(2):177-178.
22. H Alsarraf A, Kujan O, Farah CS. The utility of oral brush cytology in the early detection of oral cancer and oral potentially malignant disorders: A systematic review. *J Oral Pathol Med* 2018;47(2):104-116.
23. O'Donnell ME, Salem A, Badger SA, et al. Fine needle aspiration at a Regional Head and Neck Clinic: a clinically beneficial and cost-effective service. *Cytopathology* 2009;20(2):81-86.
24. Rammeh S, Romdhane E, Sassi A, et al. Accuracy of fine-needle aspiration cytology of head and neck masses. *Diagn Cytopathol* 2019;47(5):394-399.
25. Cozzolino I, Vigliar E, Todaro P, et al. Fine needle aspiration cytology of lymphoproliferative lesions of the oral cavity. *Cytopathology* 2014;25(4):241-249.
26. Shergill U, Vitkovski T, Stoffels G, et al. Fine-needle aspiration biopsy of lytic bone lesions: An institution's experience. *Diagn Cytopathol* 2017;45(11):989-997.
27. Santos APC, Sugaya NN, Pinto Jr DS, Lemos Jr CA. Evaluation of fine needle aspiration biopsy in oral cavity and head and neck region with different stains techniques. *Braz Oral Res* 2015;29(1):1-7.
28. Carter MD, Moore DP, MacIntosh RF, Bullock MJ. Impact of routine cell block preparation on results of head and neck fine needle aspirates. *Diagn Cytopathol* 2016;44(11):880-887.

29. Grosse C, Noack P, Silye R. Accuracy of grading pancreatic neuroendocrine neoplasms with Ki-67 index in fine-needle aspiration cellblock material. *Cytopathology* 2019;30(2):187–193.
30. Anderson CE, Duvall E, Wallace WA. A single ThinPrep slide may not be representative in all head and neck fine needle aspirate specimens. *Cytopathology* 2009;20(2):87–90.
31. Fowler LJ, Lachar WA. Application of immunohistochemistry to cytology. *Arch Pathol Lab Med* 2008;132(3):373-383.
32. Briffod M, Hacène K, Le Doussal V. Immunohistochemistry on cell blocks from fine-needle cytopunctures of primary breast carcinomas and lymph node metastases. *Mod Pathol* 2000;13(8):841-850.
33. Díaz KP, Gerhard R, Domingues RB, et al. High diagnostic accuracy and reproducibility of fine-needle aspiration cytology for diagnosing salivary gland tumors: cytohistologic correlation in 182 cases. *Oral Surg Oral Med Oral Pathol Oral Radiol* 2014;118(2):226-235.
34. Pantanowitz L, Thompson LDR, Rossi ED. Diagnostic Approach to Fine Needle Aspirations of Cystic Lesions of the Salivary Gland. *Head Neck Pathol* 2018;12(4):548-561.
35. Allison DB, McCuiston AM, Kawamoto S, Eisele DW, Bishop JA, Maleki Z. Cystic major salivary gland lesions: Utilizing fine needle aspiration to optimize the clinical management of a broad and diverse differential diagnosis. *Diagn Cytopathol* 2017;45(9):800-807.
36. Baykul T, Colok G, Gunhan O. The value of aspiration cytology in cystic lesions of the maxillofacial region. *Eur J Dent* 2010;4(1):1-5.

3 CONCLUSÃO

Os resultados do presente estudo permitem concluir que:

- A citopatologia realizou diagnósticos de diferentes lesões na região oral e maxilofacial, mostrando ser um exame complementar útil na clínica de Estomatologia;
- A citologia esfoliativa é realizada em lesões sem aumento de volume, como úlceras, placas, pápulas e crosta, e contribui para o diagnóstico de lesões infecciosas da cavidade oral e região da cabeça e pescoço;
- A punção aspirativa por agulha fina é realizada em nódulos na região oral e maxilofacial, sendo extremamente útil para diferenciar neoplasias malignas de neoplasias benignas, e identificar lesões císticas e reativas.

REFERÊNCIAS¹

Al-Abbadi MA. Basics of cytology. *Avicenna J Med* 2011;1(1):18–28.

Díaz KP, Gerhard R, Domingues RB, et al. High diagnostic accuracy and reproducibility of fine-needle aspiration cytology for diagnosing salivary gland tumors: cytohistologic correlation in 182 cases. *Oral Surg Oral Med Oral Pathol Oral Radiol* 2014;118(2):226-235.

Dolens ES, Nakai FVD, Parizi JLS, Nai GA. Cytopathology: A Useful Technique for Diagnosing Oral Lesions?: A Systematic Literature Review. *Diagn Cytopathol* 2012;41(6):505-514.

Faria KM, Fonseca FP, Silva WG, et al. Fine needle aspiration cytology in the diagnosis of perioral adverse reactions to cosmetic dermal fillers. *Oral Surg Oral Med Oral Pathol Oral Radiol* 2014;117(5):393-395.

Fonseca FP, Ribeiro AC, Santos-Silva AR, Vargas PA. Fine needle aspiration cytology and intralesional steroid injection in a central giant cell granuloma affecting the gingiva: a new clinical approach. *Braz Dent J* 2013;24(4):420-427.

Franklin CD, Jones AV. A survey of oral and maxillofacial pathology specimens submitted by general dental practitioners over a 30-year period. *Br Dent J* 2006;200(8):447-450.

Fregnani ER, Gerhard R, da Cruz Perez DE, Lopes MA, Jorge J, Vargas PA. Cytological features of intraoral tumour. *Cytopathology*. 2006;17(4):205-9.

Gandhi S, Lata J, Gandhi N. Fine needle aspiration cytology: a diagnostic aid for oral lesions. *J Oral Maxillofac Surg* 2011;69(6):1668-1677.

¹De acordo com as normas da UNICAMP/FOP, baseadas na padronização do International Committee of Medical Journal Editors - Vancouver Group. Abreviatura dos periódicos em conformidade com o PubMed.

Houcine Y, Romdhane E, Blel A, et al. Evaluation of fine needle aspiration cytology in the diagnosis of cervical lymph node lymphomas. *J Craniomaxillofac Surg* 2018;46(7):1117-1120.

Kazanowska K, Hálon A, Radwan-Oczko M. The Role and Application of Exfoliative Cytology in the Diagnosis of Oral Mucosa Pathology – Contemporary Knowledge with Review of the Literature. *Adv Clin Exp Med* 2014;23(2):299–305.

Kelloway E, Ha WN, Dost F, Farah CS. A retrospective analysis of oral and maxillofacial pathology in an Australian adult population. *Aust Dent J* 2014;59(2):215-220.

Loss R, Sandrin R, França BH, et al. Cytological analysis of the epithelial cells in patients with oral candidiasis. *Mycoses* 2011;54(4):130-135.

Santos APC, Sugaya NN, Pinto Júnior DS, Lemos Júnior CA. Fine needle aspiration biopsy in the oral cavity and head and neck region. *Braz Oral Res* 2011;25(2):186-191.

Silva AR, Vargas PA, Ribeiro AC, Martinez-Mata G, Coletta RD, Lopes MA. Fine-needle aspiration cytology in the diagnosis of cervical tuberculosis and paracoccidioidomycosis. *Cytopathology* 2010;21(1):66-68.

Silva WA, Lima AP, Vasconcellos LMR, Anbinder AL. (2014). Evaluation of dentists' knowledge of the use of oral exfoliative cytology in clinical practice. *Braz Oral Res* 2014;28(1): 1-7.

Vargas PA, da Cruz Perez DE, Mata GM, de Almeida OP, Jones AV, Gerhard R. Fine needle aspiration cytology as an additional tool in the diagnosis of odontogenic keratocyst. *Cytopathology* 2007;18(6):361-366.

Xavier-Júnior JCC, Camilo-Júnior DJ, D'Ávilla SCGP, Mattar NJ. Fine-needle aspiration of the Warthin-like variant of papillary thyroid carcinoma: A report of three cases. *Diagn Cytopathol* 2019 Sep 12. doi: 10.1002/dc.24292

ANEXOS

Anexo 1 - Verificação de originalidade e prevenção de plágio

APLICAÇÃO DA CITOPATOLOGIA NO DIAGNÓSTICO DE
LESÕES ORAIS E MAXILOFACIAIS: UMA ANÁLISE
RETROSPECTIVA DE 18 ANOS

RELATÓRIO DE ORIGINALIDADE

12% ÍNDICE DE SEMELHANÇA	8% FONTES DA INTERNET	10% PUBLICAÇÕES	5% DOCUMENTOS DOS ALUNOS
------------------------------------	---------------------------------	---------------------------	------------------------------------

FONTES PRIMÁRIAS

1	Díaz, Katya Pulido, Renê Gerhard, Regina Barros Domingues, Leandro Liporoni Martins, Ana Carolina Prado Ribeiro, Márcio Ajudarte Lopes, Paulo Campos Carneiro, and Pablo Agustin Vargas. "High diagnostic accuracy and reproducibility of fine-needle aspiration cytology for diagnosing salivary gland tumors: cytohistologic correlation in 182 cases", Oral Surgery Oral Medicine Oral Pathology and Oral Radiology, 2014. Publicação	1%
2	www.scielo.br Fonte da Internet	1%
3	repositorio.unicamp.br Fonte da Internet	1%
4	www.pubfacts.com Fonte da Internet	1%

Anexo 2 - Certificado do Comitê de Ética em Pesquisa





COMITÊ DE ÉTICA EM PESQUISA
FACULDADE DE ODONTOLOGIA DE PIRACICABA
UNIVERSIDADE ESTADUAL DE CAMPINAS

CERTIFICADO

O Comitê de Ética em Pesquisa da FOP-UNICAMP certifica que o projeto de pesquisa "Estudo retrospectivo dos casos diagnosticados por citopatologia no laboratório de patologia oral e maxilofacial da FOP-UNICAMP", CAAE 86606318.9.0000.5418, dos pesquisadores Maria Eduarda Pérez de Oliveira, Pablo Agustín Vargas e Vivian Petersen Wagner, satisfaz as exigências das resoluções específicas sobre ética em pesquisa com seres humanos do Conselho Nacional de Saúde – Ministério da Saúde e foi aprovado por este comitê em 03/05/2018.

The Research Ethics Committee of the Piracicaba Dental School of the University of Campinas (FOP-UNICAMP) certifies that research project "Retrospective study of cases diagnosed by cytopathology in the laboratory of oral and maxillofacial pathology of FOP-UNICAMP", CAAE 86606318.9.0000.54188606318.9.0000.5418, of the researcher's Maria Eduarda Pérez de Oliveira, Pablo Agustín Vargas e Vivian Petersen Wagner, meets the requirements of the specific resolutions on ethics in research with human beings of the National Health Council - Ministry of Health, and was approved by this committee on May, 05 2019.



Profa. Fernanda Miori Pascon
 Vice Coordenador
 CEP/FOP/UNICAMP



Prof. Jacks Jorge Junior
 Coordenador
 CEP/FOP/UNICAMP

Nota: O título do protocolo e a lista de autores aparecem como fornecidos pelos pesquisadores, sem qualquer edição.
 Notice: The title and the list of researchers of the project appears as provided by the authors, without editing.

Anexo 3 - Comprovante de submissão do artigo à revista Cytopathology

Submission Confirmation

 Print

Thank you for your submission

Submitted to
Cytopathology

Manuscript ID
CYT-2019-0213

Title
Overview of cytopathology in the oral and maxillofacial region: 18-year experience

Authors
Pérez-de-Oliveira, Maria Eduarda
Wagner, Vivian
AMARAL-SILVA, Gleyson
Leite, Amanda
Lopes, Márcio
Silva, Alan Roger
Jorge Júnior, Jacks
Almeida, Oslei
Vargas, Pablo

Date Submitted
05-Nov-2019