

## CASE STUDY

## *Fasciolopsis buski* Vomited Out by a Child; The First Case Reported from Nepal

Narayan Dutt Pant<sup>1\*</sup>, Manisha Sharma<sup>2</sup>, Saroj Khatiwada<sup>3</sup><sup>1</sup>Department of Microbiology Grande International Hospital, Dhapasi, Kathmandu, Nepal<sup>2</sup>Department of Microbiology, Kathmandu medical college, Kathmandu, Nepal<sup>3</sup>CIST College, Kathmandu, Nepal

### Abstract

Live adult worms of *Fasciolopsis buski* are rarely seen in humans except in autopsy. Only a few such cases have been reported in the world literature. We reported a case of fasciolopsiasis in a child of age 14 months who coughed out the live adult *Fasciolopsis buski* after administration of antihelminthic drug. The patient was a resident of Terai (Far Western) region of Nepal and had history of travelling to India. This is the first case of fasciolopsis reported from Nepal.

**Key words:** Fasciolopsiasis, Nepal, antihelminthic drug, diarrhea.

**\*Corresponding author**

**Email:** [ndpant1987@gmail.com](mailto:ndpant1987@gmail.com)

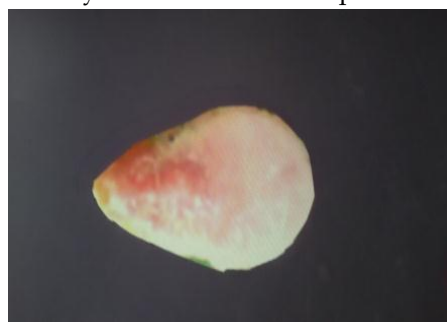
### Introduction

Fasciolopsiasis is a gastrointestinal infestation by a trematode; *Fasciolopsis buski* mainly involving duodenum and jejunum. The fluke is the largest intestinal fluke parasitizing humans and was first noted by Busk in 1943 from the duodenum of a deceased Indian sailor. Fasciolopsiasis is prevalent in various parts of South East Asia including the neighboring countries China and India. The infections by *Fasciolopsis buski* are common in impoverished countries where proper sanitation systems are lacking [1]. The disease occurs due to ingestion of encysted metacercariae on aquatic vegetation or direct water [2]. Mostly the infection is asymptomatic but in severe infection the common symptoms are abdominal pain, diarrhea, low-grade fever, toxemia, allergy, anemia, ascites, generalized edema, obstruction of intestine sometimes leading to death [1, 3]. Diagnosis is made by detection of eggs in stool but the differentiation between *Fasciolopsis buski* and *Fasciola hepatica* is very difficult in routine examination of stool [1]. Here we report a case of fasciolopsiasis in a child of age 14 months who coughed out the live adult *Fasciolopsis buski* after administration of antihelminthic drug. This is the first case of fasciolopsis reported from Nepal.

### Case report:

A 14 months male child attended outpatient department with the chief complain of diarrhea, vomiting, refusal to eat, fever, irritability, and weakness. The child was a resident of Terai (Far Western) region of Nepal and had travel history to

Lucknow, India for treatment of urinary tract infection and follow up for the treatment of epilepsy. The patient was under medication (ofloxacin and carbamazepine). He had significant leucocytosis (14000 cells/mm<sup>3</sup>) with eosinophilia (12%). Stool routine examination and culture didn't reveal any significant findings. Since the patient was already in broad spectrum antibiotic for treatment of urinary tract infection the possibility of bacteria being the cause of the illness was quite low. So the patient was given metronidazole and mebendazole to cover all other possible causes of the diarrhea. After around 12 hours of administration of the medication the patient vomited out a moving worm of size 30×19 mm<sup>2</sup>, leaf shaped with anterior end narrower and the posterior end broadly rounded, dorsoventrally flattened, unsegmented and flesh colored (**Figure 1**). The worm was identified as *Fasciolopsis buski* on the basis of the morphological characteristics such as lack of cephalic cone, poorly-developed suckers (oral and ventral) and the unbranched ceca. All symptoms subsided after the full course of treatment and total leucocyte counts and eosinophil counts became normal.



**Figure 1.** *Fasciolopsis buski* vomited out by the child.

## Discussion

Fasciolopsiasis is endemic in India, cases being reported mainly from areas including Bihar and Uttar Pradesh but no cases have been yet reported from Nepal which is surprising as those areas are connected with the Terai region of Nepal with open borders and shares cultural and geographical similarities [4]. The cases may have been underdiagnosed due to poor health facility and hence unreported. In the country like Nepal where the open defecation around the water bodies is common and the pigs are kept in close contact with humans the prevalence of the disease may be alarming as the habit of eating aquatic vegetation and drinking untreated water is common in Nepal. So a study is necessary to determine the prevalence of the *Fasciolopsis buski* infection at least in the areas of Nepal which are connected with the high prevalence area of India.

The child had history of drinking water from a pond during his stay in India. So it is high chance that the child may have got infection from the water he drank from the pond as no other history which might involve the risk of getting infection by *Fasciolopsis buski* could be elucidated. Live adult worms of this parasite are very rarely seen in humans except in autopsy [5]. There are two more reports of live adult worms being vomited out [1, 5]. Other cases of live adult worms causing different clinical conditions are reported by Cao et al. [2], Mahajan et al. [4] and Lee et al. [6]. The present case raises the possibility of unidentified cases of fasciolopsiasis in Nepal.

## Conclusion

With reporting of this case it can be concluded that the cases of fasciolopsiasis are possible in Nepal and it should also be considered as differential diagnosis in case of the suspected patients with gastrointestinal symptoms.

## Competing interests

The authors declare that they have no competing interests.

## Statement Regarding the Patient's Consent

Patient's guardian's consent was taken for the publication of this case report.

## References

1. Mohanty I, Narasimham MV, Sahu S, Panda P, Parida B: **Live *Fasciolopsis buski* vomited out by a boy.** *Ann Trop Med Public Health* 2012,5:403-405.
2. Cao YH, Ma YM, Qiu F, Zhang XQ: **Rare cause of appendicitis: Mechanical obstruction due to *Fasciolopsis buski* infestation.** *World J Gastroenterol* 2015,21(10):3146-3149.
3. Sen-Hai Y, Mott KE: **Epidemiology and morbidity of food borne intestinal trematodes infections.** *Trop Dis Bull* 1994, 91:r126-r150.
4. Mahajan RK, Duggal S, Biswas NK, Duggal N, Hans C: **A finding of live *Fasciolopsis buski* in an ileostomy opening.** *J Infect Dev Ctries* 2010,4(6):401-403.
5. Le TH, Nguyen VD, Phan BU, Blair D, McManus DP: **Case report: unusual presentation of *Fasciolopsis buski* in a Vietnamese child.** *Trans R Soc Trop Med Hyg* 2004, 98(3):193-194.
6. Lee TH, Huang CT, Chung CS: **Gastrointestinal: *Fasciolopsis buski* infestation diagnosed by upper gastrointestinal endoscopy.** *Journal of Gastroenterology and Hepatology* 2011, 26(9):1464.