

We are IntechOpen, the world's leading publisher of Open Access books Built by scientists, for scientists

5,300

Open access books available

130,000

International authors and editors

155M

Downloads

Our authors are among the

154

Countries delivered to

TOP 1%

most cited scientists

12.2%

Contributors from top 500 universities



WEB OF SCIENCE™

Selection of our books indexed in the Book Citation Index
in Web of Science™ Core Collection (BKCI)

Interested in publishing with us?
Contact book.department@intechopen.com

Numbers displayed above are based on latest data collected.
For more information visit www.intechopen.com



New Technologies to Improve Surgical Outcome during Open-Cranial Vault Remodeling

David García-Mato, Javier Pascau and Santiago Ochandiano

Abstract

Current approaches for the surgical correction of craniosynostosis are highly dependent on surgeon experience. Therefore, outcomes are often inadequate, causing suboptimal esthetic results. Novel methods for cranial shape analysis based on statistical shape models enable accurate and objective diagnosis from preoperative 3D photographs or computed tomography scans. Moreover, advanced algorithms are now available to calculate a reference cranial shape for each patient from a multi-atlas of healthy cases, and to determine the most optimal approach to restore normal calvarial shape. During surgery, multiple technologies are available to ensure accurate translation of the preoperative virtual plan into the operating room. Patient-specific cutting guides and templates can be designed and manufactured to assist during osteotomy and remodeling. Then, intraoperative navigation and augmented reality visualization can provide real-time guidance during the placement and fixation of the remodeled bone. Finally, 3D photography enables intraoperative surgical outcome evaluation and postoperative patient follow-up. This chapter summarizes recent literature on all these technologies, showing how their integration into the surgical workflow could increase reproducibility and reduce inter-surgeon variability in open cranial vault remodeling procedures.

Keywords: craniosynostosis, surgery, shape analysis, computer-assisted planning, outcome evaluation

1. Introduction

Craniosynostosis is a birth defect defined as the premature closure of one or more cranial sutures [1]. Compensatory growth of the brain along the non-fused sutures produces morphological abnormalities, including dysmorphic cranial vault and facial asymmetry, which can lead to severe conditions such as increased intracranial pressure and impaired brain growth [2]. Prevalence studies indicate that craniosynostosis affects 1 of every 2000–2500 live births worldwide [3, 4].

Although the management of craniosynostosis has significantly improved, surgical correction is the preferred approach for treatment in most cases. The objective of surgical correction is to release the fused suture and to normalize calvarial shape. Minimally invasive techniques (endoscopic, linear craniectomy) have been proposed as an alternative to open surgery [5]. These procedures are usually followed by postoperative helmet-molding therapy to facilitate appropriate changes in the

cranial morphology [6]. However, these limited approaches are typically reserved for the treatment of mild-to-moderate deformities affecting young patients (less than 6 months old) [2].

The rest of the cases are commonly treated through open cranial vault remodeling, which aims to normalize the calvarial shape to increase intracranial volume and reduce the risk of elevated intracranial pressure. Typical cranial vault remodeling begins with a coronal incision to allow exposure of the calvarial surface. Then, osteotomy of multiple segments in the affected bone region is performed and the different fragments are reconfigured to achieve a normal cranial morphology. Finally, the remodeled bone fragments are transferred to the patient and rigidly fixed and secured using resorbable plates [7, 8]. This operation is typically performed before the first year of life to maximize reossification and to benefit from the malleability of the bone tissue [9].

Distraction osteogenesis is an alternative surgical approach for the treatment of craniosynostosis, which has been accepted by many surgeons [10]. This technique involves the application of graduated tension to the bone tissue using external fixation devices. The main advantage of this procedure is the reduced invasiveness in comparison with open cranial vault remodeling, since the dissection of the dura is limited [11]. However, it shows limitations such as long treatment duration and, in some cases, secondary surgical interventions.

Nowadays, diagnosis and surgical correction of craniosynostosis are still highly dependent on the subjective assessment and artistic judgment of surgeons [12]. They must determine the degree of the deformity and the best approach for remodeling of the cranial vault to restore normal calvarial shape. As a result, there exists a high variability in the performance of surgeons and, thus, in the surgical outcomes. Although optimal surgical results may be achieved by the more experienced craniofacial surgeons, more complications may arise among the less experienced. Several studies, evaluating the long-term postoperative results after surgical correction between 1987 and 2013, have reported complication rates varying between 2% and 23.3%, and reoperation rates as high as 10–36% [13–19]. In addition, these studies reported that between 9.9% and 36% of the patients presented moderate-to-severe malformations after surgical treatment, causing suboptimal esthetic outcomes (Whitaker class III/IV).

Therefore, there is a clinical need to improve the reproducibility of surgical outcomes and to reduce intersurgeon variability in craniosynostosis surgery. Multiple technological advancements are now available to improve diagnosis, preoperative planning, surgical performance, and postoperative evaluation of craniosynostosis patients. However, recent literature presenting and comparing alternative technologies to assist during craniosynostosis surgery is not available and, as a result, craniofacial surgeons may not be aware of these advances. This chapter aims to provide an overview of the different developments in the field of craniosynostosis through a detailed review and analysis of the literature.

2. Cranial shape analysis and diagnosis

Although the fusion of sutures is a clear indication of craniosynostosis in most cases, an evaluation of the cranial shape abnormality is crucial to determine the need for surgical correction. However, there are no objective methods available in the clinical practice to quantify cranial malformations, making the diagnosis and the virtual surgical planning highly dependent on the surgeon's expertise [20].

The analysis of the preoperative morphology is the most critical step when planning surgery [21]. A 3D volumetric evaluation of the patient's anatomy in comparison with normal morphology is essential to comprehend the basis of the cranial

malformations and to determine the best approach for surgical correction. In this context, several methods based on statistical shape models have been proposed to objectify diagnosis and planning in craniosynostosis. The idea of these approaches is to define the normal cranial shape from a dataset of healthy subjects and to compare it with the pathological shape of the subject under evaluation to provide a patient-specific diagnosis and reference for planning.

Saber et al. [22] generated a library of normative pediatric skulls from computed tomography (CT) scans of 103 healthy subjects. Each CT scan was segmented, and a set of reference points was distributed onto the outer surface of the skull. Then, all 3D models were aligned and an average composite skull, “super-skull”, was created from the data of all 103 patients providing an estimation of what a normal child skull looks like. For each new subject with craniosynostosis, the composite skull model can be scaled to their age and head circumference to obtain an appropriate normative reference for that subject. This approach requires age stratification and suffers from the limitation of defining landmark correspondence.

Later, Mendoza et al. [23] presented a statistical shape model of normal anatomy constructed via principal component analysis (PCA). Each new subject under study is projected into the PCA shape space and its closest normal cranial shape is computed through similarity metrics in the PCA space. Moreover, age-invariance is achieved using a registration algorithm that aligns and scales the subject’s cranial shape with the reference normal shape only considering the anatomy at the base of the skull, where pathological deformations during craniosynostosis are negligible [24]. This methodology presents an improvement in comparison with previous approaches [22, 25], which were based on population averages or age-matched templates, and accounts for normal variations in healthy anatomy (e.g. due to sex or ethnicity [26]).

Comparison of the cranial shape of a patient with its closest normal reference, computed from statistical shape models, can be used to discriminate pathological shape abnormalities from healthy phenotypes. The malformation field for each subject can be computed by measuring the Euclidean distance from each vertex of the subject’s skull surface model to the closest vertex in the most similar normal model. Local malformation values in the different regions of the cranium can then be visualized using a color map (**Figure 1**).

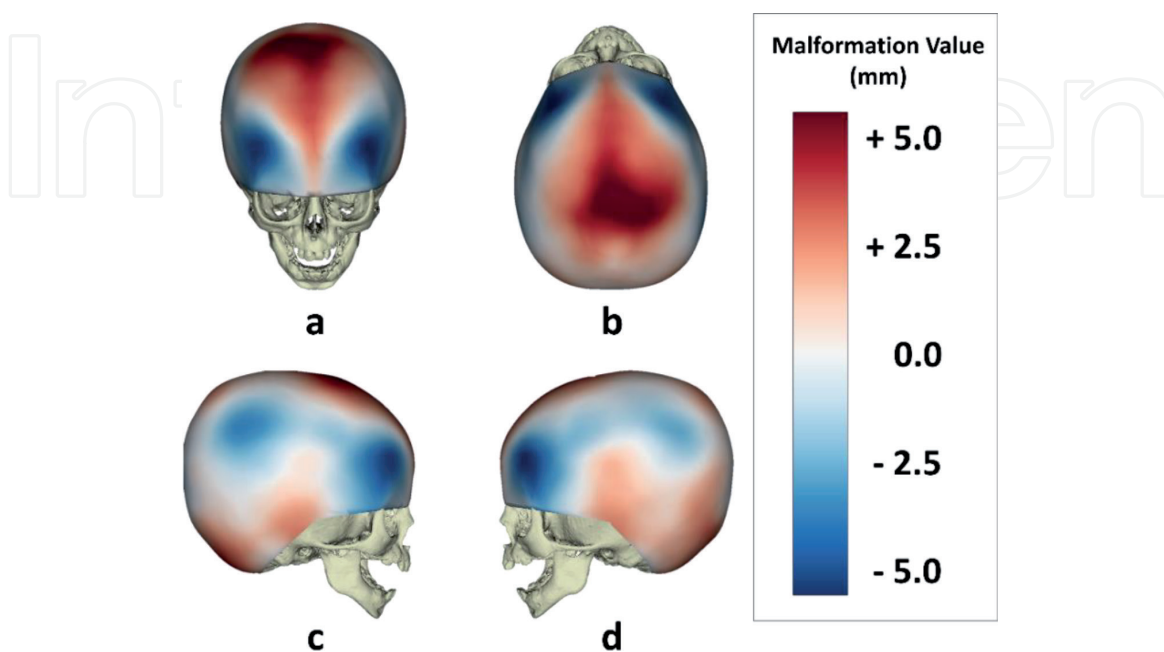


Figure 1. Malformation field of a patient with metopic craniosynostosis computed by comparing the preoperative cranial shape with its closest normal reference: (a) anterior view, (b) superior view, (c) right view, and (d) left view.

Malformation fields provide valuable information on the degree of morphological abnormality and can be used for automatic diagnosis. Mendoza et al. [27] used a dataset of 18 patients with metopic craniosynostosis to identify three robust landmarks for diagnosis and characterization of trigonocephaly. The malformation field for each patient in the dataset was averaged across metopic craniosynostosis subjects and represented on a template of normal anatomy. Then, optimal landmarks were defined on the points of maximum average malformation on the frontal bone region. Wood et al. [28] demonstrated that the interfrontal angle value, measured using these three optimal landmarks, presented significantly different values in metopic craniosynostosis patients and healthy phenotypes. They obtained an accuracy of 98% for the diagnosis of metopic synostosis using this methodology. Similar approaches have been proposed for the quantification of other types of craniosynostosis, such as unicoronal [29] or sagittal [30].

3D reconstructions generated from CT scans are the basis of most methods for quantitative evaluation of cranial shape. This imaging technique has become the standard for the investigation of potential craniosynostosis due to its ability to display bone tissue with high spatial resolution [31]. CT imaging enables the generation of accurate 3D reconstructions of the cranium which can be used for diagnosis, shape analysis, and virtual surgical planning. However, this technique involves the exposure of the infants to ionizing radiation and frequently requires sedation or anesthesia. For these reasons, CT imaging is rarely used for postoperative evaluation of surgical outcomes and patient follow-up [32].

Due to the limitations of CT imaging, 3D photography has been introduced for the evaluation of cranial malformations. The validity and reliability of this technology to obtain craniofacial anthropometric measurements have already been demonstrated [33–35]. In particular, Porrás et al. [36] showed how 3D photography discriminates between patients with and without craniosynostosis with a sensitivity

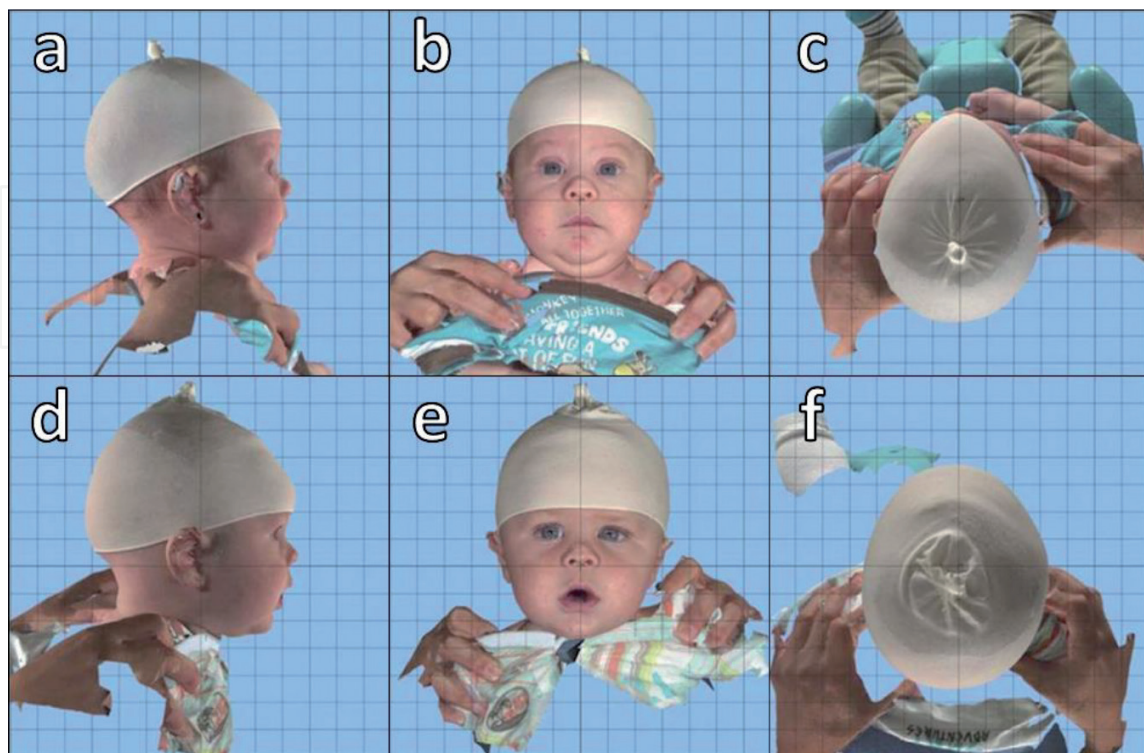


Figure 2. Preoperative (a-c) and postoperative (d-f) 3D photographs of a metopic craniosynostosis patient. The patient's hair covered using a skull cap to avoid artifacts. Image adapted from [35].

above 94%. Other authors have shown that it is possible to calculate intracranial volume with this technique [37].

3D photography followed by statistical shape analysis provides a powerful tool for fast, non-invasive, and radiation-free quantification of cranial shape, presenting a valuable alternative to CT imaging. This technology enables the visualization and quantification of global and regional cranial malformations without exposure to ionizing radiation. Besides, the acquisition of 3D photographs is very fast, avoiding the need for sedation or anesthesia of the infant. Multiple 3D photographs can be acquired for diagnosis and postoperative evaluation of the surgical outcomes. The main limitation of 3D photography is the difficulty in capturing hair. This issue is easily solved by covering the patient's hair during the acquisition using tight nylon skull caps to avoid artifacts (**Figure 2**) [38]. A suboptimal covering of the hair may cause bumps on the surface that will affect cranial shape quantification.

Cranial shape analysis can provide an objective and accurate diagnosis of craniosynostosis. This tool can eliminate subjectivity and increase reproducibility during the diagnostic phase. The integration of these advancements in the clinical practice will contribute to the early diagnosis of craniosynostosis, which is crucial for management, prevention of complications, and consideration for prompt surgical correction [39].

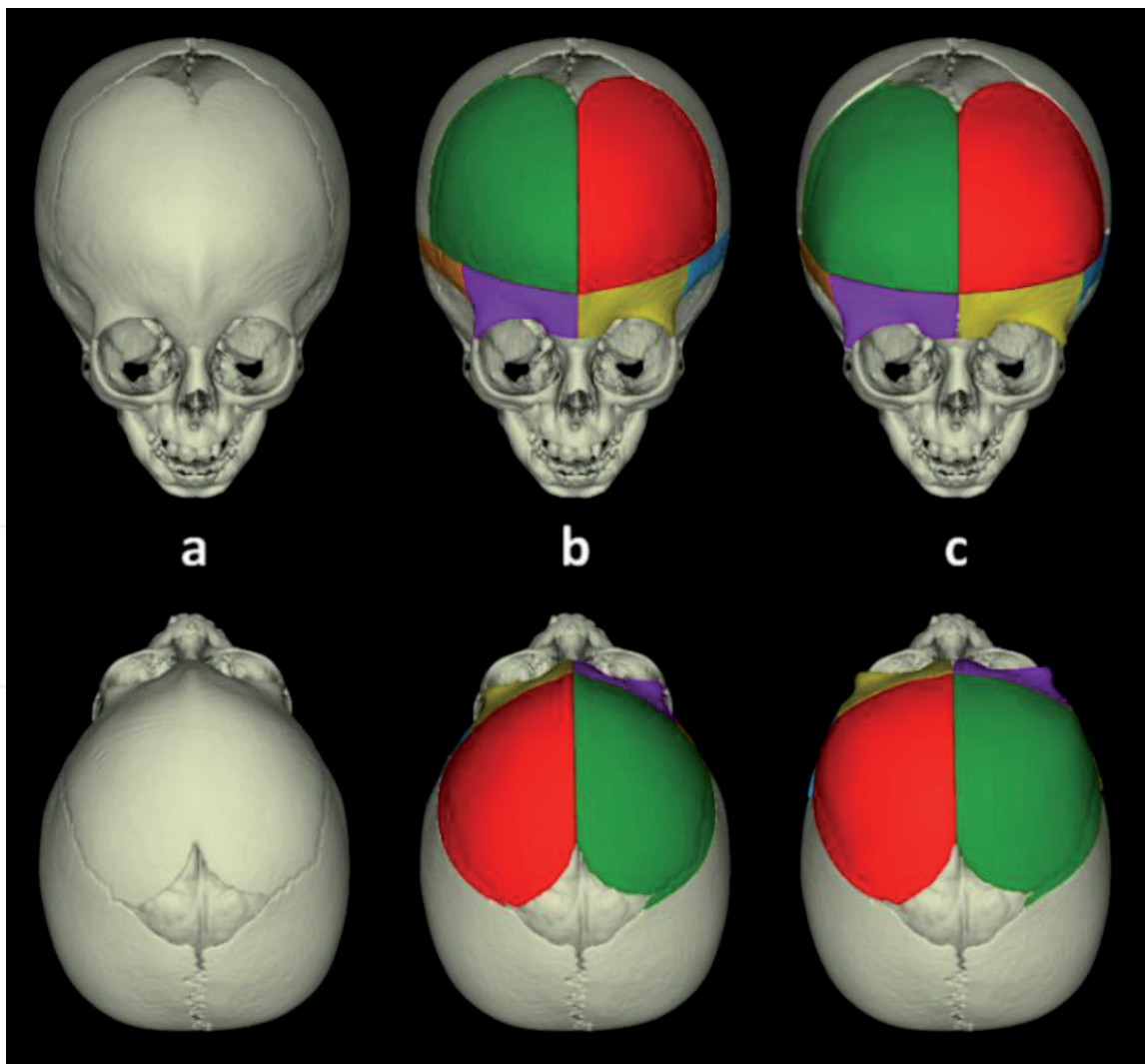


Figure 3. Virtual surgical plan of open cranial vault remodeling for correction of metopic craniosynostosis: (a) 3D model of the cranium obtained from preoperative CT scan, (b) definition of osteotomy lines and fragments, and (c) configuration of bone fragments to achieve desired postoperative cranial shape.

3. Computer-assisted planning

Once a patient is diagnosed with craniosynostosis, surgical correction is the standard of care for most moderate to severe deformities. During the surgical procedure, surgeons perform a remodeling of the affected region to create a normal cranial shape. However, “normal” cranial shape is usually defined through mental constructions by experienced craniofacial surgeons, and is thus highly subjective. Therefore, determining the best approach to restore normal shape remains a subjective surgical art, leading to a less reliable prediction of the surgical outcome of each patient.

Computer-assisted surgical planning has been proposed to enhance the accuracy, efficiency, and reproducibility of craniosynostosis surgeries [21, 40]. Virtual surgery can be performed preoperatively on a computer workstation to reduce time-consuming intraoperative decision making. During virtual planning, osteotomies are defined and bone fragments are configured to achieve the desired target cranial morphology and features (**Figure 3**). Most reported techniques are based on free-hand approaches requiring extensive manual human interaction, and the planning results are still highly dependent on the physicians’ experience [41, 42].

Automatic surgical planning methodologies have been developed to find a personalized and optimal shape to target during the intervention [20]. Porras et al. [20] developed the first fully automatic and objective framework for interventional planning of metopic craniosynostosis. First, the algorithm uses a statistical shape model generated from a set of healthy subjects to determine the closest normal cranial shape to target during the surgical intervention. Then, a global registration approach is employed to arrange the fragments in the most appropriate configuration considering the interactions between bone fragments and avoiding overlaps. The optimal configuration of fragments is found by minimizing the degree of malformation and curvature discrepancies of the cranium. This framework was improved in a second study [43] to include bending of the fragments and to allow the users to define the desired number of fragments for interventional planning. They virtually planned 15 patients with metopic craniosynostosis, obtaining optimal target cranial shapes in all cases. The algorithm could also be adapted for the interventional planning of other types of craniosynostosis, although this is future work to be developed.

Automatic planning software enables to adjust bone fragments in the most optimal configuration to achieve normal morphology, reducing the cranial malformation of craniosynostosis patients. However, the results of longitudinal studies of the cranial growth of craniosynostosis patients indicate inadequate development following surgery [44]. Therefore, overcorrections considering growth and relapse must be factored into the surgical plan to ensure optimal long-term esthetic and functional outcomes [45]. Nowadays, there are no methodologies for automatic interventional planning of craniosynostosis integrating and considering overcorrection during the configuration of bone fragments. Future research is necessary to automatically determine the optimal degree of overcorrection for each patient, and to apply this overcorrection to the preoperative virtual surgical plan.

4. Computer-aided design and manufacturing

Transforming the preoperative virtual plan into a reality is a challenging endeavor and it is highly dependent on the surgical experience and judgment of the craniofacial surgeons. Computer-aided design and manufacturing (CAD/CAM) enables the fabrication of patient-specific cutting guides and shaping templates that

can be used during surgery to guide osteotomy and remodeling according to the preoperative virtual plan [40].

Using a 3D reconstruction of the cranial surface as a reference, surgical cutting guides are designed to fit into the affected anatomical region (**Figure 4a**) and to guide the location of osteotomies as defined during the planning stage (**Figure 4b**) [12]. In addition, shaping templates can also be designed to assist during the intraoperative remodeling of the cranial vault [8, 46]. These templates enable the configuration of the resected bone fragments following the design decided during planning. Each of the fragments is fitted into their corresponding position on the template (**Figure 4c** and **d**) and rigidly fixed using resorbable plates and screws.

Accurate 3D reconstructions of the cranium are required to ensure optimal design and application of CAD/CAM guides and templates. CT imaging is the standard technique used for the generation of 3D models of the cranium prior to surgery. However, a new MRI technique called “black bone” has already been validated as a reference for CAD/CAM craniosynostosis surgery [47]. Therefore, MRI could be used to avoid CT scans and the exposure of the infants to ionizing radiation.

Fabrication of the patient-specific surgical cutting guides and templates must ensure a fast availability and secure sterilization without the risk of deformation. For this reason, manufacturing is commonly performed with selective laser sintering and polyamide material [12]. Other approaches have proposed the use

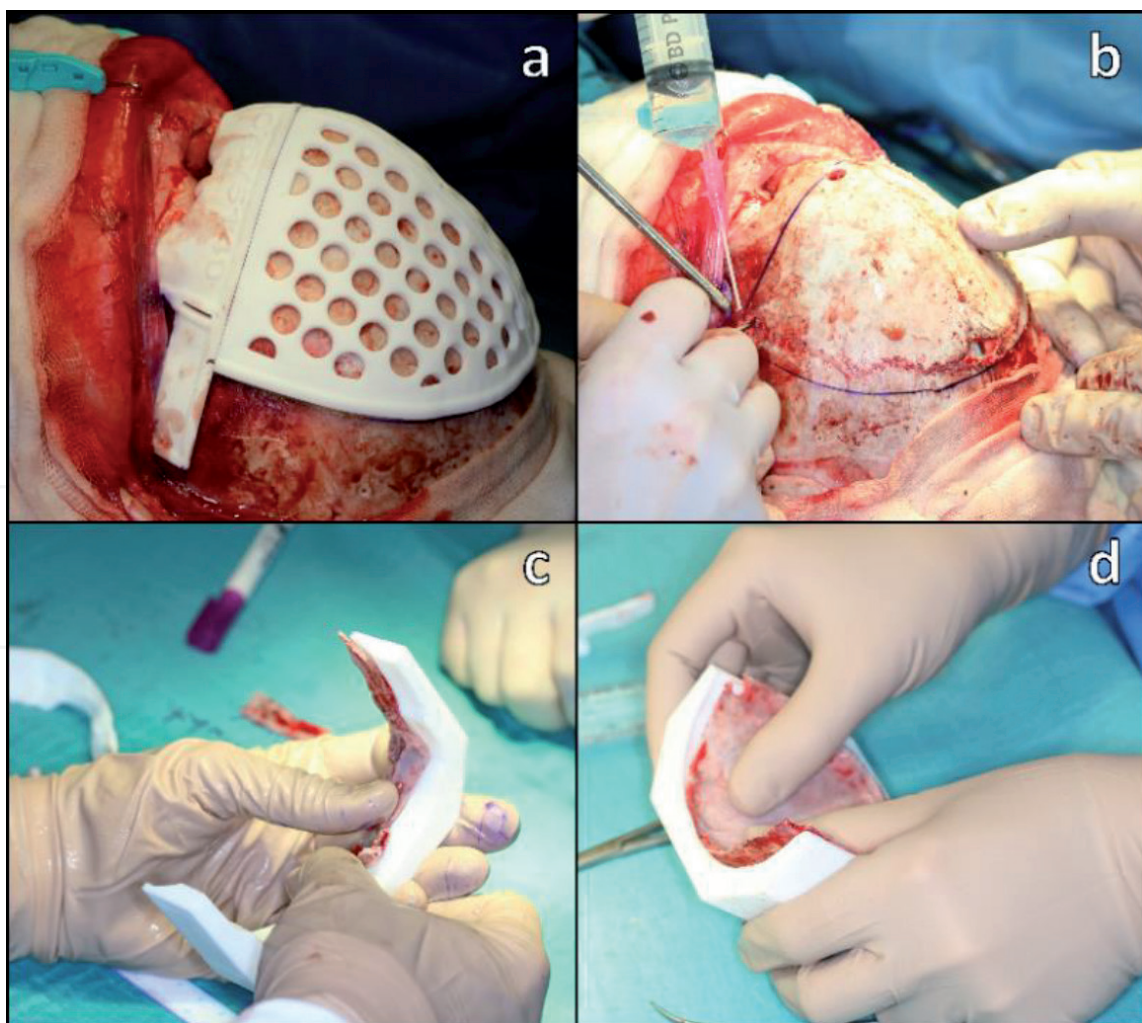


Figure 4. Cutting guides and templates used during fronto-orbital advancement for surgical correction of a patient with metopic craniosynostosis. (a) Placement of surgical cutting guides on the calvarium, (b) marking of planned osteotomies on the calvarium, (c) shaping template for supraorbital bar remodeling, and (d) shaping template for frontal bone remodeling. Image adapted from [12].

of stainless steel templates [48]. Both types of materials can be sterilized before surgery using standard autoclave protocols [46].

Several studies have demonstrated the advantages of combining virtual surgical planning and CAD/CAM guides and templates for craniosynostosis surgery [8, 40, 45, 49]. This technology has been applied to single-suture and multiple-suture craniosynostosis [50]. Results indicate improved surgical outcomes and reduced operative time. Also, these technologies could reduce the experiential gap between younger and veteran craniofacial surgeons by accelerating the learning curve of future trainees. Overall, these studies demonstrate that the inclusion of this technology in the surgical workflow improves the efficiency, accuracy, and reproducibility of the interventions.

5. Image-guided surgery

The use of patient-specific CAD/CAM cutting guides and templates enables cutting the affected bone tissue and remodeling of the bone fragments as defined during the virtual surgical plan. However, after remodeling, reshaped bone tissue must be manually placed and fixed to the patient. In most cases, the placement of the reshaped bone tissue is assessed visually, and the final position may differ from the preoperative plan. Therefore, surgical outcomes can be compromised by slight positional and rotational variations of the remodeled bone tissue position.

In this context, different methodologies have been reported to assist during bone fragment placement. Hochfeld et al. [51] proposed the use of a stereotactic frame and Schanz screws to control the position of the fragments during the remodeling phase. Individual bone fragments are attached to the Schanz screws by bone brackets and configured based on a reference cranial shape obtained from a statistical shape model. Then, the frame is assembled in the surgical field to confirm fragment positions, and, finally, the remodeled fragments are rigidly fixed to each other by resorbable plates. Although the preliminary results obtained with this frame-based remodeling approach are positive, the incorporation of this technique into the standard clinical practice is limited by the increased surgical time, complexity, and invasiveness associated with the fixation of the frame to the patient.

Later on, Kobets et al. [52] described a guidance system to confirm bone fragment placement through the use of intraoperative CT imaging. First, remodeling of the cranial vault is performed exclusively based on the subjective assessment of the surgeons. Then, an intraoperative CT imaging scan is acquired and aligned with the preoperative plan for comparison and analysis. Finally, any necessary corrections in the bone fragment positions are applied before surgery is completed. Although intraoperative CT imaging provides accurate 3D reconstructions of the patient's anatomy, this technique requires the exposure of the infant to ionizing radiation, increases operative time, and does not enable real-time adjustment of bone fragments position to achieve the desired surgical outcome. Therefore, its application into the standard clinical practice is also limited.

In this situation, 3D photography has been suggested for intraoperative imaging and guidance during craniosynostosis surgery (**Figure 5**) [53]. In contrast to CT imaging, 3D photography can generate 3D models of the patient's anatomy without harmful ionizing radiation. This technology has already been successfully applied for diagnosis [34] and evaluation of surgical outcomes in craniosynostosis [36]. The mobility of hand-held 3D photography devices enables their use inside the operating room for intraoperative quantification. During the scanning process, the mobile device can be moved around the surgical field to acquire 3D models of the cranial vault during open cranial vault remodeling. Acquired intraoperative 3D

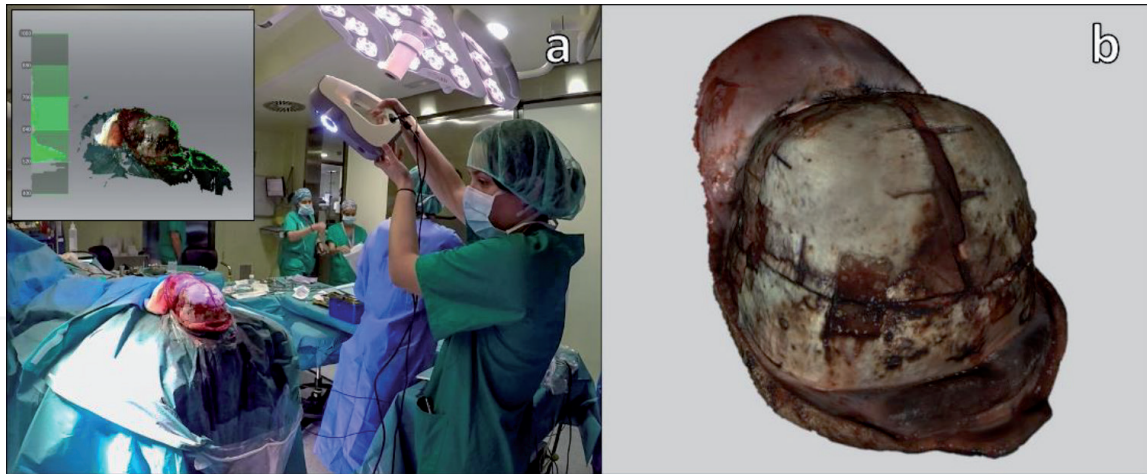

Figure 5.
(a) Acquisition of an intraoperative 3D photograph of the cranial vault during craniostylosis surgery using the hand-held structured light scanner. (b) Acquired 3D photograph of the remodeled cranial vault.

photographs can be aligned with the preoperative virtual surgical plan for comparison and analysis (**Figure 6**) [54]. Overlaying of the actual and planned outcomes allows studying the accuracy of the surgical intervention and defining any necessary corrections to improve the outcome. This innocuous scanning technique can be used to acquire multiple scans during surgery to provide guidance to surgeons and to ensure optimal surgical outcomes.

Previously mentioned methodologies based on intraoperative CT imaging [52] or 3D photography [53] do not provide real-time feedback to the surgeons. Although multiple CT scans or 3D photographs could be acquired during surgery for more accurate and continuous guidance, this methodology would be limited by the increased operative time and, in the case of CT imaging, by the increased exposure to ionizing radiation.

An intraoperative navigation system has been specifically developed for real-time guidance during craniostylosis reconstructions surgeries [12]. This system tracks the position of a surgical tool, which can then record points along the surface of the remodeled bone tissue. Then, the recorded position of the fragments can be compared with the target position defined during the planning phase, providing accurate and iterative quantitative feedback to surgeons (**Figure 7**). Navigation can

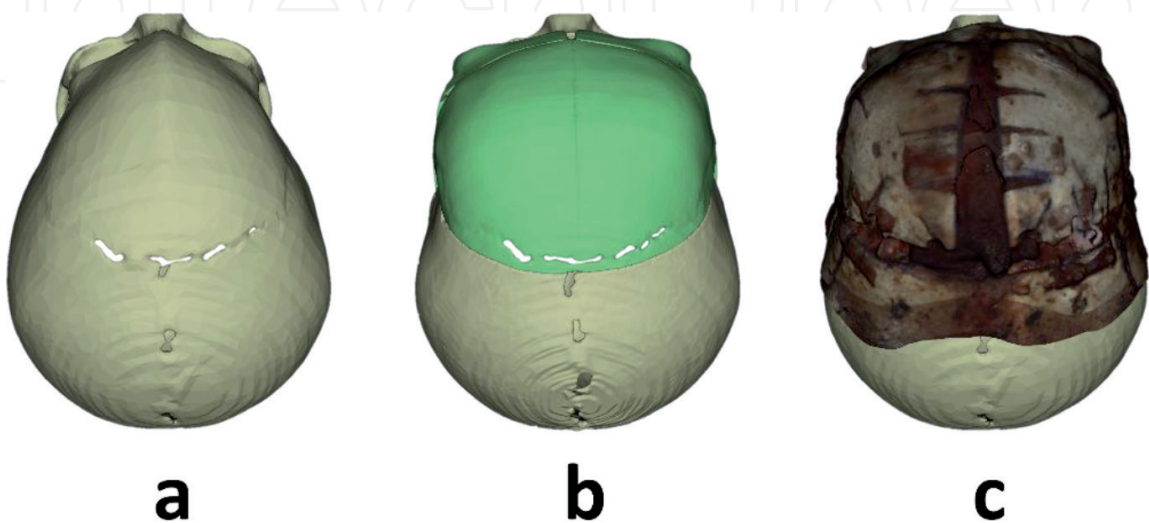


Figure 6.
Superior view of (a) preoperative model obtained from CT scan, (b) virtual surgical plan, and (c) intraoperative 3D photograph after cranial vault remodeling. Adapted from [12].

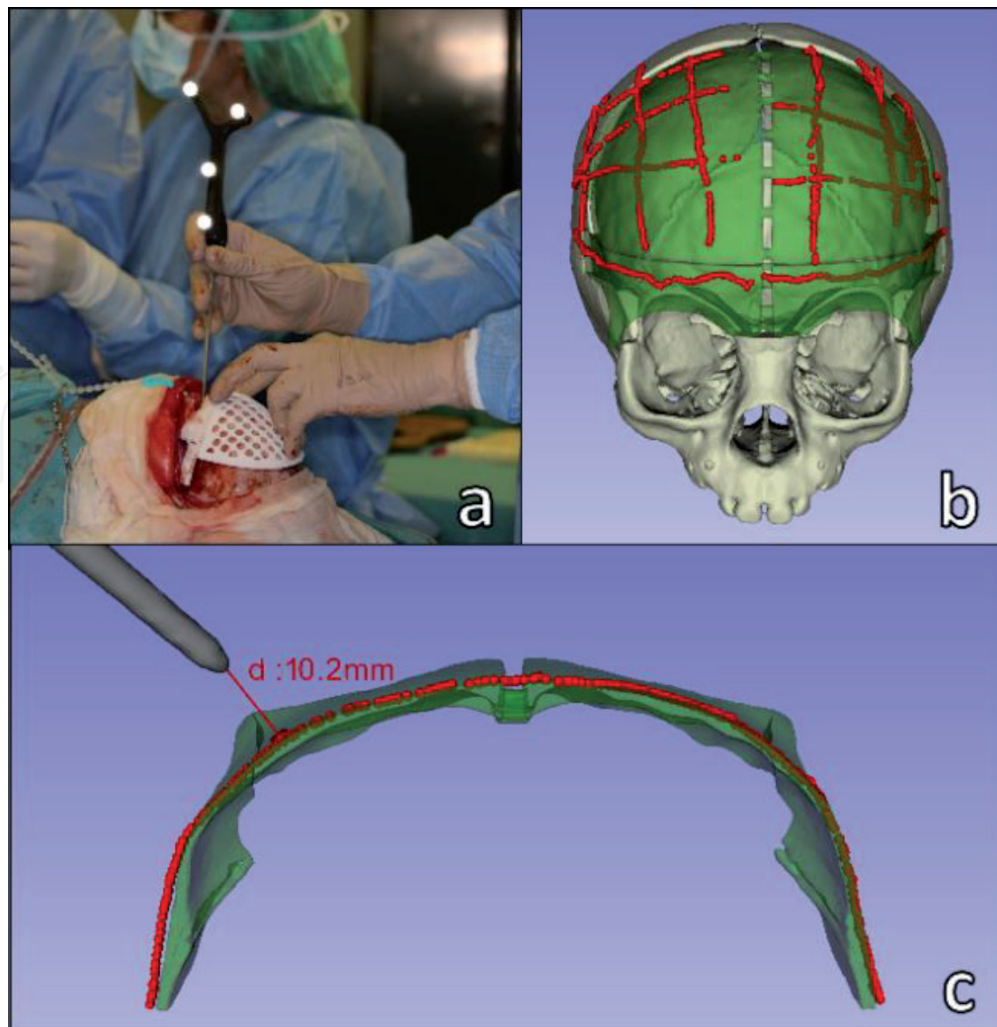


Figure 7. Intraoperative navigation system: (a) surgeon recording registration points using tracked pointer tool; (b) points recorded by the navigation systems on the remodeled bone surface (red) and virtual surgical planning (green); (c) navigation of supraorbital bar region using tracked pointer tool. Image adapted from [12].

be used multiple times during surgery, making any necessary correction to ensure accurate matching with the preoperative virtual plan. This system has already been tested in five patients suffering from single-suture craniosynostosis in combination with CAD/CAM cutting guides and templates. The results of the study indicate high navigation accuracy (< 1 mm) and optimal surgical outcomes.

Although intraoperative navigation has demonstrated high accuracy and feasible integration into the surgical workflow, it presents some potential limitations. First, it requires the use of an optical tracking system in the operating room to track the position of the bone fragments. This hardware increases the cost associated with craniosynostosis surgery and may not be available in all centers for clinical deployment. Secondly, the navigation information is displayed on an external screen adjacent to the surgical field. Therefore, surgeons need to look at two different information sources and then mentally match the virtual data from the screen with the patient's anatomy. This visualization technique increases their cognitive load and may affect hand-eye coordination during the procedure.

Augmented reality (AR) technology has been applied in the medical field and, more specifically, to surgical procedures. AR enables the surgeons to focus on the surgical field while having access to external virtual information which is overlaid on the scene. This technology has already demonstrated to improve the accuracy and safety of surgical procedures [55].

Han et al. [56] reported the use of AR technology for guidance during open cranial vault reconstructions for the correction of craniosynostosis. Their methodology is based on the attachment of AR markers using occlusal splints for the alignment of virtual models in the AR visualization. An external high-definition camera captures images of the surgical field, which are then augmented and displayed to the surgeons on an external screen. The system was successfully tested on seven patients presenting plagiocephaly, but without evaluating the accuracy of AR. However, a thorough characterization of the accuracy of AR guidance is required before its clinical deployment.

Another work has proposed an AR visualization system for navigation of craniosynostosis surgeries [57]. It uses structured light scanning and sterilizable AR markers attached to the bone surface to ensure accurate alignment of the virtual models in the AR visualization. This methodology presents a significant improvement with respect to previous approaches [56], since the AR markers can be located using structured light scanning and attached near the region of interest to minimize alignment error. This system enables the visualization of the virtual plan overlaid on the surgical field, indicating the planes for bone osteotomy and the target position of remodeled bone fragments (**Figure 8**). The performance of the system has been evaluated on several 3D printed phantoms, obtaining a submillimetric accuracy when guiding both osteotomy and remodeling phases of the intervention. Moreover, the system has been successfully tested in two patients demonstrating the feasibility for integration in the surgical workflow and obtaining positive feedback from craniofacial surgeons. The AR visualization software is compatible with external cameras, smartphones, and head-mounted displays and, therefore, surgeons can choose the desired visualization platform according to their preferences and surgical needs. The main limitation of this system is that poor lighting conditions or occlusions of the markers may interrupt tracking and even cause inaccuracies in the AR display. However, illumination of the surgical field during interventions is usually homogeneous, and the position of the markers can be defined to avoid occlusions and maximize tracking capabilities.

While intraoperative navigation is a well-established technique for guidance in craniofacial surgery, AR visualization has recently emerged in the medical

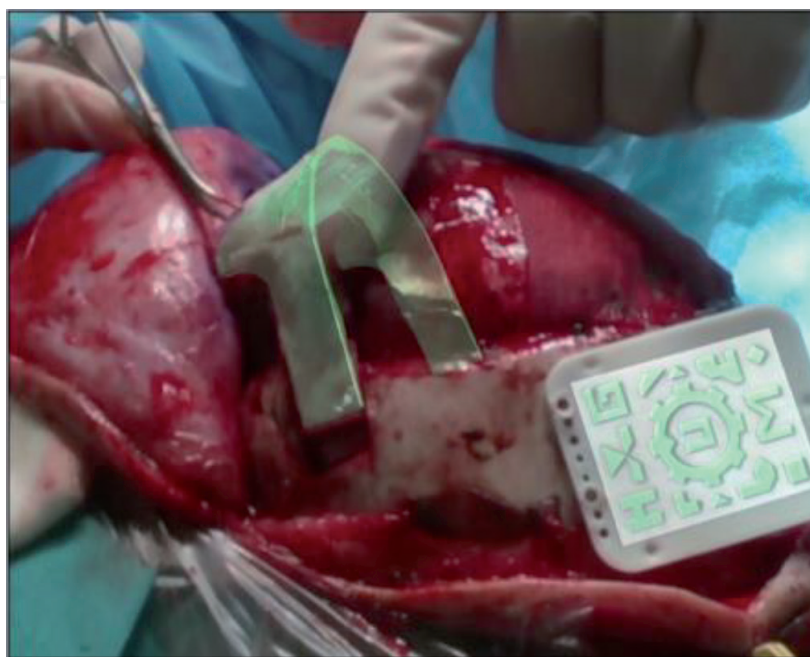


Figure 8.
Visualization of virtual surgical planning (green) overlaid on the surgical field during craniosynostosis surgery.

field and has not been yet integrated into the standard of care. Navigation systems are characterized by their accuracy and robustness during surgical instrument tracking with respect to patient anatomy [58]. On the other hand, AR technology is still under development and future research is still required to achieve optimal performance and robustness. Intraoperative guidance could benefit from the mixed integration of both technologies in the operating room to combine real-time and accurate positioning feedback provided by navigation systems with valuable AR visualization within the surgical field. Although both technologies require specialized training of craniofacial surgeons, proficiency could be achieved by the trainees through simulation-based training using realistic phantoms [59].

6. Conclusions

Multiple technological developments have demonstrated a positive impact on the management of craniosynostosis, from the diagnosis to the postoperative patient follow-up. Cranial shape analysis based on statistical shape models contributes to a more objective and precise diagnosis of craniosynostosis that will lead to earlier detection and surgical correction. Furthermore, statistical shape models can improve preoperative planning by determining the most optimal cranial shapes to target during surgical interventions and facilitating the automatic virtual arrangement of bone fragments. This target cranial shape enables to evaluate the stability of the surgical outcome during postoperative cranial development and to identify possible relapses. In that manner, it will be possible to assess the need for overcorrection to compensate for cranial underdevelopment after surgical remodeling.

Also, the use of CAD/CAM tools, intraoperative navigation, and augmented reality will enable the accurate translation of the preoperative plan into the operating room to ensure optimal surgical outcomes. All these technologies can be integrated into the surgical workflow to increase reproducibility, to reduce operative time, to streamline the methodology, and to reduce intersurgeon variability in open cranial vault remodeling procedures.

In addition, it has been demonstrated that 3D photography presents a valuable alternative to CT imaging. This non-invasive scanning technology can be easily used for diagnosis, intraoperative surgical outcome evaluation, and patient follow-up of craniosynostosis patients avoiding the exposure of the infants to harmful ionizing radiation. Besides, 3D photographs can be acquired instantly, and sedation or anesthesia is not required.

Most of the technological developments presented in this chapter have been tested and validated in non-syndromic single-suture synostosis. However, these approaches could also be applied to syndromic multi-suture synostosis. In these complex cases, most anatomical references in the cranium are altered and optimal surgical correction is challenging. Therefore, these cases will highly benefit from computer-assisted diagnosis, planning, and intraoperative guidance to achieve optimal surgical outcomes. Furthermore, these techniques could also be applied to secondary surgical interventions performed to correct possible complications or relapses after initial treatment.

Although all technologies mentioned can greatly benefit the management of craniosynostosis, there are some limitations to bear in mind. First of all, most of these technologies are costly, and this factor may restrict their integration into clinical practice in some centers with limited budgets. However, many of the previously mentioned technological developments are based on free and open-source software

platforms [12, 53], which could reduce the costs associated with its integration on the surgical workflow. Also, CAD/CAM guides and templates can be designed and manufactured in-hospital to reduce cost and production time [60, 61]. These technologies could also be shared among different hospital departments, improving their impact at a lower cost.

Apart from the economic perspective, some indirect costs must also be considered. The addition of advanced cranial shape analysis, automatic planning algorithms, and design and manufacturing of CAD/CAM tools may increase the duration of the planning phase and will also require the collaboration of engineers. However, patient-specific planning of craniosynostosis surgeries is essential to improve surgical treatment. Advanced algorithms can provide valuable objective metrics to determine the best remodeling approach for each patient. Therefore, the benefits of these technological advancements may outweigh the increased duration of the preoperative planning phase.

In addition, most of the technologies developed for image-guided craniosynostosis surgeries require specialized training for craniofacial surgeons and some of them present a steep learning curve. However, surgeries can be simulated preoperatively using patient-specific phantoms to provide the trainees with realistic tactile feedback of the patient's anatomy. Simulation offers a safe environment where surgery can be replicated step-by-step leading to the acquisition of technical skills which can be translated into better performance during the surgical task [59].

To conclude, multiple technologies are currently available to improve the surgical management of craniosynostosis. The integration of these developments on the surgical workflow of craniosynostosis will have a positive impact on the surgical outcomes, increasing the reproducibility and efficiency of these procedures. Multidisciplinary collaborations between scientific and clinical personnel are essential to improve patient care. Further studies must evaluate the cost-effectiveness of these technologies to determine how to integrate them optimally into clinical practice.

Acknowledgements

Supported by projects PI18/01625 (Ministerio de Ciencia, Innovación y Universidades, Instituto de Salud Carlos III and European Regional Development Fund “Una manera de hacer Europa”) and IND2018/TIC-9753 (Comunidad de Madrid).

Conflict of interest

The authors declare that they have no conflicts of interest.

IntechOpen

Author details

David García-Mato^{1,2}, Javier Pascau^{1,2*} and Santiago Ochandiano^{2,3}

1 Department of Bioengineering and Aerospace Engineering, Universidad Carlos III de Madrid, Madrid, Spain

2 Gregorio Marañón Health Research Institute, Madrid, Spain

3 Department of Oral and Maxillofacial Surgery, Hospital General Universitario Gregorio Marañón, Madrid, Spain

*Address all correspondence to: jpascau@ing.uc3m.es

IntechOpen

© 2020 The Author(s). Licensee IntechOpen. This chapter is distributed under the terms of the Creative Commons Attribution License (<http://creativecommons.org/licenses/by/3.0>), which permits unrestricted use, distribution, and reproduction in any medium, provided the original work is properly cited. 

References

- [1] Sharma R. Craniosynostosis. *Indian J Plast Surg.* 2013;46(1):18.
- [2] Cohen SR, Frank RC, Meltzer HS, Levy ML. Craniosynostosis. *Handb Craniomaxillofacial Surg.* 2014;343-68.
- [3] Boulet SL, Rasmussen SA, Honein MA. A population-based study of craniosynostosis in metropolitan Atlanta, 1989-2003. *Am J Med Genet Part A.* 2008;146(8):984-91.
- [4] Kweldam CF, Van Der Vlugt JJ, Van Der Meulen JJNM. The incidence of craniosynostosis in the Netherlands, 1997-2007. *J Plast Reconstr Aesthetic Surg [Internet].* 2011;64(5):583-8. Available from: <http://dx.doi.org/10.1016/j.bjps.2010.08.026>
- [5] Jimenez DF, Barone CM. Early treatment of anterior calvarial craniosynostosis using endoscopic-assisted minimally invasive techniques. *2007;1411-9.*
- [6] Cohen SR, Holmes RE, Ozgur BM, Meltzer HS, Levy ML. Fronto-orbital and cranial osteotomies with resorbable fixation using an endoscopic approach. *Clin Plast Surg.* 2004 Jul;31(3):429-42, vi.
- [7] Persing JA. MOC-PS(SM) CME Article: Management Considerations in the Treatment of Craniosynostosis. *Plast Reconstr Surg.* 2008;121(Supplement):1-11.
- [8] Mardini S, Alsubaie S, Cayci C, Chim H, Wetjen N. Three-dimensional preoperative virtual planning and template use for surgical correction of craniosynostosis. *J Plast Reconstr Aesthetic Surg.* 2014;67(3):336-43.
- [9] Slater BJ, Lenton KA, Kwan MD, Gupta DM, Wan DC, Longaker MT. Cranial sutures: A brief review. *Plast Reconstr Surg.* 2008;121(4):170-8.
- [10] Hirabayashi S, Sugawara Y, Sakurai A, Harii K. Fronto-orbital advancement by gradual distraction. *J Neurosurg.* 1998;89(6):1058-61.
- [11] Gomi A, Sunaga A, Kamochi H, Oguma H, Sugawara Y. Distraction osteogenesis update: Introduction of multidirectional cranial distraction osteogenesis. *J Korean Neurosurg Soc.* 2016;59(3):233-41.
- [12] García-Mato D, Ochandiano S, García-Sevilla M, Navarro-Cuéllar C, Darriba-Allés J V, García-Leal R, et al. Craniosynostosis surgery: workflow based on virtual surgical planning, intraoperative navigation and 3D printed patient-specific guides and templates. *Sci Rep.* 2019;9(1):17691.
- [13] Whitaker LA, Bartlett SP, Schut L, Bruce D. Craniosynostosis: an analysis of the timing, treatment, and complications in 164 consecutive patients. *Plast Reconstr Surg [Internet].* 1987 Aug [cited 2018 Aug 28];80(2):195-212. Available from: <http://www.ncbi.nlm.nih.gov/pubmed/3602170>
- [14] McCarthy JG., Glasberg SB., Cutting CB., Epstein FJ., Grayson BH., Ruff G., et al. Twenty-year experience with early surgery for craniosynostosis: I. Isolated craniofacial synostosis--results and unsolved problems. *Plast Reconstr Surg.* 1995;96(2):272-83.
- [15] Greenberg BM, Schneider SJ. Trigenocephaly: surgical considerations and long term evaluation. *J Craniofac Surg.* 2006 May;17(3):528-35.
- [16] Selber JC, Brooks C, Kurichi JE, Temmen T, Sonnad SS, Whitaker LA. Long-term results following fronto-orbital reconstruction in nonsyndromic unicoronal synostosis. *Plast Reconstr Surg.* 2008;121(5):251-60.
- [17] Pearson GD, Havlik RJ, Eppley B, Nykiel M, Sadove AM. Craniosynostosis:

- a single institution's outcome assessment from surgical reconstruction. *J Craniofac Surg.* 2008 Jan;19(1):65-71.
- [18] Seruya M, Oh AK, Boyajian MJ, Posnick JC, Myseros JS, Yaun AL, et al. Long-term outcomes of primary craniofacial reconstruction for craniosynostosis: A 12-year experience. *Plast Reconstr Surg.* 2011;127(6):2397-406.
- [19] Engel M, Castrillon-Oberndorfer G, Hoffmann J, Mühling J, Seeberger R, Freudlsperger C. Long-term results in nonsyndromatic unilateral coronal synostosis treated with fronto-orbital advancement. *J Craniomaxillofac Surg.* 2013 Dec;41(8):747-54.
- [20] Porras AR, Zukic D, Equobahrie A, Rogers GF, Linguraru MG. Personalized Optimal Planning for the Surgical Correction of Metopic Craniosynostosis. Clin image-based Proceed from Plan to Interv Int Work CLIP ., held conjunction with MICCAI . Revis Sel Pap CLIP. 2016;2016:60-7.
- [21] Steinbacher DM. Three-Dimensional Analysis and Surgical Planning in Craniomaxillofacial Surgery. *J Oral Maxillofac Surg.* 2015;73(12):S40-56.
- [22] Saber NR, Phillips J, Looi T, Usmani Z, Burge J, Drake J, et al. Generation of normative pediatric skull models for use in cranial vault remodeling procedures. *Child's Nerv Syst.* 2012;28(3):405-10.
- [23] Mendoza CS, Safdar N, Okada K, Myers E, Rogers GF, Linguraru MG. Personalized assessment of craniosynostosis via statistical shape modeling. *Med Image Anal.* 2014;18(4):635-46.
- [24] Kotrikova B, Krempien R, Freier K, Mühling J. Diagnostic imaging in the management of craniosynostoses. *Eur Radiol [Internet].* 2007;17(8):1968-78. Available from: <https://doi.org/10.1007/s00330-006-0520-y>
- [25] Marcus JR, Domeshek LF, Loyd AM, Schoenleber JM, Das RR, Nightingale RW, et al. Use of a three-dimensional, normative database of pediatric craniofacial morphology for modern anthropometric analysis. *Plast Reconstr Surg.* 2009;124(6):2076-84.
- [26] Dean D, Bookstein FL, Koneru S, Lee JH, Kamath J, Cutting CB, et al. Average African American three-dimensional computed tomography skull images: The potential clinical importance of ethnicity and sex. Vol. 9, *Journal of Craniofacial Surgery.* 1998. p. 348-59.
- [27] Mendoza CS, Safdar N, Myers E, Kittisarapong T, Rogers GF, Linguraru MG. An optimal set of landmarks for metopic craniosynostosis diagnosis from shape analysis of pediatric CT scans of the head. *Med Imaging 2013 Comput Diagnosis.* 2013;8670:86702T.
- [28] Wood BC, Mendoza CS, Oh AK, Myers E, Safdar N, Linguraru MG, et al. What's in a Name? Accurately Diagnosing Metopic Craniosynostosis Using a Computational Approach. *Plast Reconstr Surg.* 2015;137(1):205-13.
- [29] Robertson E, Kwan P, Louie G, Boulanger P, Aalto D. Test-retest validation of a cranial deformity index in unilateral coronal craniosynostosis. *Comput Methods Biomech Biomed Engin [Internet].* 2020;0(0):1-13. Available from: <https://doi.org/10.1080/10255842.2020.1795143>
- [30] Tenhagen M, Bruse JL, Rodriguez-florez N, Angullia F, Borghi A, Koudstaal MJ, et al. Three-Dimensional Handheld Scanning to Quantify Head-Shape Changes in Spring-Assisted Surgery for Sagittal Craniosynostosis. *J Craniofac Surg.* 2016;27(8):2117-23.
- [31] Branson HM, Shroff MM. Craniosynostosis and 3-Dimensional Computed Tomography. *Semin*

Ultrasound, CT MRI [Internet]. 2011;32(6):569-77. Available from: <http://www.sciencedirect.com/science/article/pii/S0887217111000989>

[32] Schweitzer T, Böhm H, Meyer-Marcotty P, Collmann H, Ernestus RI, Krauß J. Avoiding CT scans in children with single-suture craniosynostosis. *Child's Nerv Syst.* 2012;28(7):1077-82.

[33] Wong JY, Oh AK, Ohta E, Hunt AT, Rogers GF, Mulliken JB, et al. Validity and reliability of craniofacial anthropometric measurement of 3D digital photogrammetric images. *Cleft Palate-Craniofacial J.* 2008;45(3):232-9.

[34] Meulstee JW, Verhamme LM, Borstlap WA, Van der Heijden F, De Jong GA, Xi T, et al. A new method for three-dimensional evaluation of the cranial shape and the automatic identification of craniosynostosis using 3D stereophotogrammetry. *Int J Oral Maxillofac Surg.* 2017;46(7):819-26.

[35] Wilbrand JF, Szczukowski A, Blecher JC, Pons-Kuehnemann J, Christophis P, Howaldt HP, et al. Objectification of cranial vault correction for craniosynostosis by three-dimensional photography. *J Cranio-Maxillofacial Surg [Internet].* 2012;40(8):726-30. Available from: <http://dx.doi.org/10.1016/j.jcms.2012.01.007>

[36] Porras AR, Tu L, Tsering D, Mantilla E, Oh A, Enquobahrie A, et al. Quantification of head shape from three-dimensional photography for pre- and post-surgical evaluation of craniosynostosis. *Plast Reconstr Surg [Internet].* 2019 Aug; Available from: <https://doi.org/10.1097/PRS.0000000000006260>

[37] Freudlsperger C, Steinmacher S, Bächli H, Somlo E, Hoffmann J, Engel M. Metopic synostosis: Measuring intracranial volume change following

fronto-orbital advancement using three-dimensional photogrammetry. *J Cranio-Maxillofacial Surg [Internet].* 2015;43(5):593-8. Available from: <http://www.sciencedirect.com/science/article/pii/S1010518215000487>

[38] Rodriguez-Florez N, Göktekin ÖK, Bruse JL, Borghi A, Angullia F, Knoops PGM, et al. Quantifying the effect of corrective surgery for trigonocephaly: A non-invasive, non-ionizing method using three-dimensional handheld scanning and statistical shape modelling. *J Cranio-Maxillofacial Surg [Internet].* 2017;45(3):387-94. Available from: <http://www.sciencedirect.com/science/article/pii/S1010518217300021>

[39] Kirmi O, Lo SJ, Johnson D, Anslow P. Craniosynostosis: A Radiological and Surgical Perspective. *Semin Ultrasound, CT MRI.* 2009;30(6):492-512.

[40] Seruya M, Borsuk DE, Khalifian S, Carson BS, Dalesio NM, Dorafshar AH. Computer-Aided Design and Manufacturing in Craniosynostosis Surgery. *J Craniofac Surg.* 2013;24(4):1100-5.

[41] Havlik RJ, Azurin DJ, Bartlett SP, Whitaker LA. Analysis and treatment of severe trigonocephaly. *Plast Reconstr Surg.* 1999 Feb;103(2):381-90.

[42] Selber J, Reid RR, Gershman B, Sonnad SS, Sutton LN, Whitaker LA, et al. Evolution of Operative Techniques for the Treatment of Single-Suture Metopic Synostosis. *Ann Plast Surg [Internet].* 2007;59(1). Available from: https://journals.lww.com/annalsplasticsurgery/Fulltext/2007/07000/Evolution_of_Operative_Techniques_for_the.2.aspx

[43] Porras AR, Paniagua B, Ensel S, Keating R, Rogers GF, Enquobahrie A, et al. Locally Affine Diffeomorphic Surface Registration and Its Application to Surgical Planning of Fronto-Orbital Advancement. *IEEE Trans Med Imaging.* 2018;37(7):1690-700.

- [44] Fearon JA, Dittthakasem K, Chan WNJ, Herbert M. Long-Term Growth following Trigenocephaly Repairs: Are Overcorrections Necessary? *Plast Reconstr Surg* [Internet]. 2020;145(3). Available from: https://journals.lww.com/plasreconsurg/Fulltext/2020/03000/Long_Term_Growth_following_Trigenocephaly_Repairs_.33.aspx
- [45] Khechoyan DY, Saber NR, Burge J, Fattah A, Drake J, Forrest CR, et al. Surgical outcomes in craniosynostosis reconstruction: The use of prefabricated templates in cranial vault remodelling. *J Plast Reconstr Aesthetic Surg*. 2014;67(1):9-16.
- [46] Soleman J, Thieringer F, Beinemann J, Kunz C, Guzman R. Computer-assisted virtual planning and surgical template fabrication for frontoorbital advancement. 2015;38(May):1-8.
- [47] Lethaus B, Gruichev D, Gräfe D, Bartella AK, Hahnel S, Yovev T, et al. "Black bone": the new backbone in CAD/CAM-assisted craniosynostosis surgery? *Acta Neurochir (Wien)* [Internet]. 2020; Available from: <https://doi.org/10.1007/s00701-020-04445-z>
- [48] Burge J, Saber NR, Looi T, French B, Usmani Z, Anooshiravani N, et al. Application of CAD/CAM Prefabricated Age-Matched Templates in Cranio-Orbital Remodeling in Craniosynostosis. *J Craniofac Surg*. 2011;22(5):1810-3.
- [49] Queiros C, Joly A, Paré A, Listrat A, Travers N, Goga D, et al. Use of cutting guides during craniosynostosis sequelae surgery: A comparative study between computer-assisted planning and post-operative results. *J Cranio-Maxillofacial Surg*. 2017;45(7):1062-8.
- [50] Iyer RR, Wu A, Macmillan A, Musavi L, Cho R, Lopez J, et al. Use of computer-assisted design and manufacturing to localize dural venous sinuses during reconstructive surgery for craniosynostosis. *Childs Nerv Syst*. 2018 Jan;34(1):137-42.
- [51] Hochfeld M, Lamecker H, Thomale U-W, Schulz M, Zachow S, Haberl H. Frame-based cranial reconstruction. *J Neurosurg Pediatr*. 2014;13(3):319-23.
- [52] Kobets AJ, Ammar A, Nakhla J, Scoco A, Nasser R, Goodrich JT, et al. Virtual modeling, stereolithography, and intraoperative CT guidance for the optimization of sagittal synostosis reconstruction: a technical note. *Child's Nerv Syst*. 2018;34(5):965-70.
- [53] García-Mato D, García-Sevilla M, Ochandiando S, Navarro-Cuéllar C, Darriba-Allés JV, García-Leal R, et al. Structured Light Scanning for Morphometric Analysis in Craniosynostosis Reconstruction Surgery. In: *International Journal of Computer Assisted Radiology and Surgery*. Rennes, France; 2019. p. 40-1.
- [54] García-Mato D, García-Sevilla M, Ochandiando S, Moreta-Martinez R, Darriba-Allés JV, García-Leal R, et al. Intraoperative Outcome Evaluation in Craniosynostosis Reconstruction Surgery using 3D Photography. In: *International Journal of Computer Assisted Radiology and Surgery*. Munich, Germany; 2020. p. 87-8.
- [55] Berryman DR. Augmented Reality: A Review. *Med Ref Serv Q*. 2012;31(2):212-8.
- [56] Han W, Yang X, Wu S, Fan S, Chen X, Aung ZM, et al. A new method for cranial vault reconstruction: Augmented reality in synostotic plagiocephaly surgery. *J Cranio-Maxillofacial Surg*. 2019;47(8):1280-4.
- [57] García-Mato D, Moreta-Martinez R, García-Sevilla M, Ochandiano S, García-Leal R, Pérez-Mañanes R, et al. Augmented Reality Visualization for Craniosynostosis Surgery. *Comput Methods Biomech Biomed Eng Imaging Vis*. 2020;

[58] Peters T, Cleary K. Image-guided interventions: Technology and applications. *Image-Guided Interventions: Technology and Applications*. 2008. 1-557 p.

[59] Palter VN, Grantcharov TP. Simulation in surgical education. *Can Med Assoc J [Internet]*. 2010 Aug 10;182(11):1191 LP – 1196. Available from: <http://www.cmaj.ca/content/182/11/1191.abstract>

[60] Arnal-Burró J, Pérez-Mañanes R, Gallo-del-Valle E, Igualada-Blazquez C, Cuervas-Mons M, Vaquero-Martín J. Three dimensional-printed patient-specific cutting guides for femoral varization osteotomy: Do it yourself. *Knee [Internet]*. 2017 Dec 1;24(6):1359-68. Available from: <https://doi.org/10.1016/j.knee.2017.04.016>

[61] Moreta-Martinez R, García-Mato D, García-Sevilla M, Pérez-Mañanes R, Calvo-Haro J, Pascau J. Augmented reality in computer-assisted interventions based on patient-specific 3D printed reference. *Healthc Technol Lett*. 2018;5(5):162-6.