

Accuracy of Palpation for Cricothyroidotomy ^{PC}

Xiaofeng Shen, * Shiqin Xu, * Fuzhou Wang, *^Δ

CRICOTHYROIDOTOMY IS A practical procedure that is critical for patients in the context of emergency. Accurately identify the cricothyroid membrane takes a crucial part in determining the success of cricothyroidotomy. However, it is not that easy for clinicians when facing patients with different conditions that limit the palpation accuracy. Obesity is a risk factor for the failure of cricothyroidotomy. Special care is needed for obese patients. We herein build a mathematic model to explain why it is hard for obese patients to be palpated, and we also give recommendations based on the model on how to increase the rate of the palpation accuracy.

*Department of Anesthesiology and Critical Care Medicine, Nanjing Maternity and Child Health Care Hospital, Nanjing Medical University, Nanjing, China

^Δ Correspondence to Fuzhou Wang, No. 123, Tianfei Xiang, Mochou Rd., Nanjing 210004, China

Tel: +86-25-5222 6112

Fax: +86-25-8420 0723

Email: zfwang50@njmu.edu.cn

✉: Publisher Copyright

Received: 03 June 2013

In-House Reviewed: 09 June 2013

Accepted: 12 June 2013

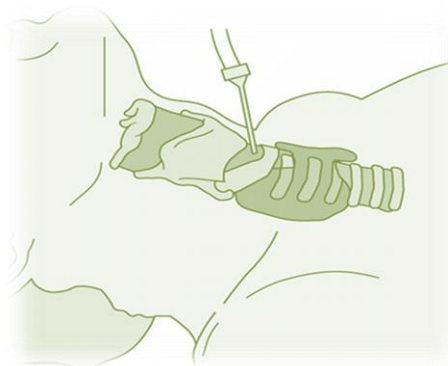
SCI INSIGHTS 2013; 1(3): 30-31.

Keywords: Cricothyroid membrane - Obesity - Cricothyroidotomy - Emergency - Mathematic model

RECENT study showed the successful rate for palpation accuracy to identify the cricothyroid membrane (CTM) in female patients is low (1). The researchers merely got a some 25% success (10/41) and 0% (0/15) in identifying the CTM in non-obese and obese patients, respectively when the neck was in the supine neutral position, and ~30% (12/41) and about 7% (1/15) in both kinds of patients when the neck was extended maximally. These were interestingly as same as another report by Dr Elliott and colleagues in which only 30% attempts by anesthesiologists accurately marked the skin area over the CTM (2). To such a low accuracy of the CTM identifi-

cation, I analyzed theoretically how they occurred and wanted to give an explanation for this phenomenon.

As showing in the Figure 1 (panels A and B), the cervical spine will form an angle (θ) between the line b in the neutral position and line d in the extended position. This is the normal and typical change when we perform cricothyroidotomy and neck examination. We mimicked this situation and modeled the neck like a cylinder theoretically (Panel C in the Fig. 1). Thus, in this model, the



middle point as showing the dot “m” will not shift up and down when both cephalic and caudal sides changing their positions simultaneously (Panel D in the Fig. 1), at this position, therefore, the y axis of the coordinate will not be displaced by the extension and still directs upward tangentially to the middle line. However, this is not the actual clinical situation; generally our necks will be extended with only cephalad backwards (Panel E in the Fig. 1) which will result in a shift of dot “m” upwards to the position of

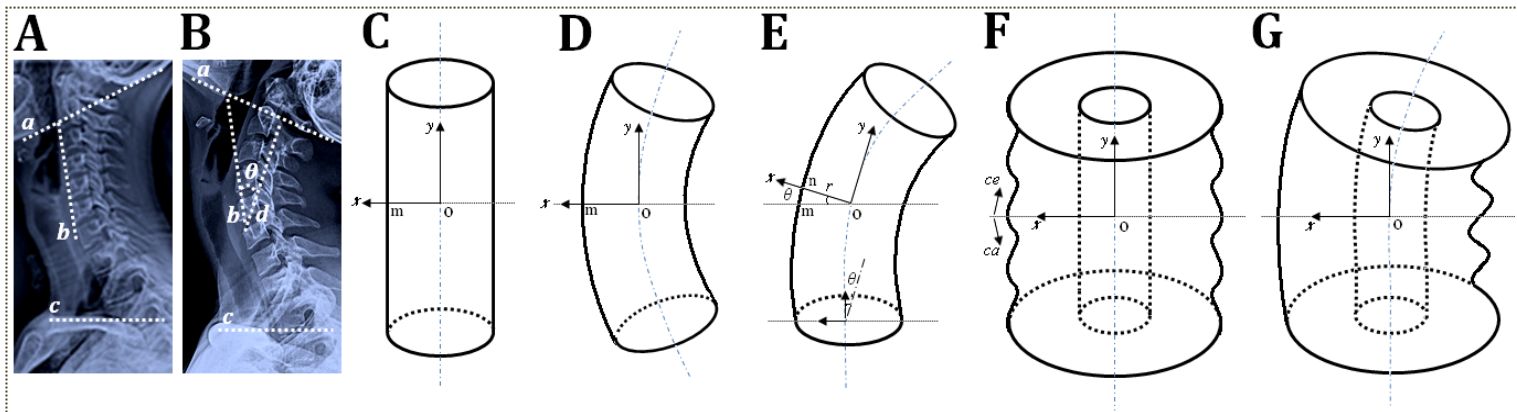


Figure 1. Calculation model of the extended neck for palpation accuracy. (A and B) Lateral radiography of the cervix in supine neutral and maximally extended positions; (C to E) simplified model of the cervix for the shift of the palpation point when the neck is extended in nonobese population; (F and G) obesity model for palpation accuracy. r denotes the radius; θ denotes the radian; ce means cephalad; ca means caudad.

dot “n”. So an angle between the lines of “om” and “on” formed, and this is exactly the angle of “ θ ” in the panel B. According to the mathematic formula of arc length of a sector,

$$a = \frac{\pi \cdot r \cdot \theta}{180^\circ} = \frac{C \cdot \theta}{360^\circ}$$

where a is the arc length, r is the radius, θ is the radian, and C is the neck circumference, thereafter we calculated the arc length of “mn” on the bases of the reported normal ranges of θ (10-30°, the maximal extension angle of the human neck) (3) and C (37.5 cm and 40 cm in female and male, respectively) in nonobese population. As thus the real palpation point will shift upward the following distance: $a_{\text{male}} = 1.11\text{-}3.33$ cm, and $a_{\text{female}} = 1.04\text{-}3.13$ cm. Meanwhile, given the movement tendency of skin during palpation and the possible rotation of the axial neck, so this theoretic calculation will encounter alteration and may be moved up or down, or left or right. For the patients of Drs Aslani et al. (1), their changing ranges of the skin palpation point

were $a_{\text{nonobese}} = 0.97 \pm 0.08 - 2.91 \pm 0.24$ cm, and $a_{\text{obese}} = 1.12 \pm 0.11 - 3.36 \pm 0.34$ cm. Nonetheless, it is more complex when assessing such changes in the obesity because of the increased neck circumferences of obese patients (Panel F in the Fig. 1) (4), which will lead to a relatively smaller extending angle than that in the normal people, plus the stretch of the wrinkled skin (Panel G in the Fig. 1), so the palpation point will move far easier on the fattened neck and in fact cannot be assessed using this theoretic proposal. Therefore, the elevated palpation point will lower down when the extended neck returned back normal, which will undoubtedly result in a big change in the accuracy of the identification of the actual CTM in nonobese adult patients and a more difficult situation in obese patients, after all, a clinically meaningful 0.5cm shift will result in a failure of cricothyroidotomy. ■

Acknowledgements

This work is supported by the National Natural Scientific Foundation of China (NSFC, 30901397, 81271242); Nanjing

Medical University Grant for Science & Technology Development (08NMUZ-033); Nanjing Municipal Young Scientist Grant (201208009); and Nanjing Municipal Developmental Key Grant of Medical Science (ZKX10018).

Conflict of Interests

None

References

1. Aslani A, Ng SC, Hurley M, McCarthy KF, McNicholas M, McCaul CL. Brief report: accuracy of identification of the cricothyroid membrane in female subjects using palpation: an observational study. *Anesth Analg* 2012; 114: 987-92.
2. Elliott DS, Baker PA, Scott MR, Birch CW, Thompson JM. Accuracy of surface landmark identification for cannula cricothyroidotomy. *Anaesthesia* 2010; 65: 889-94.
3. Takasaki H, Hall T, Kaneko S, Ikemoto Y, Jull G. A radiographic analysis of the influence of initial neck posture on cervical segmental movement at end-range extension in asymptomatic subjects. *Man Ther* 2011; 16: 74-9.
4. Ben-Noun L, Sohar E, Laor A. Neck circumference as a simple screening measure for identifying overweight and obese patients. *Obes Res* 2001; 9: 470-7. ■