




RS Global
Journals

Scholarly Publisher
RS Global Sp. z O.O.
ISNI: 0000 0004 8495 2390

Dolna 17, Warsaw, Poland 00-773
Tel: +48 226 0 227 03
Email: editorial_office@rsglobal.pl

| | |
|----------------------|-------------------------------------------------------------------------------------------------------------------------------------------------------------------------------------------------------------------|
| JOURNAL | Science Review |
| p-ISSN | 2544-9346 |
| e-ISSN | 2544-9443 |
| PUBLISHER | RS Global Sp. z O.O., Poland |
| ARTICLE TITLE | DYNAMICS OF MORPHOMETRIC INDICATORS OF GINGIVAL MUCOUS MEMBRANE COMPONENTS OF RATS IN THE LATE TERMS OF CHRONIC OPIOID INFLUENCE |
| AUTHOR(S) | Fik V. B. |
| ARTICLE INFO | Fik V. B. (2020) Dynamics of Morphometric Indicators of Gingival Mucous Membrane Components of Rats in the Late Terms of Chronic Opioid Influence. Science Review. 6(33). doi: 10.31435/rsglobal_sr/30092020/7186 |
| DOI | https://doi.org/10.31435/rsglobal_sr/30092020/7186 |
| RECEIVED | 14 July 2020 |
| ACCEPTED | 23 August 2020 |
| PUBLISHED | 27 August 2020 |
| LICENSE |  This work is licensed under a Creative Commons Attribution 4.0 International License . |

© The author(s) 2020. This publication is an open access article.

DYNAMICS OF MORPHOMETRIC INDICATORS OF GINGIVAL MUCOUS MEMBRANE COMPONENTS OF RATS IN THE LATE TERMS OF CHRONIC OPIOID INFLUENCE

Fik V. B., PhD in Anatomy, Assoc. Professor, Department of Normal Anatomy, Danylo Halytsky Lviv National Medical University, Lviv, Ministry of Health of Ukraine,
ORCID ID: <https://orcid.org/0000-0002-2284-4488>

DOI: https://doi.org/10.31435/rsglobal_sr/30092020/7186

ARTICLE INFO

Received 14 July 2020

Accepted 23 August 2020

Published 27 August 2020

KEYWORDS

gingival components,
rats,
opiod analgesic,
morphometric study.

ABSTRACT

The aim of this study was to examine the morphometric parameters of the thickness of the epithelial plate of the gingival mucosa, the height of the connective tissue papillae and the diameter of the lumen of hemomicrovascular white rats in the dynamics after eight, ten and twelve weeks of chronic opioid exposure. Experimental studies were performed on white male rats of reproductive age. For twelve weeks, rats were injected intramuscularly with the opioid analgesic nalbuphine at increasing average therapeutic doses of 0.212 to 0.3 mg/kg body weight. Fragments of rat jaws were used for histological and morphometric studies. Based on the analysis of the obtained morphometric parameters of the studied components of the gums, it was found that in the late stages of chronic opioid exposure there was a significant decrease in epithelial thickness and connective tissue papillae and a significant increase in the lumen diameter of hemomicrocirculatory progression of inflammatory-dystrophic changes in periodontal tissues.

Citation: Fik V. B. (2020) Dynamics of Morphometric Indicators of Gingival Mucous Membrane Components of Rats in the Late Terms of Chronic Opioid Influence. *Science Review*.6(33). doi: 10.31435/rsglobal_sr/30092020/7186

Copyright: © 2020 Fik V. B. This is an open-access article distributed under the terms of the **Creative Commons Attribution License (CC BY)**. The use, distribution or reproduction in other forums is permitted, provided the original author(s) or licensor are credited and that the original publication in this journal is cited, in accordance with accepted academic practice. No use, distribution or reproduction is permitted which does not comply with these terms.

Opioid analgesics due to their analgesic properties are indispensable in medical practice [3]. Long-term use of opioids usually begins with the treatment of acute pain [15]. However, the unprecedented increase in overdose from prescription opioids over the past two decades has caused concern in the medical community about the validity of long-term therapeutic treatment for such patients [9, 11, 12]. Due to the urgency of this medical and social problem, there are increasingly scientific studies that focus on the study of structural reorganization and functional disorders in various organs and systems [1, 2, 13, 16], where the study of pathological changes in the organs and tissues of the oral cavity occupy a leading place in addicts, and in experimental modeling [4, 7, 8]. It is known from scientific sources that morphological changes in the organs of the oral cavity in drug addicts are manifested by an increase in destructive changes, the development of inflammation, sclerosis, which leads to the formation of signs characteristic of generalized periodontitis [5, 10]. However, according to researchers, the effect of drugs on periodontal tissues remains unclear [6]. In the available professional literature we have not found data on the peculiarities of pathomorphological changes in periodontal tissues, gingival mucosa at the microstructural level with the introduction of average therapeutic doses of opioid analgesics, in particular, the drug nalbuphine, at different times of its use.

The aim of the study was to study the morphometric parameters of the thickness of the epithelial plate of the gingival mucosa, the height of the connective tissue papillae and the diameter

of the lumen of white blood vessels in eight dynamics after eight, ten and twelve weeks of chronic opioid exposure.

Materials and methods.

Experimental studies were performed on 46 white male rats, aged 4.5 – 7.5 months. The animals were divided into four groups. The first group includes intact rats. The second group consisted of animals that were injected daily for eight weeks with the intramuscular opioid analgesic nalbuphine in terms of rats. The initial dose was 0.212 mg/kg, during the seventh and eighth weeks – 0.260 mg/kg body weight. In the third group of animals, during the ninth and tenth weeks, the dose was gradually increased to 0.283 mg/kg. In the fourth group, taking into account the average weight of the experimental group, the dosage of nalbuphine during the eleventh and twelfth weeks was gradually increased to 0.3 mg/kg.

All animals were kept in a vivarium and work on keeping, care, labeling and all other manipulations were carried out in compliance with the provisions of the European Convention for the Protection of Vertebrate Animals Used for Experimental and Other Scientific Purposes [Strasbourg, 1985], ethical principles of animal experiments”, approved by the First National Congress of Bioethics [Kyiv, 2001]. As a material for histological and morphometric studies used amputated upper and exarticulated lower jaws, taking into account the preservation of the topographic ratio of the tissues of the dental organ by conducting histological sections with a thickness of 5 – 7 μm . Histological specimens were prepared according to the conventional method by pre-decalcification using the dye hematoxylin, eosin and 7 azan by the method of Heidenhain. Morphometric examination and micrographs were performed using a MICROMed XS-4130 microscope. Further measurements were performed using ImageJ v.1.51 [7]. It was determined the average values of the thickness of the epithelium of the free gingival margin and of the gingival sulcus, the height of connective tissue papillae, as well as the diameter of the lumen of the components of the hemomicrocirculatory bed (HMCB) – arterioles, capillaries and venules of the superficial vascular bed of the mucous membrane of the gums. ANOVA analysis of variance with Tukey`s test for post-hoc was used to determine the significance of the difference between three or more groups of animals. The difference was considered significant at a value of $p < 0.05$. All statistical calculations were performed using RStudio v software. 1.1.442 and R Commander v.2.4-4.

Results and discussion.

At the end of the eighth week, all morphometric indicators tended to decrease (Fig. 1). Thus, the thickness of the epithelium of the free gingival margin decreased on 5,96 μm and its average value was $118,74 \pm 27,72 \mu\text{m}$ (significant difference when compared with intact animals, $p < 0,001$), and the thickness of the sulcular epithelium decreased on 5,10 μm , which was $52,14 \pm 10,97 \mu\text{m}$ ($p < 0,001$). Significant dynamics of decrease in height of papillae, in comparison with the previous term where this indicator decreased by 5,82 μm is fixed and was $39,84 \pm 7,22 \mu\text{m}$ (a significant difference when compared with the intact group and the previous term, $p < 0,001$). The diameters of the hemomicrocirculatory bed components during this term did not have any significant dynamics. However, all indicators of vascular lumen diameter had a statistically significant difference compared with the corresponding indicators of the intact group ($p < 0,001$). Only the diameter of venules increased slightly compared to the indicator of the previous term and was $20,31 \pm 2,23 \mu\text{m}$, this increase was statistically significant both in comparison with the indicator of the intact group ($p < 0,0001$) and when compared with the indicator of the previous term ($p < 0,05$). The capillary diameter remained almost at the same level as on the previous term and was $5,94 \pm 0,63 \mu\text{m}$ (Fig. 2). The diameter of the arterioles also remained approximately at the level of the indicator of the previous term and was $13,90 \pm 1,51 \mu\text{m}$. However, all indicators of vessel diameters had statistical significance of changes (increase) in comparison with the indicators of the intact group $p < 0,001$).

Thus, after eight weeks of action of the opioid analgesic Nalbuphine, a significant decrease in morphometric parameters of epithelial plate thickness and connective tissue papillae, as well as a statistically significant increase in the diameter of the lumen of hemomicrosvesins, due to more complicated changes in the course of the process.

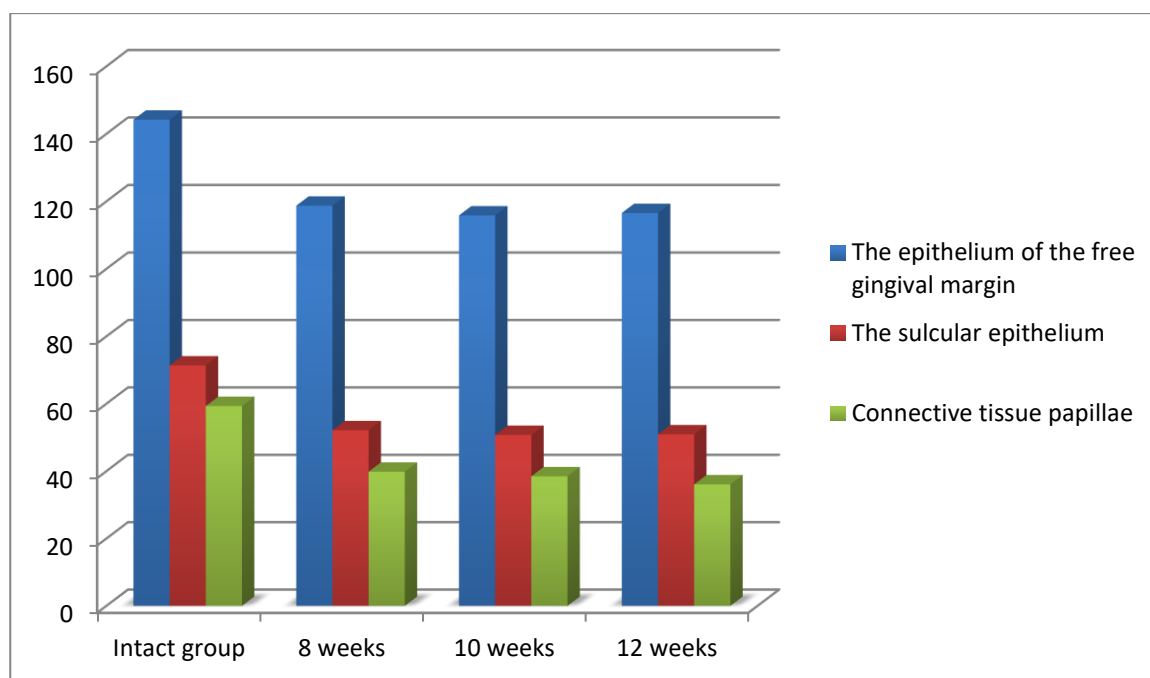


Fig. 1. Dynamics of morphometric indices of the thickness of the epithelium of the gingival and the height of the connective tissue papillae of rats during the twelve weeks of opioid exposure.

All morphometric indicators after ten weeks of opioid exposure showed a slight decrease, which had no statistically significant difference from the previous period, however, there was a significant difference between the values of the intact group. Thus, the thickness of the epithelium was reduced on 2,89 μm and was $115,85 \pm 20,41 \mu\text{m}$ on this term (significant difference when compared to the intact group, $p < 0,001$). The thickness of the sulcular epithelium decreased on 1,38 μm and was $50,76 \pm 11,61 \mu\text{m}$, and the height of the papillae decreased on 1,37 μm to $38,47 \pm 6,56 \mu\text{m}$. Both indicators have a significant difference compared to the corresponding indicators of the intact group ($p < 0,001$) (Fig. 1).

Diameters of the hemomicrocirculatory bed components had small dynamics during this term, with all indicators remaining significantly higher than the corresponding values of the indicators of the intact group. The diameters of the arterioles and capillaries decreased slightly to $12,81 \pm 1,51 \mu\text{m}$ and $5,63 \pm 0,58 \mu\text{m}$, respectively. This decrease was statistically significant when compared to the previous term indicator ($p < 0,001$ and $p < 0,05$, respectively). The diameter of the venules also remained approximately at the level of the indicator of the previous term and was $19,97 \pm 2,45 \mu\text{m}$. (Fig. 2).

Thus, at the end of the tenth week of opioid exposure, morphometric parameters had a statistically significant difference between a significant decrease in epithelial thickness and papillary height and a significant increase in vascular diameter, compared with the corresponding indicators of the intact group, indicating progression of pathomorphological changes in the mucosa of animals.

At the end of the twelfth week of opioid exposure, all morphometric indicators remained close to the previous term, showing little dynamics. However, no statistically significant difference from the previous term was found. The reliability of the difference of all indicators is preserved when compared with the intact group ($p < 0,001$). The thickness of the epithelium of the free gingival margin was $116,56 \pm 17,45 \mu\text{m}$, and the thickness of the sulcular epithelium was $50,94 \pm 6,09 \mu\text{m}$. The height of the papillae decreased on 2,38 μm to an index of $36,09 \pm 6,10 \mu\text{m}$. (Fig. 1). Indices of the diameters of the hemomicrocirculatory bed components in this term had no significant dynamics in comparison with the previous term, remaining significantly higher than the corresponding values of the indicators of the intact group. The diameter of the arterioles was $12,41 \pm 1,76 \mu\text{m}$. The capillary diameter remained almost at the same level as the previous term – $5,44 \pm 0,51 \mu\text{m}$. The diameter of the venules also remained approximately at the level of the indicator of the previous term – $19,25 \pm 1,90 \mu\text{m}$. (Fig. 2).

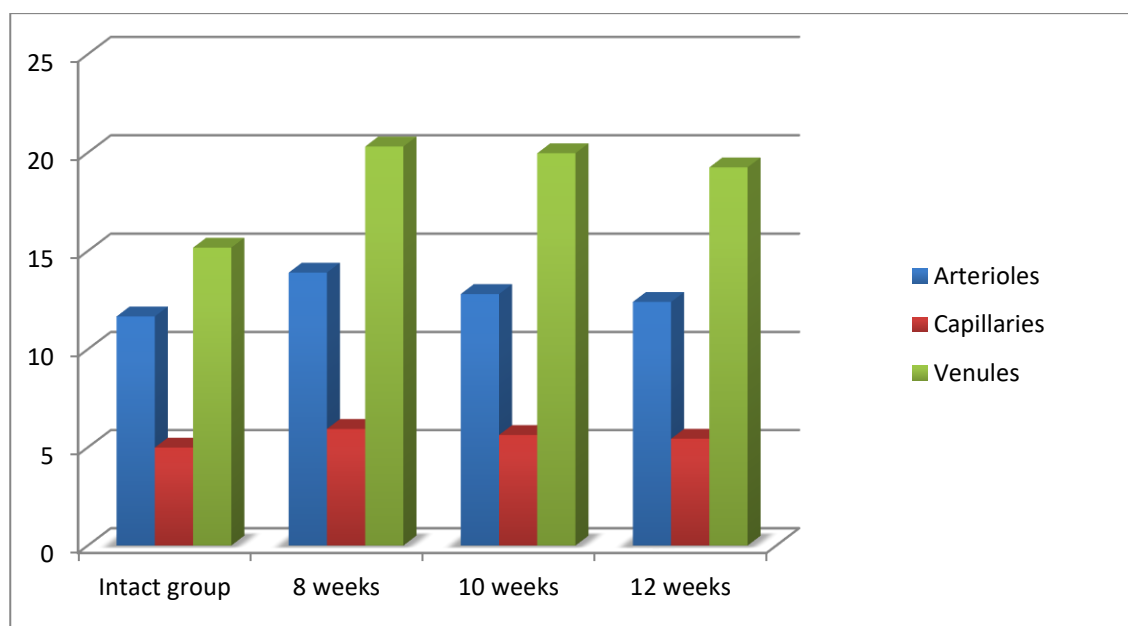


Fig. 2. Dynamics of morphometric indices of the lumen diameter of the rat gingival hemomicrovessels within twelve weeks of opioid exposure.

Thus, at the end of the twelfth week of chronic opioid exposure, the morphometric parameters of epithelial thickness and papillary height were significantly reduced, and the average values of vascular lumen diameter were significantly increased, compared with intact animals, indicating profound destructive changes in periodontal tissues.

Conclusions.

1. At the end of the eighth week, a significant decrease in epithelial thickness and connective tissue papillae, a statistically significant increase in vascular diameter, compared with the corresponding indicators of the intact group of animals, which caused dyscirculatory changes and progression of dystrophic-inflammatory process in the mucous membrane.

2. Ten weeks after the opioid, a statistically proven difference in morphometric parameters of the structural components of the gingival mucosa and components of the hemomicrocirculatory tract compared with similar values of intact animals, which led to deepening hypoxia, periodontal tissue trophism and chronicity.

3. All morphometric parameters after twelve weeks of opioid action had a statistically significant difference with the indicators of intact animals, which caused severe microcirculation disorders, congestion in blood vessels and led to severe hypoxia in periodontal tissues and progression of irreversible inflammatory-dystrophic components.

REFERENCES

1. Войценко К.І. Динаміка морфологічних змін структурних компонентів хрящового покриття колінного суглоба на ультраструктурному рівні на субхронічному та хронічному періодах експериментального опіоїдного впливу наприкінці четвертого, п'ятого та шостого тижнів / К.І. Войценко, С.В. Пальтов, В.Б. Фік, Ю.Я. Кривко Science Review. 2019; 2(19): 15-24.
2. Войцеховский В.В. Поражение легких у больных с наркотической зависимостью / В.В. Войцеховский, Н.В. Коржова, Н.Д. Гоборов, А.А. Григоренко, А.В. Пивник, О.В. Демура, А.Ю. Базилевич, В.В. Глущенко, В.И. Анисенков // Бюллетень физиологии и патологии дыхания. 2018; 68: 79-91.
3. Дацюк Н.О. Аналіз чинників, що мають вплив на доступність опіоїдних анальгетиків для медичних цілей. / Н.О. Дацюк, Л.П. Брацюнь, Д.С. Волох, Ю.І. Губський Здоров'я суспільства. 2018; 4(7):176-180.
4. Зубачик В.М. Біохімічні показники ротової рідини у наркозалежних хворих на хронічний генералізований пародонтит / В.М. Зубачик, І.Р. Федун // Клінічна стоматологія. 2017; 2:9-14.
5. Паталаха О.В. Особливості імунної відповіді та оптимізація лікування генералізованого пародонтиту у хворих токсичним опіоїдним гепатитом. [автореферат]. Харків: Ін-т мікроб. та імунол. ім.І.І.Мечнікова; 2019. 26 с.
6. Федун І.Р. Патоморфологічні зміни в яснах наркозалежних пацієнтів із дистрофічно-запальними захворюваннями тканин пародонта. / І.Р. Федун // Клінічна стоматологія. 2018; 4:31-5.

7. Fik V. Morphofunctional peculiarities of the periodontal tissue under conditions of simulated eight – week opioid effect / V. Fik, Y. Paltov, Y Kryvko. *Deutscher Wissenschaftsherold. German Science Herald.* – 2018. – №1. – p. 14 – 17.
8. Fraser A.D. Prescription Opioid Abuse and its Potential Role in Gross Dental Decay / A.D. Fraser, B. Zhang, H. Khan, H. Ma, E.V. Hersch // *Curr Drug Saf.* 2017;12(1):22-26.
9. Garg R.K. Patterns of opioid use and risk of opioid overdose death among Medicaid patients / R.K. Garg, D. Fulton-Kehoe, G.M. Franklin // *Med Care.* 2017. 55: 661–8.
10. Kayal R.A. Illicit drug abuse affects periodontal health status / R.A. Kayal, W.Y. Elias, K.J. Alharthi, A.K. Demyati, J.M. Mandurah // *Saudi Med J.* 2014; 35 (7):724–28
11. Liang Y. Assessing risk for drug overdose in a national cohort: role for both daily and total opioid dose? / Y. Liang, B.J. Turner // *J Pain* 2015;16:318–25.
12. Miller M. Prescription opioid duration of action and the risk of unintentional overdose among patients receiving opioid therapy. / M. Miller, C.W. Barber, S. Leatherman // *JAMA Intern Med* 2015;175:608–15.
13. Paltov E. V. Pathomorphological changes in rats` retinal layers at the end of the twelfth week of experimental opioid influence / E.V. Paltov, O.A. Kovalyshyn, V.B. Fik, Y.Ya. Kryvko., M.V. Podoliuk, M. V.Holeyko // *International Academy Journal Web of Scholar* 4(34) April 2019 C. 19-22.
14. Schneider C.A. NIH Image to ImageJ: 25 years of image analysis / C.A. Schneider, W.S. Rasband, K.W. Eliceiri // *Nat Methods.* 2012; 9(7): 671–675.
15. Shah A. Characteristics of initial prescription episodes and likelihood of long-term opioid use—United States, 2006–2015. / A. Shah, C.J. Hayes, B.C. Martin // *MMWR Morb Mortal Wkly Rep* 2017;66:265–269.
16. Soleimanpour, H. Opioid drugs in patients with liver disease: a systematic review / H. Soleimanpour, S. Safari, K. Shahsavari Nia, S. Sanaie, S.M. Alavian // *Hepat. Mon.* 2016;16(4):e32636.