

## Complex treatment of children with distal malocclusions and osteopathy problems

\*<sup>1</sup>Cristina Postaru, MD, Assistant Professor; <sup>2</sup>Victoria Malkina, MD, Assistant Professor;  
<sup>3</sup>Natalia Pankratova, MD, PhD, Associate professor; <sup>2</sup>Mihail Postnikov, MD, PhD, Associate Professor

<sup>1</sup>Pavel Godoroja Department of Propaedeutical Stomatology  
 Nicolae Testemitsanu State University of Medicine and Pharmacy, Chisinau, the Republic of Moldova.

<sup>2</sup>Department of Stomatology, State University of Medicine, Samara, Russian Federation.

<sup>3</sup>Department of Orthodontic and Prosthetic Pediatrics, Moscow State University of Medicine and Dentistry, Russian Federation

\*Corresponding author: c\_railean@yahoo.com. Received July 05, 2018; accepted September 25, 2018

### Abstract

**Background:** The aim of the study included interdisciplinary efficiency in treatment children with class II Angle malocclusions in association with osteopathy problems.

**Material and methods:** there were examined 30 patients of the 6- 12 years old with class II Angle malocclusion in association with osteopathy problems. The patients were divided into two groups, the main group consists of children, who have complex treatment, and in the control group they have just orthodontic treatment.

**Results:** The results show that patients with complex treatment have potentially positive contributions in anthropometric changes as well as in facial appearance and postural problems. The orthodontic treatment of patients, from the control group, was 1.5 times longer than in the main group. So complex treatment of patients combined with postural problems is much shorter and have a positive influence on musculoskeletal disorders than in the control group.

**Conclusions:** Efficient complex treatment of children with malocclusion and osteopathic problems influences the duration of orthodontic treatment of class II malocclusion conditioned by distal position of mandible.

**Key words:** malocclusions, orthodontic treatment, functional therapy, osteopathic treatment.

### Introduction

Human body is considered to be a multifunctional and self-regulating apparatus by its nature. "The systems that have the similar direction or having a common origin and location are joined in one word—apparatus. So, the skeletal system and its compounds, organs and muscular system are all can be connected in musculoskeletal system" [1].

All components of stomatognathic system have a morphofunctional relation among them which can be able to change into pathological if one of its elements is disturbed. Among some aspects of stomatognathic system such as mandible position, dentition phase, dental or skeletal occlusion and temporomandibular disorders can be associated with body posture alteration [2,3,4,5]. That's why it is important to have a multidisciplinary approach in treatment of malocclusions in children and it should be taken into consideration by orthodontics in practical as well as in scientific research. "From contemporary point of view, mastication system is a complex interaction and interdependent system of organs participating not just in mastication but in respiration function, in the formation of voice and speech" [6]. Kalvelis D. A. once wrote that "orthodontic is a science which deals with the problems of disorders and regulation of growth and development, as well as alignment the teeth and all stomatognathic system that correlates with changes in shape, involving functional disorders of mastication system and changes in facial appearance of humans" [7]. Orthodontic is a department of dentistry, which studies the di-

agnosis, prevention and treatment of malalignment of teeth, dental arches and bones [8].

In normal occlusion the centric relation coincides with centric occlusion. In malocclusion this relation is not the same because lower jaw can be situated forward or back (overjet or reverse overjet). It also can be often seen no contact between teeth. We have the concept of normal occlusion which is considered to have maximal contact between teeth and make the mastication system function good [9] (fig. 1).

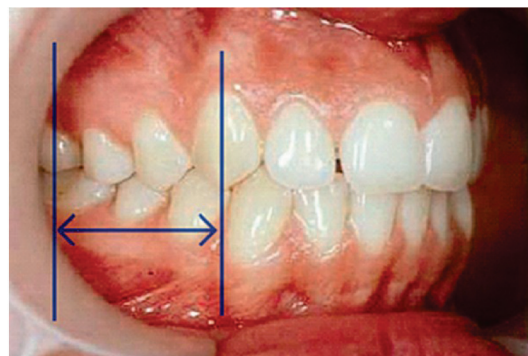


Fig. 1. Normal occlusion.

Law of creativity requires that an idea of an object should consider this object in the same content of signs. That's why orthodontics needs reliable information on the relationships and condition of the musculoskeletal system.

Osteopathy allows determining physically handicapped

disorders and the action of it is to treat this morphofunctional changes.

At the beginning of 20<sup>th</sup> century the founder of craniocervical osteopathy William Garner Sataland discovered the theory of micro-mobility of cranial bones through the observation and palpation. He revealed the existence of a slow rhythmic impulse inside the skull that is synchronized with a very perceptible sacral movement. Clinical experiments made him confirm that the base physiological complex is the generator of the body's homeostasis considered as a functional unity called by him the primary respiratory mechanism [18].

One of the basic concepts of osteopathic science is the cranio-sacral system. This anatomical and functional system includes brain shells and the place of their attachment, cranial bones and their sutures, spine including the sacrum and coccyx, membranes lining the cerebral canal as well as the impact on these structures [14].

We mostly pay attention to the component of this system called sphenoccipital synchondrosis especially on sphenoid bone which has relation to many cranial bones (fig.2). The forces developed during mastication, swallowing and contact of teeth influence the micro-mobility of sphenoid bone and other cranial bones, but direction of teeth forces influence the movement of each cranial bone and sutures. These processes have an impact on the dura mater which is attached to the bones of the cranium. Long-term action of torque is reflected in the movement of the cerebrospinal fluid along the brain and spinal cord [12,13,17].

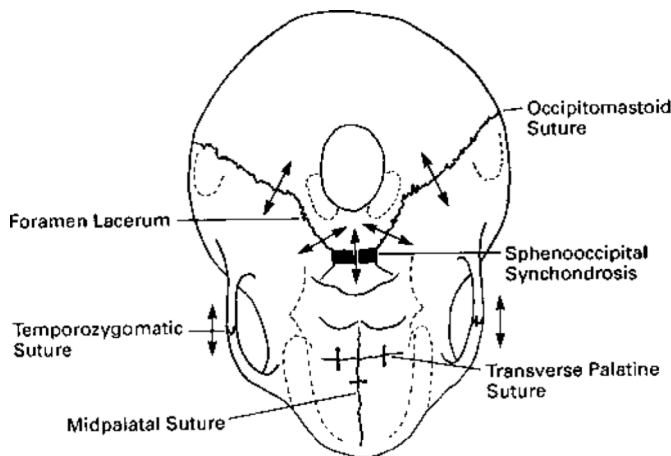


Fig. 2. Sphenooccipital synchondrosis.

Muscles of head and neck functionally integrated and work together with other muscles within the fascial spider web which is also the subject of osteopathy. If changes in

the musculoskeletal system occur, there can be pathological tension of the membranes, which makes difficult normal physiological movement [18-20].

Abnormal body posture can make changes in function in all cranial bones up to the compression of the skull and as consequences of the malocclusion. Also we can see reverse action of this system [12].

Occlusion is considered a dynamic interaction of the components of the mastication system, determining the relationship of the teeth. It is a complex action included the teeth, temporomandibular joint (TMJ) and oral-facial muscles. High prevalence of malocclusion among children and adolescents and its effects on body posture, make orthodontic treatment to be indicated in children with osteopathy problems [21, 22].

Every system works relatively to a certain center. We think that the center of occlusion is sphenoccipital synchondrosis, in this way the occlusion is in direct relation to cranial-sacral system.

Anatomic and function aspects of stomatognathic system together with complex neuromuscular relations make an important field of cooperation between orthodontic and orthopedics. So, the interdisciplinary approach is being taken increasingly into account in these special cases [23].

The aim of the study is to evaluate the results of a complex treatment of class II malocclusion in children of 6-12 years old.

**Material and methods**

This study included 30 patients within the age range of 6-12 years with class II malocclusion, nonskeletal problems. Examining the patients in occlusion can reveal any antero-posterior problems in the buccal and in the anterior relationships (fig. 3). The patients were divided in two groups (study and control group) according to the treatment methods (tab. 1). In the study group which consisted of 12 children, it was made both orthodontic and osteopathy treatment. In the control group that consisted of 18 children it was made just orthodontic treatment (fig. 4). Informed consent was obtained from patients.

**Table 1**  
**Distribution of patients within the age range of 6-12 years with class II malocclusion in two groups during examination**

Patients with class II malocclusion	Study group	Control group
Complex treatment	20% (6 patients)	30% (9 patients)
Orthodontic treatment	20% (6 patients)	30% (9 patients)

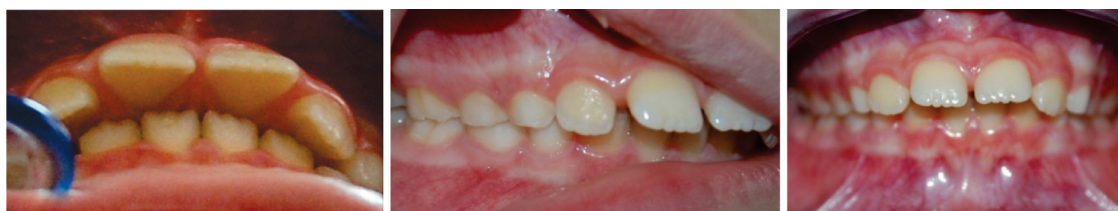

Fig. 3. Patient A., 10 years, with class II malocclusion due to distal position of the mandibular, overjet – 5mm.

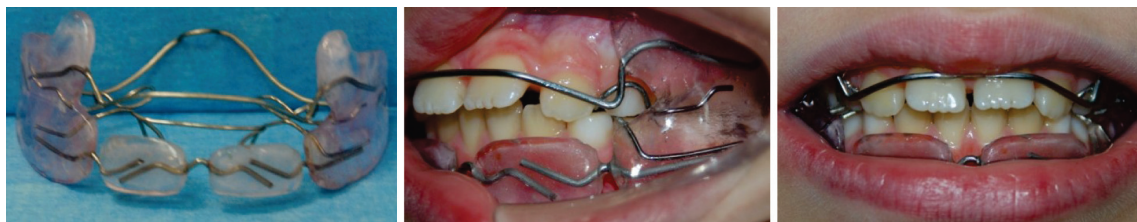

Fig. 4. The Frankel II appliance, used in patient with Class II malocclusion in both groups.

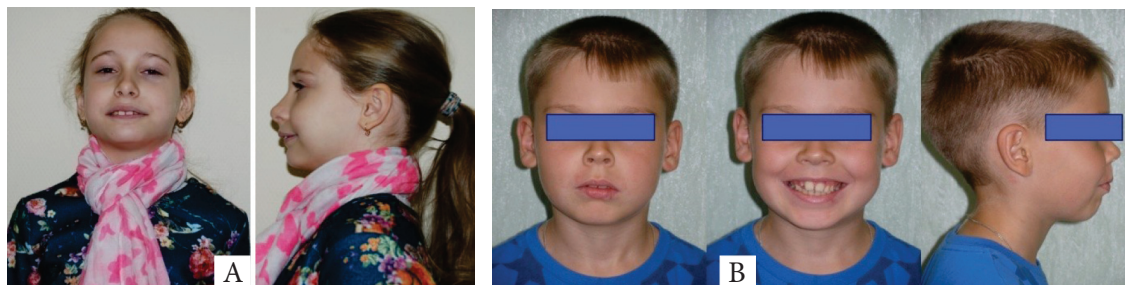

Fig. 5. Facial proportion in the frontal and lateral views of the patient A., 10 years old (a) and patient B., 8 years (b) with class II malocclusion due to distal position of the mandible.

Clinical evaluation of the patient was carried out according to the general accepted scheme (interview/questionnaire, facial and dental appearance). A systematic examination of facial appearance was done in the following steps: facial proportions and symmetry in the frontal and lateral views, position of head and body (fig. 5).

It was also made a clinical examination of this patient by osteopathy which assessed interview, posture. The position of the shoulder and pelvic bones was studied (was compared the level of shoulder joints, shoulder blade, crests, presence of lateral rotation of pelvic bones). The deviation of the spinal line from the vertical axis form of back was noted (deformation by kyphosis and lordosis or smoothing of physiological bends) (fig. 6).

For establishing the dominant dysfunction were used active and passive tests by an osteopathic physician. Palpation diagnosis was performed on the skull: sphenoccipital synchondrosis, estimation of primary breathing mechanism, test of suture dysfunction of the bones of the brain and facial

skull, test for functional evaluation of temporomandibular joint (TMJ) and muscles which participate in opening and closing of the mandible.

The dental cast analysis evaluates sagittal and transversal dimensions of dental arch, X-rays investigation was made as panoramic radiograph and cephalometric analysis. Cephalometric analysis used Dolphin Imaging program to determine conditionality of malocclusion- insignificant distal position of mandible. Patients who did not have any previous orthodontic treatment were included in research. Exclusion criteria included patients with complicated diseases, cranial-facial trauma, with severe neurological disorders.

Patients from both groups were treated with functional appliance Frankel II and the time of wearing this appliance lasted 8 months in the study group, 12 months in the control group. Also the patients performed osteopathic correction once in two weeks for two months, then once in three-four weeks using the main technique: technique of compression of the fourth ventricle CV-4; technique of venous sinus



Fig. 6. Posture of the patient who was included in complex treatment. (Both orthodontic and osteopathy treatment).

drainage; decompression technique of sphenoccipital synchondrosis; elimination of suture dysfunction; technique of correction of muscles of cervical part; myofascial relaxation of mastication muscles, technique of TMJ on upper and lower jaw. After each procedure the system of the body was balanced along the craniosacral axis. The protocol of this study was approved by the Human Research Ethics Committee in State University from Samara. The parents were informed about the procedures of the study and provided their written informed consent prior to child's participation in the research.

**Results and discussion**

The testing osteopathy revealed the following dysfunctions:

- Sphenoccipital synchondrosis, in 100% in study and control groups
- Primary breathing mechanism in 100% in study and control groups
- Deregulation of 4<sup>th</sup> horizontal lines in 100% in study and control groups
- Hyoid bone in 85% of patients from study and control groups

So, after the osteopathy testing was made, the same initial level of certain dysfunction was identified in study and control groups. Complex treatment was conducted in the study group while the control group underwent just orthodontic treatment.

Changes in dimensions of dental arches that were seen before complex treatment of class II malocclusion in patients of 6-12 years old in both groups are identical to normal and are shown in figure 7.

After 8±0.3 months of complex treatment there was a positive evolution in changes of the anthropometric indicators (fig. 8) as well as in facial appearance and postural problems (fig. 9).

Patients from study groups were treated by correction of the posture under the scheme that was described above, once

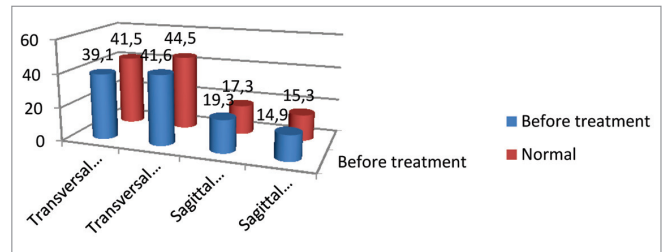


Fig. 7. Changes in dimensions of dental arches before complex treatment of class II malocclusion in patients of 6-12 years compared to normal.

in two weeks during two months, continued once in a week. In 50% of patients from the study group were noted reduced cases of sphenoccipital synchondrosis disorders (p=2.1; p<0.05) compared to the control group (p=3.1; p<0.001). Also there were changes in primary breathing mechanism in 45% of patients from the study group ( p=1,97; p<0.05), but in the control group – in 85% of cases (p=2,58; p< 0,01), it was also reduced dysfunction of hyoid bone in 35% of cases (p=1,0; p>0,05), but in the control group in 75% of cases ( p=2,58; p<0,01).

Consequently, making the diagnosis correctly, determining the conditionality of malocclusion, making up a complex treatment plan and choosing orthodontic device in both study and control groups lead to decrease of the function disorders in human body.

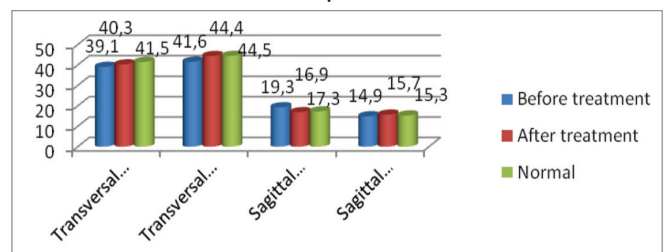


Fig. 8. Changes in anthropometric measurements on models before and after complex treatment of distal occlusion in patients of 6-12 years old compared to normal.

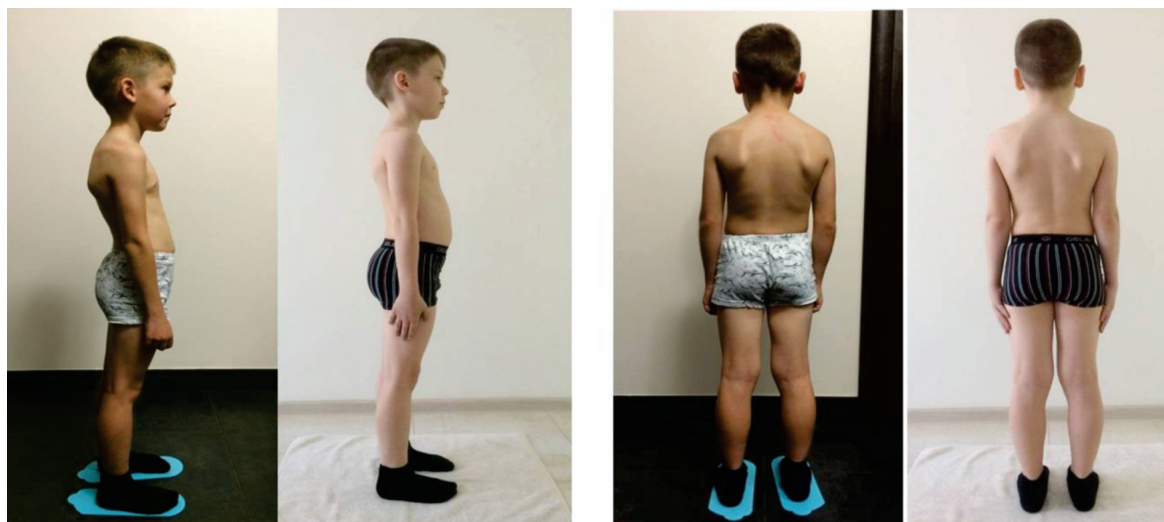

Fig. 9. Postural changes in patient of 8 years old (before treatment) and the same patient 9 years old (after orthodontic treatment).

The results showed that after 12,0±0,5 months was observed positive evolution in changes of anthropometric measurements as well as in osteopathic disorders. Control group established the same changes in anthropometric measurements because the initial data were identical.

The timing of treatment was different in both groups: the control group didn't have any help from osteopathic doctor and as a result the time of orthodontic treatment increased ( $p=2,61$ ;  $p<0,01$ ).

The statements of scientific research confirmed all the processes of the relations and dependencies in the body. The problems of malocclusions are eliminated faster, in less time with positive solution of osteopathic problems. At the same time, just orthodontic treatment of distal malocclusion in children 6-12 years old also received positive solution in dysfunctional osteopathic disorders, but it was more time consuming.

### Conclusions

1. Osteopathic treatment really influences in reducing the time of distal malocclusion treatment, dental-alveolar form due to insignificant distal position of the mandible.

2. Making correctly diagnosis, determining the conditionality of malocclusion, planning a complex treatment, choosing orthodontic appliances in both groups lead to reducing the cases of dysfunctions in body.

### References

- Mikhailov SS. Anatomiiia cheloveka [Human's anatomy]. Moscow: Meditsina; 1984. 704 p. Russian.
- Sakaguchi K, Mehta NR, Abdallah EF, Forgione AG, Hirayama H, Kawasaki T, et al. Examination of the relationship between mandibular position and body posture. *Cranio*. 2007;25(4):237-49.
- Ishizawa T, Xu H, Onodera K, Ooya K. Weight distributions on soles of feet in the primary and early permanent dentition with normal occlusion. *J Clin Pediatr Dent*. 2005;30(2):165-8.
- Nobili A, Adversi R. Relationship between posture and occlusion: a clinic and experimental investigation. *Cranio*. 1996;14(4):274-85.
- Perinetti G. Temporomandibular disorders do not correlate with detectable alterations in body posture. *J Contemp Dent Pract*. 2007;8(5):60-7.
- Kurliandskii VIu. Zubocheliustnye anomalii u detei i metody lecheniia: Ortodontiia. [Dentofacial anomalies in children and treatment methods: Orthodontics]. Moscow: Medgiz; 1957. 222 p. Russian.
- Kalvelis DA. Ortodontiia. Zubo-cheliustnye anomalii v klinike i eksperimente. [Orthodontics. Tooth- maxillary anomalies in the clinic and experiment]. Leningrad: Meditsina; 1964. 238 p. Russian.
- Petrovskii BV, editor. Entsiklopedicheski slovar' meditsinskikh terminov. T.2. [Encyclopaedic dictionary of medical terms]. Moscow: Sovetskaia entsiklopediia; 1983. 500 p. Russian.
- Persin LS. Vidy zubocheliustnykh anomalii i ikh klassifitsirovanie [Types of dentoalveolar anomalies and their classification]. Moscow: MGMSU; 2006. 23 p. Russian.
- Baroeva IV, Kolesov MA, Persin LS, Slabkovskaia AB. [Modification of the Persin appliance for treatment of patients with distal occlusion]. *Ortodontiia*. 2014;4(68):44-50. Russian.
- Postnikov MA. Ortodonticheskoe lechenie patsientov s anomaliiami okkliuzii v sagittal'nom napravlenii i chastichnoi adentiei. [Orthodontic treatment of patients with anomalies of occlusion in the sagittal direction and partial adentia]. Samara: Ofort; 2015. 120 p. Russian.
- Amigues J-P. La pratique ostéopathique: L'articulation temporo-mandibulaire [Osteopathic practice: The temporomandibular joint]. Aix en Provence: Verlaque; 1990. 240 p. French.
- Magoun HI. Osteopathy in the cranial field. Kirksville: Journal Printing Co; 1976. 380 p.
- Carlson J. Fiziologicheskaia okkliuziia [Physiologic occlusion]. Moscow: Midwest Press; 2009. 218 p. Russian.
- Klozad MA, Daraian B. [Osteopathic concept of occlusion]. 2007. 25 p. Russian.
- Retzlaff EW, Michael DK, Roppel RM. Cranial bone mobility. *J Am Osteopath Assoc*. 1975;74(9):869-73.
- Upledger JE, Vredevoogd JD. Kraniosakral'naia terapiia. Ch.1. [Craniosacral Therapy. Part 1]. St. Petersburg: Severnaia Zvezda; 2010. 390 p. Russian.
- Postnikov MA. [Optimization of orthodontic treatment of children with mesial occlusion during the shift and after the change of teeth] [dissertation]. Samara (Russia): Samara State Medical University; 2016. 316 p. Russian.
- Postnikov MA, Stepanov GV, Pankratova NV, Kirilin MM, Malkina VD. [The use of cephalometric analysis in the computer program "Dolphin Imaging" in planning the treatment of patients with maxillofacial anomalies]. *Ortodontiia* 2017;1(77):16-27. Russian.
- Bredikhin AV, Bredikhin KA, Chekha OA. [Craniosacral system, its components and signs of dysfunction]. *Meditsinskie novosti*. 2014;(11):43-49. Russian.
- Brunelle JA, Bhat M, Lipton JA. Prevalence and distribution of selected occlusion characteristics in the US population, 1988-1991. *J Dent Res*. 1996;75 Spec No:706-13.
- Perinetti G, Cordella C, Pellegrini F, Esposito P. The prevalence of malocclusion traits and their correlations in mixed dentition children: results from the Italian OHSAR Survey. *Oral Health Prev Dent*. 2008;6(2):119-29.
- Korbmacher H, Eggers-Stroeder G, Koch L, Kahl-Nieke B. Correlations between anomalies of the dentition and pathologies of the locomotor system – a literature review. *J Orofac Orthop*. 2004;65(3):190-203. doi:10.1007/s00056-004-0305-3.

