

**EARLY POSTOPERATIVE DELAYED
HEARING LOSS:
Patterns of behavioural and electrophysiological
auditory responses following vestibular
schwannoma surgery**

A thesis submitted in partial fulfilment of the
requirements for the Degree of

Master of Audiology

in the Department of Communication Disorders
at the University of Canterbury

by

Melissa J. Babbage

University of Canterbury

2009

ACKNOWLEDGEMENTS

I would like to thank my supervisors; Dr Greg O’Beirne and Mr Phil Bird, for their enthusiasm, help, and encouragement throughout the last year. I also gratefully acknowledge Mr Martin MacFarlane for sharing his time and expertise, and for accommodating and assisting me in the operating theatre.

I would like to thank Mr Jeremy Hornibrook and John Gourley for providing their time to help with the electrocochleographic recordings in this study. Thank you also to the Audiology Department at Christchurch Hospital for sharing your space and equipment, and to the staff in the Neurosurgical ward for assisting me and making my time at the hospital easier.

I am extremely grateful to the patients who participated in this study. Their co-operation, tolerance and good humour were remarkable. I would also like to acknowledge the families and friends of these patients who were so accommodating and friendly during my frequent visits.

I would like to thank The Oticon Foundation in New Zealand for their generous assistance with funding for travel to the 6th Australasian Auditory Neuroscience Workshop. Canberra, Australia, 31st January 2009.

Thank you to my classmates, for their friendship and moral support; to my family, who have always encouraged me; and to Bryan, whose unwavering support and patience over the last year I am so grateful for.

ABSTRACT

Following vestibular schwannoma excision, a subset of cases has been reported in which hearing is present immediately after surgery, but is lost in the early postoperative period. Such cases have rarely been reported, and the postoperative audiological data collected from patients in these cases lacks the time resolution necessary to determine the pathophysiological mechanism responsible for the pattern of hearing loss. The present study aimed to more clearly define delayed hearing loss by collecting detailed data documenting changes in behavioural and electrophysiological auditory responses following vestibular schwannoma surgery. In particular, we aimed to use this data to determine the time course of changes in auditory function and to identify whether the site of impairment was cochlear or neural.

Preoperative and daily postoperative monitoring of auditory function was performed in 19 patients undergoing vestibular schwannoma excision via the retrosigmoid approach at Christchurch Public Hospital. The pre- and postoperative assessment battery included pure-tone and speech audiometry, tympanometry, tone decay, distortion product otoacoustic emissions (DPOAEs), and auditory brainstem response (ABR) measurement. Intraoperative ABR was performed in four cases in which clear preoperative waveforms were present. Transtympanic electrocochleography (ECoChG) was carried out if wave I was lost in the early postoperative period.

Thirteen of the 19 patients suffered immediate anacusis following surgery and six had measurable hearing postoperatively. The behavioural and electrophysiological data collected in each case is discussed with regard to the likely pathophysiology of pre- and postoperative hearing loss.

No patients demonstrated behavioural evidence of delayed hearing loss, however a gradual deterioration of ABR in the early postoperative period was observed in Case 16. ECoChG and DPOAEs in this case indicated the presence of cochlear function although the patient presented with immediate postoperative anacusis in the ipsilateral ear. These results are consistent with postoperative retrograde degeneration of the cochlear nerve.

TABLE OF CONTENTS

ACKNOWLEDGEMENTS	II
ABSTRACT.....	III
TABLE OF CONTENTS	IV
LIST OF FIGURES	VI
LIST OF TABLES	X
1. INTRODUCTION.....	1
1.1. THE PERIPHERAL AUDITORY PATHWAY.....	2
1.1.1. <i>Afferent auditory transmission.....</i>	<i>2</i>
1.1.2. <i>Efferent auditory transmission.....</i>	<i>4</i>
1.2. THE INTERNAL AUDITORY CANAL AND THE VESTIBULOCOCHLEAR NERVE	6
1.3. THE VASCULAR SUPPLY TO THE COCHLEA AND VESTIBULOCOCHLEAR NERVE	8
1.4. VESTIBULAR SCHWANNOMAS	10
1.5. ELECTROPHYSIOLOGICAL TECHNIQUES.....	12
1.5.1. <i>Auditory Brainstem Response</i>	<i>12</i>
1.5.2. <i>Electrocochleography.....</i>	<i>15</i>
1.5.3. <i>Otoacoustic emissions</i>	<i>18</i>
1.6. PREOPERATIVE HEARING	20
1.7. TONE DECAY	24
1.8. SURGICAL INTERVENTION	26
1.9. INTRAOPERATIVE MONITORING	27
1.10. NERVE ORIGINS OF THE VESTIBULAR SCHWANNOMA	28
1.11. POSTOPERATIVE OUTCOMES	30
1.12. EARLY POSTOPERATIVE DELAYED HEARING LOSS	32
1.13. PROPOSED MECHANISMS LEADING TO EARLY POSTOPERATIVE DELAYED HEARING LOSS	35
1.13.1. <i>Retrograde degeneration following direct mechanical insult to the cochlear nerve?</i>	<i>36</i>
1.13.2. <i>Retrograde degeneration following a disturbance of neural microcirculation?</i>	<i>37</i>
1.13.3. <i>Collapse of the internal auditory artery?</i>	<i>38</i>
1.13.4. <i>Post-traumatic inflammatory reaction?</i>	<i>38</i>
1.14. POTENTIAL TREATMENTS OF EARLY POSTOPERATIVE DELAYED HEARING LOSS...39	
1.15. AIMS AND HYPOTHESES	39
2. METHOD	42
2.1. PARTICIPANTS.....	42
2.2. GENERAL PROCEDURE	43
2.3. SPECIFIC PROCEDURES	45
2.3.1. <i>Pure-tone and speech audiometry.....</i>	<i>45</i>
2.3.2. <i>Tympanometry.....</i>	<i>46</i>
2.3.3. <i>Pre- and postoperative ABR.....</i>	<i>47</i>
2.3.4. <i>Intraoperative ABR</i>	<i>50</i>
2.3.5. <i>DPOAE measurement and analysis.....</i>	<i>52</i>
2.3.6. <i>Tone decay.....</i>	<i>53</i>
2.3.7. <i>ECochG measurement and analysis</i>	<i>54</i>
2.4. INTERPRETATION OF RESULTS	57
2.5. ETHICAL CONSIDERATIONS	58

3. RESULTS	59
3.1. PREOPERATIVE HEARING AND OVERALL RATE OF HEARING PRESERVATION	59
3.2. PERMANENT POSTOPERATIVE ANACUSIS	62
3.2.1. <i>Anacusis with preservation of electrophysiological responses</i>	<i>65</i>
3.3. POSTOPERATIVE HEARING PRESERVATION	75
3.3.1. <i>Postoperative preservation of behavioural and electrophysiological responses.....</i>	<i>78</i>
3.3.2. <i>Postoperative hearing preservation with loss of electrophysiological responses</i>	<i>96</i>
4. DISCUSSION	97
4.1. TUMOUR SIZE.....	98
4.1.1. <i>The influence of tumour size on preoperative hearing</i>	<i>99</i>
4.1.2. <i>The influence of tumour size on postoperative hearing.....</i>	<i>100</i>
4.2. PREOPERATIVE AUDITORY FUNCTION	101
4.2.1. <i>Causes of preoperative hearing loss</i>	<i>103</i>
4.3. PREOPERATIVE PROGNOSTIC FACTORS FOR HEARING OUTCOME	106
4.4. NERVE OF TUMOUR ORIGIN	108
4.5. POSTOPERATIVE HEARING PRESERVATION	109
4.5.1. <i>Neural origin of hearing deterioration</i>	<i>111</i>
4.5.2. <i>Cochlear origin of hearing deterioration</i>	<i>113</i>
4.5.3. <i>Improvement in ABR</i>	<i>114</i>
4.7. POSTOPERATIVE ANACUSIS	115
4.7.1. <i>Anacusis with anatomical preservation of the cochlear nerve</i>	<i>116</i>
4.8. RETROGRADE DEGENERATION OF THE COCHLEAR NERVE	124
5. SUMMARY OF MAIN FINDINGS	126
5.1. CLINICAL IMPLICATIONS	127
5.2. LIMITATIONS	128
5.3. DIRECTIONS FOR FUTURE RESEARCH	130
REFERENCES.....	132
APPENDIX A	150
APPENDIX B	160

LIST OF FIGURES

Figure 1. The peripheral auditory system. Sound waves travel through the external auditory canal and the middle ear to the cochlea. The cochlea performs mechano-electrical transduction to create a signal that is transmitted to the brain via the cochlear nerve (adapted from http://www.virtualmedicalcentre.com/anatomy.asp?sid=29&title=Ear).	3
Figure 2. The normal anatomic relationship of the right internal auditory canal (from Wilson, Hodgson, Gustafson, Hogue, & Mills, 1992).	7
Figure 3. Schematic drawing of the vascular supply to the labyrinth (from Baloh & Honrubia, 2001).	8
Figure 4. A schematic depiction of a vestibular schwannoma growing within the IAC and expanding out into the CPA. In this case the brainstem is compressed by the tumour. The intracanalicular (IAC) portion of the tumour is outlined in red, and the extracanalicular or CPA portion of the tumour is indicated by the blue box (adapted from http://www.neurosurgery.ufl.edu/Patients/acoustic.shtml).	11
Figure 5. The Auditory Brainstem Response (ABR) to click stimuli at increasing intensities in a normal hearing subject (from Gorga et al., 2006).	13
Figure 6. The human electrocochleogram evoked by click stimuli. The top trace displays responses to rarefaction (R) and condensation (C) polarity clicks. The middle trace shows the addition of R and C responses, which enhances the Summating Potential (SP) and Action Potential (AP). Subtracting R and C responses (bottom trace), enhances the Cochlear Microphonic (CM) (from ASHA, 1988, based on data from Coats, 1981).	16
Figure 7. ABR traces from the right ear of a subject who underwent repeated ABRs over a 3 year period because of a family history of bilateral acoustic tumours. A small vestibular schwannoma was detected using enhanced CT scanning in 1983, around the time of the around the time of the third trace shown above. Note the progressively longer wave I-V interval as the tumour increases in size and the loss of amplitude of waves II and III (from Josey, 1987).	21
Figure 8. The results of Carhart's threshold tone decay in eighth cranial nerve lesions. In curve A a plateau is reached at 50 dB, in curve B and C tone decay has reached the limits of the audiometer (from Morales-Garcia & Hood, 1972).	25
Figure 9. Schematic of vestibular schwannomas originating from the inferior (a) and superior (b) vestibular nerves (adapted from Wilson, Hodgson, Gustafson, Hogue, & Mills (1992), incidence data from Khrais et al., 2008).	29
Figure 10. Intraoperative ABR during vestibular schwannoma excision. Note the gradual, reversible loss of wave V (from Strauss et al., 2001).	34
Figure 11. The AAO-HNS (1995) guidelines for classifying hearing in cases of vestibular schwannomas. Pure-tone average at 0.5, 1, 2 and 3 kHz is shown on the vertical axis, and the	

maximum word recognition score is shown on the horizontal axis. The white boxes, A and B, indicate “serviceable” hearing.	46
Figure 12. Electrode configuration for ABR recordings. Fz = high forehead, Fpz = lower forehead, A1 = left earlobe, A2 = right earlobe.	48
Figure 13. Photographs of set-up used for intraoperative ABR monitoring in Case 8. Part a shows the positioning of self-adhesive Ag/AgCl- electrodes and the transducer on the ipsilateral side. The ABR monitoring equipment is shown in part b.	51
Figure 14. Electrocochleogram elicited by click stimuli illustrating the measurement of the amplitude of the compound action potential (AP) and summing potential (SP) relative to a baseline value (adapted from Ferraro, 2000).	56
Figure 15. An electrocochleogram elicited by tone-burst stimuli. The amplitude of the summing potential (SP) was measured at the midpoint of response (B), with reference to the pre-stimulus baseline value (A) (from Ferraro et al., 1994).	57
Figure 16. Pre- and postoperative hearing classifications for the ear ipsilateral to the tumour according to the Committee on Hearing and Equilibrium guidelines (1995), for all participants. The number adjacent to each closed dot denotes the case to which that marker refers.	59
Figure 17. Case 10: Electrophysiological auditory responses collected before and after vestibular schwannoma surgery. Part A shows a time-ordered sequence of click-evoked ABR traces from the left and right ears; with the latencies of waves present in these traces shown in part B. Part C shows the serial DPOAE data collected pre- and postoperatively; + indicates present DPOAEs and – indicates their absence.	69
Figure 18. Case 10: Behavioural audiological responses collected before and after vestibular schwannoma surgery. Part A shows a time-ordered sequence of results of pure-tone and speech audiometry. The right and left ears are represented by circles and crosses respectively (filled circles and double crosses indicate the use of contralateral masking). Part B shows the duration of tone perception at each intensity level presented in tone decay testing.	70
Figure 19. Case 16: Electrophysiological auditory responses collected before and after vestibular schwannoma surgery. Part A shows a time-ordered sequence of click-evoked ABR traces from the left and right ears; with the latencies of waves present in these traces shown in Part B.	71
Figure 20. Case 16: Electrophysiological auditory responses collected before and after vestibular schwannoma surgery. Part A shows transtympanic electrocochleograms evoked from the left ear by tone-bursts (left panel) and clicks (right panel), 12 weeks after surgery. The amplitudes of the summing potential (SP) and compound action potential (CAP) in these recordings are shown in Part B. Part C shows the serial DPOAE data collected pre- and postoperatively; + indicates present DPOAEs and – indicates their absence.	72
Figure 21. Case 16: Behavioural audiological data collected before and after vestibular schwannoma removal. Results of pure-tone and speech audiometry are shown in Part A. The right and left ear are shown by circles and crosses respectively (filled circles and double	

crosses indicate the use of contralateral masking). Part B shows the duration of tone perception at each intensity level presented in tone decay testing.....73

Figure 22. Case 16: ABR recorded from the ipsilateral ear at important points during vestibular schwannoma surgery. The blue traces show the waveforms following smoothing using a 21-point running average, and grey traces show the raw data.74

Figure 23. Change in PTA, WRS and AAO-HNS (1995) hearing classification from the pre- to postoperative period in the six patients in whom hearing was preserved. Preoperative hearing is indicated by the open circle and postoperative hearing is indicated by the closed circle.....76

Figure 24. Case 8: Electrophysiological auditory responses collected before and after vestibular schwannoma surgery. Part A shows a time-ordered sequence of click-evoked ABR traces from the left and right ears; with the latencies of waves present in these traces shown in part B. Part C shows the serial DPOAE data collected pre- and postoperatively; + indicates present DPOAEs and – indicates their absence.86

Figure 25. Case 8: Behavioural audiological data collected before and after vestibular schwannoma removal. Results of pure-tone and speech audiometry are shown in Part A. The right and left ear are shown by circles and crosses respectively (filled circles and double crosses indicate the use of contralateral masking). Part B shows the duration of tone perception at each intensity level presented in tone decay testing.....87

Figure 26. Case 8: ABR recorded from the ipsilateral ear at important points during vestibular schwannoma surgery. The red traces show the waveforms following smoothing using a 21-point running average, and grey traces show the raw data.88

Figure 27. Case 11: Electrophysiological auditory responses collected before and after vestibular schwannoma surgery. Part A shows a time-ordered sequence of click-evoked ABR traces from the left and right ears; with the latencies of waves present in these traces shown in part B. Part C shows the serial DPOAE data collected pre- and postoperatively; + indicates present DPOAEs and – indicates their absence.89

Figure 28. Case 11: Behavioural audiological data collected before and after vestibular schwannoma removal. Results of pure-tone and speech audiometry are shown in Part A. The right and left ear are shown by circles and crosses respectively (filled circles and double crosses indicate the use of contralateral masking). Part B shows the duration of tone perception at each intensity level presented in tone decay testing pre- and postoperatively...90

Figure 29. Case 13: Electrophysiological auditory responses collected before and after vestibular schwannoma surgery. Part A shows a time-ordered sequence of click-evoked ABR traces from the left and right ears; with the latencies of waves present in these traces shown in part B. Part C shows the serial DPOAE data collected pre- and postoperatively; + indicates present DPOAEs and – indicates their absence.91

Figure 30. Case 13: Behavioural audiological data collected before and after vestibular schwannoma removal. Results of pure-tone and speech audiometry are shown in Part A. The right and left ear are shown by circles and crosses respectively (filled circles and double

crosses indicate the use of contralateral masking). Part B shows the duration of tone perception at each intensity level presented in tone decay testing.....92

Figure 31. Case 13: ABR recorded from the ipsilateral ear at important points during vestibular schwannoma surgery. The blue traces show the waveforms following smoothing using a 21-point running average, and grey traces show the raw data.93

Figure 32. Case 17: Electrophysiological auditory responses collected before and after vestibular schwannoma surgery. Part A shows a time-ordered sequence of click-evoked ABR traces from the left and right ears; with the latencies of waves present in these traces shown in part B. Part C shows the serial DPOAE data collected pre- and postoperatively; + indicates present DPOAEs and – indicates their absence.94

Figure 33. Case 17: Behavioural audiological data collected before and after vestibular schwannoma removal. Results of pure-tone and speech audiometry are shown in Part A. The right and left ear are shown by circles and crosses respectively (filled circles and double crosses indicate the use of contralateral masking). Part B shows the duration of tone perception at each intensity level presented in tone decay testing.....95

LIST OF TABLES

Table 1. Participant demographic characteristics and tumour size	43
Table 2. Summary of pre- and postoperative data for participants who suffered from postoperative anacusis following vestibular schwannoma removal	61
Table 3. Summary of pre- and postoperative data for patients with measurable behavioural audiological responses following vestibular schwannoma removal.	77

1. INTRODUCTION

The characteristics of the typical patient presenting with a vestibular schwannoma have changed as advances in diagnosis have enabled the detection of very small extracanalicular and intracanalicular tumours (Dornhoffer, Helms, & Hoehmann, 1995). As a result of diagnostic techniques such as magnetic resonance imaging (MRI) with gadolinium contrast, patients are presenting with smaller tumours and better preoperative hearing. Intraoperative facial nerve monitoring has also improved postoperative nerve function and is now considered a standard of care for vestibular schwannoma surgery (Glasscock, Hays, Minor, Haynes, & Carrasco, 1994). These changes have resulted in a shift towards attempting to preserve residual hearing where possible. However, the most common outcome for patients that undergo vestibular schwannoma excision with attempted hearing preservation is anacusis on the affected side (Gardner & Robertson, 1988; Kaylie, Gilbert, Horgan, Delashaw, & McMenemy, 2001; Lassaletta, Fontes, Melcon, Sarria, & Gavilan, 2003; Magnan et al., 2002; Moffat, da Cruz, Baguley, Beynon, & Hardy, 1999; Samii & Matthies, 1997). Postoperative anacusis following vestibular schwannoma excision may result from dissection of the cochlear nerve during surgery, or occur in the presence of anatomical preservation of the cochlear nerve (Colletti, Fiorino, Carner, & Tonoli, 1997). Anacusis in spite of preservation of the cochlear nerve is thought to result from direct mechanical damage to the cochlea or cochlear nerve, or to the vascular supply of either structure (Colletti et al., 1997).

In addition to reports of hearing preservation or immediate postoperative anacusis, there is a subset of cases reported in which hearing is demonstrated immediately postoperatively, but lost in the early postoperative period (Fahlbusch, Neu, & Strauss, 1998; Neu, Strauss, Romstock, Bischoff, & Fahlbusch, 1999; Palva, Troupp, & Jauhiainen, 1985; Strauss et al., 2001; Strauss et al., 1991). Surgeons at Christchurch Public Hospital have provided anecdotal reports of this phenomenon of apparent preservation of hearing immediately after vestibular schwannoma excision, followed by a rapid hearing deterioration in the early postoperative period (P. Bird, personal communication, December 19, 2007).

Intraoperative monitoring of electrophysiological responses has been used to identify patterns of responses correlated with delayed postoperative hearing loss (Neu, Strauss, Romstock, Bischoff, & Fahlbusch, 1999; Strauss et al., 2001; Strauss et al., 1991). Although this

intraoperative data offers some insights into the possible mechanisms of the pattern of hearing loss, *postoperative* electrophysiological and behavioural data documenting patterns of change in responses is rare. The absence of sufficiently detailed postoperative data limits the inferences that can be drawn from the extant literature regarding the likely pathophysiological mechanism of delayed hearing loss.

The present study aimed to closely monitor patterns of responses from the cochlear and cochlear nerve intraoperatively and during the early postoperative period following vestibular schwannoma excision. Behavioural tests of auditory function were also used to monitor changes in hearing postoperatively. All assessments were also performed preoperatively to provide baseline data from which to assess the degree of change in responses following surgery. Documenting patterns of changes in electrophysiological and behavioural responses postoperatively provided detailed information regarding the time course of damage, the possible site(s) of impairment and the pathophysiological mechanisms responsible for hearing loss following vestibular schwannoma removal. In particular, we aimed to use the data collected to determine whether the site of impairment leading to delayed hearing loss is cochlear or neural. The determination of the cause(s) of early postoperative delayed hearing loss offers the possibility of improving surgical techniques or postoperative therapies to improve the rates of postoperative hearing preservation.

1.1. The peripheral auditory pathway

The anatomy of the afferent and efferent auditory pathways is critical in interpreting the cause of auditory dysfunction in cases of vestibular schwannomas. Therefore, an overview of the anatomy and physiology of the peripheral auditory system is provided here.

1.1.1. Afferent auditory transmission

The first step in the afferent auditory pathway is the transmission of airborne vibrations through the external auditory canal to the tympanic membrane. Sound waves vibrate the tympanic membrane and pass through the middle ear, where they are converted from acoustic energy to mechanical energy. Movement of the stapes footplate at the oval window in the middle ear provokes a longitudinal wave in the cochlear fluids that causes a transverse

travelling wave on the basilar membrane (Von Bekesy, 1960). This wave propagates from the base to the apex of the cochlea, with the place of maximum displacement obtained at the base of the cochlea for high-frequency stimuli and at the apex for low-frequency stimuli. This tonotopic arrangement is the result of the structural characteristics of the cochlea, in particular the stiffness gradient along the basilar membrane (Von Bekesy, 1960). A schematic of the peripheral auditory system is shown in Figure 1.

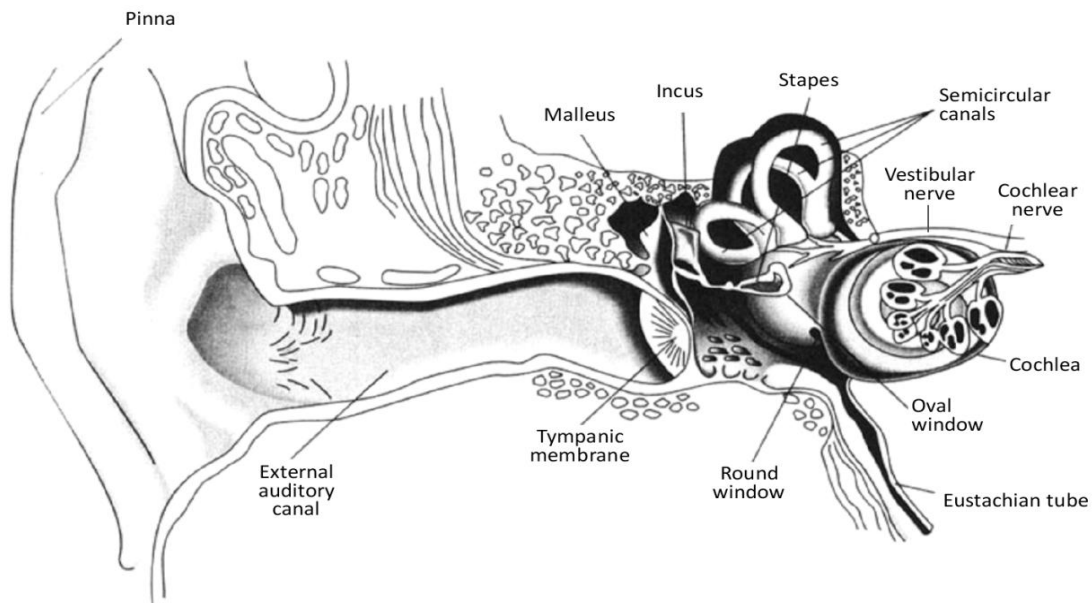


Figure 1. The peripheral auditory system. Sound waves travel through the external auditory canal and the middle ear to the cochlea. The cochlea performs mechano-electrical transduction to create a signal that is transmitted to the brain via the cochlear nerve (adapted from <http://www.virtualmedicalcentre.com/anatomy.asp?sid=29&title=Ear>).

Displacement of the basilar membrane causes a radial shearing of the outer hair cell (OHC) stereocilia, allowing an influx of potassium ions from the endolymph in the scala media into the hair cell (Pickles, 2008). Sound is an alternating stimulus that causes mechanically gated ion channels in the OHC stereocilia to open and close as the basilar membrane moves upward and downward. The alternating current (AC) of potassium ions into the cell results in an AC receptor potential which causes active contractions of the OHC, which acts to partially cancel the friction of the travelling wave, thereby improving hearing sensitivity and frequency selectivity for low intensity stimuli (Brownell, Bader, Bertrand, & de Ribaupierre, 1985; Dallos, 1992). The driving force for auditory transduction is the +95 mV endocochlear potential, which is generated by the stria vascularis, a highly vascular pumping epithelium in the lateral wall of the cochlea (Tasaki & Spyropoulos, 1959).

The inner hair cell (IHC) stereocilia do not touch the tectorial membrane and are believed to move due to fluid flow between the reticular lamina and the tectorial membrane caused by the movement of OHC cilia (Hu, Evans, & Dallos, 1999). Shearing of the IHC stereocilia results in a depolarisation of the IHC which triggers the release of glutamate and initiates an action potential in the primary afferent cochlear nerve fibres that innervate the IHCs (Pickles, 2008).

The afferent innervation of the cochlear consists of two distinct types of nerve fibres (Spoendlin & Schrott, 1989). Type I fibres are thick and myelinated fibres that constitute 90 to 95% of all the afferent cochlear nerve fibres. These fibres innervate primarily the IHCs, with each IHC receiving innervation 20 to 30 type I fibres (Liberman, Dodds, & Pierce, 1990) The remaining 5 to 10% of cochlear nerve fibres, termed type II fibres, are unmyelinated and therefore thinner in diameter than the type I fibres (Hurd, Hutson, & Morest, 1999). Type II fibres connect with the OHCs, with each nerve fibre typically connecting with multiple OHCs (Simmons & Liberman, 1988).

1.1.2. Efferent auditory transmission

In addition to the afferent innervation, the cochlea receives an efferent input from the olivocochlear bundle. In comparison to the afferent auditory system, the anatomy of the efferent system has not been well defined and some ambiguity still surrounds its function. The efferent auditory pathway begins at the primary auditory cortex and association areas and follows a similar course as the afferent auditory pathway, (but in an opposite direction) through the medial geniculate body (Rasmussen, 1946, 1960). Upon leaving the brainstem, the efferent fibres proceed laterally around the vestibular nerve root and course with the vestibular fibres through the IAC to enter the cochlea via the habenula perforata (Liberman & Brown, 1986). The key component of the efferent system is the olivocochlear bundle (OCB); a complex of descending fibres that originates in the superior olivary complex (SOC) (Hashikawa & Kawamura, 1983). The OCB consists of two anatomical subsystems:

The lateral olivocochlear system (LOC):

The LOC fibres are thin, unmyelinated fibres arising from the lateral superior olive complex and its surrounding area. These fibres travel from the SOC, through the IAC to

enter the cochlea between its first and second turns and terminate on the dendrites of the type I nerve fibres beneath the IHCs, and to a much lesser extent, the IHCs themselves (Warr, 1980; Warr & Guinan, 1979). In humans, the LOC pathway to the cochlea is predominantly ipsilateral (Warr, 1980).

The medial olivocochlear system (MOC):

The MOC system consists primarily of myelinated fibres that are larger in diameter than the lateral efferent fibres (Warr & Guinan, 1979). The medial efferent pathway originates in medial, ventral, or peripheral olivary zones (Rasmussen, 1946; Warr, 1980) and is predominantly a crossed system, with approximately 60%-70% of the neurons crossing the brainstem to innervate the contralateral ear (Guinan, Warr, & Norris, 1983; Warr, 1980, 1992). The crossed MOC fibres combine with the fibres in the LOC bundle and course to the contralateral cochlea. Once in the cochlea, the majority of the medial efferents synapse directly to the lower part of the OHCs (Kimura & Wersall, 1962).

Although originally considered as principally an inhibitory system, recent evidence suggests that the efferent system is also involved in excitatory processes (e.g. Groff & Liberman, 2003; Le Prell, Halsey, Hughes, Dolan, & Bledsoe, 2005; Le Prell, Shore, Hughes, & Bledsoe, 2003). The extant evidence therefore indicates that the efferent auditory system plays a role in modulating excitatory and inhibitory interactions within the auditory system (Musiek & Baran, 2007).

Medial efferent activation via electrical stimulation inhibits auditory nerve action potentials evoked by brief sounds in a quiet background (Desmedt, 1962; Galambos, 1956). However, introducing masking noise to the contralateral ear activates the MOC pathway and has an excitatory effect on the auditory nerve (Dolan & Nuttall, 1988; Fex, 1962, 1963; Folsom & Owsley, 1987; Kawase & Liberman, 1993). The inhibitory effects of the medial efferent system result from a frequency-dependent reduction of the amplitude of mechanical vibration of the basilar membrane (Dolan, Guo, & Nuttall, 1997). Contralateral stimulation of the MOC pathways evokes changes in cochlear potentials by increasing the conductance of outer hair cells and changing current flows within the cochlea (Fex, 1967). The suppressive effects of the efferent system on the cochlea and auditory nerve may function to help decrease neural activity to protect the cochlea from damage by intense noise (Darrow, Maison, & Liberman, 2007; Kujawa & Liberman, 1997; Maison & Liberman, 2000; Reiter & Liberman, 1995).

Selective disruption of the LOC system is difficult to achieve, therefore it has been more challenging to isolate the effects of the LOC system (Kujawa & Liberman, 1997; Liberman, 1991). Recent evidence suggests that the LOC pathway comprises two functional subdivisions, capable of eliciting slow excitation or suppression of auditory nerve responses (Groff & Liberman, 2003). Several studies have indicated that the dominant result of destruction of the LOC pathway is a decrease in the amplitude of the auditory nerve compound action potential, indicating that the primary effect of LOC activation is excitatory (Le Prell et al., 2005; Le Prell et al., 2003). However, Darrow and colleagues recently found the opposite effect of selective LOC disruption in mice (Darrow et al., 2007).

1.2. The internal auditory canal and the vestibulocochlear nerve

The ganglion cells of the cochlear nerve leave the cochlea through the habenula perforata, converge in Rosenthal's canal, and are gathered in a twisted bundle to form the trunk of the modiolus (Pickles, 2008). These bundled axons of the type I and type II afferent neurons form the cochlear branch of the eighth cranial nerve, known as the vestibulocochlear nerve. The cochlear nerve is partially myelinated, proximal to the habenula perforata (Spendlin & Schrott, 1989). Like the cochlea, the cochlear nerve is organised tonotopically; high-frequency fibres are located on the outside of the nerve trunk and low frequency fibres are in the core (Sando, 1965). The tonotopic arrangement of the cochlea and cochlear nerve is preserved throughout the auditory system (Romani, Williamson, & Kaufman, 1982). Functionally, the cochlear nerve relays information about the intensity, frequency, and timing of a sound to the brain (Ruggero, 1992).

These cochlear and vestibular nerves exit the inner ear together through the internal auditory canal (IAC), located on the posterior surface of the petrous part of the temporal bone. The vestibular nerve, the second branch of the cochleovestibular nerve, consists of two branches; the inferior and superior vestibular nerves, and transmits balance information from the vestibular end organs of the inner ear to the brain (Baloh & Honrubia, 1990). The IAC also houses the seventh cranial (facial) nerve and the internal auditory artery (IAA), which supplies blood to the vestibulocochlear nerve and the cochlea. Four individual nerves exist only in the most lateral portion of the canal. The inferior and superior vestibular nerves combine into a single nerve approximately 1 to 2 mm from the falciform crest at the lateral

end of the IAC (Rubinstein, Sandberg, & Cajade-Law, 1996). The vestibular nerve and cochlear nerve fuse to form the vestibulocochlear nerve approximately 3 to 4 mm from the lateral end of the IAC (De Ridder et al., 2004; Spöndlin & Schrott, 1989). The efferent auditory fibres also constitute part of the vestibulocochlear nerve.

The vestibulocochlear nerve in the human adult ranges in length from approximately 22 to 26 mm (Møller, 2000). Jerger (1960) suggests that the vestibulocochlear nerve can be viewed as an auditory bottleneck because all auditory information being transmitted from the cochlea to the brain must travel through the vestibulocochlear nerve fibres. In the cochlea and beyond the vestibulocochlear nerve, activity is spread throughout the structure. Jerger (1960) suggests that this is why what appears to be slight damage to or compromise of the structure of the vestibulocochlear nerve may result in major auditory dysfunction in some patients.

Within the IAC, the cochlear nerve is located beneath the facial nerve and adjacent to the vestibular nerves, as shown in Figure 2. The nerves within the IAC rotate ninety degrees clockwise as they approach the brainstem, therefore the spatial relationship between nerves changes as they course through the IAC. Most medially, the cochlear portion is located caudally with respect to the vestibular portion, and in the most lateral portion of the IAC the cochlear portion of the vestibulocochlear nerve is located anteriorly to the inferior vestibular nerve (Silverstein, Norrell, Haberkamp, & McDaniel, 1986).

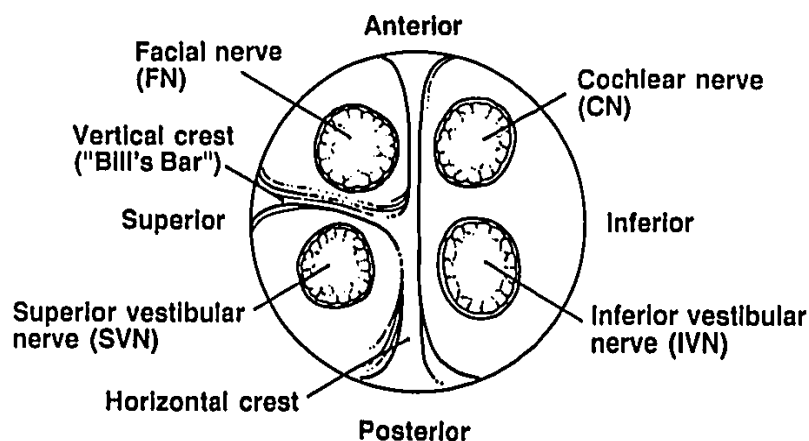


Figure 2. The normal anatomic relationship of the right internal auditory canal (from Wilson, Hodgson, Gustafson, Hogue, & Mills, 1992).

As they leave the IAC, the vestibulocochlear and facial nerves course through an anatomic space between the cerebellum and the pons, known as the cerebellopontine angle (CPA), to

enter the brainstem at the level of the cochlear nucleus on the latero-posterior aspect of the caudal pons (Pickles, 2008). At this point, neural impulses from the peripheral nervous system are conveyed to the central nervous system.

1.3. The vascular supply to the cochlea and vestibulocochlear nerve

The vascular supply to the cochlea and vestibulocochlear nerve is a complex system that contributes to metabolism and fluid homeostasis in these structures (Axelsson & Ryan, 2001). The IAA constitutes the vascular supply for eighth cranial nerve, the cochlea, the vestibular system, and the facial nerve (Portmann, Sterkers, Charachon, & Chouard, 1975). As shown in Figure 3, the IAA branches either directly from the basilar artery or, more commonly, arises from the anterior inferior cerebellar artery (AICA), a branch of the basilar artery (Waddington, 1974). From the point of branching, the IAA proceeds into the inferior (caudal) half of the pons then courses laterally across the CPA and into the IAC (Axelsson & Ryan, 2001; Sugita, Masutani, Moriguchi, Matsunaga, & Nakai, 1991; Waddington, 1974).

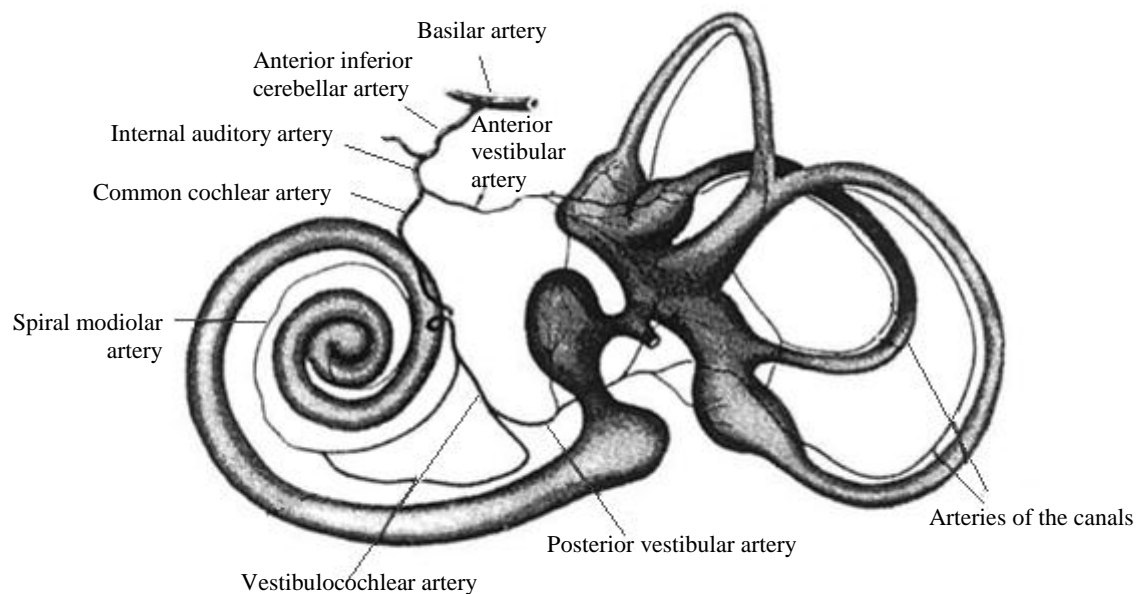


Figure 3. Schematic drawing of the vascular supply to the labyrinth (from Baloh & Honrubia, 2001).

Within the IAC, the IAA branches into the vestibular artery and into the common cochlear artery near the site where the cochlear nerve penetrates into the modiolus (Axelsson & Ryan, 2001; Portmann et al., 1975). The common cochlear artery then gives rise to the spiral modiolar artery, which ascends spirally around the modiolus to primarily supply the apical

portion of the cochlea, and to the vestibulocochlear artery, which supplies the lower basal turn of the cochlea. The spiral modiolar and vestibulocochlear arteries progressively branch to form a network of arterioles that supply most of the cochlea. The main radiating arterioles emerge from the area of Rosenthal's canal, to supply the limbus, tectorial membrane, and organ of Corti. There is also a particularly extensive vascular network supplying the stria vascularis (Axelsson & Ryan, 2001). The amount of vascularisation is greater in the base than the apex of the cochlea, consistent with greater physiological activity of the cochlea at its base (Axelsson & Ryan, 2001).

A detailed study of the vascular anatomy of the peripheral auditory system by Matsunaga, Kanzaki, and Hosoda (1996) confirmed the findings of Fisch, Dobozi, and Greig (1972) that the IAA and its main branches are typically found on the surface of the eighth cranial nerve within the IAC. In addition, Matsunaga and colleagues found that the main branch of the IAA was frequently found within the endoneurium of the cochlear nerve. The vestibulocochlear nerve has a dual vascular system consisting of extrinsic vessels and intrinsic microvessels, which are connected by anastomosing vessels (Axelsson & Ryan, 2001; Matsunaga et al., 1996). The extrinsic vascular system consists of many arterioles and venules that run longitudinally along the outside of the sheath of vestibulocochlear nerve. The intrinsic microvascular system is contained within the endoneurium, and consists of many capillaries and postcapillary venules arranged in a longitudinal direction. The microvascular supply to the peripheral portion of the vestibulocochlear nerve consists of sparse and large microvessels, with many anastomoses, which represents an effective system for maintaining the ionic and osmotic balance of the endoneurial fluid (Matsunaga et al., 1996). In contrast to the peripheral portion, the microvasculature of the central portion of the cochlear nerve is sparse and irregularly distributed (Matsunaga et al., 1996).

A disruption or alteration to the vascular supply of the peripheral auditory system is likely to damage and compromise the function of the tissue dependent on this blood supply (Reisser & Schuknecht, 1991). Vascular abnormalities, such as vessel occlusion, vasospasm, and haemorrhage can cause irreversible damage to the vestibulocochlear nerve and the cochlea (Baloh, 1995; Goodhill, 1979). Occlusion of the IAA or one of its main branches initially results in necrosis and eventually leads to ossification of the membranous tissue in the inner ear (Baloh, 1995). Temporary ischemia, caused by a disruption to the vascular supply to the cochlea or cochlear nerve, depending on its severity and duration, may cause permanent

damage to the nerve, or the inner ear structures (Perlman, Kimura, & Fernandez, 1959). In particular, reduced blood supply to the stria vascularis may result in compromise of the metabolic function of the organ of Corti (Martini & Prosser, 2003). The increased demand for blood supply at the basal end of the cochlea may make it more susceptible to damage following reduced blood flow than other portions of the cochlea (Axelsson & Ryan, 2001; Morawski et al., 2004).

1.4. Vestibular schwannomas

Vestibular schwannomas are histologically benign tumours originating from the vestibular portion of the eighth cranial nerve. These tumours arise from the Schwann cells in the myelin sheath of the nerve (Sterkers & Bowdler, 1987). The incidence of vestibular schwannomas in the general population is approximately 0.9/100 000 annually (Tos, Charabi, & Thomsen, 1999) and they account for approximately 80% of tumours of the CPA (Brunori, Scarano, & Chiappetta, 1997; Grey, Moffat, & Hardy, 1996). Clinical symptoms typically present between the ages of 40 and 60 years, and rarely appear in individuals before puberty (Schuknecht, 1993).

The majority of vestibular schwannomas (95%) are unilateral (Moffat, Baguley, Von Blumenthal, Irving, & Hardy, 1994; Nestor, Korol, Nutik, & Smith, 1988). The exception is neurofibromatosis type II, which is an extremely rare condition of the nervous system resulting from a mutation in the NF2 gene on chromosome 22. The mutation in this gene typically results in unfettered cell proliferation, leading to multiple tumours, including bilateral vestibular schwannomas (Callan, Lasky, & Fowler, 1999; Da Cruz, Hardy, & Moffat, 2000; Nager, 1985).

In most cases, the tumour grows within the IAC and gradually advances into the CPA as it enlarges (Perre, Viala, & Foncin, 1990). Therefore, the tumour consists of two portions: the intracanalicular portion, and an extracanalicular portion in the CPA, as depicted in Figure 4 (Nager, 1985). Rarely, tumours are confined to the CPA, with no intracanalicular portion (Nager, 1985). As the vestibular schwannoma grows within the IAC it directly compresses the vestibulocochlear nerve, presumably causing degenerative changes to the nerve, and resulting in balance disturbance, and sensorineural hearing loss and tinnitus on the affected side (Perre et al., 1990; Selesnick, Jackler, & Pitts, 1993). By disrupting the IAA, a vestibular

schwannoma can also directly impair the cochlea. The tumour may press against the facial nerve causing facial numbness or weakness (Avezaat & Pauw, 1998). As the tumour grows larger it extends towards the brainstem and protrudes from the internal auditory canal into the CPA (see Figure 4).

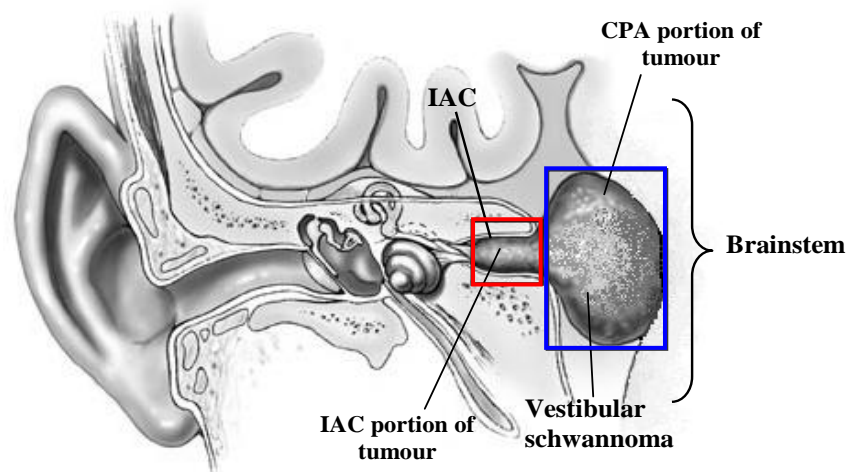


Figure 4. A schematic depiction of a vestibular schwannoma growing within the IAC and expanding out into the CPA. In this case the brainstem is compressed by the tumour. The intracanalicular (IAC) portion of the tumour is outlined in red, and the extracanalicular or CPA portion of the tumour is indicated by the blue box (adapted from <http://www.neurosurgery.ufl.edu/Patients/acoustic.shtml>).

If the tumour continues to enlarge it will eventually grow into the pontomedullary junction of the brainstem, compressing the brainstem and cerebellum producing serious morbidity or, rarely, death (Kentala & Pyykko, 2001). Compression of the fourth ventricle may produce an increase in intracranial pressure and lead to an internal hydrocephalus (Nager, 1985). Due to their close proximity, a tumour growing within the CPA can also affect adjacent cranial nerves including cranial nerve V (trigeminal), IX (glossopharyngeal), X (vagus), and XI (spinal accessory) (Avezaat & Pauw, 1998). Vestibular schwannomas are typically slow growing lesions, with mean growth rates reported as 0.7 ± 1.4 mm per year (Battaglia, Mastrodimos, & Cueva, 2006). In a meta-analysis of published studies reporting the growth rate of untreated vestibular schwannomas, Battaglia and colleagues (2006) found that 82% of tumours grew less than 1 mm per year, whereas 18% grew 1 mm or more per year.

MRI is now used as the standard diagnostic test for vestibular schwannomas (Stangerup et al., 2004). Typically, patients are referred for MRI based on the presence of clinical symptoms. As schwannomas are benign tumours that respond poorly to classical chemotherapeutic

regimes, tumour excision with microsurgery, stereotactic radiation, or conservative management with serial monitoring with MRI and audiometry are the current treatment options (Bird & MacFarlane, 2007). The morbidity and mortality associated with surgical tumour removal has diminished significantly with improvements in surgical techniques, postoperative care and intraoperative monitoring. Therefore, surgical excision is often the first choice for the management of vestibular schwannomas when symptoms are significant enough to reduce the advantages of watchful waiting (Battaglia et al., 2006).

1.5. Electrophysiological techniques

In the present study, the primary methods used to objectively assess the functional status of the auditory system following vestibular schwannoma surgery were electrophysiological in nature; therefore a discussion of these techniques is warranted here. It is important to note that no electrophysiological technique can replace pure-tone audiometry as a measure of hearing sensitivity. Pure-tone audiometry is dependent on the status of the middle ear, cochlea, eighth cranial nerve, central auditory system, and auditory processing abilities (Vinck, Van Cauwenberge, Leroy, & Corthals, 1999). Thus, pure-tone audiometry offers a more comprehensive evaluation of hearing sensitivity than electrophysiological responses that do not reflect all of these elements collectively. It has been demonstrated that the absence or gross abnormality of electrophysiological responses, can occur in the presence of normal pure-tone thresholds (Legatt, Arezzo, & Vaughan, 1988). However, normal pure-tone thresholds do not guarantee normal hearing either, as demonstrated in cases of auditory neuropathy (Starr, Sininger, & Pratt, 2000). For this reason, speech discrimination testing to determine whether complex signals are processed to the point that they can be understood, is a necessary adjunct to measuring pure-tone thresholds. Electrophysiological methods of assessing auditory function must therefore be used in conjunction with behavioural tests to accurately assess a patient's hearing ability.

1.5.1. Auditory Brainstem Response

The Auditory Brainstem Response (ABR) is currently the most commonly used technique to monitor auditory function during vestibular schwannoma surgery. The ABR is a non-invasive

and objective method of assessing the functional integrity of the cochlea and ascending auditory brainstem pathways (Beattie, Garcia, & Johnson, 1996).

ABR is composed of seven voltage deflections occurring within 10 ms of an abrupt stimulus onset (Jewett, Romano, & Williston, 1970). These deflections are far-field representations of synchronous activity generated by the auditory nerve and subsequent fibre tracts and nuclei within the auditory brainstem pathways, in response to the onset of an acoustic stimulus (Hall, 2006). The most popular system of nomenclature is to label the positive voltage peaks with Roman numerals: waves I to VII (Jewett et al., 1970). Wave I arises from the distal portion of the auditory nerve in the cochlea, and wave II from the proximal portion of the auditory nerve as it enters the brainstem. Waves III to V are believed to be the complex sum of the activity of several nuclei in the auditory brainstem (Hall, 2006). Of the seven peaks, waves I, III, and V are sufficiently robust to be used clinically (Junius & Dau, 2005), as shown in Figure 5.

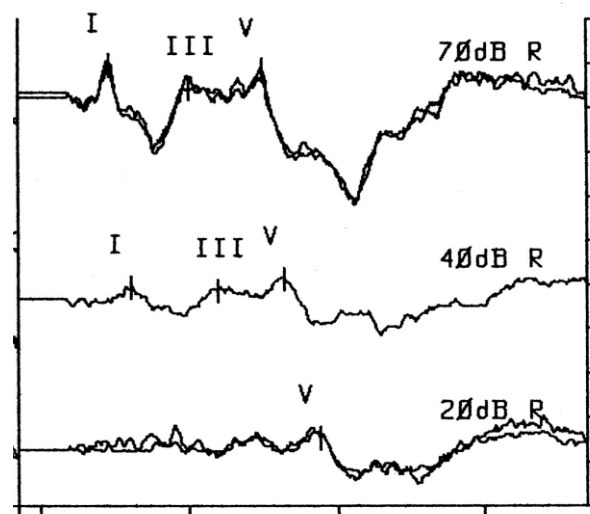


Figure 5. The Auditory Brainstem Response (ABR) to click stimuli at increasing intensities in a normal hearing subject (from Gorga et al., 2006).

Broadband acoustic stimuli, such as clicks, are commonly used to evoke ABR (Hall, 2006). There is also strong evidence that the ‘chirp’ may become the stimulus of preference, due to its ability to generate larger amplitude responses by producing a synchronous response from a larger portion of the basilar membrane than the click (Dau, Wegner, Mellert, & Kollmeier, 2000; Fobel & Dau, 2004). However, many commercially available evoked auditory response

measurement systems are not yet equipped with the chirp stimulus. Click stimuli have a rapid onset and broadband spectrum, therefore elicit a response from a large number of neurons almost synchronously and are likely to produce a robust response when measured from the scalp (Don & Kwong, 2002). Although the pure-tone audiometric threshold that the click-evoked ABR threshold best correlates with is not certain, the majority of research agrees that the region most closely associated with ABR evoked by a moderately intense click is 2 kHz and above (Gorga, Kaminski, Beauchaine, & Jesteadt, 1988; Kulecki, Terlemez, Ciprut, & Akdus, 2007; Picton, Durieux-Smith, & Moran, 1994). More apical regions of the cochlea are activated by the click stimulus, but these regions do not usually contribute to the ABR due to the phase cancellation of activity generated from more apical regions of the cochlea by earlier activity from the more basal, high-frequency regions (Don & Kwong, 2002).

The primary measurement parameters of ABR are the latency and amplitude of its peaks (Hall, 2006). Latency refers to the time interval between the stimulus onset and a particular peak of the waveform. Peak latencies are determined by a number of mechanical and physiologic processes, including the delay in the cochlea to the site of activation; the synaptic delay between the inner hair cells and the auditory nerve; and the neural conduction time and any intervening synaptic delays to the point in the brainstem pathway responsible for the peak activity (Don & Kwong, 2002). In addition, factors including the transducer type, stimulus intensity, and gender can affect the absolute latency of ABR waves in young, normal hearing adults. In normal hearing young female subjects tested using click ABR at 70 dB SL, the latency of wave I should occur approximately 1.6 ms after stimulus onset, wave III at about 3.7 ms and wave V at approximately 5.6 ms (Hall, 2006). The absolute wave latencies for males are approximately 0.3 ms longer than those recorded from female subjects (Hall, 2006). Due to the effects of the aforementioned factors that can influence wave latencies, absolute latencies should be used with caution in inter-patient comparisons and interaural comparisons of both absolute latencies and interpeak intervals are considered more robust measures of retrocochlear status (Hall, 2006). An interaural latency difference or interaural interpeak interval difference (between waves I-III, III-V, or I-V) of 0.2 ms or greater is indicative of retrocochlear pathology (Selters & Brackmann, 1977).

The amplitude of an ABR waveform is defined as the voltage difference between a peak and its subsequent trough. The amplitude of a given waveform reflects the amount of synchronous neural activity contributing to the response, and therefore is determined by the

amplitude of responses from individual neurons, the number of neurons responding to the stimulus, and the degree of synchronisation of the responding neurons (Don & Kwong, 2002; Don, Ponton, Eggermont, & Masuda, 1994). ABR amplitude rarely exceeds 1.0 μV , therefore interference or artefact may seriously interfere with, or preclude, accurate identification of ABR components (Don & Kwong, 2002). In particular, ABR can be negatively affected by the presence of large amplitude, low-frequency artefact, usually related to patient movement, or small amplitude, high-frequency electrical or myogenic artefact. Conventional signal averaging is used to extract and enhance auditory evoked responses embedded within background noise (Hall, 2006). Amplitude can be an unreliable diagnostic measure, as it is highly influenced by between-subjects factors such as electrode placement, EEG activity level, and muscle artefact (Don & Kwong, 2002). Within-subject amplitude measures may also be affected by variation in levels of background noise and electrical interference (Don & Elberling, 1994).

1.5.2. Electrocochleography

Electrocochleography (ECoChG) is a method of recording the auditory evoked potentials of the cochlea and auditory nerve (Ferraro, Best, & Arenberg, 1983). ECoChG provides information on a more peripheral part of the auditory pathway than ABR, and is used to record synchronous neural activity generated in response to sound stimuli by the cochlea and the distal portion of the cochlear nerve (Hall, 2006). ECoChG is particularly useful in evaluating cochlear and cochlear nerve function because it is comprised of three distinct potentials, as shown in Figure 6: the cochlear microphonic (CM), the summing potential (SP), and the compound action potential (CAP) (Ferraro et al., 1983; Hall, 2006; Lenarz & Ernst, 1992). The CM reflects OHC function, whereas the CAP reflects activity of the distal portion of the cochlear nerve, therefore analysis of the ECoChG makes it possible to distinguish between cochlear and neural sites of impairment. The neural response that is measured in ECoChG occurs within the first two to three milliseconds following the presentation of an abrupt auditory stimulus, whereas the hair cell components last for the duration of stimulus presentation (Hall, 2006). The ECoChG action potential reflects the neuronal activity of only the most distal part of the cochlear nerve therefore is poorly sensitive to disturbances to the proximal part of the cochlear nerve.

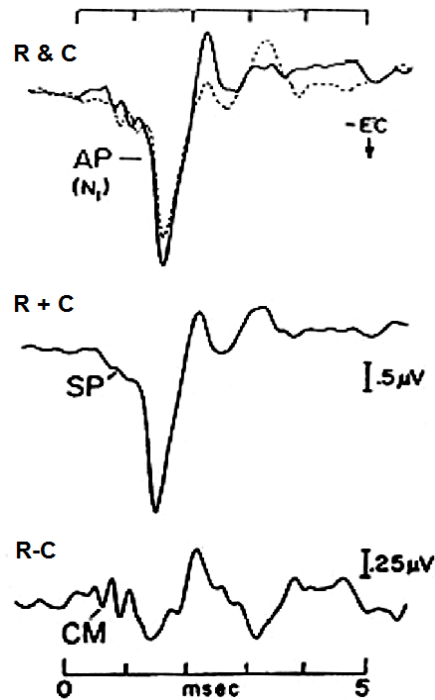


Figure 6. The human electrocochleogram evoked by click stimuli. The top trace displays responses to rarefaction (R) and condensation (C) polarity clicks. The middle trace shows the addition of R and C responses, which enhances the Summating Potential (SP) and Action Potential (AP). Subtracting R and C responses (bottom trace), enhances the Cochlear Microphonic (CM) (from ASHA, 1988, based on data from Coats, 1981).

The cochlear microphonic (CM) is an alternating current (AC) electrical potential that reflects the instantaneous displacement of the OHC stereocilia (Patuzzi, Yates, & Johnstone, 1989). The CM represents the summation of the responses from a large number of OHCs from across the basilar membrane, with a small contribution from the IHCs (Chertoff, Amani-Taleshi, Yuqing, & Burkard, 2002). The frequency response of the CM mimics that of the stimulus, and the amplitude increases linearly with stimulus intensity up to moderate levels, then saturates in response to higher intensity stimuli (Dallos, 1973).

The summating potential (SP) is a sustained direct current (DC) response that reflects the asymmetry of the IHC receptor potential (Tasaki, Polley, & Orrego, 1954). Like the CM, the SP reflects the stimulus waveform, however in the case of the SP a rectified, DC version of this pattern more representative of the stimulus envelope is displayed (Dallos, Schoeny, & Cheatham, 1972). The polarity of the SP is determined by an interactive effect between stimulus parameters and the location of the recording

electrode (Dallos et al., 1972; Durrant, Wang, Ding, & Salvi, 1998; Tasaki et al., 1954; Whitfield & Ross, 1965).

The compound action potential (CAP) represents the summed response of the synchronous firing of afferent auditory nerve fibres in the distal part of the cochlear nerve. The CAP is the first neural response and is made up of three components, N1, P1, and N2. N1 represents the major component of the CAP at suprathreshold stimulus intensities and is indicative of the functional status of the distal cochlear nerve, but not of the central part of the nerve where it enters the brainstem (Lambert & Ruth, 1988). Recent studies have provided evidence suggesting that the cochlear CAP is a stationary potential generated across the *dura mater* (Brown & Patuzzi, 2008).

The most effective method of obtaining and measuring the stimulus-related potentials of the cochlea and vestibulocochlear nerve is to position the recording electrodes as close as possible to the generators of the response. When recording the ECoChG response, the recording electrode is located i) on the round window, ii) on the promontory wall of the middle ear or iii) in the external ear canal. The most frequently used invasive ECoChG electrode is the transtympanic needle, which is generally placed on the promontory wall of the middle ear, near the round window niche (Ruth, Lambert, & Ferraro, 1988). This technique produces ECoChG recordings that are generally very robust and stable, due primarily to the magnitude of the AP, which when recorded with the transtympanic electrode is approximately 20 to 40 μV at higher stimulus intensities and can typically be observed down to stimulus levels approximating hearing threshold (Ruth et al., 1988).

Measures of component amplitude and latency are used to interpret the ECoChG. Component magnitudes are the most commonly analysed parameter, and can be measured from a single point or a baseline reference. Controversy exists regarding which is the best technique for determining component amplitude. The single point method is often preferred for its simplicity (Ferraro & Durrant, 2002). In this method, the SP and CAP measurements are made from their leading edge, from peak to trough. However, the single point method may be subject to bias from noise peaks, whereas the baseline reference method avoids this limitation (Ferraro & Durrant, 2002). The CM is often large and difficult to separate from stimulus artefact, therefore it may obscure or interfere with the recording and measurement of the SP and CAP. Because the CM follows the polarity of a click stimulus, summing or averaging the

CM response to stimuli of alternating polarity can be used to cancel out the CM and eliminate the interference of CM in recording the SP and CAP (Yoshie, 1971).

N_1 , the first and largest of the CAP peaks, is the same response as wave I of the ABR (Møller & Jannetta, 1983). As with ABR, the CAP shows reductions in amplitude and latency prolongation in response to reductions in stimulus intensity at suprathreshold levels (Hall, 2006). ECochG is typically recorded with the electrode placed close to the tympanic membrane or the round window of the cochlea, therefore the amplitude of the CAP is significantly larger compared to Wave I of the ABR recorded from earlobe or mastoid electrodes (Bauch & Olsen, 1990; Ferraro & Ferguson, 1989). The enhancement of ABR wave I allows visual detection of the response at lower intensities and, in cases of cochlear dysfunction, may allow identification of a wave I that is absent from the ABR (Lenarz & Ernst, 1992; Schlake et al., 2001).

1.5.3. Otoacoustic emissions

Otoacoustic emissions (OAEs) are acoustic signals generated in the cochlea and recorded in the ear canal. OAEs are believed to reflect the electromotile activity of the OHCs, therefore their measurement constitutes an objective non-invasive technique for assessing the functional status of the cochlea, and in particular, the OHCs (Brownell, 1990; Kemp, 1978). OAEs will not be affected by damage restricted to the afferent neurons of the cochlear nerve, but may be affected by disturbances to the efferent neurons, which modulate cochlear processes, including OHC motility (Guinan, 2006).

There are several techniques in current clinical use to elicit and record OAEs. Distortion product otoacoustic emissions (DPOAEs) are low-intensity sounds emitted by the cochlea in response to the simultaneous presentation of two sinusoidal primary tones of different frequencies; f_1 and f_2 . DPOAEs occur because the normally functioning cochlea is a nonlinear system, with a byproduct of this being distortion. To record DPOAEs, the primary tone levels, level difference, and frequency ratio are held constant while the primaries are changed in frequency. Sound in the ear canal in response to the presentation of the primary tones is recorded, and a spectral analysis of the recording is performed. DPOAEs evoked by f_1 and f_2 occur at predictable frequencies that are mathematically related to the frequencies of the primaries (Moulin, Bera, & Collet, 1994). The largest amplitude response occurs at $2f_1-f_2$, and

the presence of acoustic activity at this frequency is considered to reflect OHC function at the frequency equal to the geometric mean of the primary tone frequencies (Moulin et al., 1994). The most common method of analysis in clinical practice is to plot DPOAE level as a function of f_2 frequency, to provide an estimation of OHC function at that frequency. DPOAEs have been shown to perform better at predicting the lower and upper frequency boundaries of the interval with hearing loss, compared with another method of recording OAEs; transient evoked otoacoustic emissions (TEOAEs) (Avan & Bonfils, 2005).

The parameter used for clinical detection of hearing loss is DPOAE signal to noise ratio (SNR), as it is considered more correlative with hearing loss than DPOAE amplitude at most frequencies (Gorga et al., 1997). In people with normal hearing, DPOAEs typically have a SNR of greater than 5 dB (Hall, 2000), however OAEs are generally not present, or are significantly reduced, when the level of sensorineural hearing loss exceeds 40 to 50 dB HL (Gorga et al., 1997; Harris, 1990). The reliability, specificity, and sensitivity of OAEs have been found to be high, with Gorga, Neely, & Dorn (1999) finding sensitivity approached 100% for participants with sensorineural hearing loss greater than 40 dB HL at the frequency being measured. It is, however, important to note that although OAEs can reliably distinguish ears with normal hearing from ears with various degrees of hearing loss, they are not yet able to provide an accurate measure of hearing level or the degree of hearing loss in an individual ear (Gorga, Neely, Dorn, & Hoover, 2003).

OHCs, and therefore OAEs, are highly vulnerable to hypoxia and ischemia (Mom, Telischi, Martin, & Lonsbury-Martin, 1999; Rebillard & Lavigne-Rebillard, 1992; Schmiedt & Adams, 1981; Widick, Telischi, Lonsbury-Martin, & Stagner, 1994). By inducing a temporary blockage to the IAA of rabbits, Widick and colleagues found that DPOAE amplitudes were highly sensitive to even temporary interruptions of cochlear blood flow (Widick et al., 1994), therefore transitory changes in DPOAEs may act as early warning signs for vascular compromise of cochlear function. Phase changes to DPOAEs may provide more real-time information on cochlear function, with evidence showing phase changes to DPOAEs within 1-5 seconds of IAA compression in rabbits (Telischi, Stagner, Widick, Balkany, & Lonsbury-Martin, 1998).

DPOAEs may provide valuable information postoperatively on the cause of hearing loss in the presence of an intact cochlear nerve. It is hypothesised that in some patients cochlear circulation becomes compromised during surgery, thus measuring DPOAEs in patients

postoperatively may provide useful information about the contribution of cochlear versus neural sources to the hearing impairment (Telischi, Roth, Stagner, Lonsbury-Martin, & Balkany, 1995). At present, a detailed analysis of postoperative DPOAE levels following vestibular schwannoma excision has not been published.

1.6. Preoperative hearing

A progressive, either unilateral or asymmetric sensorineural hearing loss is found in up to 94% of individuals with vestibular schwannomas; however, the majority of these individuals have some degree of measurable hearing (Harner, Fabry, & Beatty, 2000; Jackler, 2000; Kentala & Pykko, 2001; Selesnick et al., 1993). Approximately 10% of patients report a sudden hearing loss on the tumour side (Hashimoto, Toshima, & Sakurada, 1991; Pensak, Glasscock, Josey, & Jackson, 1985). High-frequency sensorineural hearing loss in the affected ear is the most common presenting audiometric configuration in vestibular schwannoma patients (Harner et al., 2000). This may be because most tumours approach the outside of the cochlear nerve first, therefore, due to the tonotopic arrangement of the nerve, the high-frequency fibres are initially compromised. In addition, the basal portion of the cochlea, and thus hearing at high frequencies, has also been demonstrated to be more vulnerable than more apical regions to disruptions of the vascular supply to the cochlea (Kimura & Perlman, 1958). Controversy currently exists regarding what constitutes serviceable hearing, however it is most commonly defined by the '50/50 rule' as a pure tone average (PTA) at 0.5, 1 and 2 kHz of less than or equal to 50 dB HL with a speech discrimination score of 50% or more (Brackmann, Owens, & Fayad, 2001; Gardner & Robertson, 1988). This definition is in agreement with the American Academy of Otolaryngology – Head and Neck Surgery (AAO-HNS) recommendations for classification of hearing following vestibular schwannoma surgery (AAO-HNS, 1995). These guidelines classify hearing as A, B, C or D, based on PTA and maximum speech discrimination scores. Classes A and B correspond to a PTA of no greater than 50 dB HL at 0.5, 1, 2 and 3 kHz, and a speech discrimination score of at least 50% (AAO-HNS, 1995).

The ABR is abnormal in approximately 90% of patients with lesions of the eighth cranial nerve (Selters & Brackmann, 1977). Vestibular schwannomas typically cause prolonged

absolute latency values of all waves beyond wave I. This latency shift results in abnormally long I-V and I-III inter-wave intervals (see Figure 7). However, in subjects with a cochlear component to their hearing loss, wave I of the ABR may be reduced, distorted or absent regardless of the presence or absence of an identifiable wave V (Cashman & Rossman, 1983; Hyde & Blair, 1981). In addition, abnormally small peak amplitudes or absent waveforms are often seen in patients with vestibular schwannomas. These findings have been attributed to the tumour exerting pressure on the cochlear nerve at some point along its length leading to delays in neural conduction time and/or disrupting neural synchrony by slowing or blocking the conduction of action potentials along the axon (Badie, Pyle, Nguyen, & Hadar, 2001; Lightfoot, 1992). It is also possible that in some cases, invasion of the tumour cells into the nerve causes the reduction in the number of functional nerve fibres (Matsunaga, Kanzaki, & Igarashi, 1995). The disruption of neural synchrony caused by vestibular schwannomas also results in discrepancies with greater deficits in speech recognition thresholds than would be predicted based on pure-tone thresholds (Morlet, Dubreuil, Duclaux, & Ferber-Viart, 2003; Van Dijk, Duijndam, & Graamans, 2000).

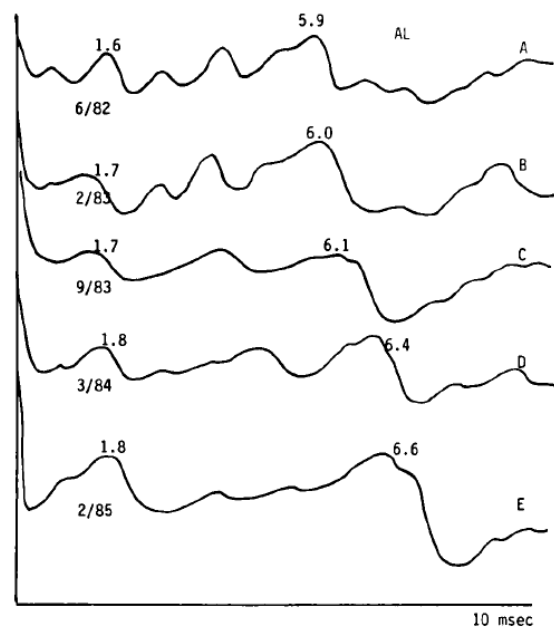


Figure 7. ABR traces from the right ear of a subject who underwent repeated ABRs over a 3 year period because of a family history of bilateral acoustic tumours. A small vestibular schwannoma was detected using enhanced CT scanning in 1983, around the time of the around the time of the third trace shown above. Note the progressively longer wave I-V interval as the tumour increases in size and the loss of amplitude of waves II and III (from Josey, 1987).

While the precise pathophysiology of the hearing loss caused by vestibular schwannomas is unknown, evidence suggests that vestibular schwannomas can have both neural *and* cochlear effects on hearing (Gouveris & Mann, 2004). The cause of noncochlear hearing loss is thought to be direct pressure on the cochlear nerve and its vasculature (Telischi et al., 1995). A study by Lapsiwala, Pyle, Kaemmerle, Sasse, & Badie (2002) investigated preoperative intracanalicular pressure (ICaP) in patients with vestibular schwannomas by inserting a pressure microsensor into the IAC before any tumour manipulation. These measurements demonstrated a direct correlation between ICaP and ABR wave V latency, indicating the neural component of the hearing loss in these patients may, at least in part, be the result of the pressure on the cochlear nerve from tumour growth within the IAC. Further evidence for this theory was provided by Forton, Cremers and Offeciers (2004) who conducted histological examinations of en-bloc removed vestibular schwannomas with evidence of cochlear nerve ingrowth. No significant differences were found between the clinical presentation of these patients and the presentation of patients documented in previous studies reviewed by the authors (Brackmann et al., 2000; Thomsen & Tos, 1988; Van Leeuwen, Cremers, Thewissen, Harhangi, & Meijer, 1995). Forton et al. (2004) assumed that these previous studies included cases that did not demonstrate ingrowth into the cochlear nerve. The authors interpret the absence of a difference between patients with and without ingrowth into the cochlear nerve as support for the theory that preoperative hearing impairment in vestibular schwannomas patients is mainly the result of compression on the vessels of the cochlea and/or on the cochlear nerve, rather than the degree of invasion of tumour cells into the nerve. Matsunaga and Kanzaki (2000) morphologically examined microvessels and nerve fibres in the intracanalicular portion of eighth nerve specimens attached to vestibular schwannomas. They found frequent mild to moderate abnormalities in myelin sheaths, and occasional endoepithelial hyperplasia and hypertrophy, consistent with a slight to moderate reduction of endoneurial blood flow in the nerves. The authors propose that the resultant ischemic condition in the eighth nerve is a cause of the eighth nerve conduction block in vestibular schwannomas.

Cochlear dysfunction has also been reported in 57-100% of vestibular schwannoma cases in the literature (Noguchi, Komatsuzaki, & Nishida, 1998; Prasher, Tun, Brookes, & Luxon, 1995; Telischi, 2000; Yokoyama, Nishida, Noguchi, & Komatsuzaki, 1999). Cochlear loss presumably results from the tumour restricting the vascular supply of the organ of Corti due to pressure exerted on the IAA, leading to cochlear atrophy (Gouveris & Mann, 2004).

Histological studies of the temporal bones of patients with unoperated vestibular schwannomas have provided definitive evidence of degeneration of cochlear structures. These investigations have documented significant degeneration of the hair cells, the stria vascularis, and the spiral ligament in the cochleae of vestibular schwannoma patients (De Moura, 1967; Eckermeier, Pirsig, & Mueller, 1979; Mahmud, Khan, & Nadol, 2003; Suga & Lindsay, 1976).

DPOAEs are likely to be absent for subjects with a moderate hearing loss or worse, therefore recording the CAP and CM may be necessary to adequately assess cochlear function. Studies on animals have shown that vascular occlusion or cochlear nerve compression affected the spiral ganglion cells more in the basal turn of the cochlea than other portions (Kimura, 1986). Thus, a disruption to microcirculation by compression or obstruction of the cochlear nerve and its vascular supply can be expected to affect the high frequencies to a greater degree. This provides an alternative or, at least, supplementary explanation for the high frequency hearing loss that typically presents in vestibular schwannoma patients.

There is potentially a contribution of the cochlear efferent system to cochlear function and tumour-related hearing loss in cases of vestibular schwannoma (Prasher et al., 1995). The vestibular nerve is the carrier of the efferent fibres to the cochlea and given that vestibular schwannomas arise from the vestibular nerve, disruption of the efferent fibres during tumour growth is likely (Ferguson, O'Donoghue, & Owen, 2001). Studies of the efferent system in patients with tumours of the CPA suggest that neural compression by the tumour disrupts the medial efferent control of the basilar membrane of the tumour ear (Ferguson et al., 2001; Maurer, Hinni, Beck, & Mann, 1995). Prasher et al. (1995) found that in 11 vestibular schwannoma patients, all patients demonstrated a reduction in the contralateral suppression of OAEs on the side of the tumour. The authors postulate that the loss of efferent control of active mechanical tuning of the cochlea may lead to loss of frequency selectivity in the early stages of tumour growth and later, a loss of sensitivity (Prasher et al., 1995).

Telischi et al. (1995) describe three distinct types of DPOAE activity associated with vestibular schwannomas: cochlear, noncochlear, and mixed effects. The majority (59%) of tumour ears studied showed cochlear effects, indicating that DPOAEs were reduced from normal levels in a manner that was consistent with the associated diminished hearing. Approximately 30% of subjects demonstrated a noncochlear relationship between DPOAE and hearing levels, defined as DPOAEs that are more robust than expected from the

corresponding hearing thresholds. DPOAE levels for the noncochlear group tended to be similar for the tumour and nontumour ears whereas corresponding hearing thresholds for the tumour ears were about 30-40 dB worse than the nontumour ear. "Mixed" DPOAE patterns were described for ears that had both cochlear and noncochlear patterns present in the same ear at different DPOAE (and respective pure-tone) frequencies. Further evidence for the presentation of mixed cochlear/neural hearing loss in vestibular schwannomas patients was provided by Morlet et al. (2003). In their study of 65 patients Morlet et al. showed that ABRs and TEOAEs can both be normal or abnormal or either one of the tests can be impaired. Collectively, these findings indicate that depending on the location and size of the lesion, vestibular schwannomas can lead to different types of auditory impairment caused by a progressive compression of the cochlear nerve and/or the vascular supply of the peripheral auditory system.

1.7. Tone decay

Tone decay is a reduction in the ability to perceive a continuous tone presented at or above hearing threshold (Carhart, 1957; Thornton & Coleman, 1975). People with no otologic or neurologic abnormalities typically do not perceive a significant reduction in the loudness of a continuously presented tone over time. In some cases of retrocochlear hearing loss, the loudness of the tone progressively decreases until it becomes inaudible. This "tone decay" is a symptom generally associated with a vestibular schwannoma, and previous studies have found abnormal adaptation of 10 to 30 dB in patients with known vestibular schwannomas (Gerull, Morwinski, & Thoma, 1982; Hood, 1955; Morales-Garcia & Hood, 1972; Olsen & Noffsinger, 1974).

The Carhart tone decay test (Carhart, 1957) is used to assess the integrity of the auditory pathway. It is administered through a conventional audiometer, and typically begins with the presentation of a continuous pure-tone (between 0.5 and 4 kHz) at the subject's threshold. The stimulus intensity is adapted by the tester according to the subject's responses. If the subject continues to hear the tone for the full 60 seconds, the test is completed. If the subject fails to maintain perception of the tone for the full 60 seconds, the length of the subject's response to the stimulus is noted, the intensity is increased by 5 dB, and a new 60 second

period begins This procedure is repeated until the subject hears the tone continuously for the 60 seconds or the upper limit of the audiometer is reached.

The tone decay test has been traditionally used by audiologists to differentiate cochlear from retrocochlear pathology. Retrocochlear pathology, such as vestibular schwannomas, is often associated with very high levels of rapid decay at both high and low frequencies (Gertner, 1981; Harbert & Young, 1964; Jerger, 1960; Morales-Garcia & Hood, 1972; Ogawa, Ogawa, Yamamoto, Ikeda, & O-Uchi, 1991). Figure 8 shows patterns of tone decay found in patients with eighth cranial nerve lesions. During sustained stimulation by a pure tone, the threshold intensity may rise 40-50 dB in as little as 60 seconds when the vestibulocochlear nerve is diseased (Jerger, 1960). Subjects with cochlear pathologies typically exhibit tone decay of between 0 to 15 dB, with an increase in the duration of audibility with increasing tone intensity (Morales-Garcia & Hood, 1972; Palva, 1964). In cases of known vestibular schwannomas, tone decay testing may provide an indicator of whether the site of origin of the hearing loss is cochlear or neural. The sensitivity and specificity of tone decay testing in separating ears with and without retrocochlear pathologies does, however, limit the utility of this test. In a meta-analysis of 15 years of published data, Turner, Shepard and Frazer (1984) found that tone decay testing was correct in 70% of cases where retrocochlear pathology was present, and in 87% of cases without retrocochlear pathologies.

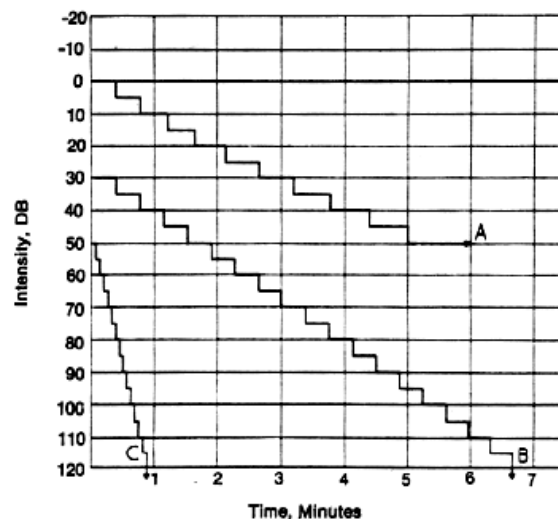


Figure 8. The results of Carhart's threshold tone decay in eighth cranial nerve lesions. In curve A a plateau is reached at 50 dB, in curve B and C tone decay has reached the limits of the audiometer (from Morales-Garcia & Hood, 1972).

1.8. Surgical intervention

The current standard therapy for vestibular schwannomas is surgical excision. Four surgical approaches are presently used for vestibular schwannoma resection: the translabyrinthine, suboccipital, middle (cranial) fossa, and retrosigmoid approaches (Jackler & Pitts, 2008). The approach selected depends primarily on the surgeon's preference and experience, with consideration given to factors including the extent of preoperative symptoms, tumour size and tumour location (Samii & Matthies, 1997). In patients with serviceable preoperative hearing, the retrosigmoid or middle fossa approaches are preferred (Jackler & Pitts, 2008). While the middle fossa approach is only suitable for removal of tumours with limited CPA extension, the retrosigmoid approach uses a posterior fossa craniotomy to provide extensive visualisation of the CPA and provides good exposure of the IAC through drilling of its posterior wall (Yang et al., 2008). Through this approach, the possibility of hearing preservation may be afforded for tumours of all sizes (Lassaletta et al., 2003). Selecting candidates for a hearing preservation approach takes into account a number of factors, including preoperative pure tone thresholds and speech discrimination score, tumour size and depth of tumour penetration in the IAC, and the preferences of the surgeons (Jackler & Pitts, 2008). The translabyrinthine approach is the most reliable for complete tumour removal as sufficient exposure of the CPA and brainstem is provided to permit atraumatic and complete tumour removal of even very large acoustic neuromas. However, this approach inherently sacrifices hearing in the course of the procedure (Arriaga & Chen, 2001).

There are several critical points for hearing preservation during the retrosigmoid approach, including drilling of the IAC, removal of the tumour from the fundus of the IAC, lateral to medial tumour traction, separation of the cochlear nerve from the facial nerve, and stretching of the cochlear nerve (Colletti et al., 1997). In particular, changes in cochlear nerve potentials corresponding to postoperative hearing loss were noted during removal of the tumour within the IAC fundus (Colletti et al., 1997). Colletti and colleagues (1997) suggest that this vulnerability comes from the containment of the cochlear nerve, IAA, and the tumour, within a narrow space at this point. This compact arrangement means that vascular and neural damage may occur simultaneously during this surgical phase (Colletti et al., 1997). However, the authors also note that the effects of potentially damaging surgical manoeuvres are variable as to their impact on hearing in each patient, and are dependent on predisposing

factors, such as the degree of involvement of the cochlear nerve by the tumour (Colletti et al., 1997).

As well as the risk of permanent hearing loss, vestibular schwannoma surgery carries some risk of meningitis (2 to 10%), cerebrospinal fluid leak (5 to 15%) which increases the risk of meningitis (Selesnick, Liu, Jen, & Newman, 2004), facial weakness (4 to 15%), dizziness (5 to 15%) (Enticott, O'Leary, & Briggs, 2005), and headache, which is persistent in 10 to 34% of cases (Ruckenstein, Harris, Cueva, Prioleau, & Alksne, 1996; Soumekh, Levine, Haines, & Wulf, 1996). Intraoperative electromyographic monitoring of the facial muscles may be used to detect and prevent facial nerve damage during surgery (Bozorg et al., 2005; Neff, Ting, Dickinson, & Welling, 2005; Prell, Rampp, Romstock, Fahlbusch, & Strauss, 2007). Independent of tumor size, overall rates of anatomical preservation of the facial nerve greater than 90% are reported (Samii & Matthies, 1997; Yang et al., 2008). Despite recent clinical interest and various refinements in micro-surgical technique, hearing loss is still by far the greatest risk factor associated with vestibular schwannoma surgery.

1.9. Intraoperative monitoring

Electrophysiological measures of auditory function such as ABR, ECochG, and OAEs may be used to objectively assess auditory pathway function intraoperatively. On the basis of these tests, any surgically induced trauma, whether directly damaging the inner ear structures, indirectly damaging the cochlea through the compromise of the blood vessels, or damaging the cochlear nerve, can be detected (Telischi et al., 1999). Monitoring electrophysiological responses using a combination of measures both intraoperatively and postoperatively may allow for real-time detection of damage and the identification of the likely pathophysiological mechanisms of hearing loss. However, intraoperative monitoring of auditory responses is limited by the notoriously high electrical noise in the surgical environment (Martin & Shi, 2006). For this reason it is often not possible to record during portions of the surgery, such as during drilling or cauterisation (Strauss et al., 2001).

Numerous studies have investigated the use of real-time monitoring of electrophysiological responses to provide surgeons with feedback on manoeuvres that cause changes in waveforms, indicating potential damage to auditory structures. For example, a repositioning

of a brain retractor at the point of operation when a change in waveforms is noted can lead to a regeneration of the electrophysiological response (Lenarz & Ernst, 1992). Results of these studies have primarily indicated that on-line monitoring and feedback can improve hearing outcomes (Cohen, Lewis, & Ransohoff, 1993; Danner, Mastrodimos, & Cueva, 2004), however this area is still controversial (Piccirillo et al., 2008).

The prognostic value of intraoperative monitoring during vestibular schwannoma surgery for postoperative hearing outcome is more widely acknowledged (Abramson, Stein, Pedley, Emerson, & Wazen, 1985; Brackmann et al., 2000; Dornhoffer et al., 1995; Fischer, Fischer, & Remond, 1992; Levine, Ojemann, Montgomery, & McGaffigan, 1984). Characteristic patterns have been noted that predict specific hearing outcomes: stable waves during surgery, in particular wave V, indicate the likelihood of hearing preservation; whereas abrupt or progressive irreversible loss of these waves is associated with permanent anacusis (Neu et al., 1999; Strauss et al., 2001). Gradual reversible loss, which is described as a single or repeated transient absence of waves I and/or V, carries a considerable risk for postoperative delayed hearing loss (Strauss et al., 1991).

1.10. Nerve origins of the vestibular schwannoma

Hearing outcome following vestibular schwannoma resection may be influenced by the nerve of origin of the tumour. Tumours originating from the superior (a) and inferior (b) vestibular nerves are depicted in Figure 4. Reports in the literature suggest that the majority of vestibular schwannomas originate from the inferior vestibular nerve (IVN), although the ratio of vestibular schwannomas arising from the superior vestibular nerve (SVN) versus the IVN varies considerably across studies (Jacob et al., 2007; Khrais, Romano, & Sanna, 2008; Komatsuzaki & Tsunoda, 2001; Slattery, Brackmann, & Hitselberger, 1997; Ylikoski, Palva, & Collan, 1978).

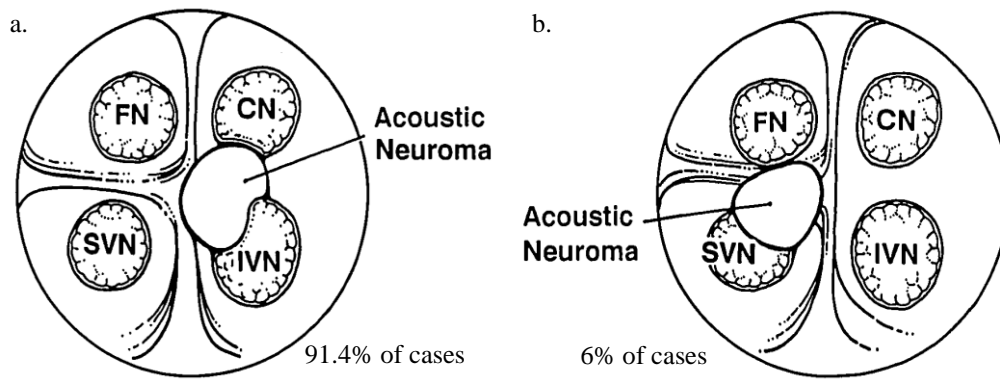


Figure 9. Schematic of vestibular schwannomas originating from the inferior (a) and superior (b) vestibular nerves (adapted from Wilson, Hodgson, Gustafson, Hogue, & Mills (1992), incidence data from Khrais et al., 2008).

Khrais and colleagues (2008) have published the largest series examining nerve of origin in vestibular schwannomas to date. In a prospective review of 200 cases of unilateral vestibular schwannoma, Khrais et al. found that in 152 cases, the tumour involved only one nerve at the fundus. From these cases, the tumour originated from the IVN in 139 cases (91.4%), and from the SVN in only nine cases (6%). The remaining four cases involved tumours originating from either the cochlear nerve or the facial nerve, therefore cannot be classified as true vestibular schwannomas. As the tumour size increased, so did the possibility that more than one nerve was involved.

Because the cochlear nerve is immediately adjacent to the IVN in the internal auditory canal, more surgical manipulation is needed near the cochlear nerve to remove these tumours (Khrais et al., 2008). This may traumatise the cochlear nerve directly or compromise its blood supply. The retrosigmoid surgical approach allows a tumour originating from IVN to shield the anteriorly lying cochlear nerve, thus reducing the surgical trauma (Khrais et al., 2008). The nerve of origin is therefore more likely to be an important consideration when the middle cranial fossa approach is being employed, when this protection is not afforded to the cochlear nerve.

The differential outcome for hearing preservation depending on the nerve or origin of the tumour was recently investigated by Jacob et al. (2007). A retrospective chart review of 40 patients who had tumours removed via the sub-occipital or middle cranial fossa approaches (and for whom hearing outcome and nerve of origin data were available) showed that both

tumour size and nerve of origin were correlated with hearing preservation and facial nerve outcomes. Functional hearing (defined as < 50 dB pure tone average and >50% speech discrimination) was preserved in 10 of 15 patients with tumours of the SVN and seven of 25 patients with IVN tumours. However, Fiscina, Gouveris, & Mann (2007) found that surgically induced damage to the cochlear nerve and/or the IAC vasculature was similar during the dissection via the middle fossa approach of vestibular schwannoma of either superior or inferior nerve origin. It is of note that the ratio of tumours originating from the IVN to tumours originating from the SVN was markedly less in the study of Jacob et al. (2007) compared to the rates reported by Khrais et al. (2008).

1.11. Postoperative outcomes

Postoperative auditory function may be classified into three categories: permanent hearing preservation, permanent anacusis, and hearing fluctuation (Neu et al., 1999). Several factors have been demonstrated to be crucial for hearing preservation, including preservation of the endolymphatic fluids, preservation of the cochlear hair cells and spiral ganglion cells, maintenance of a fluid-filled vestibule, and preservation of the cochlear nerve and its vasculature (McElveen, Wilkins, Erwin, & Woldford, 1991; Schuknecht & Woellner, 1955).

There is a wealth of literature dealing with hearing preservation during vestibular schwannoma surgery and there is a wide variation of reported rates of hearing preservation. Recently reported hearing preservation rates vary from 8 to 70%, however most estimates are typically in the range of 30 to 50% (Betchen, Walsh, & Post, 2005; Darwish, Bird, Goodisson, Bonkowski, & MacFarlane, 2005; Fischer et al., 1992; Fiscina et al., 2007; Frerebeau et al., 1987; Gardner & Robertson, 1988; Jacob et al., 2007; Kaylie et al., 2001; Lassaletta et al., 2003; Magnan et al., 2002; Moffat et al., 1999; Saleh et al., 1996; Samii, Gerganov, & Samii, 2006; Samii & Matthies, 1995; Samii & Matthies, 1997; Samii, Matthies, & Tatagiba, 1997; Sterkers, Morrison, Sterkers, & El-Dine, 1994). Studies reporting hearing preservation rates use a variety of different patient inclusion criteria, surgical procedures and criteria for determining postoperative hearing status. Therefore, the ability to make comparisons of outcomes between studies is limited. In addition, hearing classified as preserved postoperatively may not always be serviceable and is typically worse than hearing preoperatively (Harner et al., 2000).

The most common hearing outcome following surgery for patients that present with some degree of hearing preoperatively is permanent anacusis on the affected side immediately following surgery. Postoperative anacusis may occur in the presence of apparent cochlear nerve preservation, and is believed to be secondary to direct trauma to the cochlea or cochlear nerve, or interruption of the vascular supply to the cochlea and/or cochlear nerve, with subsequent sensorineural hearing loss (Colletti et al., 1997).

The principle preoperative determinants of postoperative hearing outcome are preoperative pure-tone thresholds (Brackmann et al., 2000) and tumour size (Gjuric, Mitrecic, Greess, & Berg, 2007; Hecht, Honrubia, Wiet, & Sims, 1997; Yates, Jackler, Satar, Pitts, & Oghalai, 2003). In a recent study of 110 patients, Yang et al. (2008) reported that preoperative hearing level at high frequencies was a stronger prognostic factor for hearing outcome than overall pure tone average. In patients with tumours larger than three centimetres, hearing preservation is particularly unlikely, and considered to be an unrealistic goal by some authors (Frerebeau et al., 1987; Yates et al., 2003).

There is also evidence that rates of functional hearing preservation are higher in patients with tumours that partially, as opposed to completely, fill the IAC (Mohr, Sade, Dufour, & Rappaport, 2005). However, the importance of the degree of tumour extension into the IAC has been debated by some authors. In a meta-analysis of the impact of tumour size on hearing outcome by Satar, Yetiser, and Ozkaptan (2003), the prognostic strength of tumour size on hearing outcome was found to be significantly weaker when the tumour size included the intracanalicular portion of the tumour. Yong, Westerberg, Dong & Akagami (2008) interpret these findings as indicating a different relationship between the surgical risk of cochlear nerve injury and tumour size in the IAC and CPA compartments. However, they do not consider the variation in risk to the vascular supply of the cochlea. In a study of 31 patients, Yong et al. (2008) demonstrated that the extracanalicular length of contact between the cochlear nerve and the tumour within the CPA, which they propose as a measure of cochlear nerve stretch or extension, is a better determinant of hearing outcome than total tumour diameter. They suggest that IAC involvement imparts a constant risk factor for hearing loss, as no additional predictive value was found for the length of contact between the cochlear nerve and the IAC portion of the tumour (Yong et al., 2008).

Postoperative hearing fluctuation has not been widely reported in the literature documenting the outcomes of vestibular schwannoma surgery (Fahlbusch, Neu, & Strauss, 1998; Neu et

al., 1999; Palva, Troupp, & Jauhiainen, 1985; Strauss et al., 2001; Strauss et al., 1991). Strauss et al. (1991) define postoperative hearing fluctuation as either reversible or delayed hearing loss. In cases of reversible hearing loss hearing recovers following anacusis immediately after surgery. Delayed hearing loss is a phenomenon where hearing is measurable immediately following surgery but anacusis occurs in the early postoperative period. The reported occurrence of delayed hearing loss in the literature ranges from 13 to 24%, although differences between the studies make it difficult to establish the true prevalence (Fahlbusch et al., 1998; Neu et al., 1999; Palva et al., 1985; Strauss et al., 2001; Strauss et al., 1991).

1.12. Early postoperative delayed hearing loss

Delayed deterioration of hearing in the early postoperative period following vestibular schwannoma removal has been documented in at least five studies (Fahlbusch et al., 1998; Neu et al., 1999; Palva et al., 1985; Strauss et al., 2001; Strauss et al., 1991). Such a pattern of postoperative hearing deterioration has also been reported in single cases (Fischer et al., 1992; Levine et al., 1984; Nadol et al., 1987). The published results of Fahlbusch et al. (1998) and Palva et al. (1985) document the occurrence of delayed anacusis in the early postoperative period, but fail to provide any electrophysiological or detailed audiological data that could elucidate the mechanism or time course of hearing loss.

Strauss et al. (1991) were the first to publish a report detailing intraoperative ABR patterns associated with early postoperative delayed hearing loss. In their retrospective analysis of 26 patients with medium to large vestibular schwannomas (average tumour size = 28 mm) and measurable preoperative hearing, Strauss et al. (1991) reviewed intraoperative ABR in each case to attempt to correlate intraoperative patterns of responses with postoperative hearing outcomes. Of the seven patients who showed early postoperative delayed hearing loss, all showed reversible or irreversible deterioration of ABR waves I and/or V during surgery (see Figure 9). This pattern was not specific to patients showing delayed postoperative hearing loss, and a gradual reversible loss electrophysiological pattern accounted for 46% of patients in whom hearing was documented preoperatively. The authors conclude that during the natural postoperative course in these patients who show an intraoperative pattern consistent with hearing fluctuation, up to two-thirds will eventually suffer from anacusis as a result of

tumour removal. Postoperative ABR was recorded in some, but not all cases, and the point at which hearing was lost postoperatively is not well documented.

In a comparable study, Neu et al. (1999) investigated intraoperative ABR patterns in 70 patients with preoperative hearing undergoing surgical removal of vestibular schwannomas, in order to identify patterns associated with postoperative hearing fluctuation. Postoperative audiometry revealed 12 patients with postoperative hearing fluctuation. Of the patients with postoperative hearing fluctuation, one recovered their hearing and 11 showed initial preservation of hearing, but suffered from anacusis in the affected ear in the early postoperative period. Consistent with the observations of Strauss et al. (1991), 32 patients were identified as showing reversible loss of intraoperative ABR. Intraoperatively, eight patients who suffered early postoperative anacusis showed a gradual loss of wave V accompanied by either a gradual loss or a stable wave I. Two patients experienced an abrupt loss of wave I and/or V. One patient did not have wave V present preoperatively but showed a stable wave I throughout surgery. Postoperative ABR data is not provided in this study.

Strauss et al. (2001) conducted a prospective study of patterns of postoperative hearing loss in a series of 41 patients who were identified intraoperatively as having a reversible loss of ABR potentials, as shown in Figure 10. In a group of 20 randomly selected patients whose postoperative care followed the standard protocols, eight showed postoperative fluctuations in hearing, and all these patients eventually suffered from anacusis. In a second group of 21 patients to whom the calcium-channel blocker nimodipine was administered postoperatively, two presented with delayed anacusis in the early postoperative period.

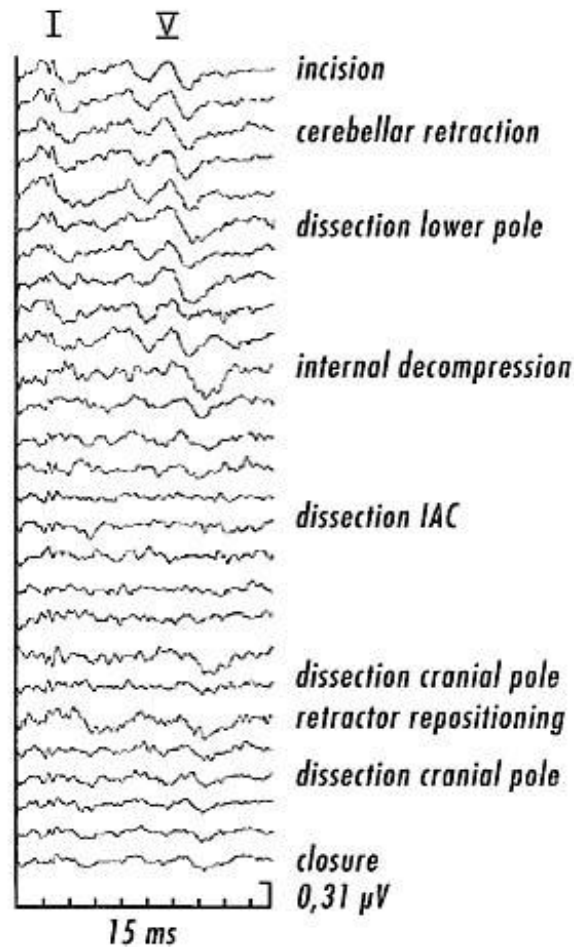


Figure 10. Intraoperative ABR during vestibular schwannoma excision. Note the gradual, reversible loss of wave V (from Strauss et al., 2001).

The documented cases of deterioration of hearing suggest a pathophysiological mechanism is initiated during surgery that continues postoperatively (Neu et al., 1999; Strauss et al., 2001; Strauss et al., 1991). Although only ABR data is provided, an analysis of these responses can provide some information about possible site of impairment and pathophysiological mechanisms that may be responsible for delayed hearing loss. The key result across the ABR data reported in cases of early postoperative delayed hearing loss is a gradual loss of waves I and/or V during tumour removal that is not necessarily associated with specific surgical manoeuvres (Neu et al., 1999; Strauss et al., 2001; Strauss et al., 1991). Across all three studies in which intraoperative ABR results are provided, all patients who suffered from delayed anacusis showed a single or repeated transient absence of a least one wave component during surgery. The most typical presentation of this ABR pattern was a gradual loss of wave V with relatively stable wave I (Neu et al., 1999; Strauss et al., 2001; Strauss et al., 1991). Although a reduction or loss of wave I was noted for some patients, this was

reported less frequently (Neu et al., 1999; Strauss et al., 1991). As stated above, wave I of the ABR reflects only the functional status of the distal cochlear nerve, and does not provide information regarding the transmission of stimuli beyond this point, through the CPA into the brainstem. Therefore, the ABR findings reported in the extant literature implicate the initial site of damage to the auditory pathway in most patients as a portion of the cochlear nerve distal to the generator site of wave I.

Neu et al. (1999), Strauss et al. (1991) and Strauss et al. (2001) each describe a gradual decrease in amplitude or abrupt loss of ABR waves I and/or V, but no changes in the latency of either wave. This suggests that there is a reduction in the synchrony of neurons firing, a delay in neural conduction, or a reduction in the number of nerve fibres responding. A reduction in the number of responding fibres may be indicative of severance of those fibres, or of a neural conduction block caused by a disruption of the continuity of the axons. The fact that no latency changes were observed in intraoperative ABR indicates that neural conduction velocity was not impaired further than the damage already caused by the presence of the tumour during surgery. Alternatively, changes in the integrity of the *dura mater* could reduce resistance, which would increase the velocity of the action potential without affecting latency. A recent study by Brown and Patuzzi (2008) demonstrated that the CAP can be altered by either changes in the action currents themselves, or by changes in the integrity of the *dura mater* which alters its resistance.

On discharge from hospital, all patients in the Neu et al. (1999) study with delayed hearing loss showed an absence of wave I, suggesting that damage to the proximal cochlear nerve eventuated at some point postoperatively. The time course of the progression of damage to the cochlear nerve was not documented. Such data may assist in identifying the pathophysiological mechanism that is responsible for delayed hearing loss.

1.13. Proposed mechanisms leading to early postoperative delayed hearing loss

The pathophysiological mechanism resulting in early postoperative delayed hearing loss is unknown, however, several theories have been proposed. There are two major hypotheses regarding the mechanisms responsible for delayed hearing loss: retrograde degeneration of cochlear neurons due to either direct mechanical insult or disturbances in microcirculation;

and obstruction or vasospasm of the IAA (Levine et al., 1984; Neu et al., 1999; Strauss et al., 2001; Strauss et al., 1991).

1.13.1. Retrograde degeneration following direct mechanical insult to the cochlear nerve?

The initial loss of wave V with a slow deterioration of wave I is consistent with the hypothesis of retrograde degeneration of cochlear neurons as the mechanism of delayed postoperative hearing loss (Hatayama, Sekiya, Suzuki, & Iwabuchi, 1999). This process of retrograde degeneration may be instigated by direct mechanical insult to the nerve during surgery, such as compression, manipulation or stretching of the nerve. Support for this hypothesis comes from animal studies investigating the effect of experimentally induced mechanical compression of the cochlear nerve. Shimamura, Sekiya, Yagihashi, & Suzuki (2002) found that following mechanical compression to the central (CPA) portion of the cochlear nerve in rats, neural degeneration proceeds in a retrograde fashion towards the spiral ganglion cells, eventually leading to disappearance of these cells. This process of degeneration was complete by the end of the first week after the insult, suggesting that cochlear nerve degeneration following compression injury progresses relatively rapidly following the insult.

The mechanism by which compression of the cochlear nerve may lead to degeneration is through disruption of the plasma membrane of the cochlear neurons (Shimamura et al., 2002). Such trauma would allow glutamate to access damaged cochlear neurons directly, causing excessive activation of the excitatory amino acid receptors and an inevitable massive influx of calcium from the extracellular space into the intracellular space (Choi, 1985). Excessive calcium influx can induce a necrotic mechanism, leading to the degeneration of spiral ganglion cells (Choi, 1992; Sekiya, Yagihashi, Asano, & Suzuki, 2002). The trauma to the cochlear nerve would be expected to occur in the central portion of the nerve during vestibular schwannoma surgery. Thus, mechanical damage to the nerve during surgery can be expected to initially affect only ABR components beyond wave I (generated by the lateral portion of the cochlear nerve), in particular wave V. Retrograde degeneration of the nerve would necessarily proceed toward the spiral ganglion cells, and the generator site of wave I. Therefore, as the number of neurons that make up the cochlear nerve deteriorates, wave I can be expected to decrease in amplitude or increase in latency.

Spoendlin (1975) reports that following resection of the cochlear nerve within the IAC, type II neurons and the organ of Corti resist degeneration. The type I fibres, which are the afferent innervation of the IHCs, almost entirely disappeared following nerve resection. This means that essentially the afferent neurons for the OHC system resist degeneration, while the afferent neurons for the IHCs are vulnerable to degeneration following nerve cochlear nerve damage (Spoendlin, 1975).

1.13.2. Retrograde degeneration following a disturbance of neural microcirculation?

An alternative explanation for the patterns of hearing loss observed is a disturbance to the microvasculature of the cochlear nerve (Strauss et al., 2001). Strauss and colleagues (2001) suggest that as a result of direct or indirect surgical manipulations, nerve oedema and vasospasm of the cochlear nerve can initiate disturbances in microcirculation in the endoneurial vasa nervorum, instigating hearing deterioration. As with mechanical insult to the cochlear nerve, disturbed microcirculation of the capillaries supplying the cochlear nerve can lead to massive releases of glutamate during and after nerve ischemia, which in turn can cause an influx of calcium into the damaged neurons, resulting in cell death (Shimamura et al., 2002). Sekiya & Møller (1987) found that compression injury to the cochlear nerve in dogs resulted in disturbances to microvasculature. Following surgical manipulations, histological examination of the cochlear nerve revealed petechial or confluent haemorrhages occurred at the compressed portions of the nerve and degeneration of the nerve fibres and the myelin sheath. Moreover, haemorrhagic foci were found to extend along the cochlear nerve, remote from the site of compression. This suggests that the effects of stretching on the vasa nervorum of the cochlear nerve were transmitted beyond the injured portion of the nerve. In particular, the vasa nervorum haemorrhaged heavily at the Obersteiner-Redlich zone; a relatively avascular portion of the cochlear nerve located at the margin between central and peripheral myelinisation of the cochlear nerve. Postoperative nerve oedema may be aggravated by these disturbances in the microvasculature of the cochlear nerve (Sekiya, Møller, & Jannetta, 1986). In the compact space of the IAC or the modiolus of the cochlea, nerve oedema may compromising the vasculature of the cochlear nerve, leading to ischemia (Sekiya & Møller, 1987).

1.13.3. Collapse of the internal auditory artery?

The same mechanisms that may compromise microcirculation within the IAC may damage the blood supply to the cochlea and vestibulocochlear nerve more directly through obstruction or vasospasm of the IAA (Levine et al., 1984; Neu et al., 1999; Strauss et al., 1991). As described above, cochlear nerve oedema can result in the accumulation of fluid within the confined space of the IAC. As an alternative to disturbances in microcirculation, this could cause the IAA to collapse in the weeks following surgery (Sekiya et al., 1986). MRI changes indicative of cochlear nerve oedema have been observed during the first two weeks after tumour removal, supporting the hypothesis that oedema may disturb cochlear nerve circulation in the early postoperative period (Sekiya, Suzuki, & Iwabuchi, 1990). Sekiya et al. (1990) suggest that the cause of the postoperative oedema was traumatic disruption of the blood-nerve barrier. Vascular disruption to cochlea due to IAA obstruction or vasospasm is likely to manifest as an abrupt deterioration of potentials from the cochlea (CM and DPOAEs), auditory nerve (CAP and ABR wave I) and brainstem (wave V). Electrophysiological tests capable of assessing cochlea function, such as DPOAEs or ECoChG were not carried out by Strauss et al. (1991), Strauss et al. (2001) or Neu et al. (1999), therefore in these studies it was not possible to draw conclusions about cochlear involvement in the observed patterns of delayed hearing loss.

1.13.4. Post-traumatic inflammatory reaction?

There is evidence to suggest that a post-traumatic inflammatory reaction may play a role in the progression of cochlear nerve damage following vestibular schwannoma resection (Sekiya, Shimamura, Suzuki, & Hatayama, 2001). Sekiya et al. (2001) found a massive infiltration of ED-1 immunopositive macrophages into the compressed portion of the cochlear nerve of rats two weeks following experimentally induced nerve compression. This is indicative of the presence of an inflammatory reaction, one of the primary features of necrosis (Bartholdi & Schwab, 1995). Administration of methylprednisolone to one group of rats resulted in a marked reduction in the recruitment of macrophages in the cochlear nerve compared to a control group. The residual number of spiral ganglion cells was also found to be greater in the treatment group than in the control compression group, however, the link

between attenuated macrophage recruitment and improved spiral ganglion cell survival may not necessarily be direct (Sekiya et al., 2001).

1.14. Potential treatments of early postoperative delayed hearing loss

The investigation of the effect of pharmacological effects on postoperative hearing loss following vestibular schwannoma resection can provide additional insights into the mechanisms of such loss. Anti-inflammatory and rheological substances have been used in several studies in an attempt to minimise inflammation, oedema, and the disturbance of the microcirculation of the cochlear nerve and cochlear structures that occur during or after removal of the vestibular schwannoma.

Strauss et al. (2001) investigated whether vasoactive medical treatment with nimodipine, a calcium-channel blocker, following surgical resection of vestibular schwannomas had an effect on hearing preservation. Nimodipine has been successfully used to treat vasospasm following subarachnoid haemorrhage (Barker & Ogilvy, 1996). Based on the pattern of intraoperative reversible loss of potentials, 41 patients were recruited into a prospective randomised study. Twenty-one patients received additional intravenous medication nimodipine for an average of nine days. A control group of 20 patients were given no additional postoperative medication. Results indicated that the treated group had significantly better postoperative hearing outcomes (66.6% versus 30% had hearing preserved) than the untreated group. There were two cases of delayed hearing loss in the treated group and eight in the untreated group. The authors interpret these results as support for the concept of adjuvant medical treatment following removal of a vestibular schwannoma to minimise functional deterioration that would otherwise occur due to disturbed microcirculation. However, two patients in the treated group still exhibited delayed hearing loss, indicating that disturbed microcirculation may not be the mechanism of delayed hearing loss in all cases.

1.15. Aims and hypotheses

The present study aimed to more clearly define the mechanisms responsible for early postoperative delayed hearing loss by closely monitoring patterns of cochlear and cochlear nerve responses during vestibular schwannoma excision and in the early postoperative period.

This study builds on an earlier study that monitored postoperative electrophysiological and behavioural auditory responses in six vestibular schwannoma patients. No cases of early postoperative delayed hearing loss were observed in those six patients. In continuing this study we aimed to increase the number of patients monitored in order to increase the probability of observing delayed hearing loss. In addition, the present study included serial DPOAE testing over the early postoperative period to more closely monitor any changes in OHC function. ABR and DPOAE testing were also continued throughout the postoperative period, even in cases where anacusis was apparent immediately postoperatively. This was not done in the earlier part of the study, but was included here in order to document changes in cochlea and cochlear nerve responses that may occur even in the absence of measurable hearing. Furthermore, the present study included the addition of intraoperative monitoring wherever possible.

These detailed data on electrophysiological and behavioural responses as hearing deteriorates postoperatively are necessary to accurately define the phenomenon of postoperative delayed hearing loss and provide information about likely causal mechanisms. In particular, we aimed to determine if the initial site of impairment leading to delayed hearing loss is neural or cochlear in origin and document the time course of changes in both behavioural and electrophysiological responses. ECoChG and DPOAE measures were included in this study to provide information regarding the cochlear contribution to delayed hearing loss. This is an important aspect in determining the mechanism of delayed hearing loss that has not yet been demonstrated in the literature. Strauss et al. (2001) propose that one reason that postoperative hearing fluctuation has been rarely observed is the difficulty of documenting hearing within the first days following surgery due to the patient's inability to cooperate immediately after the surgical procedure. The focus on electrophysiological recording techniques in the initial postoperative period therefore allows data on the integrity of the cochlea and cochlear nerve to be obtained even when the patient is unable to participate in behavioural testing. It was hoped that information collected on the patterns and time course of delayed hearing loss would assist in identifying the aetiology of such hearing loss, which in turn may lead to the development of techniques and protocols to prevent such damage occurring in the future.

There were two primary hypotheses of the mechanisms of delayed hearing loss and the corresponding patterns of electrophysiological responses that would be observed:

1. Retrograde degeneration of the cochlear nerve due to disturbances to microcirculation or mechanical injury may result in delayed hearing loss. These mechanisms are likely to result in gradual damage to the cochlear nerve, demonstrated electrophysiologically by the initial persistence then gradual loss of ABR wave I and CAP, and the possible preservation of DPOAEs, the CM, and SP postoperatively.
2. Vascular impairment may cause damage to cochlea, affecting cochlear transduction and resulting in loss of all ABR waves and DPOAEs. Internal auditory artery obstruction would cause an abrupt loss of all electrophysiological responses.

2. METHOD

2.1. Participants

In the 11-month period from February to December 2008, 19 patients underwent surgical removal of a suspected vestibular schwannoma via the retrosigmoid approach at Christchurch Public Hospital. Christchurch Public Hospital employs either the retrosigmoid or the translabyrinthine approach for vestibular schwannoma excision. Candidacy for the retrosigmoid approach is determined by tumour size and the possibility of hearing preservation, which cannot be achieved via the translabyrinthine approach. Based on the preference of the surgeons at Christchurch Public Hospital (M. MacFarlane, personal communication, December 1, 2008), the retrosigmoid approach is used for patients with large tumours, even when the likelihood of hearing preservation is poor, because facial nerve preservation rates for large tumours are higher using this approach (Anderson, Leonetti, Wind, Cribari, & Fahey, 2005). All participants were recruited into the present study on the basis that they had some degree of measurable hearing preoperatively.

Demographic characteristics of all participants are shown in Table 1. Of the 19 participants, seven were male and 12 female. One participant (participant 15) had NF2 and was undergoing partial removal of only the left vestibular schwannoma. All other participants were undergoing removal of a unilateral vestibular schwannoma. The range in age was 22 to 75 years (mean = 49.1 years). Tumour size was classified based on the maximal diameter of the extracanalicular portion of the tumour on MRI: tumours <15 mm in maximal diameter were classified as small, 15-29 mm as medium, and >30 mm as large. Using this classification system, eight participants had tumours classified as small, five as medium and four as large. In addition, two patients had tumours confined to the IAC. Of those patients with tumour extension into the CPA, tumour size ranged from 7 to 43 mm ($M = 19.8$ mm, $SD = 10.3$ mm). For the purposes of this study, mean tumour size was calculated based on the extracanalicular diameter, therefore a size of 0 mm was used for patients with intracanalicular tumours. The overall mean tumour size in the CPA, including those patients with intracanalicular tumours, was 17.7 mm ($SD = 11.8$).

Table 1. Participant demographic characteristics and tumour size

Case	Age (years)	Sex	Tumour side	Maximum tumour diameter (mm)	Tumour size classification
1	67	F	R	23	Medium
2	49	F	R	0	Intracanalicular
3	60	F	L	23	Medium
4	49	M	L	9	Small
5	53	M	R	13	Small
6	41	F	R	12	Small
7	57	F	R	9	Small
8	37	F	R	11	Small
9	40	M	L	30	Large
10	40	F	R	18	Medium
11	62	M	R	14	Small
12	37	F	R	37	Large
13	22	M	L	34	Large
14	29	F	R	43	Large
15 ^{NF2}	75	M	R	20	Medium
16	55	F	L	0	Intracanalicular
17	61	F	L	14	Small
18	62	F	R	7	Small
19	47	M	L	20	Medium

NF2 = Case of Neurofibromatosis Type 2

2.2. General Procedure

Preoperative MRI was performed on all patients to confirm the presence of a CPA tumour (classified as a suspected vestibular schwannoma) and to determine the size of the tumour. All participants had undergone previous audiological assessment to confirm the presence of some degree of preoperative hearing, and thus their candidacy for surgery with attempted hearing preservation. The testing procedure included two to four phases: pre- and postoperative monitoring of auditory function was conducted for all participants, and intraoperative monitoring and postoperative ECoG were performed in selected cases where it was considered that this data could provide additional, useful information. To ensure consistency, all testing was performed by the author. A brief outline of all procedures is presented below, with more detail provided on the following pages.

Preoperative assessment – participants underwent a preoperative audiological assessment on the day prior to surgery. This assessment was performed in sound treated rooms in the Audiology Department at Christchurch Public Hospital. The preoperative assessment battery included otoscopy, pure-tone audiometry, speech audiometry, tone decay testing,

tympanometry, DPOAEs, and ABR testing.

Intraoperative assessment – when practically possible and when a clear ABR waveform was identified on the tumour side preoperatively, ABR was recorded intraoperatively at selected intervals throughout the surgery.

Postoperative assessment – The first postoperative assessment of electrophysiological responses was performed 0.5-3 hours following the participant's return to the ward following surgery. This initial assessment included ABR and DPOAEs on the ipsilateral side, and on the contralateral side if the participant was able to move their head to allow positioning of the necessary recording equipment. Otoscopy was carried out prior to testing to rule out significant middle ear effusion due to surgery. ABR and DPOAE testing was repeated on both sides approximately every 24 hours from the time of the initial assessment for the duration of hospitalisation (range = 4-8 days, mean = 6 days). Pure-tone audiometry and speech audiometry were performed as soon as the participant was able to cooperate with the test requirements, and were repeated at 24-hour intervals, or as often as the participant would allow, for the remaining period of hospitalisation. Where participant co-operation was limited the participant was encouraged to undergo a limited section of the test battery (either electrophysiologic or behavioural tests), and normal testing procedures were resumed at the next testing session. Contralateral ear measures acted as an internal control for the effect of external and internal noise on electrophysiological measures, and the effect of pharmacological treatment, general anaesthetic, attention, and background noise on behavioural measures. All postoperative testing was carried out in the neurosurgery ward of Christchurch Public Hospital, in the intensive care room for the first 2-3 postoperative days, and then in a standard six-bed room. The ambient noise levels in the ward were assessed using a sound level meter (IVIE IE33J, Ivie Technologies Inc., Utah, USA). On average, the ambient noise level was 35 dB SPL in ICU, and 40 dB SPL in standard six person rooms, and never exceeded 50 dB SPL in either setting.

Postoperative electrocochleography - Transtympanic electrocochleography (ECochG) was carried out 12 weeks postoperatively if the patient had lost wave I of the ABR during the early postoperative period.

2.3. Specific procedures

2.3.1. *Pure-tone and speech audiometry*

Pure-tone thresholds in dB HL were determined using the modified Hewson-Westlake technique with a calibrated diagnostic audiometer (Grayson-Stadler GSI 61 audiometer for testing in the hospital audiology department and a portable Interacoustic AD28 audiometer for testing in the ward). Signals were presented to each ear using Etymotic Research ER-3A insert earphones or a Radioear B-71 bone conductor. Each participant's air conduction thresholds were measured in 5 dB steps at half-octave frequencies from 0.25 - 8 kHz in each ear. Where air conduction thresholds were 20 dB HL or greater at any frequency(s) from 0.5 - 4 kHz, bone conduction thresholds were measured at the relevant frequency(s). Air conduction masking was applied using a step masking method when the difference between the air conduction thresholds in the non-test and test ears exceeded the minimal interaural attenuation values of 75 dB HL at 1000 Hz and below and 50 dB HL at frequencies above 1000 Hz (Yacullo, 1996). Bone conduction masking was also applied using the step masking method when an air-bone gap of 15 dB or greater was present.

Speech audiometry was performed using the New Zealand Recording of the CVC (Revised AB) Word Lists (National Audiology Centre, Auckland, New Zealand). Word lists were presented via ER-3A insert earphones using a portable compact disc player (Sony D-EJ011) and calibrated audiometer (Grayson-Stadler GSI 61 audiometer for testing in the audiology department and a portable Interacoustic AD28 audiometer for testing in the ward). The maximum word recognition score was established by determining the percentage of words repeated correctly when stimuli were presented 30 dB above the patient's pure-tone average (PTA) at 1, 2, and 4 kHz if the audiogram was relatively flat, or at the average of the best two thresholds at these frequencies if the audiogram was steeply sloping. If the maximum score obtained at this level was less than 90%, the presentation level was increased 10 dB. The speech reception threshold (SRT); defined as the lowest intensity at which 50% of words can be recognized and repeated, was then determined from a performance-intensity function measured in 10-15 dB HL steps. Masking noise was applied to the contralateral ear when the speech presentation level exceeded the best bone conduction threshold in the non-test ear by 50 dB HL or greater.

Hearing was classified pre- and postoperatively according to the Committee on Hearing and

Equilibrium guidelines for the evaluation of hearing preservation in acoustic neuroma (AAO-HNS, 1995). Classifications under these guidelines are based on the PTA at 0.5, 1, 2 and 3 Hz in the ear ipsilateral to the tumour, and the maximum speech discrimination score in that ear at a presentation level not greater than 40 dB SL, or the maximum comfortable loudness level (whichever is lower). As shown in Figure 11, hearing was classified as Class A if the PTA was less than or equal to 30 dB and speech discrimination greater than or equal to 70%; Class B if the PTA was between 31 dB and 50 dB, and speech discrimination was greater than or equal to 50%; Class C if the PTA was greater than 50 dB and speech discrimination was 50% or higher; and Class D included PTAs of any level with maximum speech discrimination scores of less than 50%. Pure-tone average changes of ≥ 10 dB were considered significant.

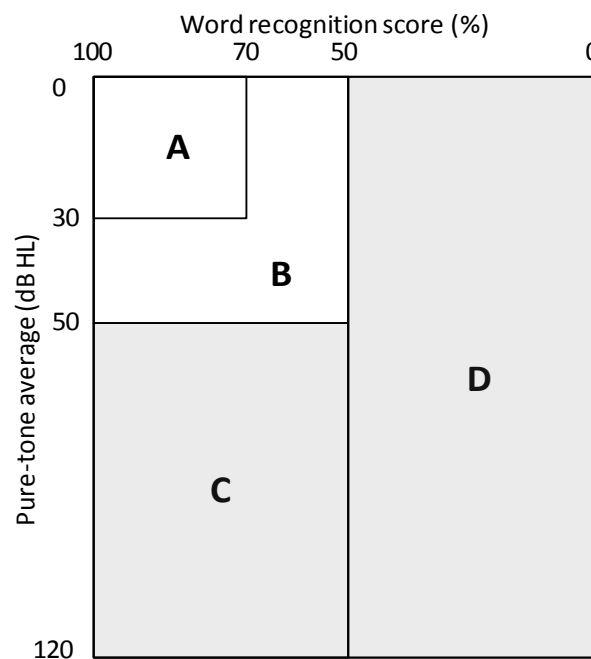


Figure 11. The AAO-HNS (1995) guidelines for classifying hearing in cases of vestibular schwannomas. Pure-tone average at 0.5, 1, 2 and 3 kHz is shown on the vertical axis, and the maximum word recognition score is shown on the horizontal axis. The white boxes, A and B, indicate “serviceable” hearing.

2.3.2. Tympanometry

Tympanometry was performed preoperatively using a Grayson-Stadler GSI Tymptstar tympanometer. The purpose of tympanometry in this study was to check for the presence of middle ear effusion, which causes a conductive hearing loss, thus altering results of both

electrophysiological and behavioural hearing measures. A 226 Hz probe tone was used, with a sweep rate of 50 daPa per second. The recorded traces were compared to normative data published by ASHA (1990). A Type A tympanogram, consistent with normal middle ear pressure and compliance, was classified as a trace with a static admittance between 0.3 and 1.4 mmho, a peak pressure between -100 and +100 daPa, and an ear canal volume at +200 daPa of 0.6-1.6 cm³. Traces with normal volumes and peak pressures, and static admittance values above or below the normal range were classified as Type Ad and Type As respectively. A low peak pressure was interpreted as evidence of a retracted tympanic membrane. A trace with no peak and normal ear canal volume was classified as Type B, indicative of the presence of middle ear effusion. A flat trace with a high volume was taken to suggest a tympanic membrane perforation and a flat trace with a low volume as indicating wax blockage or positioning of the probe tip against the canal wall (ASHA, 1990).

2.3.3. Pre- and postoperative ABR

Apparatus

The ABR was elicited and recorded using the SmartEP evoked potential measurement system (Intelligent Hearing Systems, Florida, USA) and a laptop computer (Toshiba Satellite). Differential recordings were made between the high midline forehead (F_Z) and the ipsilateral earlobe (A₁ or A₂) using self-adhesive silver/silver chloride (Ag/AgCl-) (Ambu Ltd., Xiamen, China) EEG surface electrodes. Earlobe placement of the inverting electrode is preferred over mastoid placement as wave I amplitude is enhanced (Hall, 2006). The earlobe electrode placement also minimised disruption of the site of surgical incision post-operatively. A ground electrode was attached to the lower midline forehead (F_{zp}) (see Figure 12). All participants were tested in a supine position; lying down with the head slightly raised, to minimise electromyogenic interference. The skin was prepared for electrode placement using a combination of abrasion with electrode gel and cleaning with 70% isopropyl alcohol swabs. It was ensured that prior to the commencement of recording, the impedance between any electrode pair was 3000Ω or less. Electrode impedances as low as possible minimise internal noise, thus increasing the common mode rejection ratio and maximising the quality of recordings (Hall, 2006). All possible measures were taken to minimise the electrical interference within the room in which recordings were made. This was achieved by

unplugging unnecessary equipment and turning off lights where possible. In addition, the participants were positioned as far away from the computer and recording equipment as possible.

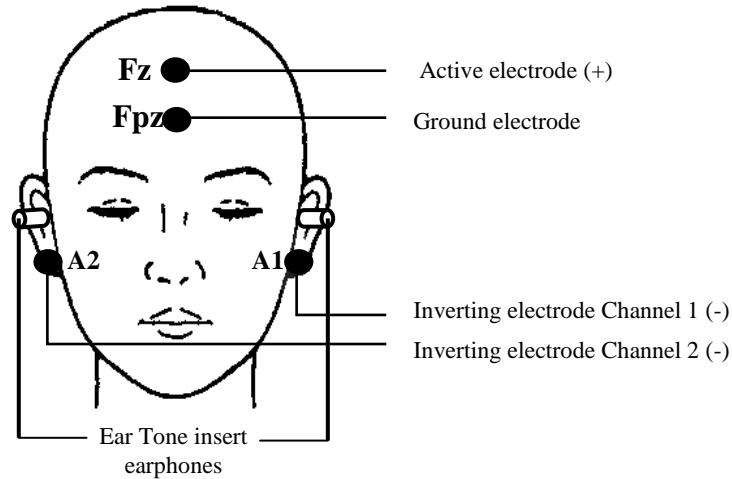


Figure 12. Electrode configuration for ABR recordings. Fz = high forehead, Fpz = lower forehead, A1 = left earlobe, A2 = right earlobe.

Acoustic Stimuli

The ABR was generated using rarefaction clicks with a duration of 100 μ s, presented at a rate of 21.3 clicks per second. The purpose of the ABR in the present study was to test the integrity of the peripheral auditory pathway. As described above, click stimuli activate a large area of the cochlea, thus generating a more robust and synchronous response than ABR elicited with more frequency-specific tone-burst stimuli. The resulting waveforms typically have well-defined peaks, therefore are well suited to determining the integrity of the cochlear nerve. Rarefaction stimuli are preferred for click ABR as evidence suggests that the latency of wave I is shorter and the amplitude larger with rarefaction compared to condensation clicks (Emerson, Brooks, Parker, & Chiappa, 1982; Peake & Kiang, 1962). The chosen stimulus rate was considered optimal for obtaining high amplitude responses in the minimal amount of time (Paludetti, Maurizi, & Ottaviani, 1983). These parameters also allow comparison of the present results with the data of Neu et al. (1999) and Strauss et al. (1991). The air-conducted stimuli were presented monaurally through a shielded Ear Tone ABR insert earphone (Etymotic Research Inc., Illinois, U.S.A.). Insert earphones provide greater attenuation of background noise, have low stimulus artefact, and increase interaural

attenuation, decreasing the need for masking of asymmetric hearing losses, relative to supra-aural headphones (Hall, 2006).

Procedure

Recorded activity was amplified (x 100 000) and sampled for 12 ms after stimulus onset. Responses were filtered using a band-pass filter with a bandwidth of 30 - 3000 Hz and a slope of 6 dB/octave. These filter settings were selected to preserve the morphology, amplitude, and latency of the waveforms, whilst reducing the influence of artefacts and noise on the response (Hall, 2006). In addition, a 50 Hz notch filter was used to eliminate mains interference. The ABR recordings for each participant were obtained using clicks presented at 80 dB nHL in order to obtain maximum amplitude responses. If no clear waveforms were identified, the stimulus intensity was increased to 90 dB nHL. If it was known that the cochlear nerve had been transected during surgery, and patient co-operation was limited, testing was performed at 90 dB nHL only to quickly ascertain whether any remaining cochlear nerve responses were present. The ear contralateral to the tumour was always tested first to confirm that the equipment was working and noise levels were low enough to obtain clear waveforms. A replicate waveform was obtained for each stimulus intensity in each ear to ensure reliability of the response and confirm the presence or absence of peaks. Each waveform trace was the average of 1600-2000 stimulus presentations. Such averaging is necessary when recording ABR to see the desired response above the background EEG activity. When required the contralateral ear was masked by broadband noise to ensure that the non-test ear did not contribute to the ABR recorded from the ipsilateral ear. The criterion used for masking was a difference of 85 dB or greater between the presentation level of the click stimulus, and the best bone conduction threshold in the non-test ear. When masking was required, a standard masking level of 50 dB effective masking was applied. (Hall, 2006).

Analysis

Each ABR waveform was saved into the SmartEP software programme where the responses were visually inspected and evaluated by the author to determine the presence or absence of waveforms. A response was defined as present when the peak(s) were identified in the two traces collected for each condition. Where individual peaks (I, III, V) were identified, the absolute latencies of these peaks were determined based on the average latency of each peak across the two replicate tracings for each condition. Absolute latencies, interaural latency

differences, and interaural interpeak (waves I-V, waves I-III, and waves III-V) differences were compared over testing sessions. Peak latency values were compared to normative data published by Hall (2006). Absolute peak latency changes, interaural latency differences (ILDs), or interaural interpeak differences (IT_{I-V} , IT_{I-III} , and IT_{III-V}) of 0.2 ms or greater were considered to be significant.

2.3.4. Intraoperative ABR

Intraoperative monitoring was performed using click-evoked ABR in four participants (Cases 8, 13, 16 and 19) in whom a clear preoperative ABR was obtained. The stimulus parameters were as described for pre- and postoperative ABR testing, with the exception that each average consisted of 500 samples, to reduce the amount of time required to obtain responses. Standard self-adhesive Ag/AgCl- electrodes (Ambu Ltd., Xiamen, China) were used to record the ABR in the first two participants (Cases 8 and 13), however in an attempt to improve the signal-to-noise ratio, Ambu Neuroline subdermal needle electrodes (Ambu Ltd., Xiamen, China) were used in the third and fourth participants in whom ABR was monitored intraoperatively (Cases 16 and 19). Stainless steel 12mm subdermal needle electrodes were inserted under the skin by the surgeon, to provide consistent, low electrode-skin impedances. Further advantages of needle electrodes are that they can be applied quickly and securely, take up little area on the patient, and do not require preparation of the skin surface (Martin & Shi, 2006). An earlobe to high-forehead electrode configuration was used, as for pre- and postoperative ABR recordings. The recording set-up for intraoperative ABR is shown in Figure 13. To reduce electrical interference in the operating theatre, all cables and recording equipment near the patient were shielded with aluminium foil and earthed.

ABR was recorded from the ear ipsilateral to the tumour at selected points during surgery: prior to incision, after opening of the dura mater, when the tumour was exposed, during debulking, following removal of the CPA portion of the tumour, following completion of drilling into the IAC, following removal of the IAC component of the tumour, and after closure of the dura. These stages of the surgery were selected as representing stages at which the cochlear nerve and/or the IAA may have been damaged, and a change in the ABR could be apparent. Although investigations such as those of Strauss et al. (2001), Neu et al. (1999), and Strauss et al. (1991) have used continuous monitoring of ABR rather than recording at

selected points, the present protocol was selected to optimise ABR recordings by avoiding recording during periods of intense electrical interference, in particular during drilling or cauterisation. Such studies have used continuous monitoring of ABR to provide feedback to surgeons about manoeuvres resulting in a deterioration of auditory responses, which was not the intention of monitoring ABR in the present study. At least two replicates of each response were obtained during each recording phase.

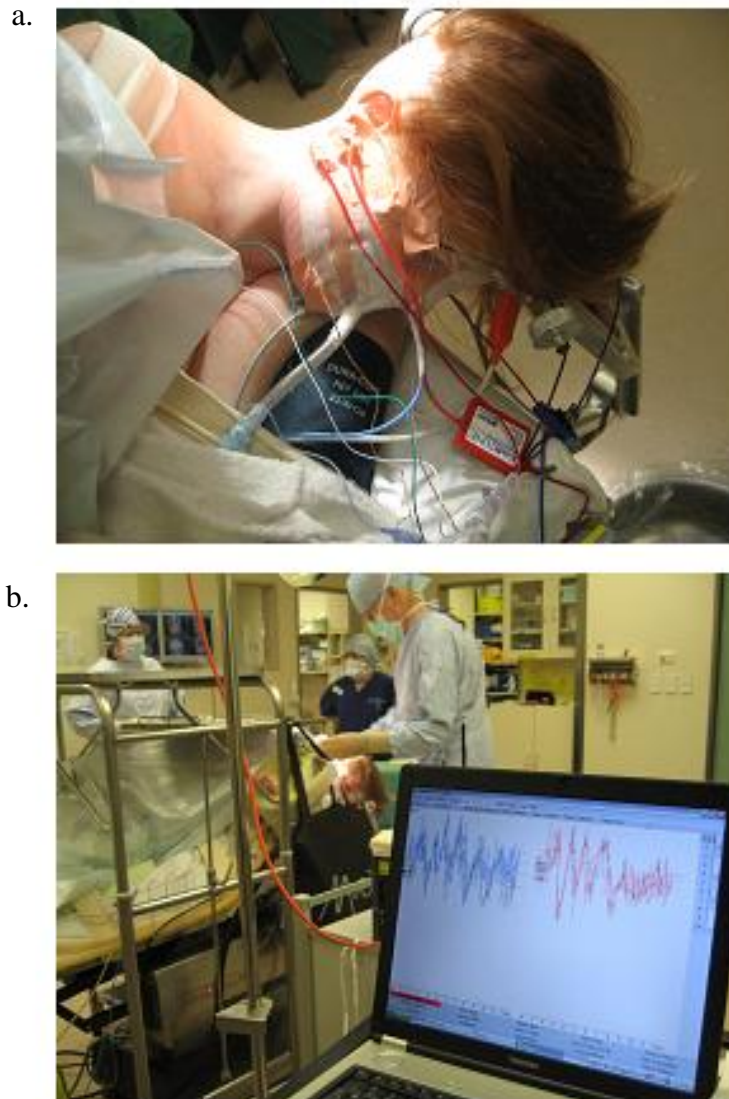


Figure 13. Photographs of set-up used for intraoperative ABR monitoring in Case 8. Part a shows the positioning of self-adhesive Ag/AgCl- electrodes and the transducer on the ipsilateral side. The ABR monitoring equipment is shown in part b.

Recordings were contaminated by the high levels of electrical noise in the operating theatre; therefore all responses recorded were smoothed using a 21-point running average to facilitate identification of replicable ABR peaks. Responses were analysed for the presence or absence

of repeatable peaks, and any changes in latency compared to preoperative responses, or responses earlier in the surgery.

2.3.5. DPOAE measurement and analysis

DPOAEs were evoked and recorded using a commercially available otoacoustic emission measurement system (Scout Otoacoustic Emission System, Bio-Logic, Illinois, U.S.A.). The stimuli consisted of two primary pure-tones; f_1 and f_2 , where the ratio of the frequency of $f_1:f_2$ was 1.22. An $f_1:f_2$ ratio of 1.22 has been shown to be optimal for producing maximal amplitude DPOAEs in humans (Abdala, 1996; Gaskill & Brown, 1990). The intensity level of f_1 and f_2 were kept constant at 65 dB SPL and 55 dB SPL respectively. The amplitude of DPOAEs is also influenced by the overall level of the primary tones, and primary tone level separation (L_1-L_2). In order to test the functional integrity of the outer hair cell's and identify cochlear hearing loss, it is necessary to elicit DPOAEs to moderate level primaries. Higher intensity stimuli evoke larger amplitude DPOAEs, but these responses reflect a passive cochlear process (Dorn et al., 2001). Evidence suggests that DPOAE amplitudes measured in response to primary levels, L_1 and L_2 , of 65 and 55 dB SPL, respectively, are preferable for clinical use, as these levels separate normal hearing and hearing impaired ears with the greatest accuracy (Stover, Gorga, Neely, & Montoya, 1996).

DPOAEs were measured in a descending order at 2.0 to 8.0 kHz by varying the frequency of f_2 in half-octave steps. The spectrum of the noise and the response was shown for the condition being measured. Graphic plots of each pure-tone stimulus level (L_1 and L_2) and the amplitudes of the distortion product emission, $2f_1-f_2$, were shown when each condition was completed. The amplitude and signal-to-noise ratios of DPOAEs were calculated based on a minimum of 50 samples, with a sample size of 1024. The stopping criteria for recording each condition was a minimum DP amplitude of -5 dB *and* a noise floor of a maximum of -17 dB, *or* 20 seconds of recording. DPOAEs were defined as present if the signal-to-noise ratio was greater than 5 dB and the absolute amplitude of the emission was greater than -10 dB SPL (Hall, 2006). The test was repeated if the DPOAE amplitude or signal-to-noise ratio was within 1 dB of the criteria at any f_2 frequency. In cases where a repeat test was performed, DPOAEs were considered present only if they met the criteria for presence in both samples.

2.3.6. *Tone decay*

The Carhart's tone decay test was used to measure abnormal auditory adaptation. Carhart's tone decay procedure has been demonstrated to have greater sensitivity and specificity in separating sensorineural from retrocochlear pathologies than other auditory adaptation testing procedures, such as the automatic Bekesey tone-decay test (Gertner, 1981; Morales-Garcia & Hood, 1972).

The acoustic stimulus presented for the tone-decay test was a 1 kHz continuous pure-tone generated by a calibrated audiometer, and presented monaurally via insert earphones. Testing commenced at the participant's subjective air conduction threshold at 1 kHz. This frequency was selected over higher frequencies as the most common audiometric presentation of vestibular schwannomas is a high frequency loss (Harner et al., 2000). By selecting a lower frequency there was a greater range over which to increase the presentation level in most participants. Although using a frequency where hearing loss is less likely reduced the chance of a pathology being detected, it was hoped that the greater chance of hearing being present postoperatively at 1 kHz would allow postoperative tone decay testing to be conducted. The tone was presented continuously for 60 seconds. If the participant maintained perception of the tone for the duration of presentation, testing was discontinued. If the participant indicated that they could no longer hear the tone during the 60 second period, the intensity of the stimulus was increased in 5 dB increments and the 60 second timing period restarted. This procedure was continued until a level was reached where the tone was heard for 60 seconds or until the participant indicated that the presentation level was uncomfortably loud. The duration for which the tone was heard at each presentation level was measured using a stopwatch, and recorded. The contralateral ear was masked by narrow band noise when the presentation level to the test ear was 75 dB HL or more greater than the air or bone conduction threshold in the non-test ear at 1 kHz (Yacullo, 1996).

Investigations of tone-decay using the Carhart procedure in normal hearing subjects, or subjects with sensorineural hearing loss, suggest that tone decay of 10 dB or less is typical for these populations (Gertner, 1981; Harbert & Young, 1964). Therefore, tone-decay of greater than 10 dB HL was considered a significant indicator for retrocochlear pathology.

2.3.7. *ECochG measurement and analysis*

Apparatus

Transtympanic ECoChG was performed using a commercially available Amplaid electrodiagnostic system (Amplaid MK15, Milan, Italy). An experienced physician performed placement of the needle electrode on the promontory. Following the application of a drop of phenol to locally anaesthetise the tympanic membrane, a sterilised Teflon-insulated stainless steel monopolar transtympanic needle electrode was placed through the tympanic membrane under microscopic guidance and positioned just inferior to the round window niche to rest on the promontory. The needle electrode was held in position using elastic bands attached to a support ring placed over the ipsilateral ear. A differential recording was made between the transtympanic needle electrode and a self-adhesive Ag/AgCl- surface electrode (Ambu Ltd., Xiamen, China) positioned on the ipsilateral mastoid. A second self-adhesive Ag/AgCl- electrode was placed on the low forehead to act as a ground. As for ABR, the skin was prepared for adhesive electrode placement with a combination of abrasion with electrode gel and cleaning with 70% isopropyl alcohol swabs. Prior to recording, it was ensured that the electrode impedance was less than 12 k Ω , which was taken to indicate acceptable needle placement. To minimise electromyogenic interference, the participant was tested in a supine position and asked to remain as still as possible during testing. Electrical interference was minimised by dimming the lights in the test room and unplugging any unnecessary electronic equipment.

The selection of the transtympanic approach over less invasive ECoChG recording methods, was based on the fact that this approach provides a much closer proximity between the recording electrode and the response generators, thus provides the greatest signal to noise ratio (Hall, 2006). The advantage of this is that a large amplitude response is generated with less signal averaging than with other recording methods (Hall, 2006).

Acoustic stimuli

ECoChG was generated using clicks and tone-burst stimuli. Click stimuli had a duration of 100 μ s presented at a rate of 7.1 clicks per second. Like ABR, the CAP of ECoChG is optimally elicited by an abrupt stimulus to obtain a synchronous, and therefore well-defined, response, by virtue of simultaneously stimulating a large population of neurons (Hall, 2006). For this reason a click stimulus was considered optimal in this case for eliciting a CAP when

the intention was to investigate the functional integrity of the cochlear nerve, rather than obtain frequency specific information. A stimulus presentation rate of less than 10 clicks per second was selected to avoid the adaptation of the CAP that may occur at higher presentation rates (Suzuki & Yamane, 1982). The SP and CAP may be obscured by stimulus artefact and the CM (Hall, 2006), therefore clicks were presented in alternating polarity to cancel out the phase-dependent stimulus artefact and CM.

Tone-burst stimuli with centre frequencies of 0.5, 1, 2 and 4 kHz were used to provide a more accurate measurement of absolute SP amplitude (Arenberg, Gibson, Höhmann, & Mihalco, 1992). Non-instantaneous stimuli, such as tone-bursts, produce an SP that extends beyond the CAP, which appears only immediately after stimulus onset and may be obscured by the CAP in click-evoked ECochG recordings (Ferraro, Blackwell, Mediavilla, & Thedinger, 1994). Each tone-burst had a duration of 10 ms with an 1 ms rise-fall time, and was shaped using a Blackman window to maximise the frequency specificity of the stimulus (Hall, 2006). Stimuli of alternating polarity were presented at a rate of 9.1 per second.

The air-conducted stimuli were presented to the participant via supraaural headphones placed in a metal shielded shell and attached magnetically to a support ring positioned over the ipsilateral ear. No contralateral masking noise was required, as ECochG responses are generated prior to the crossover point of the auditory pathway.

Procedure

All stimuli were presented at an intensity of 90 dB HL in order to obtain a response of near-maximum amplitude (Ferraro & Durrant, 2002). Activity was amplified (x 50 000), filtered, and sampled for 5 ms and 15 ms after stimulus onset for click and tone-burst stimuli respectively. The longer sample time used for tone-burst stimuli was employed so that the recorded response extended beyond the stimulus envelope and the baseline pre- and post-stimulus voltage could be seen in the recording window. All samples were filtered using band-pass filters to minimise stimulus artefact and noise. Filter settings for each stimulus type were selected to suppress this unwanted activity while maintaining the morphology of cochlear and neural responses (Hall, 2006). Given that the SP is a DC potential, it is likely to be markedly distorted in response to tone-burst stimuli unless the high-pass filter has a cut-off frequency below 10 Hz to admit DC activity (Ferraro & Durrant, 2006). However, evidence suggests that high-pass filter settings of up to 30 Hz do not distort the SP elicited by click

stimuli (Durrant & Ferraro, 1991). A band-pass filter between 30 Hz and 3 kHz (slope of 6 dB/octave) was used to filter responses to click stimuli. For tone-burst stimuli, band-pass filters were applied with pass bands of 5 Hz to 2 kHz for 0.5 kHz stimuli, 5 Hz to 3 kHz for 1 kHz stimuli, 5 Hz to 4 kHz stimuli, and 5 Hz to 6 kHz for 4 kHz stimuli. Two averaged waveforms of 1000 responses were obtained for each stimulus condition, in order to check for consistency in a replicate waveform. Response measurement was based on the average of these two waveforms for each condition.

Analysis

Waveforms were inspected visually to identify the CAP and SP and evaluate the morphology of these responses. The amplitude of the SP elicited by click stimuli was determined by measuring from the pre-stimulus baseline to the point of intercept between the SP and the CAP. The CAP amplitude was measured from the pre-stimulus baseline to the maximum negative peak of the response (Figure 14).

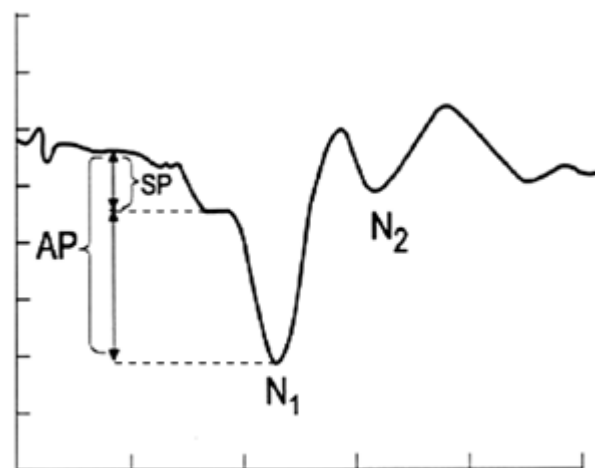


Figure 14. Electrocochleogram elicited by click stimuli illustrating the measurement of the amplitude of the compound action potential (AP) and summing potential (SP) relative to a baseline value (adapted from Ferraro, 2000).

The amplitude of the SP elicited by tone-burst stimuli was measured as the average voltage at the midpoint of the duration of the SP, compared to the pre-stimulus baseline (see Figure 15). This method of response amplitude measurement minimises the influence of the CAP at the stimulus onset, and of the decay of the SP at stimulus offset (Ferraro et al., 1994).

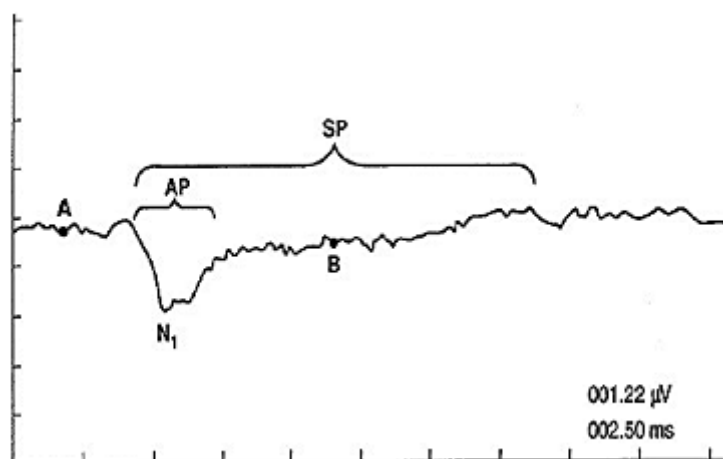


Figure 15. An electrocochleogram elicited by tone-burst stimuli. The amplitude of the summating potential (SP) was measured at the midpoint of response (B), with reference to the pre-stimulus baseline value (A) (from Ferraro et al., 1994).

For each stimulus condition, the absolute amplitude of the SP and CAP, and the ratio of the SP amplitude to the CAP amplitude, were compared with published normative data (Gibson, 1993) to estimate the degree of cochlear function.

2.4. Interpretation of results

Electrophysiological and behavioural responses were analysed on a case-by-case basis and described in detail according to patterns of responses over the early postoperative period. In addition to the audiological data collected, information was obtained from the surgeons regarding events during surgery. This information included the nerve of tumour origin, whether complete tumour removal was achieved, and whether the cochlear nerve was preserved. All analysis of audiological data then took into account these factors for each patient. The pattern of results in each case of a postoperative hearing loss was used to draw conclusions regarding the likely site of impairment.

In addition, statistical comparisons were made to assess for significant differences between the mean tumour sizes, and mean preoperative PTA and WRS between the groups of patients suffering anacusis and those with preserved hearing. Correlational analyses were performed to determine if there was a significant relationship between tumour size and preoperative PTA, and between tumour size and preoperative WRS.

2.5. Ethical Considerations

Ethical approval from the Upper South A Regional Ethics Committee was granted on 22nd May 2007 (Ref: URA/07/03/017, see Appendix A) and ethical approval from the University of Canterbury Human Ethics Committee was granted on 16 June 2008 (Ref: HEC 2008/44). Written consent was obtained from each participant prior to testing (Appendix A), and patient confidentiality was maintained in accordance with the conditions of ethical approval.

3. RESULTS

3.1. Preoperative hearing and overall rate of hearing preservation

From the series of 19 consecutive patients who underwent excision of a presumed vestibular schwannoma via the retrosigmoid approach at Christchurch Public Hospital, 13 patients suffered immediate postoperative anacusis in the ear ipsilateral to the tumour, and measurable hearing was preserved in the remaining six patients. Figure 16 displays pre- and postoperative AAO-HNS (1995) hearing classifications for the ear ipsilateral to the tumour for each patient. As shown, all participants had measurable pure-tone thresholds documented in the preoperative assessment, and all participants, except Case 6, had some degree of measurable speech discrimination in the affected ear. A Class A preoperative hearing status was ascribed to seven participants (Cases 1, 2, 8, 12, 16, 17 and 18), Class B to six (Cases 4, 5, 7, 13, 14 and 19), Class C to 2 (Cases 9 and 10), and four participants had preoperative hearing classified as Class D (Cases 3, 6, 11, 15). The mean preoperative PTA across all participants was 39.3 dB HL ($SD = 19.1$ dB HL) and the mean preoperative WRS was 74.7% ($SD = 31.4\%$).

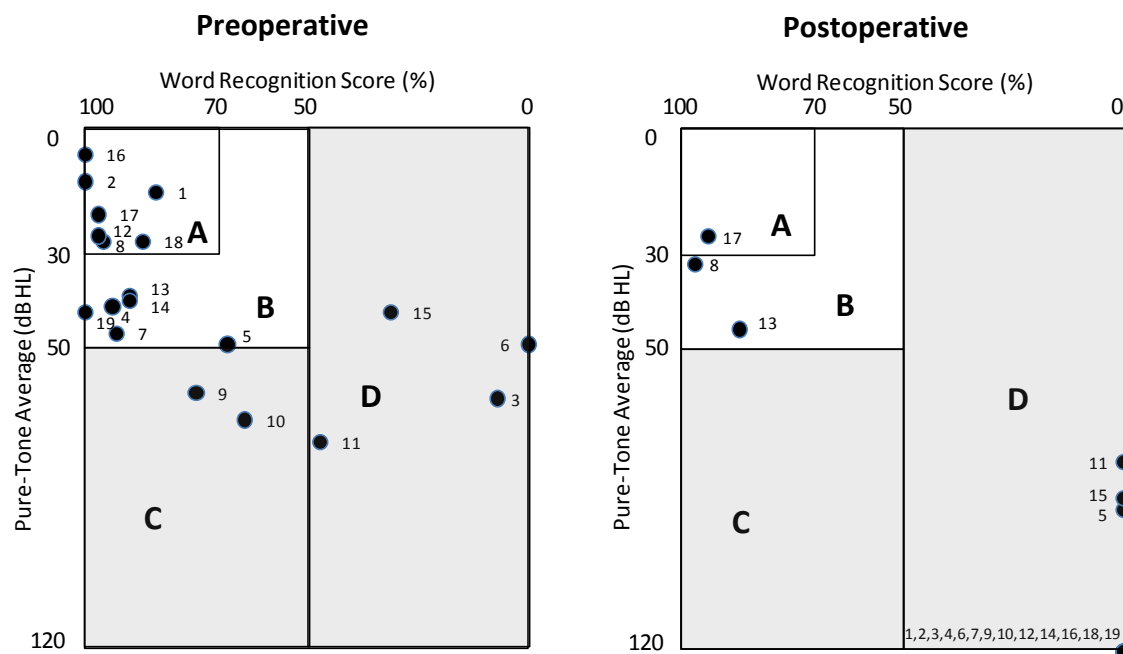


Figure 16. Pre- and postoperative hearing classifications for the ear ipsilateral to the tumour according to the Committee on Hearing and Equilibrium guidelines (1995), for all participants. The number adjacent to each closed dot denotes the case to which that marker refers.

Statistical analyses in this study were performed using a computer-based statistical software package (SPSS for Windows version 17.0, SPSS Inc., Illinois, U.S.A.). A significance criterion of $p < .05$ was used for all tests. Pearson correlations were performed to assess the relationship between preoperative hearing parameters across all participants and the mean extracanalicular tumour size of 17.7 mm ($SD = 11.8$ mm). These correlations showed that there was no significant relationship between tumour size and preoperative PTA ($r(19) = .260, p = .283$), or between tumour size and preoperative WRS ($r(19) = -.045, p = .851$).

The mean tumour size was 17.8 mm ($SD = 13.4$ mm) for patients with postoperative anacusis and 17.7 mm ($SD = 8.5$ mm) for patients with preserved hearing. Levene's Test for Equality of Variance supported the assumption of equal variance between groups for the parameters of tumour size, PTA, and WRS ($p = .20$), therefore an independent samples t-test was performed to compare the means tumour size between groups. No significant difference between tumour sizes for each group was found ($t(17) = .17, p = .987$).

Mean preoperative PTA and WRS were 38.3 dB HL ($SD = 19.4$ dB HL, range = 15.0-67.5 dB HL) and 76.2% ($SD = 34.0\%$, range = 0-100%) respectively for the postoperative anacusis group. These means were compared to those of the hearing preserved group of 41.7 dB HL ($SD = 18.6$ dB HL, range = 26.25-72.5 dB HL) for PTA and 71.5% ($SD = 27.7\%$, range = 31-97%) for WRS. Levene's Test of Equality of Variances indicated equal variance between groups for both parameters ($p = .58$ for PTA and $p = .87$ for WRS). Independent samples t-tests showed no significant difference between group means for either preoperative PTA ($t(17) = .35, p = .73$), or preoperative WRS ($t(17) = -.30, p = .77$).

According to the AAO-HNS criteria, six participants (Cases 3, 6, 9, 10, 11 and 15) did not have serviceable hearing preoperatively. Postoperatively, three participants (Cases 3, 8 and 17) retained serviceable hearing (Class A or B), whereas the remaining 16 cases had a Class D postoperative hearing classification, as shown in Figure 16. The degree of residual hearing in each case will be discussed with particular regard to the likely pathophysiology in section 3.3.

Table 2. Summary of pre- and postoperative data for participants who suffered from postoperative anacusis following vestibular schwannoma removal

Case	Tumour size (mm)	Preoperative						Surgery			Postoperative				
		PTA (dB HL)	WRS (%)	Hearing class	Tone decay (dB SL)	DPOAEs	ABR I ABR V (ms)	Cochlear nerve intact	Nerve of tumour origin	Complete tumour removal	PTA (dB HL)	WRS (%)	Hearing class	DPOAEs	ABR I ABR V (ms)
1	23	15.00	84	A	CNT	2-3 kHz	NR NR	No	IVN	Yes	NR	DNT	D	Absent	NR NR
2	IAC	12.50	100	A	0	2-8 kHz	I = 1.75 V = 5.63	Yes	SVN	Yes	NR	DNT	D	Absent	NR NR
3	23	62.50	7	D	10	8 kHz	NR V = 6.35	Yes	?	Yes	NR	DNT	D	Absent	NR NR
4	9	41.25	94	B	CNT	CNT	CNT	Yes	SVN	Yes	NR	DNT	D	Absent	NR NR
6	12	50.00	0	D	>25^	2-4 kHz	NR NR	No	?	Yes	NR	DNT	D	Absent	NR NR
7	9	47.50	93	B	5	Absent	I = 1.63 V = 6.10	Yes	IVN	Yes	NR	DNT	D	Absent	NR NR
9	30	61.25	75	C	>40^	8 kHz	I = 2.20 NR	Yes	FN	No	NR	DNT	D	Absent	NR NR
10	18	67.50	64	C	5	8 kHz	NR NR	No	SVN	Yes	NR	DNT	D	8 kHz	NR NR
12	37	25.00	97	A	0	CNT	I = 1.70 NR	No	FN	Yes	NR	DNT	D	Absent	NR NR
14	43	40.00	90	B	10	2-8 kHz	I = 2.55* NR	Yes	?	No	NR	DNT	D	Absent	NR NR
16	IAC	6.25	100	A	0	2-8 kHz	I = 1.80 V = 6.50	Yes	SVN	Yes	NR	DNT	D	2-8 kHz	NR NR
18	7	26.25	87	A	0	4 kHz	I = 2.13 V = 6.70	Yes	FN	Yes	NR	DNT	D	Absent	NR NR
19	20	42.50	100	B	0	4-8 kHz	NR NR	No	SVN	Yes	NR	DNT	D	Absent	NR NR

PTA = pure-tone average of 0.5, 1, 2 and 3 kHz

NR = no recordable response

CNT = could not test

WRS = maximum word recognition score

FN = facial nerve

SVN = superior vestibular nerve

IVN = inferior vestibular nerve

? = tumour nerve of origin could not be identified

* = No waves present at 80 dB nHL, latency given is from the response to 90 dB nHL stimuli

^ = Significant tone decay

3.2. Permanent postoperative anacusis

Table 2 presents a summary of tumour characteristics and pre- and postoperative audiological data recorded from the ear ipsilateral to the tumour for the 13 participants for whom no postoperative behavioural audiological responses were present. Postoperative data is presented from the final audiological assessment during each patient's period of hospitalisation. Data presented include:

- i. Tumour size, given as the maximum diameter of the extracanalicular portion of the tumour;
- ii. Pure-tone threshold average (PTA) at 0.5, 1, 2 and 3 kHz (AAO-HNS, 1995);
- iii. Word recognition score (WRS), defined as the maximum speech discrimination score at a presentation level up to 40 dB SL, or at the maximum comfort loudness level, whichever was less (AAO-HNS, 1995);
- iv. Hearing class according to the AAO-HNS guidelines (1995), based on the results given ii and iii;
- v. Tone decay test results - the sensation level of the tone required for the patient to maintain perception of a 1 kHz pure-tone for 60 seconds;
- vi. Presence or absence of DPOAEs at half-octave frequencies from 2-8 kHz;
- vii. ABR peak I and V latencies at 80 dB nHL, where present;
- viii. Whether anatomic preservation of the cochlear nerve was achieved;
- ix. The nerve from which the tumour originated, where identified by the surgeons; and
- x. Whether total tumour removal was accomplished.

Among the group of patients who suffered from immediate postoperative anacusis on the operated side extracanalicular tumour size ranged from 0 mm (intracanalicular) to 43 mm. Tumour size was classified as small (0-1.4 mm) in four patients, medium (1.5-2.9 mm) in four patients, and large (≥ 30 mm) in two patients. The remaining two patients (Case 2 and 16) had tumours confined to the IAC. As shown in Table 2, three of the patients (Cases 9, 12

and 18) included in this study on the basis of having a suspected vestibular schwannoma were found during surgery to have tumours originating from the facial nerve. Due to the anatomic course of the facial nerve within the IAC and CPA, many of the issues regarding hearing loss preoperatively and preservation of hearing during and following surgery, are comparable to those for vestibular schwannomas. Therefore, these data collected from patients with facial schwannomas are presented and discussed with those from patients with vestibular schwannomas. Of the remaining 10 tumours, two were found to originate from the IVN, five from the SVN, and the nerve of tumour origin could not be determined in three cases.

All participants in this group had type “A” tympanograms preoperatively, indicating normal middle ear pressure and compliance, and showed no evidence of middle ear effusion on postoperative otoscopy.

According to the AAO-HNS guidelines (1995), five had Class A hearing preoperatively, four had class B, two Class C, and two Class D. Using the significance criterion of greater than 10 dB SL, tone decay testing was indicative of retrocochlear pathology only in Cases 6 and 9, in which perception of the tone could not be maintained for 60 seconds at maximum comfortable test levels of 25 dB SL and 40 dB SL respectively.

Preoperative DPOAE testing documented the presence of at least one emission from 2-8 kHz in 10 of the 11 participants tested in this group. In two cases preoperative DPOAE testing could not be completed: Participant 4 was unavailable for preoperative electrophysiological testing and Participant 12 had severe loudness intolerance which prohibited DPOAE testing. No preoperative DPOAEs were present in Case 7. Three participants (Cases 2, 14, and 16) demonstrated robust DPOAEs from 2-8 kHz preoperatively. Cases 2 and 16 also showed the presence of ABR wave I of at normal absolute latencies (1.75 ms and 1.80 ms respectively) when tested at 80 dB nHL. In Case 14, although DPOAEs were present at 2-8 kHz, ABR wave I was not evident at 80 dB nHL, and was delayed (2.55 ms) at 90 dB nHL.

At least one reproducible ABR peak was identified in eight of the 12 cases in which ABR was recorded preoperatively. Wave I was absent or delayed in eight cases and present at a normal absolute latency in the remaining four cases (Cases 2, 16, 7, 12). Both ABR waves I and V were obtained at normal absolute latencies at 80 dB nHL in Cases 2 (I = 1.75 ms, V = 5.63 ms) and 7 (I = 1.63 ms, V = 6.10 ms). Based on interaural latency differences, however, ABR was abnormal in Case 2 given that waves III and V were significantly delayed relative

to the ABR in the contralateral ear (ILD = 0.23 and 0.28 for waves III and V respectively). In contrast to the significant absolute interaural latency differences in Case 2, the interaural interpeak differences ($IT_{I-III} = 0.13$ ms, $IT_{III-V} = 0.05$ ms, $IT_{I-V} = 0.18$ ms) in this case do not meet the criteria for abnormality. In Case 7 preoperative ABR one the ipsilateral side is abnormal based on the IT_{I-V} of 0.28 ms, despite the absence of significant interaural peak latency differences. Case 18 showed a slightly delayed wave I (2.13 ms), although no significant interaural latency difference was present for wave I, and significantly delayed waves III and V with absolute latencies of I = 4.80 and V = 6.60 ms, and ILDs of 0.62 and 1.0 ms respectively. Interaural interpeak latency differences were also significant in Case 18 ($IT_{I-III} = 0.50$ ms, $IT_{III-V} = 0.32$ ms, $IT_{I-V} = 0.82$ ms). Cases 9 and 14 (at 90 dB nHL only) each demonstrated a delayed wave I with no wave V, and in Case 3 a normal latency wave III and a delayed wave V (6.35 ms) were present in the absence of wave I. In Case 12 only a normal latency wave I was evident preoperatively. Reproducible ABR could not be obtained at 80 or 90 dB nHL in Cases 1, 6, 10, or 19.

Anatomical preservation of the cochlear nerve was achieved in eight of these thirteen cases, with the nerve being severed intraoperatively in Cases 1, 6, 2, 19, and 10. Incomplete tumour removal was achieved in Cases 9 and 14: In Case 9 the tumour was found to be a facial nerve schwannoma with complete tumour removal being sacrificed in order to preserve the facial nerve; while in Case 14 the tumour was highly vascular and subsequently difficulties maintaining haemostasis occurred during its excision. For this reason the surgeons elected to perform a subtotal removal of the tumour.

Intraoperative ABR was recorded in Cases 16 and 19 in this group. However, in Case 19 the recordings were contaminated by elevated levels of high-frequency electrical noise in the operating theatre, which obscured the responses. These recordings are presented in Appendix B. Similarly, in Case 16 the recordings were subject to high noise, however a wave I could be identified throughout most of the surgery. These data are shown in Figure 22 and discussed below with the pre- and postoperative data collected in Case 16.

Of the 13 participants who presented with immediate postoperative anacusis, 11 showed no measurable responses postoperatively on pure-tone audiometry, ABR, or DPOAE testing. Detailed pre- and postoperative results for each of these cases of postoperative anacusis with no postoperative electrophysiological responses are presented in Appendix B.

3.2.1. Anacusis with preservation of electrophysiological responses

In two of the cases in which patients suffered immediate postoperative anacusis on the ipsilateral side, DPOAEs were preserved throughout early postoperative period. Pre- and postoperative data for these two patients are presented in detail.

Case 10

Participant 10 was a 40-year old female who presented at Christchurch Public Hospital for removal of a medium suspected vestibular schwannoma on the right side. The patient was initially referred for MRI due to a sudden decrease in hearing in the right ear. The tumour had the following dimensions, as seen on most recent MRI, performed approximately five months earlier: 16 mm in maximum oblique length from the anteromedial pole to the posterolateral pole in a plane parallel to the face of the petrous bone; 18 mm in maximum oblique width from the medial pole as it indented the cerebellum to the plane of the face of the petrous bone; 18 mm in maximum oblique vertical height; with an intracanalicular portion with a maximum length of 7 mm, occupying the medial 70% of the moderately expanded high IAC.

The results of the preoperative assessment for this patient are detailed in Figures 17 and 18. Preoperative pure-tone audiometry revealed a mild to profound U-shaped sensorineural hearing loss extending to a moderate loss at 8 kHz in the right ear (ipsilateral to the tumour) (PTA = 67.5 dB HL). Speech discrimination in the right ear was poorer than would be predicted on the basis of the pure-tone audiogram, with a maximum word recognition score of 64% obtained at a presentation level of 90 dB HL. Pure-tone thresholds obtained for the left ear were within the normal range across the frequency range tested (PTA = 16.2 dB HL). Speech audiometry was also consistent with normal hearing in the left ear (WRS = 100% at 50 dB HL). Tone decay results alone did not suggest retrocochlear pathology, with a presentation level of only 5 dB SL required for the participant to maintain perception of the pure-tone for 60 seconds. Objective measures of OHC function via DPOAEs indicated emissions were present at 8 kHz only in the right ear, and at 2-8 kHz in the left ear. ABR testing in the right ear produced no identifiable waveforms at 80 or 90 dB nHL. The ABR recorded from the left ear showed reproducible waves I, III, and V at normal latencies, as shown in Figure 17A and B (Hall, 2006).

During surgery, the surgeons cut the cochlear and vestibular nerves to facilitate the removal of the tumour from the facial nerve. The surgeon noted that the tumour originated from the SVN, and that both the cochlear and vestibular nerves were very thinned out. Consistent with the dissection of the cochlear nerve and the absence of preoperative ABR, no postoperative ABR was evident at the first postoperative assessment three hours following surgery, or on postoperative days 1 or 5. Pure-tone audiometry confirmed postoperative anacusis. As indicated in Figure 17C DPOAE testing throughout the patient's hospitalisation (discharged on postoperative day 6) showed the persistence of an emission at 8 kHz.

Case 16

Figures 19, 20 and 21 detail the pre- and postoperative electrophysiological and behavioural data for Case 16. This data was collected from a 55-year old female who presented at Christchurch Public Hospital for removal of a left-sided, intracanalicular, suspected vestibular schwannoma. The patient was first seen by an otolaryngologist for diagnosis and treatment of horizontal canal benign paroxysmal vertigo (BPV). Following successful treatment of the BPV, some non-positional disequilibrium persisted, therefore the patient was referred for MRI. MRI scans taken three months prior to surgery showed that the tumour was intracanalicular with the medial pole just projecting into the CPA. The left IAC was moderately expanded and the medial 90% occupied by tumour. The tumour measured 12 mm in maximum longitudinal length in the plane along the axis on the IAC and 8 mm in maximum diameter just lateral to the plane of the face of the petrous bone in the medial portion of the IAC.

As shown in Figure 21A, Participant 16 had hearing within normal limits bilaterally, across the frequency range tested, however there is a slight asymmetry in hearing, with the left ear being poorer (left PTA = 6 dB HL, right PTA = 0 dB HL). Speech discrimination results were consistent with the pure-tone audiogram for both ears (left: WRS = 100% at 30 dB HL, right: WRS = 100% at 15 dB HL). Tone decay was negative for retrocochlear pathology, with perception of the tone maintained for 60 seconds at presentation levels of 0 dB SL in each ear. DPOAE testing showed present emissions at 2-8 kHz bilaterally. ABR recordings from the left ear (ipsilateral to the tumour) at 80 dB nHL showed a reproducible wave I at a normal latency (1.80 ms), and waves II, III, and V that were of normal morphology, but delayed relative to those recorded from the contralateral ear (wave II interaural latency difference (ILD) = 0.55 ms, wave III ILD = 0.67, and wave V ILD = 0.70 ms). Waves I, II, III and V

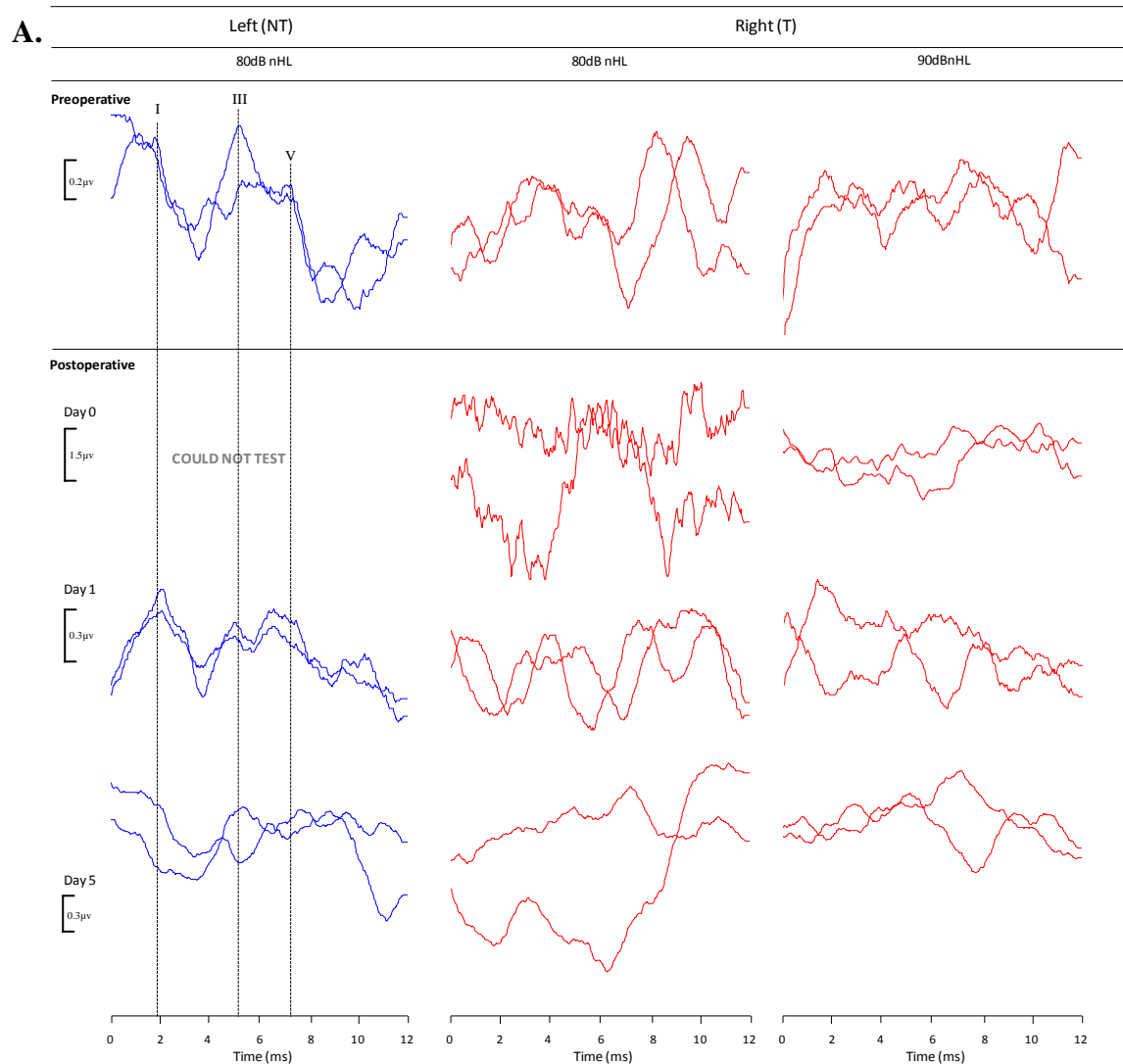
were present at normal latencies in the contralateral ear. Interaural interpeak differences were significant indicators of retrocochlear pathology for waves I-III ($IT_{I-III} = 0.6$ ms) and waves I-V ($IT_{I-V} = 0.63$ ms).

Complete tumour removal from the SVN with preservation of the cochlear nerve was achieved surgically. Intraoperative ABR recorded in this case is presented in Figure 22. Although noise levels are high in these recordings, it is evident that a wave I was present throughout surgery, but could not be recorded following closure of the dura. Wave V could not be identified at any point following opening of the dura, and wave III was not measurable following cerebellar retraction. Due to the noise and artefact in the recordings it cannot be determined whether the loss of these waves is due to damage to the auditory structures, or due to changes in noise or artefact levels obscuring parts of the response. However, these later waves were also absent postoperatively.

The initial postoperative ABR assessment in the ear ipsilateral to the tumour was performed approximately one hour after the patient's return to the ward following surgery. As shown in Figure 19A and B, the ABR recorded in this assessment documented a replicable wave I at 1.88 ms at 80 dB nHL, a latency not significantly different to that measured preoperatively, and at 1.80 ms at 90 dB nHL. No waves beyond wave I were present at 80 or 90 dB nHL. All DPOAEs from 2-8 kHz were also present. Robust DPOAEs across the frequency range tested persisted throughout the early postoperative period. The patient reported that she perceived she had some residual hearing in the first three days postoperatively, however, as shown in Figure 21A, pure-tone audiometry performed as soon as the patient was able to cooperate on postoperative day 2 showed no responses at the limits of the audiometer. No evidence of measurable behavioural thresholds was found at any time postoperatively. As shown in Figure 19A and B, ABR wave I was clearly identifiable at 80 and 90 dB nHL on recordings made on postoperative days 0-5. Over these test sessions the latency of wave I gradually increased to a maximum of 2.35 ms at 80 dB nHL and 2.10 ms at 90 dB nHL on postoperative day 5. On postoperative day 6, the final assessment before the patient was discharged, a reproducible wave I was not identifiable at 80 or 90 dB nHL. No significant changes were noted on any result from tests performed on the contralateral side during the early postoperative period.

Twelve weeks after surgery, the patient underwent further audiological assessment. Pure-tone audiometry at this time showed that the postoperative anacusis in the left ear had persisted

(see Figure 21A). DPOAEs remained present at 2-8 kHz bilaterally. No replicable ABR waves were present in recordings evoked from the left ear. Transtympanic ECoChG was performed as part of this assessment to determine the level of cochlear function. ECoChG traces are presented in Figure 20A and amplitude values are shown Figure 20B. Click-evoked transtympanic recordings from the left ear provided evidence of cochlear function, demonstrating a small CAP (9.20 μ V) with an SP (6.44 μ V). The ratio of the amplitudes of the SP and CAP was 70%. ECoChG elicited by tone-burst stimuli showed an SP with no CAP at 2 kHz and 4 kHz, and no measurable responses to stimuli of 0.5 kHz and 1 kHz.



B. Contralateral (left) peak latencies (ms)

Day	I	II	III	IV	V
Preop	1.75	-	5.35	-	7.42
Postop 0	Could not test				
Postop 1	2.01	-	5.15	-	7.43
Postop 5	No identifiable peaks				

Ipsilateral (right) peak latencies (ms)

Day	80 dB nHL					90 dB nHL				
	I	II	III	IV	V	I	II	III	IV	V
Preop	No identifiable peaks					No identifiable peaks				
Postop	No identifiable peaks					No identifiable peaks				

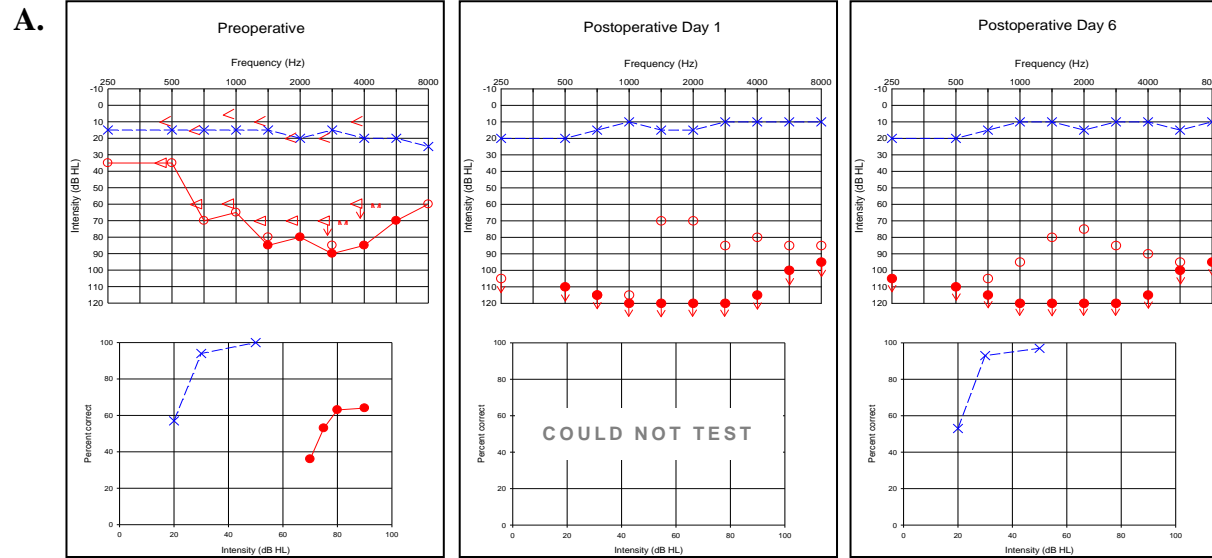
C. Contralateral (left) DPOAEs

Day	f_2 frequency (Hz)				
	2000	3000	4000	6000	8000
Preop	+	+	+	+	+
Postop 1	+	+	+	+	+
Postop 2	+	+	+	+	+
Postop 4	+	+	+	+	+
Postop 5	+	+	+	+	+

Ipsilateral (right) DPOAEs

Day	f_2 frequency (Hz)				
	2000	3000	4000	6000	8000
Preop	-	-	-	-	+
Postop 1	-	-	-	-	+
Postop 2	-	-	-	-	+
Postop 4	-	-	-	-	+
Postop 5	-	-	-	-	+

Figure 17. Case 10: Electrophysiological auditory responses collected before and after vestibular schwannoma surgery. Part A shows a time-ordered sequence of click-evoked ABR traces from the left and right ears; with the latencies of waves present in these traces shown in part B. Part C shows the serial DPOAE data collected pre- and postoperatively; + indicates present DPOAEs and – indicates their absence.



B. Preoperative tone decay

Ear tested	Tone intensity (dB HL)	Tone duration (s)
Left (NT)	15	60
Right (T)	65	0
	70	60

Figure 18. Case 10: Behavioural audiological responses collected before and after vestibular schwannoma surgery. Part A shows a time-ordered sequence of results of pure-tone and speech audiometry. The right and left ears are represented by circles and crosses respectively (filled circles and double crosses indicate the use of contralateral masking). Part B shows the duration of tone perception at each intensity level presented in tone decay testing.

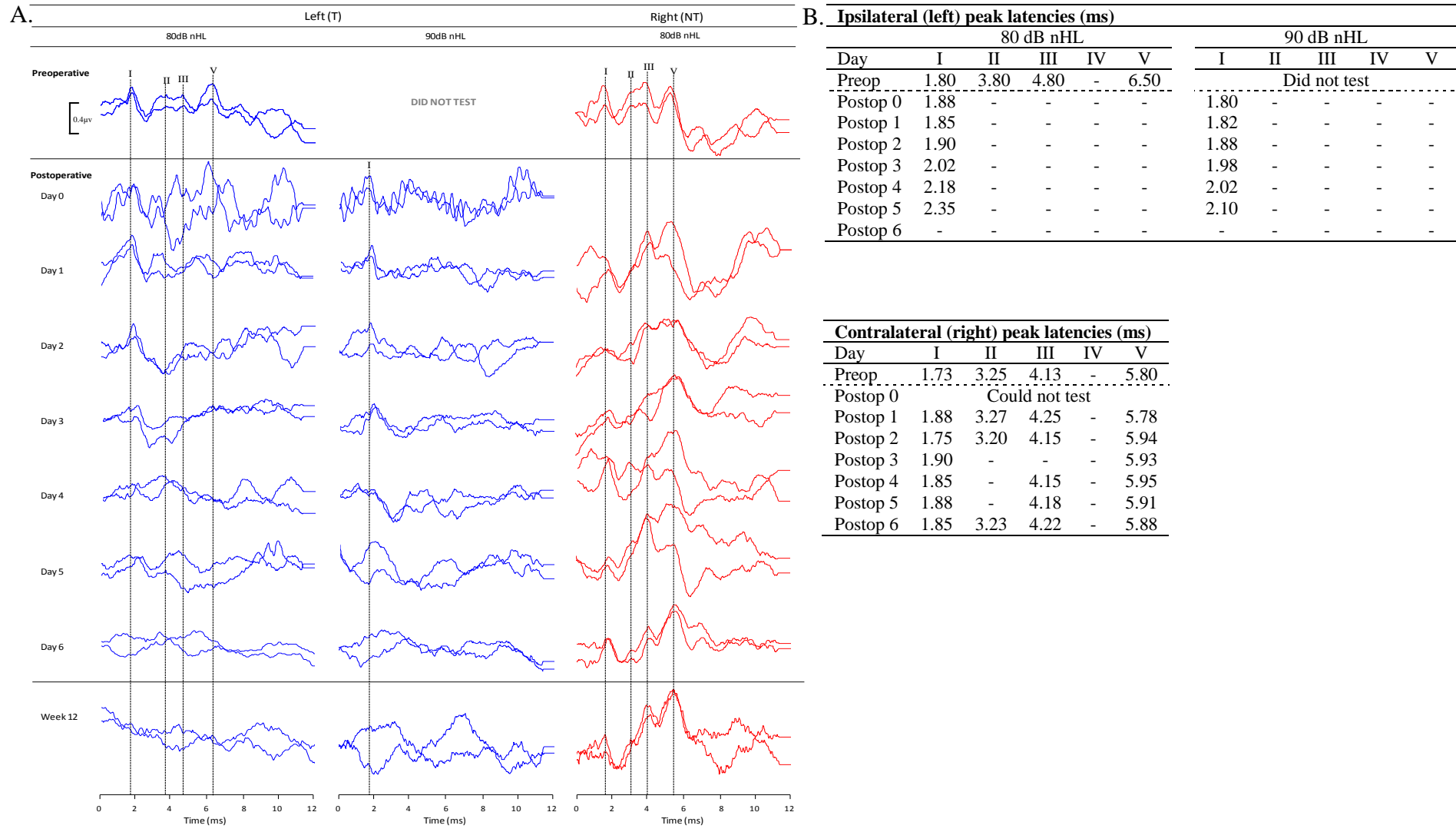
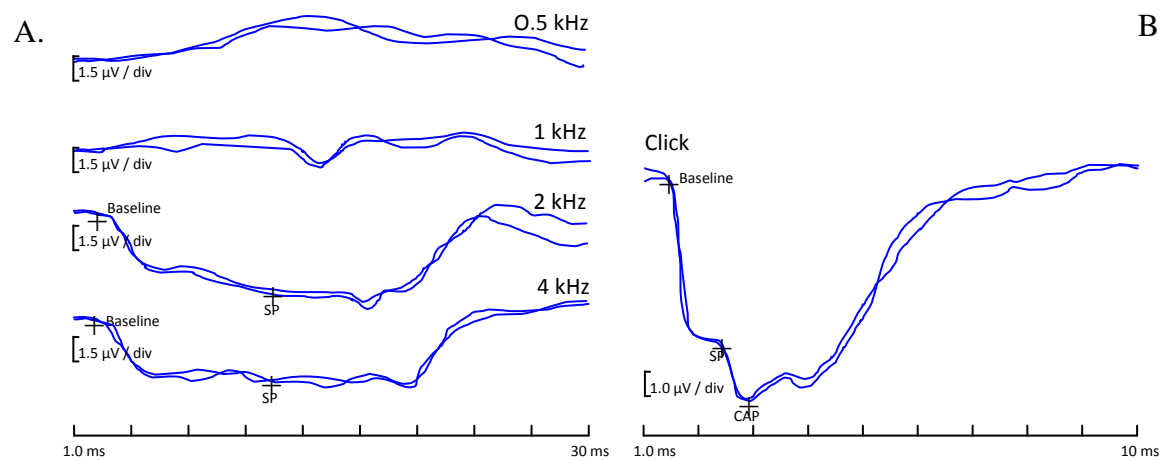


Figure 19. Case 16: Electrophysiological auditory responses collected before and after vestibular schwannoma surgery. Part A shows a time-ordered sequence of click-evoked ABR traces from the left and right ears; with the latencies of waves present in these traces shown in Part B.



B. Electrocochleography response amplitudes

	Stimulus				
	Click	Tone burst frequency (kHz)			
		0.5	1	2	4
SP amplitude (μV)	-6.44	NR	NR	-4.96	-4.40
CAP amplitude (μV)	-9.20	NR	NR	NR	NR
SP/CAP ratio	70%	-	-	-	-

C. Ipsilateral (left) DPOAEs

Day	f_2 frequency (Hz)				
	2000	3000	4000	6000	8000
Preop	+	+	+	+	+
Postop 0	+	+	+	+	+
Postop 1	+	+	+	+	+
Postop 2	+	+	+	+	+
Postop 3	+	+	+	+	+
Postop 4	+	+	+	+	+
Postop 5	+	+	+	+	+
Postop 6	+	+	+	+	+

Contralateral (right) DPOAEs

Day	f_2 frequency (Hz)				
	2000	3000	4000	6000	8000
Preop	+	+	+	+	+
Postop 0	Could not test				
Postop 1	Could not test				
Postop 2	+	+	+	+	+
Postop 3	+	+	+	+	+
Postop 4	+	+	+	+	+
Postop 5	+	+	+	+	+
Postop 6	+	+	+	+	+

Figure 20. Case 16: Electrophysiological auditory responses collected before and after vestibular schwannoma surgery. Part A shows transtympanic electrocochleograms evoked from the left ear by tone-bursts (left panel) and clicks (right panel), 12 weeks after surgery. The amplitudes of the summating potential (SP) and compound action potential (CAP) in these recordings are shown in Part B. Part C shows the serial DPOAE data collected pre- and postoperatively; + indicates present DPOAEs and – indicates their absence.

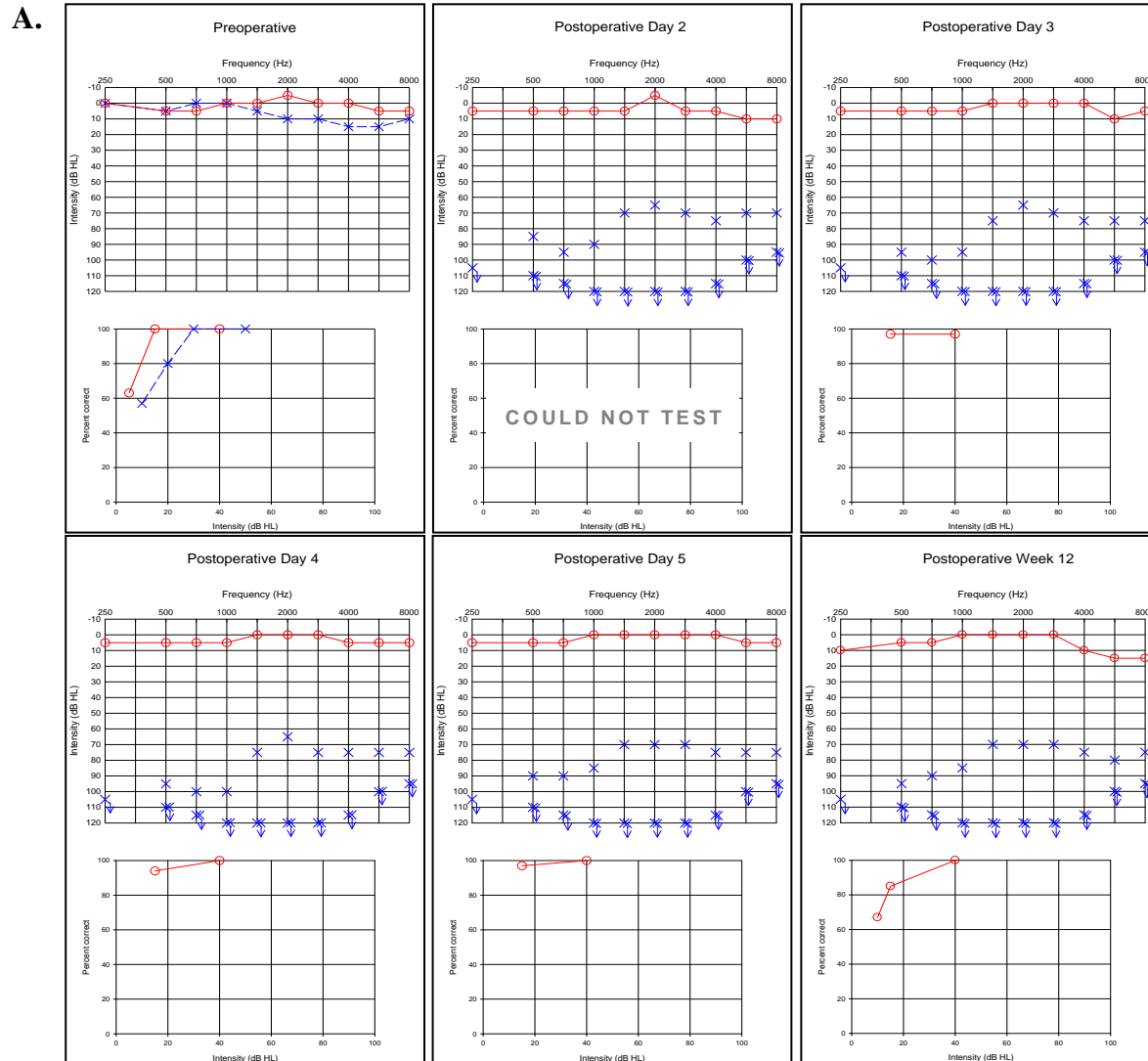


Figure 21. Case 16: Behavioural audiological data collected before and after vestibular schwannoma removal. Results of pure-tone and speech audiometry are shown in Part A. The right and left ear are shown by circles and crosses respectively (filled circles and double crosses indicate the use of contralateral masking). Part B shows the duration of tone perception at each intensity level presented in tone decay testing.

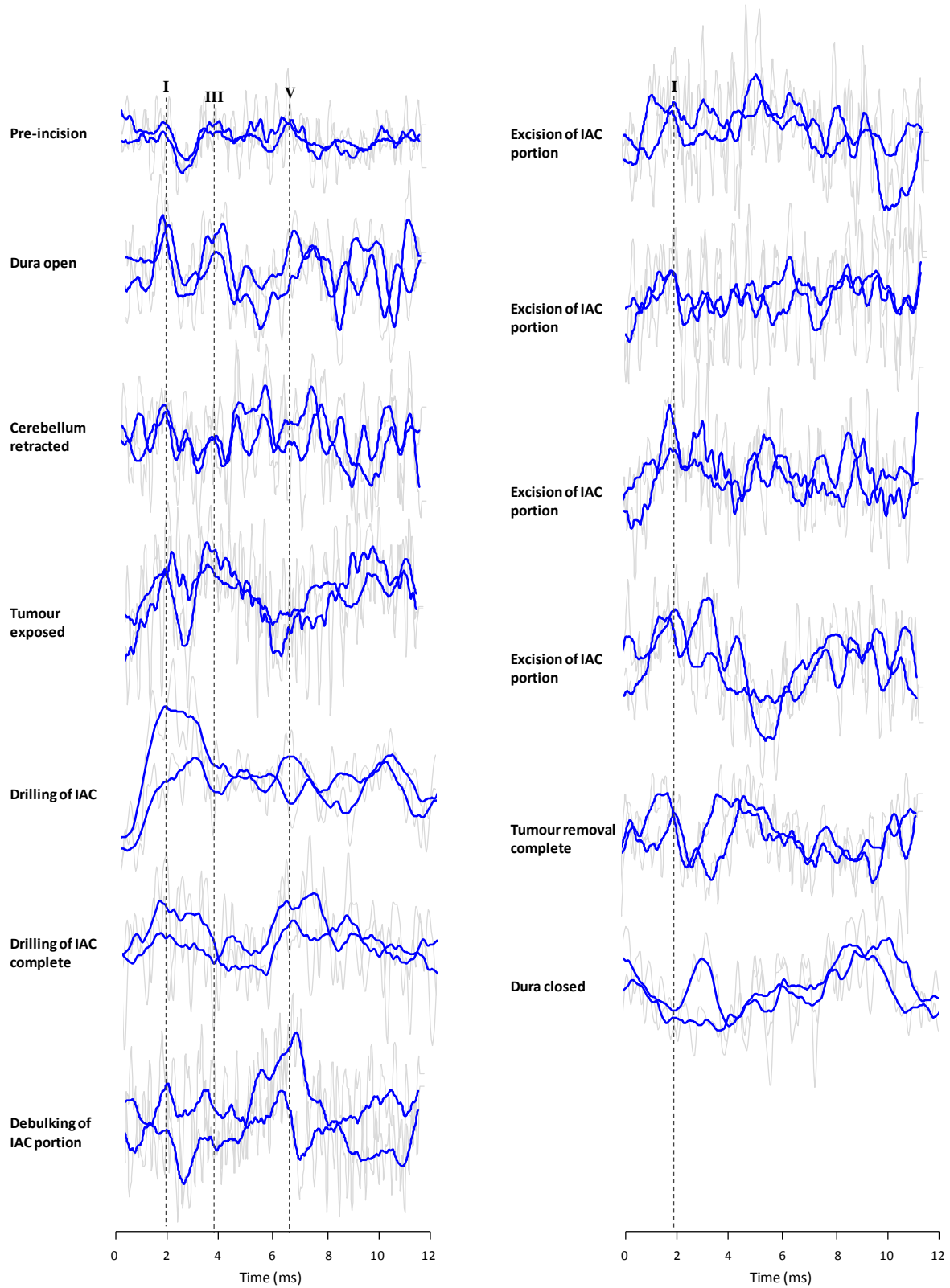


Figure 22. Case 16: ABR recorded from the ipsilateral ear at important points during vestibular schwannoma surgery. The blue traces show the waveforms following smoothing using a 21-point running average, and grey traces show the raw data.

3.3. Postoperative hearing preservation

Table 3 presents a summary of tumour characteristics and pre- and postoperative audiological data collected from the ipsilateral ear for the six participants for whom measurable pure-tone thresholds were documented postoperatively. Postoperative data is presented from the final assessment before the patient was discharged from hospital. Data presented include:

- i. Tumour size, given as the maximum diameter of the extracanalicular portion of the tumour;
- ii. PTA at 0.5, 1, 2 and 3 kHz (AAO-HNS, 1995);
- iii. WRS, defined as the maximum speech discrimination score at a presentation level up to 40 dB SL, or at the maximum comfort loudness level, whichever was less (AAO-HNS, 1995);
- iv. Hearing class according to the AAO-HNS guidelines (1995), based on the results given ii and iii;
- v. Tone decay test results - the sensation level of the tone required for the patient to maintain perception of a 1 kHz pure-tone for 60 seconds;
- vi. Presence or absence of DPOAEs at half-octave frequencies from 2-8 kHz;
- vii. ABR peak I and V latencies at 80 dB nHL, where present;
- viii. Whether anatomic preservation of the cochlear nerve was achieved;
- ix. The nerve from which the tumour originated, where identified by the surgeons; and
- x. Whether total tumour removal was accomplished.

As shown in Table 3, tumour size in this group ranged from 11-28 mm, with a mean tumour size of 17.7 mm ($SD = 8.5$ mm). The tumours of three patients were classified based on a preoperative MRI as small (0-14 mm) and three as medium (15-29 mm). All participants had type “A” tympanograms preoperatively, indicating normal middle ear pressure and compliance, and showed no evidence of middle ear effusion on postoperative otoscopy. Hearing was classified preoperatively according to the AAO-HNS (1995) guidelines as Class

A in two cases (Cases 8 and 17), Class B in two cases (Cases 5 and 13), and Class D (Cases 11 and 15) in two cases. As shown in Figure 23, postoperatively, Cases 11, 13, 15, and 17 maintained their preoperative class of hearing, whereas hearing class decreased in two patients: from Class B to Class D in Case 5, and from Class A to Class B in Case 8. The mean change in PTA in this group of patients was 17 dB HL (range = 5 – 42.5 dB HL) and the mean decrease in WRS was 25% (range = -1 - 68%).

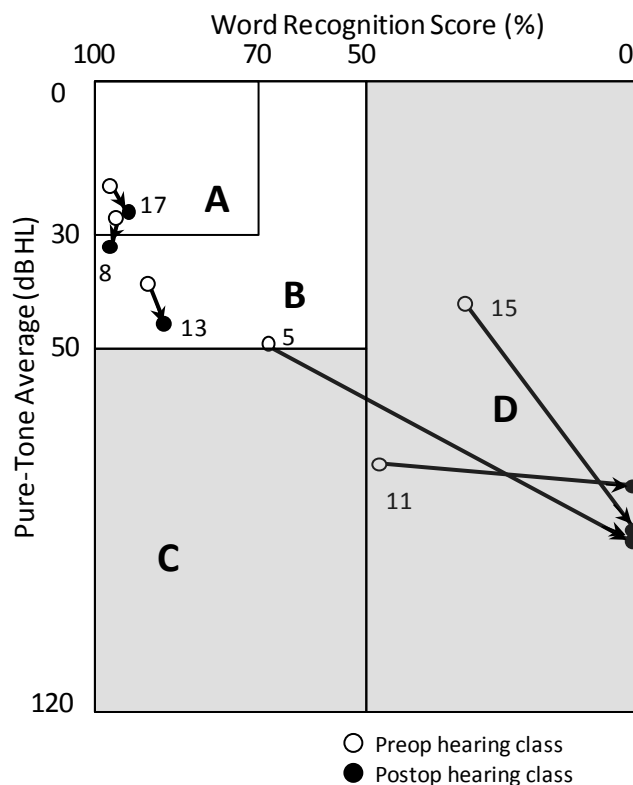


Figure 23. Change in PTA, WRS and AAO-HNS (1995) hearing classification from the pre- to postoperative period in the six patients in whom hearing was preserved. Preoperative hearing is indicated by the open circle and postoperative hearing is indicated by the closed circle.

The nerve from which the tumour originated was identified intraoperatively by the surgeons in four of the six cases, with three tumours originating from the SVN (Cases 8, 11 and 17) and one from the facial nerve (Case 15). As with the data from patients who experienced postoperative anacusis following the removal of a facial nerve schwannoma, Case 15 will be discussed together with the results of patients who retained measurable hearing following vestibular schwannoma removal.

Table 3. Summary of pre- and postoperative data for patients with measurable behavioural audiological responses following vestibular schwannoma removal.

Case	Preoperative							Surgery			Postoperative					
	Tumour size (mm)	PTA (dB HL)	WRS (%)	Hearing class	Tone decay (dB SL)	DPOAEs	ABR I ABR V (ms)	Cochlear nerve intact	Nerve of tumour origin	Complete tumour removal	PTA (dB HL)	WRS (%)	Hearing class	Tone decay (dB SL)	DPOAEs	ABR I ABR V (ms)
5	13	50.00	68	B	25 [^]	Absent	NR NR	Yes	?	Yes	87.50 ^a	0	D	> 40 [^]	Absent	NR NR
8	11	26.25	96	A	5	CNT	I = 1.88 V = 8.85	Yes	SVN	Yes	31.25	97	B	0	3-8 kHz	I = 1.95 V = 6.00
11	14	72.50	47	D	5	Absent	I = 1.30 NR	Yes	SVN	Yes	76.67 ^b	0	D	0	Absent	NR NR
13 ^{NF2}	34	38.75	90	B	0	2-8 kHz	I = 1.70 V = 5.80	Yes	?	No	46.25	87	B	5	2-8 kHz	I = 1.70 NR
15	20	42.50	31	D	CNT	Absent	NR NR	Yes	FN	No	85.00 ^c	0	D	CNT	Absent	NR NR
17	14	20.00	97	A	5	2-4 kHz	NR V = 6.88	Yes	SVN	Yes	25.00	94	A	5	2-4 kHz	NR V = 7.17

NF2 = Neurofibromatosis Type II

PTA = pure-tone average of 0.5, 1, 2 and 3 kHz

NR = no recordable response

CNT = could not test

WRS = maximum word recognition score

FN = facial nerve

SVN = superior vestibular nerve

IVN = inferior vestibular nerve

? = tumour nerve of origin could not be identified

^a No response above 1 kHz, PTA calculated based on average of the patient's thresholds at 0.5 and 1 kHz only

^b No response above 2 kHz, PTA based on average of 0.5, 1 and 2 kHz only

^c No response at 0.5, 2 and 3 kHz, PTA taken as the threshold at 1 kHz

[^]Significant tone decay

3.3.1. Postoperative preservation of behavioural and electrophysiological responses

Electrophysiological *and* behavioural evidence of functional preservation of the cochlea and cochlear nerve was documented postoperatively in Cases 8, 11, 13, and 17. Pre- and postoperative audiological data for all of these cases, and intraoperative ABR recordings from Cases 8 and 13, is presented in detail below.

Case 8

Figures 24 and 25 show the pre- and postoperative auditory responses of a 37-year old female who underwent excision of a small suspected vestibular schwannoma on the right side. The patient was referred for MRI following a slight decrease in hearing on the right side, unilateral tinnitus, and two brief episodes of right-sided facial numbness. The tumour had the following dimensions, as seen on MRI scans performed approximately six months prior to surgery: 11 mm in maximum oblique length from the anteromedial pole in the plane parallel to the face of the petrous bone; 9 mm in maximum transverse width from the medial pole as it just indented the cerebellum to the plane of the face of the petrous bone; and 10 mm in maximum oblique vertical height. The right IAC was slightly expanded in its medial half and the medial 40% was occupied by the tumour so that the length of the tumour in the IAC was 4 mm along the long axis of the IAC.

Preoperatively, the patient presented with a moderate U-shaped sensorineural hearing loss in the right ear, with thresholds within the range of normal hearing at 1 kHz and below, and 4 kHz and above, as shown in Figure 25A (PTA = 26.3 dB HL). Speech discrimination on the right side was well preserved, with a maximum word recognition score of 96% at a presentation level of 60 dB HL. Pure-tone thresholds measured for the left ear were within the normal range across the frequency range tested (PTA = 2.5 dB HL). Speech discrimination results were consistent with the pure-tone audiogram in the left ear (WRS = 100% at 40 dB HL). Tone decay testing did not provide evidence of retrocochlear pathology, with a presentation level of 5 dB SL required for the participant to maintain tone perception for 60 seconds. Preoperative DPOAE testing could not be completed in the ipsilateral ear due to high internal noise levels. Emissions were present in the contralateral ear at 2-8 kHz. ABR waves I, II, and III were replicable at normal latencies in both ears, with no interaural latency differences for these peaks. Wave V was slightly delayed in the right ear in relation to the

left, with an interaural latency difference of 0.35 ms, however the peak was present at a latency within the normal range for both ears (see Figure 24A and B) (Hall, 2006). Interaural interpeak latency differences were significant for waves III-V and I-V ($IT_{III-V} = 0.23$ ms and $IT_{I-V} = 0.22$ ms).

During surgery, complete tumour removal from the SVN with anatomical preservation of the cochlear nerve was accomplished. ABR was recorded intraoperatively at important points during surgery. The responses recorded are presented in Figure 26. The latency and morphology of wave I remained stable throughout the surgery, whereas the latencies of waves II-V increased, beginning from the time of the retraction of the cerebellum. The latencies of these waves continued to increase until the CPA portion of the tumour was completely removed. All waves then remained stable throughout drilling of the IAC and removal of the intracanalicular portion of the tumour.

The patient first underwent postoperative ABR testing in the ipsilateral ear approximately one hour following her return to the ward. ABR wave I was clear and reproducible at 80 and 90 dB nHL at latencies not significantly different (less than 0.2 ms) to those measured in preoperative testing (Figure 24A and B). Wave III was not identifiable at 80 dB nHL, but was present at 90 dB nHL at a latency of 4.65 ms, 0.55 ms delayed relative to the preoperative ABR. Wave V also increased in latency, by 0.40 ms at 80 dB nHL and 0.52 ms at 90 dB nHL. ABR testing was repeated on postoperative days 1-6, with the exception of day 5, on which the patient was unwilling to participate. ABR was not tested at 90 dB nHL after postoperative day 2, as the patient became more mobile and less tolerant of longer test sessions. Wave I of the ABR remained stable of the early postoperative period, whereas wave V fluctuated, before recovering to a latency only 0.15 ms longer than that measured preoperatively, on the day of hospitalisation. The final ABR (postoperative day 6) showed the following latency increases relative to the preoperative ABR: wave I = 0.07 ms, wave II = 0.23 ms, wave III = 0.35 ms, and wave V = 0.15 ms. Interaural interpeak latency differences also increased for waves I-V ($IT_{I-V} = 0.35$ ms) and I-III ($IT_{I-III} = 0.39$ ms), however the IT_{III-V} decreased to 0.04 ms. (DPOAEs were present at 3-8 kHz without fluctuation throughout hospitalisation.

The results of pure-tone audiometry assessments conducted on postoperative days 2-6 are shown in Figure 25A. Across these assessments the only significant change from the preoperative assessment was a threshold increase of 20 dB HL at 8 kHz in the right ear. No

significant changes in any thresholds across the frequency range tested were observed during the early postoperative period. The PTA increased from a preoperative level of 26.3 dB HL to 31.3 dB HL, shifting from a class A to a class B hearing classification. The presentation level of speech stimuli required to elicit a maximum word recognition score increased by 20 dB HL to 60 dB HL, however a speech discrimination score of 97% was found at this raised presentation level. Tone decay testing on postoperative day 6 remained a negative indicator for retrocochlear pathology, with a presentation level of 0 dB SL required for the maintenance of 60 seconds of tone perception. No significant changes were noted on any result from tests performed on the contralateral side during the early postoperative period.

Case 11

The data presented in Case 11 (Figures 27 and 28) was collected from a 62-year old male undergoing removal of a small suspected vestibular schwannoma from the right CPA. The patient was initially referred for otolaryngological assessment when an asymmetrical hearing loss was documented during an audiological assessment. As shown on MRI scans performed approximately seven months earlier, the tumour had the following dimensions: 14 mm in maximum oblique length from the anteromedial pole in the CPA to the posterolateral pole, in a plane parallel to the face of the petrous bone; 11 mm in maximum oblique width from the medial pole as it rested on the surface of the cerebellum to the plane of the face of the petrous bone; and 10 mm in maximum vertical height. The right IAC was slightly expanded, the medial two thirds being occupied by tumour.

As shown in Figure 28, preoperative pure-tone audiometry in Case 11 showed a moderate sloping to profound sensorineural hearing loss in the right ear (PTA = 72.5 dB HL). No thresholds were present above 4 kHz at the limits of the audiometer. Speech discrimination in the right ear was significantly poorer than would be predicted on the basis of the pure-tone audiogram, with a maximum speech discrimination score of 47% at presentation level of 85 dB HL. The left ear showed a mild sloping to severe sensorineural hearing loss (PTA = 41.3 dB HL), and speech discrimination consistent with this pure-tone audiogram (WRS = 97% at 60 dB HL). Tone decay testing did not provide evidence of retrocochlear pathology, with a presentation level of 5 dB SL required for the participant to maintain tone perception for 60 seconds in the ear ipsilateral to the tumour. DPOAE testing showed absent emissions at 2-8

kHz bilaterally. ABR testing in the right ear showed a repeatable wave I at normal latencies (1.30 ms and 1.35 ms at 80 and 90 dB nHL respectively) and wave III (4.15 ms) at a stimulus presentation level of 90 dB nHL only. It should be noted wave I increased in latency with increased stimulus intensity, rather than showing the expected decrease in absolute latency. Wave V could not be identified at either presentation level. In the contralateral ear wave I was absent, wave III was present at a latency within the normal range (4.13 ms) and wave V was present at slightly delayed latency of 6.20 ms. Interaural interpeak latency differences were not calculated in this case as ipsilateral and contralateral ABR were obtained with different stimulus intensities.

Complete tumour removal from the SVN was achieved during surgery, with anatomical preservation of the cochlear nerve. The patient was not available for testing on postoperative day 0, therefore the first postoperative ABR assessment was conducted 24 hours after surgery, on postoperative day 1. No reproducible ABR waveforms were identified in the right ear on postoperative days 0 to 4 postoperatively. However, on postoperative day 5 wave III was present at a normal latency of 3.70 ms at 80 dB nHL, and waves III and V were present at 90 dB nHL at latencies of 3.50 and 6.02 ms respectively. ABR in the contralateral ear fluctuated in terms of the clarity and reproducibility of the waveforms, however, as shown in Figures 27A and B, the latencies of waves were essentially unchanged. No DPOAEs could be obtained in either ear postoperatively. Pure-tone audiometry was performed on postoperative days 1-5 and fluctuated only at 0.5 kHz over these test sessions. On each occasion the patient presented with a severe to profound hearing loss in the right ear, with no measurable hearing beyond 2 kHz. The threshold at 0.5 kHz was 85 dB HL on postoperative day 1 and improved to 70 dB HL on postoperative day 5. Speech discrimination testing documented absent discrimination abilities at a maximum presentation level of 100 dB HL. Tone decay testing on postoperative day 5 remained a negative indicator for retrocochlear pathology, with a presentation level of 0 dB SL required for the maintenance of 60 seconds of tone perception. No significant changes were noted on any result from tests performed on the contralateral side during the early postoperative period.

Case 13

Case 13 documents the pre- and postoperative auditory responses of a 22- year old male with NF2. A diagnosis of NF2 was made approximately 15 months prior to the patient's participation in this study, following referral for an MRI to investigate an asymmetry in hearing. This participant had undergone subtotal removal of the right vestibular schwannoma approximately 12 months earlier, and participated in the present study during his hospitalisation for subtotal removal of the left vestibular schwannoma. MRI scans taken the day prior to surgery showed that the tumour in the left CPA had two probable components to it, the smaller occupying the markedly expanded IAC and extending medially and slightly anteriorly, the larger superimposed over the posterior and superior aspects of the slightly smaller tumour. As shown on the MRI, the total dimensions of these two tumours together were 34 mm from the anteromedial pole to the posterolateral pole in a plane parallel to the face of the petrous bone; 28 mm from the medial pole as it indented upon the cerebellum to the plane of the face of the petrous bone; and 26 mm in maximum vertical height.

Figures 29 and 30 show the pre- and postoperative behavioural and electrophysiological data collected for Case 13. Preoperatively, a mild, flat sensorineural hearing loss was documented in the left ear (PTA = 38.8 dB HL) (see Figure 30 A). Speech discrimination in the ear was concordant with the pure-tone audiogram (WRS = 90% at 60 dB nHL). The right ear showed a U-shaped sensorineural hearing loss; mild in the low frequencies, falling to 70 dB HL at 1.5 kHz, rising to mild again by 6 kHz, before steeply falling to 95 dB HL at 8 kHz (PTA = 48.8 dB HL). Speech discrimination testing in the right ear showed a maximum of score of 88% at a presentation level of 60 dB HL, however discrimination was degraded at presentation levels above this, falling to 70% at 80 dB HL. Tone decay was negative for retrocochlear pathology in both ears, with perception of the tone maintained for 60 seconds at a presentation level of 0 dB SL bilaterally. Preoperative ABR, as presented in Figure 29 A and B, showed clear and reproducible waves I, III, and V at normal latencies at 80 dB nHL in the left ear. In the right ear waves I and III were present at normal latencies, with no significant interaural latency or interaural interpeak latency differences ($IT_{I-III} = 0.15$ ms), while wave V was absent. DPOAEs were present and robust at 2-8 kHz bilaterally.

During surgery, sufficient of the larger tumour of the tumour complex was removed to achieve adequate decompression of the cranial nerves and the cerebellum. No tumour removal was attempted from within the IAC. ABR recorded intraoperatively (Figure 31)

documented the presence of wave I without any change in latency or morphology, throughout the surgery. Wave V was not identifiable at any point during surgery following opening of the skull. Wave III was present throughout the surgery up until the point when tumour debulking was complete. No waves beyond wave I were reproducible upon closure of the dura.

Daily postoperative assessments could not be completed for this participant, due to his rapid discharge and subsequent unavailability for testing. ABR wave I was maintained throughout the early postoperative period at unchanged latencies relative to the preoperative assessment, however no waves beyond wave I were reproducible at any stage postoperatively (see Figure 29A and B). No changes were observed in DPOAEs, with emissions preserved at 2-8 kHz postoperatively. Postoperative pure-tone testing revealed no change in pure-tone thresholds across the frequency range tested at any stage during the early postoperative period. Speech discrimination was also preserved at preoperative levels. Postoperative tone decay testing, conducted on postoperative day 4, remained negative for retrocochlear pathology, with 60 seconds of tone perception maintained at a presentation level of 5 dB SL in the left ear. No significant changes were noted on any result from tests performed on the contralateral side during the early postoperative period.

Case 17

The data documented in Case 17 was collected from a 61-year old female admitted for removal of a small suspected vestibular schwannoma on the left side. The presenting symptoms in this case were unilateral tinnitus and aural fullness. MRI scans two months preoperatively showed a tumour of the following dimensions: 13 mm in maximum oblique length from the anteromedial pole to the posterolateral pole in a plane parallel to the face of the petrous bone; 14 mm in maximum oblique width from the medial pole as it indented the cerebellum/pons junction to the plane of the face of the petrous bone; and 12 mm in maximum vertical height. The left IAC was slightly enlarged due to the tumour filling the medial 50% of the IAC.

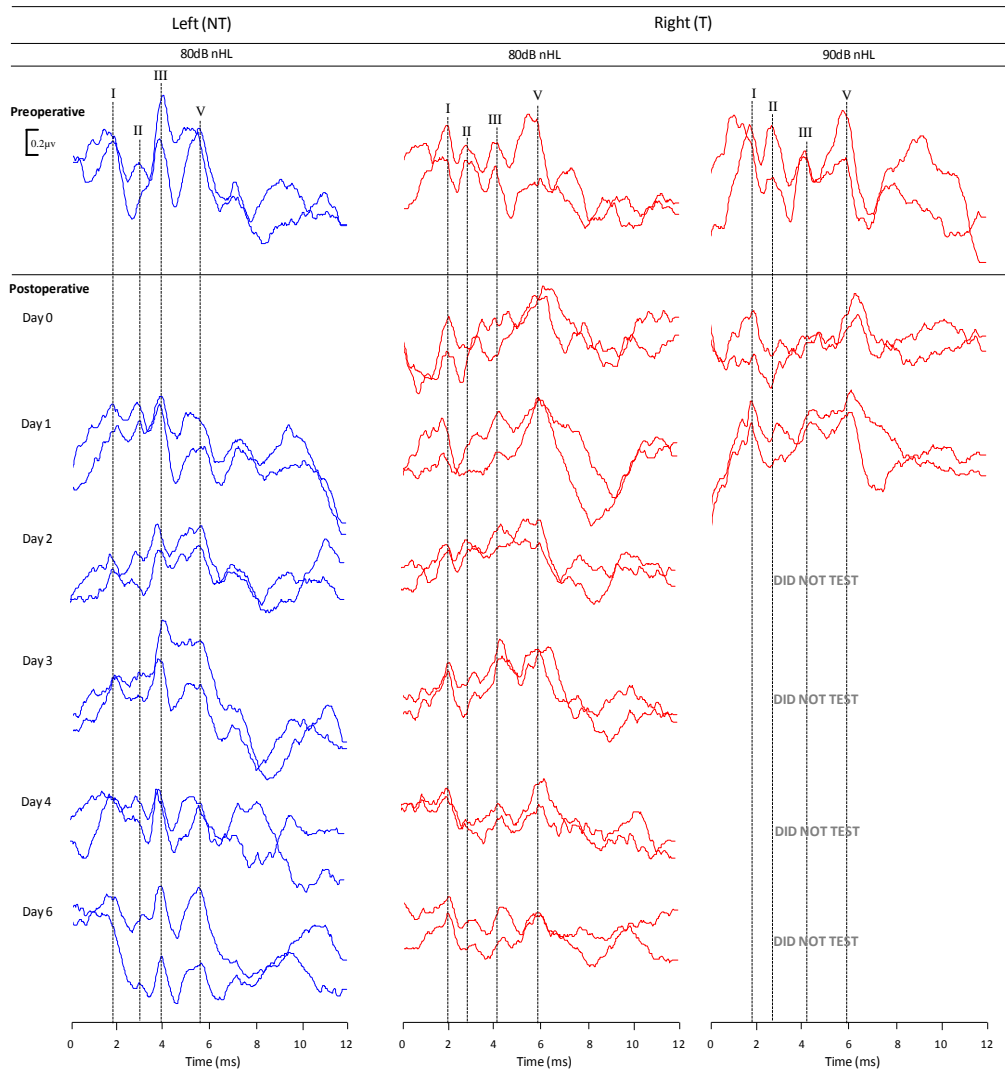
The preoperative assessment for this patient, as shown in Figures 32 and 33, showed a mild, high-frequency sensorineural hearing loss in the left ear (ipsilateral to the tumour) (PTA = 20.0 dB HL). Speech discrimination in the left ear was consistent with the pure-tone

audiogram (WRS = 97% at 50 dB HL). The right ear also showed a mild high-frequency sensorineural hearing loss, with a slightly lower PTA relative to the left ear of 7.50 dB HL. Speech discrimination was in the right ear was also consistent with the pure-tone audiogram (WRS = 97% at 25 dB HL). Tone decay was negative for retrocochlear pathology in both ears, with perception of the tone maintained for 60 seconds at a presentation level of 0 dB SL in the right ear, and at 5 dB SL in the left ear. ABR testing at 80 dB nHL showed that only wave V was reproducible at a delayed latency of 6.88 ms, 1.41 ms later than wave V in the contralateral ear. The presentation level was increased to 90 dB nHL, at which wave V was further delayed, at a latency of 6.97 ms. Wave I was evident at a stimulus presentation level of 90 dB nHL, at a normal latency of 1.88 ms. ABR waves I, III, and V were present at normal latencies in the right ear preoperatively. DPOAE testing revealed present emissions at 2-4 kHz in the left ear and at 2-6 kHz in the right ear.

Total removal of the patient's tumour from the left SVN was achieved with anatomical preservation of the cochlear nerve. Ipsilateral ABR measurements were made two hours following the patient's return to the neurosurgery ward and are presented in Figure 32A and B. The presence of wave V at both 80 and 90 dB nHL was observed in this test session, with a latency increase compared to the preoperative responses of 1.27 ms and 1.08 ms at 80 and 90 dB nHL respectively. Waves I and III were not identifiable. ABR was repeated at 24-hour intervals for the remainder of the participant's hospitalisation (discharged on postoperative day 6). Over this period the latency of wave V gradually decreased to 7.17 ms at the final test session, at both 80 and 90 dB nHL. From postoperative day 2 forward, wave III was also evident. Over postoperative test sessions on days 2 to 6, the latency of this wave gradually decreased from 5.72 ms to 5.42 ms at 80 dB nHL and 5.70 ms to 5.47 ms at 90 dB nHL (see Figure 32A and B). No changes were observed in DPOAEs, with emissions preserved throughout the early postoperative period at 2-4 kHz. Postoperative pure-tone testing revealed no significant changes in pure-tone thresholds from preoperative levels across the frequency range tested at any stage during the early postoperative period. The postoperative PTA, based on the final audiogram produced during hospitalisation, was 25.0 dB HL, 5 dB HL greater than the preoperative PTA. Speech discrimination was also preserved at preoperative levels (WRS = 94% at 50 dB HL), therefore in this case the preoperative hearing classification of class A was maintained. Postoperative tone decay testing, conducted on postoperative day 6, remained negative for retrocochlear pathology, with 60 seconds of tone perception maintained at a presentation level of 5 dB SL in the left ear. No significant changes were

noted on any result from tests performed on the contralateral side during the early postoperative period.

A.



B.

Contralateral (left) peak latencies (ms)

Day	I	II	III	IV	V
Preop	1.75	2.90	3.88	-	5.50
Postop 0	Could not test				
Postop 1	1.80	2.85	3.85	-	5.69
Postop 2	1.79	2.83	3.80	-	5.72
Postop 3	1.82	-	3.78	-	5.67
Postop 4	1.74	2.85	3.80	-	5.65
Postop 6	1.77	2.92	3.81	-	5.58

Ipsilateral (right) peak latencies (ms)

Day	80 dB nHL					90 dB nHL				
	I	II	III	IV	V	I	II	III	IV	V
Preop	1.88	2.85	4.00	-	5.85	1.72	2.73	4.10	-	5.90
Postop 0	1.92	-	-	-	6.25	1.85	-	4.65	-	6.42
Postop 1	1.70	-	4.28	-	6.13	1.77	2.88	4.47	-	6.10
Postop 2	1.92	2.92	4.35	-	6.08	Did not test				
Postop 3	2.00	3.10	4.33	-	6.19	Did not test				
Postop 4	1.97	-	4.34	-	6.15	Did not test				
Postop 6	1.95	3.08	4.35	-	6.00	Did not test				

C.

Contralateral (left) DPOAEs

Day	f_2 frequency (Hz)				
	2000	3000	4000	6000	8000
Preop	+	+	+	+	+
Postop 1	+	+	+	+	+
Postop 2	+	+	+	+	+
Postop 3	+	+	+	+	+
Postop 4	+	+	+	+	+
Postop 6	+	+	+	+	+

Ipsilateral (right) DPOAEs

Day	f_2 frequency (Hz)				
	2000	3000	4000	6000	8000
Preop	Could not test				
Postop 1	-	+	+	+	+
Postop 2	-	+	+	+	+
Postop 3	-	+	+	+	+
Postop 4	-	+	+	+	+
Postop 6	-	+	+	+	+

Figure 24. Case 8: Electrophysiological auditory responses collected before and after vestibular schwannoma surgery. Part A shows a time-ordered sequence of click-evoked ABR traces from the left and right ears; with the latencies of waves present in these traces shown in part B. Part C shows the serial DPOAE data collected pre- and postoperatively; + indicates present DPOAEs and – indicates their absence.

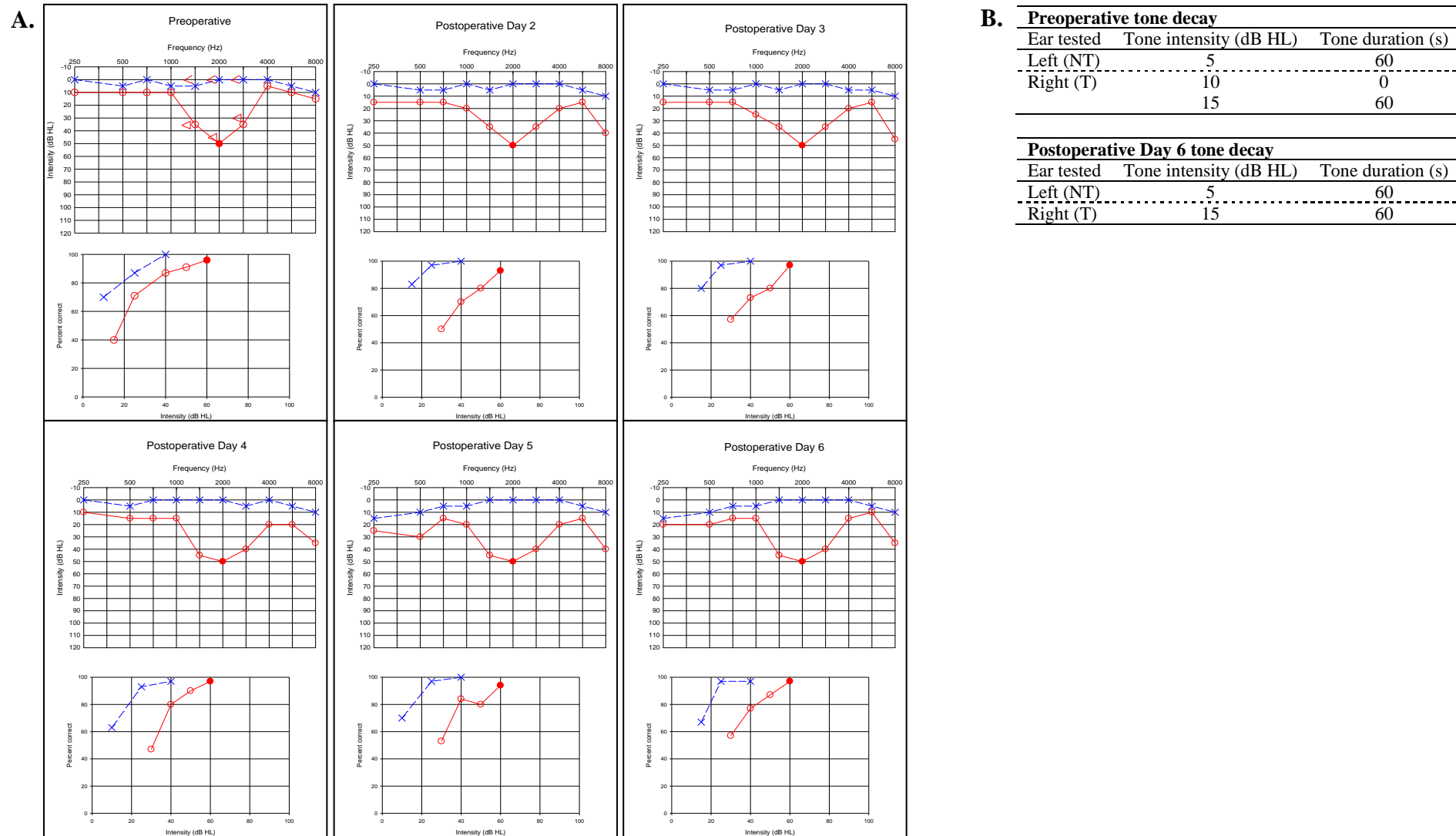


Figure 25. Case 8: Behavioural audiological data collected before and after vestibular schwannoma removal. Results of pure-tone and speech audiometry are shown in Part A. The right and left ear are shown by circles and crosses respectively (filled circles and double crosses indicate the use of contralateral masking). Part B shows the duration of tone perception at each intensity level presented in tone decay testing.

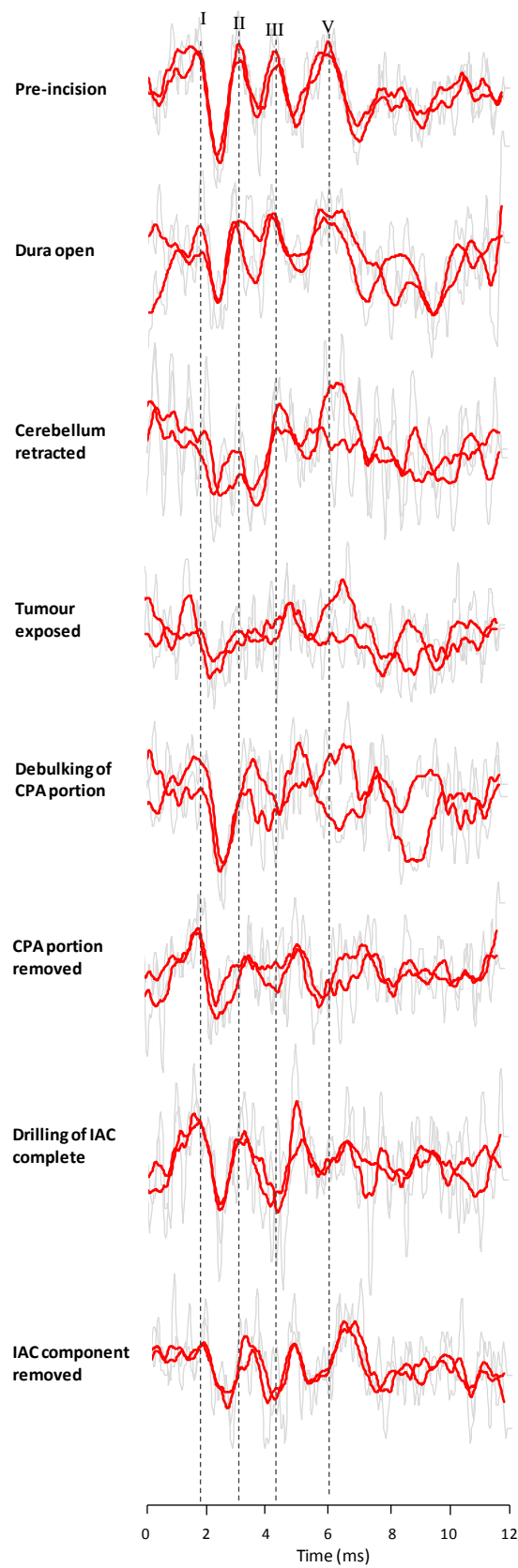
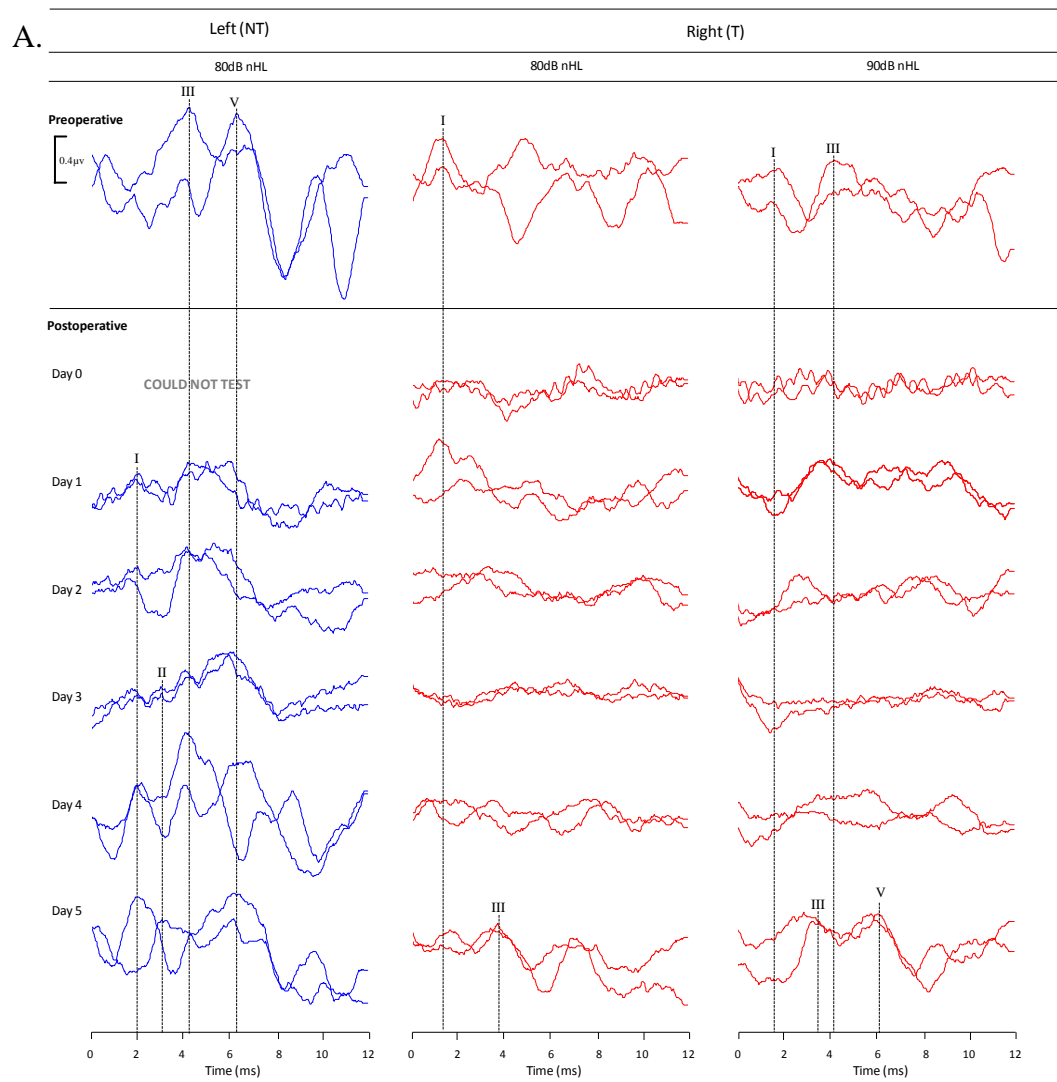


Figure 26. Case 8: ABR recorded from the ipsilateral ear at important points during vestibular schwannoma surgery. The red traces show the waveforms following smoothing using a 21-point running average, and grey traces show the raw data.



B. Contralateral (left) peak latencies (ms)

Day	I	II	III	IV	V
Preop	-	-	4.13	-	6.20
Postop 0	Could not test				
Postop 1	1.90	-	4.25	-	6.07
Postop 2	1.93	-	4.13	-	5.97
Postop 3	1.88	3.02	4.11	-	6.05
Postop 4	1.92	-	4.08	-	-
Postop 5	-	-	4.22	-	6.17

Ipsilateral (right) peak latencies (ms)

Day	80 dB nHL					90 dB nHL				
	I	II	III	IV	V	I	II	III	IV	V
Preop	1.30	-	-	-	-	1.35	-	4.15	-	-
Postop 0	No identifiable peaks					No identifiable peaks				
Postop 1	No identifiable peaks					No identifiable peaks				
Postop 2	No identifiable peaks					No identifiable peaks				
Postop 3	No identifiable peaks					No identifiable peaks				
Postop 4	No identifiable peaks					No identifiable peaks				
Postop 5	-	-	3.70	-	-	-	-	3.50	-	6.03

C. Contralateral (left) DPOAEs

Day	f_2 frequency (Hz)				
	2000	3000	4000	6000	8000
Preop	-	-	-	-	-
Postop 0	-	-	-	-	-
Postop 1	-	-	-	-	-
Postop 2	-	-	-	-	-
Postop 3	-	-	-	-	-
Postop 4	-	-	-	-	-
Postop 5	-	-	-	-	-

Ipsilateral (right) DPOAEs

Day	f_2 frequency (Hz)				
	2000	3000	4000	6000	8000
Preop	-	-	-	-	-
Postop 0	-	-	-	-	-
Postop 1	-	-	-	-	-
Postop 2	-	-	-	-	-
Postop 3	-	-	-	-	-
Postop 4	-	-	-	-	-
Postop 5	-	-	-	-	-

Figure 27. Case 11: Electrophysiological auditory responses collected before and after vestibular schwannoma surgery. Part A shows a time-ordered sequence of click-evoked ABR traces from the left and right ears; with the latencies of waves present in these traces shown in part B. Part C shows the serial DPOAE data collected pre- and postoperatively; + indicates present DPOAEs and – indicates their absence.

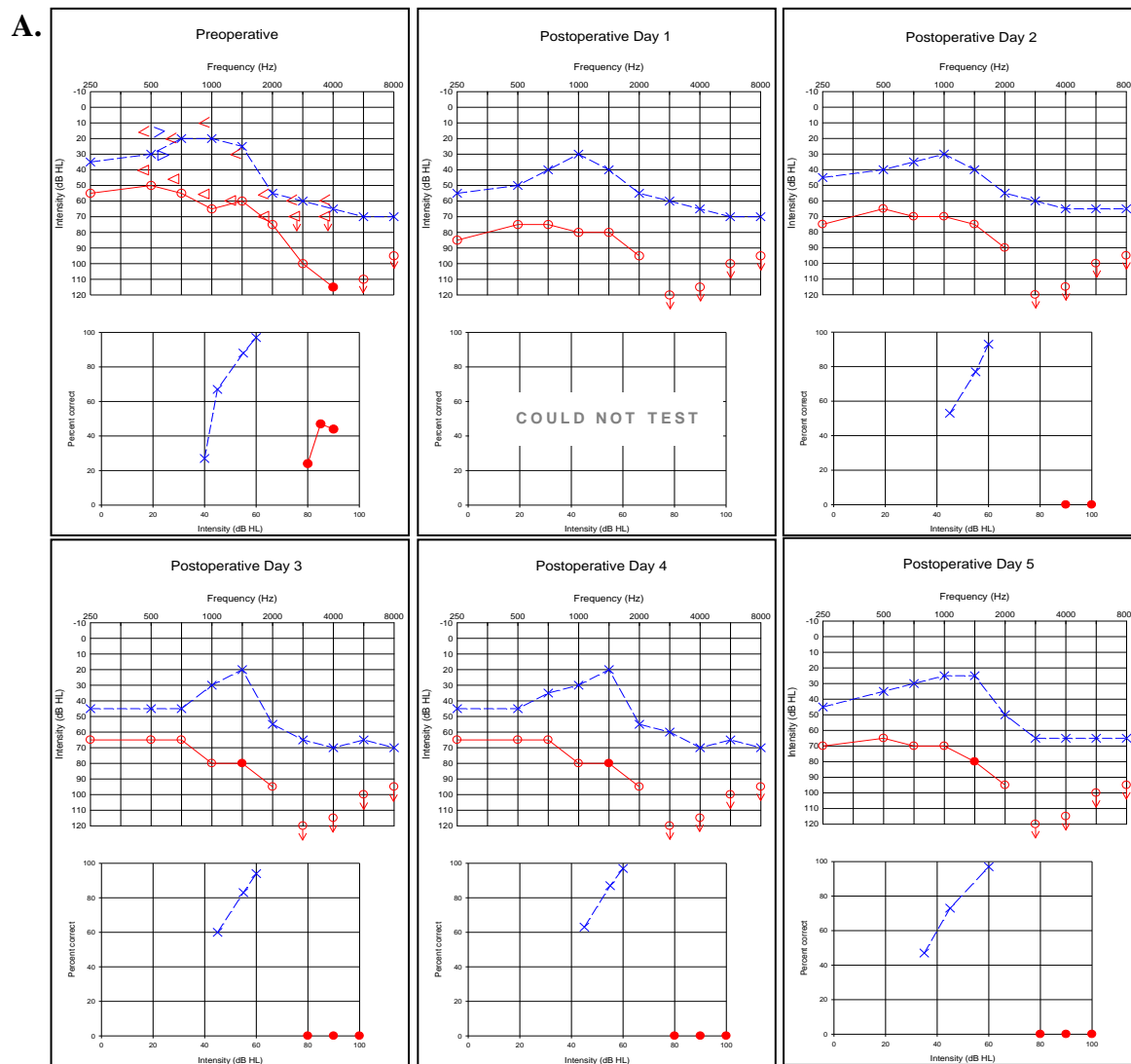


Figure 28. Case11: Behavioural audiological data collected before and after vestibular schwannoma removal. Results of pure-tone and speech audiometry are shown in Part A. The right and left ear are shown by circles and crosses respectively (filled circles and double crosses indicate the use of contralateral masking). Part B shows the duration of tone perception at each intensity level presented in tone decay testing pre- and postoperatively.

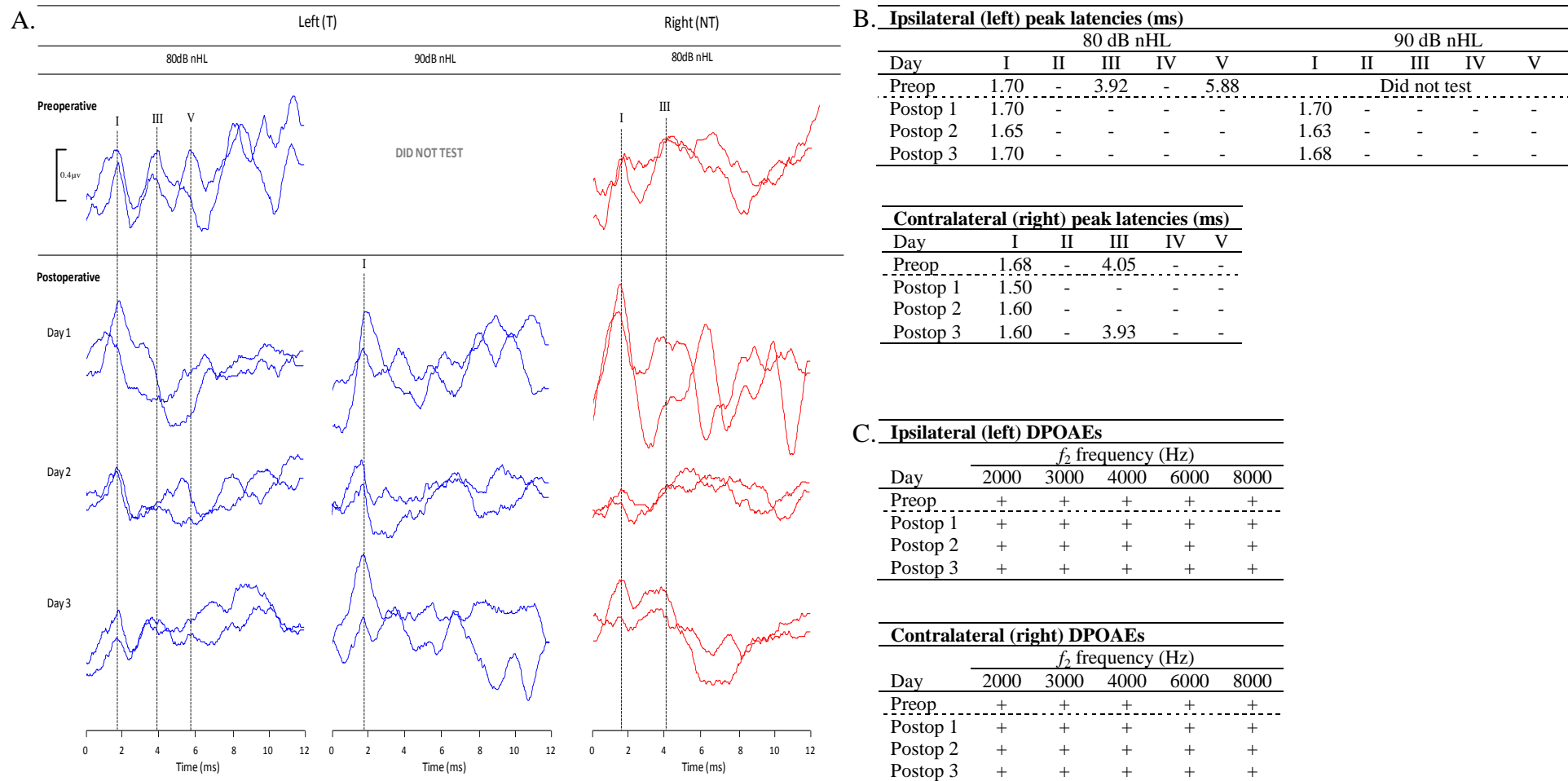
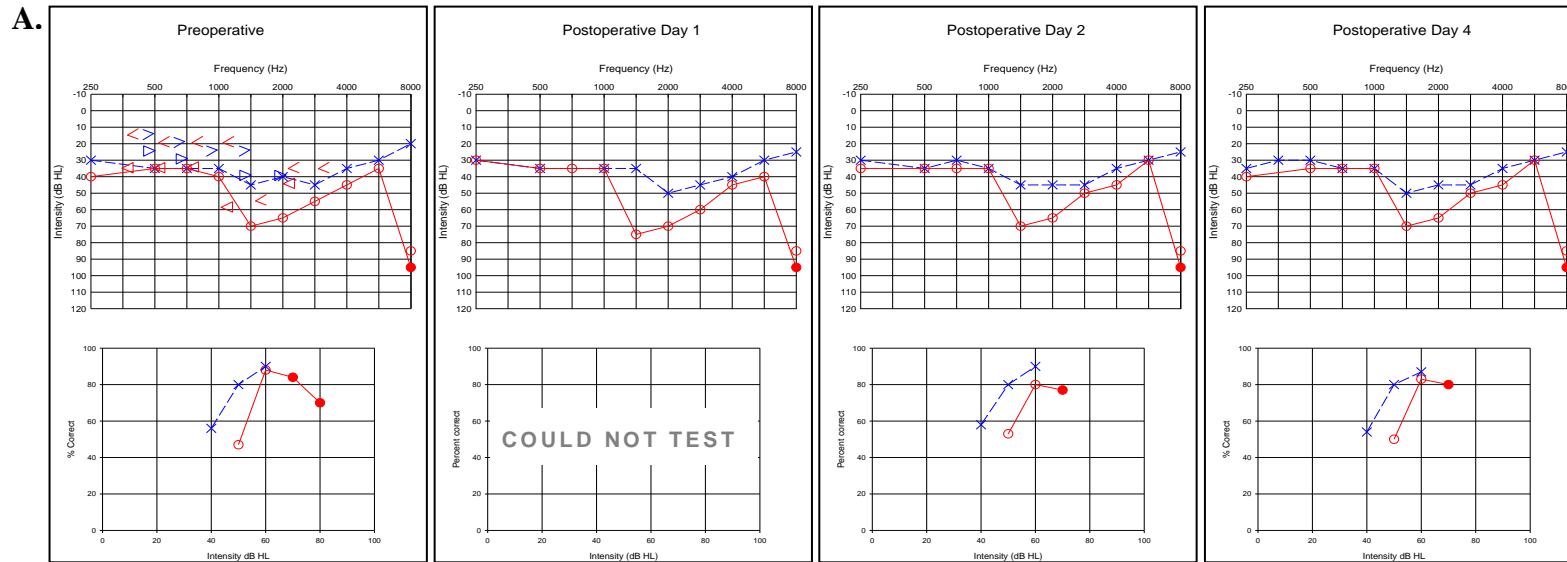


Figure 29. Case 13: Electrophysiological auditory responses collected before and after vestibular schwannoma surgery. Part A shows a time-ordered sequence of click-evoked ABR traces from the left and right ears; with the latencies of waves present in these traces shown in part B. Part C shows the serial DPOAE data collected pre- and postoperatively; + indicates present DPOAEs and – indicates their absence.



B. Preoperative tone decay

Ear tested	Tone intensity (dB HL)	Tone duration (s)
Left (T)	40	60
Right (NT)	35	60

Postoperative Day 4 tone decay

Ear tested	Tone intensity (dB HL)	Tone duration (s)
Left (T)	35	0
	40	60
Right (NT)	40	60

Figure 30. Case 13: Behavioural audiological data collected before and after vestibular schwannoma removal. Results of pure-tone and speech audiometry are shown in Part A. The right and left ear are shown by circles and crosses respectively (filled circles and double crosses indicate the use of contralateral masking). Part B shows the duration of tone perception at each intensity level presented in tone decay testing.

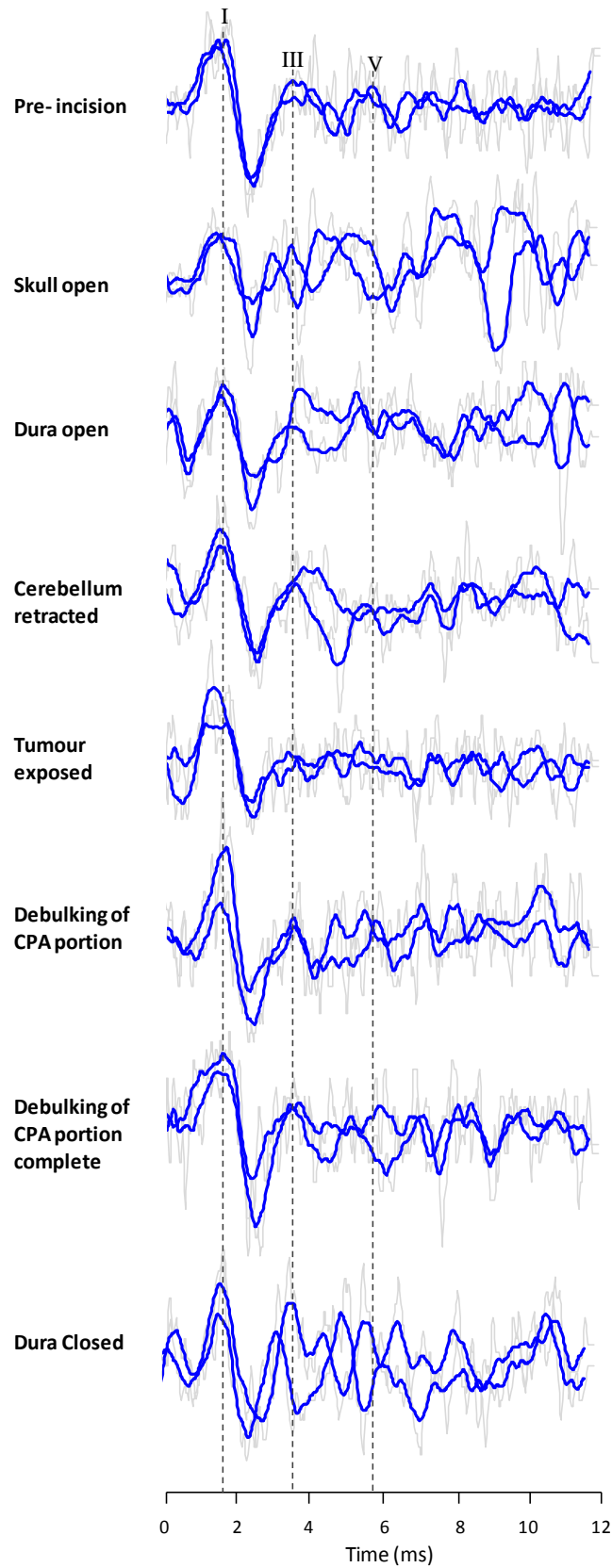
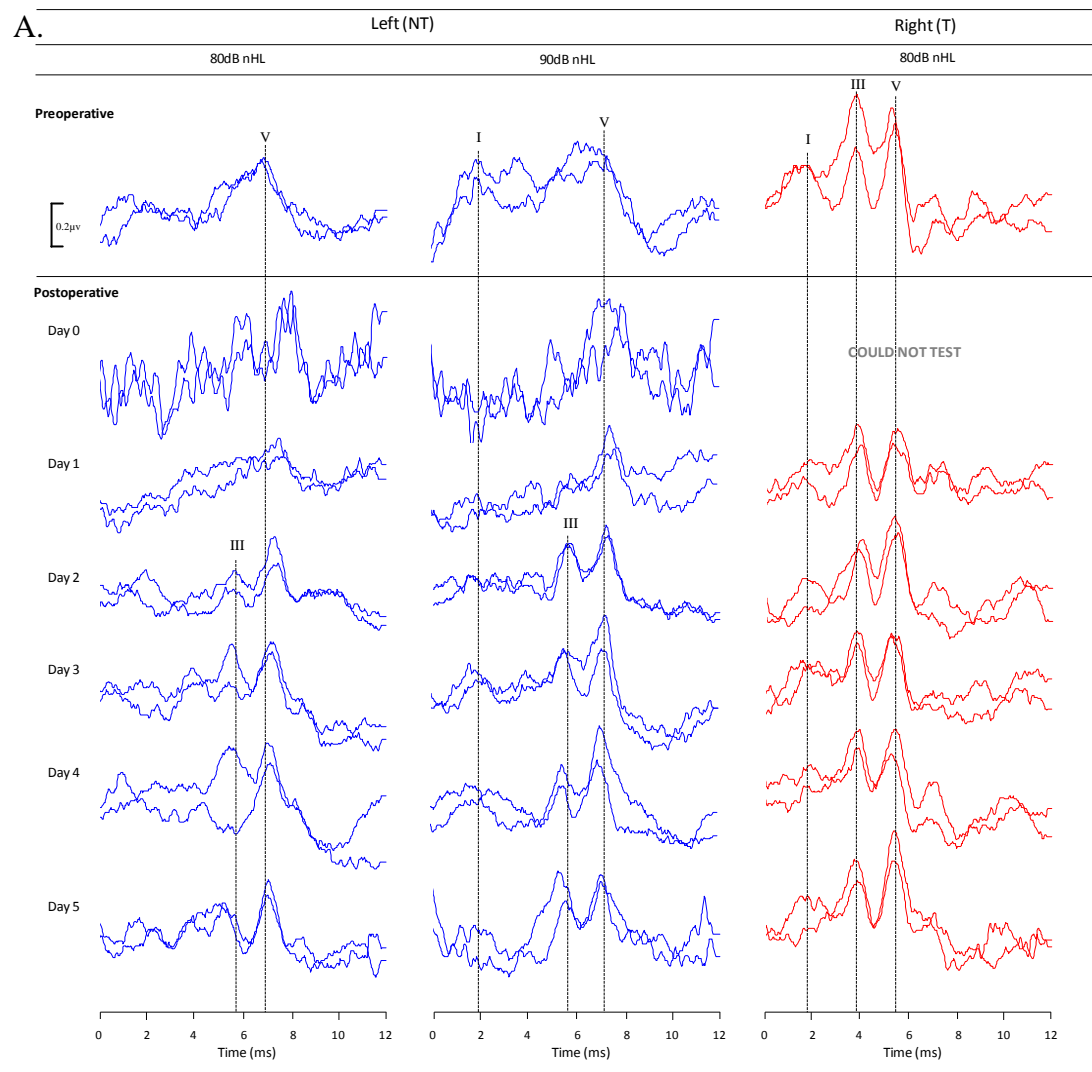


Figure 31. Case 13: ABR recorded from the ipsilateral ear at important points during vestibular schwannoma surgery. The blue traces show the waveforms following smoothing using a 21-point running average, and grey traces show the raw data.



B. Ipsilateral (left) peak latencies (ms)

Day	80 dB nHL				90 dB nHL					
	I	II	III	IV	V	I	II	III	IV	V
Preop	-	-	-	-	6.88	1.88	-	-	-	6.97
Postop 0	-	-	-	-	8.15	-	-	-	-	8.05
Postop 1	-	-	-	-	7.83	-	-	-	-	7.72
Postop 2	-	-	5.72	-	7.45	-	-	5.70	-	7.35
Postop 3	-	-	5.58	-	7.38	-	-	5.58	-	7.28
Postop 4	-	-	5.55	-	7.25	-	-	5.50	-	7.22
Postop 5	-	-	5.42	-	7.17	-	-	5.47	-	7.17

Contralateral (right) peak latencies (ms)

Day	I	II	III	IV	V
Preop	1.70	-	3.92	-	5.47
Postop 0	Could not test				
Postop 1	1.75	-	3.92	-	5.53
Postop 2	1.65	-	3.98	-	5.51
Postop 3	1.57	-	3.92	-	5.55
Postop 4	1.63	-	3.95	-	5.57
Postop 5	1.65	-	3.87	-	5.53

C. Ipsilateral (left) DPOAEs

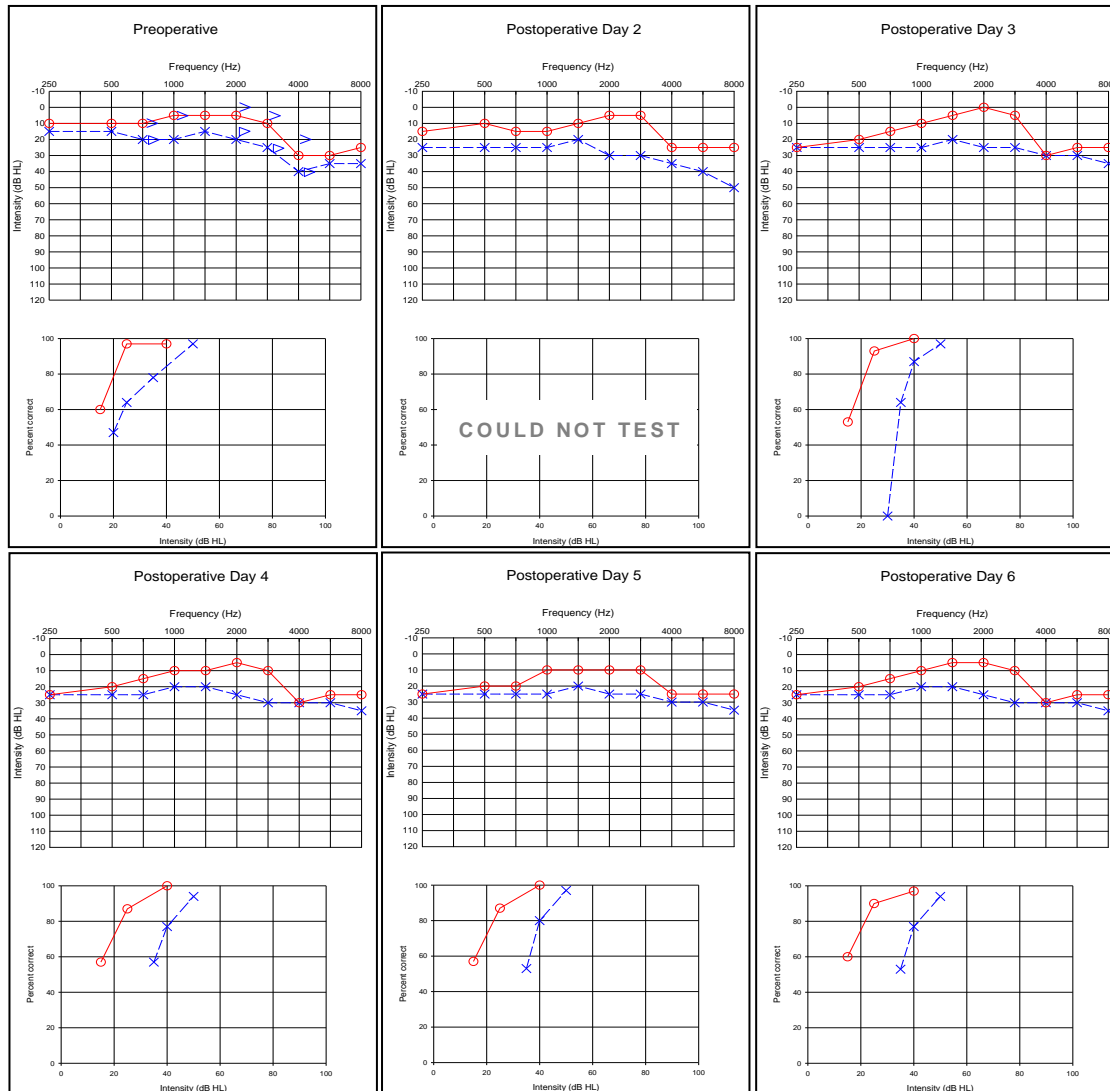
Day	f_2 frequency (Hz)				
	2000	3000	4000	6000	8000
Preop	+	+	+	-	-
Postop 0	+	+	+	-	-
Postop 1	+	+	+	-	-
Postop 2	+	+	+	-	-
Postop 3	+	+	+	-	-
Postop 4	+	+	+	-	-
Postop 5	+	+	+	-	-

Contralateral (right) DPOAEs

Day	f_2 frequency (Hz)				
	2000	3000	4000	6000	8000
Preop	+	+	+	+	-
Postop 0	Could not test				
Postop 1	+	+	+	+	-
Postop 2	+	+	+	+	-
Postop 3	+	+	+	+	-
Postop 4	+	+	+	+	-
Postop 5	+	+	+	+	-

Figure 32. Case 17: Electrophysiological auditory responses collected before and after vestibular schwannoma surgery. Part A shows a time-ordered sequence of click-evoked ABR traces from the left and right ears; with the latencies of waves present in these traces shown in part B. Part C shows the serial DPOAE data collected pre- and postoperatively; + indicates present DPOAEs and – indicates their absence.

A.



B.

Preoperative tone decay		
Ear tested	Tone intensity (dB HL)	Tone duration (s)
Left (T)	10	60
Right (NT)	20	0
	25	60

Postoperative Day 6 tone decay		
Ear tested	Tone intensity (dB HL)	Tone duration (s)
Left (T)	5	60
Right (NT)	20	0
	25	60

Figure 33. Case 17: Behavioural audiological data collected before and after vestibular schwannoma removal. Results of pure-tone and speech audiometry are shown in Part A. The right and left ear are shown by circles and crosses respectively (filled circles and double crosses indicate the use of contralateral masking). Part B shows the duration of tone perception at each intensity level presented in tone decay testing.

3.3.2. Postoperative hearing preservation with loss of electrophysiological responses

In two of the six cases in which pure-tone thresholds were measurable postoperatively, residual hearing was limited and no replicable electrophysiological responses were present. The participant in Case 5 presented with a mild sloping to severe sensorineural hearing loss preoperatively (PTA = 50 dB HL) and experienced a loss of measurable hearing below 0.5 kHz and above 1 kHz postoperatively. Postoperative thresholds at 0.5 and 1 kHz provided a postoperative PTA of 87.50 dB HL. A similar functional decrease was seen speech discrimination, from a maximum of 68% at a presentation level of 80 dB nHL preoperatively, to a complete absence of speech discrimination abilities on the ipsilateral side postoperatively. DPOAEs at 2-8 kHz and any reproducible ABR waves were absent on the ipsilateral side both pre- and postoperatively. In Case 15, hearing was classified as class D and no electrophysiological responses were present on the ipsilateral side either pre- or postoperatively. In this case, subtotal removal of the patient's facial nerve schwannoma was performed to debulk the tumour to reduce compression and preserve the facial nerve while minimising the trauma associated with complete tumour removal in this older patient. Complete pre- and postoperative audiological data for Cases 5 and 15 are presented in Appendix B.

4. DISCUSSION

In the present study, detailed pre- and postoperative audiological monitoring was performed in a series of 19 consecutive patients undergoing retrosigmoid removal of a suspected vestibular schwannoma in order to identify and more clearly define the phenomenon of early postoperative delayed hearing loss. We aimed to use this data to isolate the likely site of impairment resulting in delayed hearing loss, and thus determine the pathophysiological mechanism responsible for such loss. Ultimately, the development of methods of preventing delayed hearing loss from occurring in the future is dependent on identifying the putative mechanism responsible for this pattern of loss. From the series of 19 patients monitored, measurable hearing was present postoperatively in six, and immediate anacusis in the ear ipsilateral to the tumour was documented in the remaining 13 cases. In one of the 13 cases of postoperative anacusis, a pattern of ABR degeneration was observed that was similar to that described by Strauss et al. (1991) in cases of delayed hearing loss. This case and the possible causes of this deterioration of cochlear nerve function will be discussed in detail.

Early postoperative delayed hearing loss, defined in previous studies as a loss of behavioural responses to auditory stimuli in the early postoperative period (Fahlbusch et al., 1998; Neu et al., 1999; Strauss et al., 2001; Strauss et al., 1991), was not observed in our series of patients. The largest series in which early postoperative delayed hearing loss is documented is that of Neu and colleagues (1999), who report a rate of delayed hearing loss of 16% in their 70 patients. Strauss et al. (1991) and Fahlbusch et al. (1998) report slightly higher rates of delayed hearing loss of 24% (7/29) and 18% (11/61) respectively. Using the more conservative incidence of 16% reported by Neu et al. (1999), three cases of delayed hearing loss would be predicted to occur in our group of 19 patients. However, a major difference between the present study and those reported in the literature exists in the criteria for attempted hearing preservation and therefore inclusion in the study. Neu et al. (1999) included only patients that demonstrated measurable pure-tone thresholds and reproducible ABR wave I and/or V preoperatively. The application of these inclusion criteria to our patients would exclude six patients on the basis of an absence of preoperative ABR. This small sample size substantially reduces the likelihood that early postoperative delayed hearing loss would be expected to occur.

The incidence of delayed hearing loss may also be influenced by factors pertinent to the surgical approach and surgical techniques. Differences in the precise surgical manoeuvres

performed between surgeons may alter the chances of the specific manipulation occurring that triggers the pathophysiological mechanism of delayed hearing loss. In the Neu et al. (1999) study, surgical manoeuvres were altered in reaction to intraoperative ABR changes. For example, the surgeon repositioned or temporarily removed cerebellar retractors, in response to being informed of a decrease in amplitude of ABR waves. ABR changes were not used to guide the surgeon's actions in the present study, and this may have increased the probability that hearing would be lost intraoperatively, rather than a mechanism triggered that would lead to delayed hearing loss. Anecdotal reports of delayed hearing loss have been made by the surgeons at Christchurch Public Hospital, where intraoperative monitoring is not routinely performed (P. Bird, personal communication, November 19, 2006), thus the intraoperative trigger for this pattern of loss cannot be entirely absent from the surgeries performed at Christchurch Public Hospital, but the frequency may be reduced. The proportion of patients who have experienced delayed hearing loss in the past at Christchurch Hospital has not been documented.

4.1. Tumour size

An evaluation of tumour parameters in our study is necessary in comparing our results to others. The mean tumour size in this study, as measured by the maximal extracanalicular diameter of the tumour on MRI, was 17.7 mm. There is much variability in how the tumours are measured, therefore comparisons of tumour sizes across studies is limited to those who have defined tumour size in the same way. Such a comparison indicates that the tumour size in our study is similar to that in other large-scale international series of surgical patients in which mean tumour size ranges from 12.0 mm to 22.4 mm (Slattery et al., 1997; Stipkovits, Van Dijk, & Graamans, 1998; Van Dijk et al., 2000). The average tumour size in our patients was markedly smaller than that in the studies of Neu et al. (1999) and Strauss et al. (1991), in which mean tumour sizes of 28 mm and 32 mm respectively were reported, however the measurement method is not reported by Neu et al. (1999). Strauss et al. (2001) reported a mean tumour size of 19.25 mm in their 41 patients; however this population was limited to patients who showed fluctuating ABR intraoperatively. It is important to note that differences in tumour sizes between groups may reflect the decisions of the surgeons on when to operate, rather than indicating size at the time of detection. Hearing preservation is most likely when surgery is undertaken when tumours are small (Massager et al., 2006; Meyer et al., 2006).

However, the decision to operate when tumours are small has to take into account the morbidity of surgery and the high risk of losing hearing intraoperatively, relative to the certainty that hearing will deteriorate over time without surgery (Solares & Panizza, 2008).

4.1.1. The influence of tumour size on preoperative hearing

Most studies report little relationship between tumour diameter (either including or excluding the intracanalicular portion) and preoperative hearing (Arriaga, Long, & Nelson, 1993; Caye-Thomasen, Dethloff, Hansen, Stangerup, & Thomsen, 2007; Graamans, Van Dijk, & Janssen, 2003; Rosenberg, 2000; Stipkovits et al., 1998; Tierney, Chitnavis, Sherriff, Strong, & Gleeson, 1998). Indeed, studies of the natural progression of conservatively managed patients have shown a gradual deterioration of hearing even in the absence of growth, or in cases of negative growth, of tumours (Graamans et al., 2003; Stipkovits, Graamans, & Van Dijk, 2001). In contrast, Harner, Fabry and Beatty (2000) found a weak association between tumour size and PTA and WRS across tumour sizes, with a stronger correlation for tumours with a total size of greater than 50 mm. Nadol et al. (1996) reported an absence of correlation between hearing loss and the lateral extent of invasion of the IAC, and a relatively weak correlation between the maximum diameter of the tumour in the CPA and low-frequency hearing loss. Consistent with most previous studies, no significant relationship was found between tumour size and preoperative hearing parameters in our series of patients.

Throughout the literature there is some evidence of a relationship between the degree of preoperative *retrocochlear* hearing loss and tumour size. Using electrocochleography, Tanaka et al. (1999) demonstrated a strong positive correlation between tumour size and the extent of disparity between the PTA threshold and the detection threshold of CAP or CM. This was interpreted as indicating that the degree of retrocochlear hearing loss has a tendency to increase parallel to the increase in vestibular schwannoma size. In our series of patients, no evidence was found of an association between tumour size and the presence of ABR wave V. Indeed, in Case 13, involving a medium tumour with marked IAC expansion, preoperative ABR showed a wave I-V latency interval within normal limits. Caye-Thomasen et al. (2007) demonstrated that in a series of conservatively managed patients with vestibular schwannomas, the absolute volumetric growth rate, but not the maximum tumour diameter, correlated with the hearing deterioration rate. They interpreted this as evidence that tumour

pressure on the cochlear nerve induces the retrocochlear portion of hearing loss (Caye-Thomasen et al., 2007). Further support for this hypothesis is provided by Lapsiwala and colleagues (2002) who documented a positive correlation between the latency of ABR wave V and intracanalicular pressure as measured during surgery.

4.1.2. The influence of tumour size on postoperative hearing

A number of factors have been postulated in the literature to predict preoperatively which patients are likely to have their hearing preserved following vestibular schwannoma removal. Of these factors, tumour size appears to be one of the most significant and consistently reported prognostic indicators for hearing outcome. Most authors agree that smaller tumour size offers a greater chance of hearing preservation (Betchen et al., 2005; Cohen et al., 1993; Dornhoffer et al., 1995; Fischer et al., 1992; Gjuric et al., 2007; Jacob et al., 2007; Khrais & Sanna, 2006; Mohr et al., 2005; Nadol et al., 1992; Robinette, Bauch, Olsen, Harner, & Beatty, 1997; Samii & Matthies, 1997; Yang et al., 2008). However, there are some studies in which no relationship between tumour size and hearing outcome has been found (Brackmann et al., 2000; Slattery et al., 1997). It is possible that the variation in the literature arises from differences in patient selection criteria, in particular the maximum tumour size in which hearing preservation is attempted.

No significant difference between tumour size in the group of patients in which hearing was preserved and the group who suffered anacusis in the present study. It is of particular note that the two patients with intracanalicular tumours and the three patients with extracanalicular tumour diameters of less than 10 mm all experienced postoperative anacusis. These results are not consistent with two recent, albeit much larger, studies in which patients with an extracanalicular tumour diameter of less than 10 mm had significantly better hearing outcomes than patients with tumours larger than 10 mm (Jacob et al., 2007; Yang et al., 2008). A possible explanation is provided by Khrais and Sanna (2006), who suggest that tumour size is a significant predictor of postoperative hearing outcome for patients with large tumours only (classified as larger than 20 mm in their study). Indeed, hearing preservation was not achieved in our study in any of the three patients with large tumours (≥ 30 mm).

The increased risk of postoperative anacusis associated with larger tumours has been hypothesised to result from a greater extension of large tumours into the IAC, which has been

associated with increased intracanalicular pressure and poorer hearing outcomes (Badie et al., 2001; Lapsiwala et al., 2002; Mohr et al., 2005). Lapsiwala et al. (2002) suggest that the increased intracanalicular pressure may make the cochlear nerve and its vasculature, and the vascular supply to the cochlea, more vulnerable to surgical manipulation. However, the relationship between intracanalicular pressure and hearing outcomes may not be this simple. Lapsiwala et al. (2002) also found that the intracanalicular pressure, as measured during surgery, directly correlated with the latency of wave V in baseline ABR recordings. Given that ABR wave V is thought to be generated in the upper brainstem (Hall, 2006), it is possible that increased IAC pressure is a result of the same mechanism as the wave V latency increase, rather than the cause of the latency change. More recently, Yang et al. (2008) found no relationship between the degree of tumour filling in the IAC and hearing outcome. As the size of the tumour within the IAC was not measured in the present study, it is not possible to evaluate the impact of the degree of IAC involvement on hearing outcome. However, IAC expansion was noted in 16 cases, which provides some indication of IAC involvement. No relationship was evident between the degree of IAC expansion and hearing outcome. Indeed, hearing was not preserved in any of the three cases with no IAC expansion.

There is an increased likelihood of invasion of the tumour into the cochlear nerve in larger tumours, which provides another explanation for the association between tumour size and hearing outcome. Light microscopy of cochlear nerve specimens removed with vestibular schwannomas has demonstrated that the cochlear nerve is typically separate from the tumour in small and medium tumours, but the limiting structure between the tumour and nerve is not easily identified in large tumours (Ylikoski, Collan, & Palva, 1979). Similarly, evidence suggests that the cochlear nerve is indistinguishable from the tumour with significantly higher frequency in tumours larger than 20 mm (Koos & Perneczky, 1985; Umezu & Aiba, 1994). Increased involvement of the cochlear nerve in the tumour would be expected to require a greater degree of surgical manipulation in order to completely excise the tumour, which would necessarily increase the likelihood of damage to the cochlear nerve and a poorer hearing outcome.

4.2. Preoperative auditory function

It is likely that the rate of hearing preservation experienced in this series of patients, as well as the probability of observing delayed hearing loss, was influenced by preoperative hearing

status. The retrosigmoid approach, which conveys the possibility of hearing preservation, is employed by the surgeons at Christchurch Public Hospital for all patients with any degree of measurable preoperative hearing, and for all patients with large tumours. This provides a strong contrast with much of the literature on hearing preservation following vestibular schwannoma excision, which employs stricter criteria based on either tumour size or the presence of “serviceable” hearing preoperatively. Serviceable hearing is typically defined using the AAO-HNS criteria as a mean pure tone threshold of less than 50 dB HL, and maximum speech discrimination score of at least 50% (AAO-HNS, 1995).

According to the AAO-HNS hearing grading system, Class A and Class B hearing is considered serviceable, whereas Classes C and D are not. Using these criteria, preoperative hearing may be considered serviceable in 13 of the 19 patients who underwent surgery with attempted hearing preservation in this study. However, it has been posited that for some patients, Class C hearing may be useful, since a hearing aid is likely to be of benefit in an ear with a discrimination score of more than 70% (Caye-Thomasen et al., 2007; Meyer et al., 2006). If a shift in the criterion of serviceable hearing is applied, so that all patients with a maximum preoperative speech discrimination score of at least 70% are ascribed the status of serviceable hearing, 14 patients may be considered to have serviceable hearing.

All patients in the present study had measurable hearing preoperatively, with preoperative assessment revealing a mean pure-tone average of 39.3 dB HL ($SD = 19.1$ dB HL) and a mean maximum speech discrimination score of 74.7% ($SD = 31.3\%$). Preoperative pure-tone and speech discrimination scores vary widely in the literature, most likely as a result of variation in study inclusion criteria. Indeed, the absence of inclusion criteria based on preoperative hearing in the present study led to a wide range of preoperative hearing scores within our series of patients, as shown by the large standard deviations for both PTA and WRS data. A comparison of the mean scores in this study to the series reported by Lassaletta et al. (2003), in which no strict patient selection criteria was applied, shows that the mean preoperative hearing status of our patients was markedly better than the PTA of 54 dB HL and speech discrimination score of 58% found for their 65 patients. However, Slattery, Brackmann, & Hitselberger (1997) documented a mean preoperative PTA of 29 dB and a mean speech discrimination score of 86% in their series of 151 patients for which no inclusion criteria is specified. Consistent with previous studies, the audiometric configuration in our patients tended to show worse hearing at higher frequencies in most cases (Harner et

al., 2000; Van Dijk et al., 2000). However a flat loss was also common, and was evident in six cases.

4.2.1. Causes of preoperative hearing loss

The precise pathogenesis of hearing loss associated with a vestibular schwannoma is unknown, however there is a general consensus that hearing loss may be of cochlear, retrocochlear, or cochlear-retrocochlear origin (Morlet et al., 2003; O-Uchi et al., 1994). Clinical and histological studies indicate that the mechanisms responsible for the retrocochlear component of preoperative auditory dysfunction include destruction of cochlear nerve fibres by pressure atrophy or invasion, compression or stretching of the cochlear nerve fibres, and compression of the blood supply to the cochlear nerve (Kveton, 1990; Nadol et al., 1996; Selesnick & Jackler, 1992). In the present study, preoperative ABR showed an absence or prolonged latency of wave V, or a significant interaural interwave latency difference (one or any of IT_{I-III} , IT_{III-V} and IT_{I-V}) in 17 cases, providing evidence of neural dysfunction. In the six cases of a delayed wave V, a disruption of neural synchrony, a reduction in the number of responsive fibres, or a delay in neural conduction time, resulting from the tumour compressing the cochlear nerve and blocking the conduction of action potentials is suggested. Histopathological studies of the human temporal bone in cases of vestibular schwannoma demonstrate degeneration of spiral ganglion cells as a prominent finding, which would be consistent with the delayed neural activation found in these subjects (De Moura, 1967; Eckermeier et al., 1979; Kaga, Iwasaki, Tamura, Suzuki, & Haebara, 1997; Suga & Lindsay, 1976). Delayed neural conduction is suggestive of a conduction block caused by either direct pressure on the eighth nerve, or by impairment of the eighth nerve microcirculation resulting from tumour compression (Matsunaga & Kanzaki, 2000). In the ten subjects in whom wave V was absent, a greater degree of compression, or a greater loss of neurons may be indicated. All the participants demonstrating abnormal ABR, still presented with measurable hearing, suggesting a *total* neuronal conduction block was not responsible for the alteration of responses.

Notably, tone decay testing was indicative of retrocochlear pathology only in Cases 5, 6, 9. Tone decay has traditionally been postulated to reflect an impairment in the auditory nerve fibres (Morales-Garcia & Hood, 1972), however the present results do not indicate any correlation between tone decay results and ABR findings, which should provide a more

accurate indication of auditory nerve function. It seems likely that these findings reflect a lack of sensitivity of tone decay testing, rather than providing any additional information about neural function in these patients.

Differentiation between the cochlear and neural components of hearing loss in vestibular schwannoma patients has been previously accomplished by evoked OAE testing (Kim, Edwards, Telain, Kileny, & Arts, 2006; Morlet et al., 2003). OAEs have been shown to reflect normally functioning preneural OHC mechanisms, therefore their presence in an ear with sensorineural hearing loss suggests, by exclusion, that the hearing loss is of a primarily neural, as opposed to cochlear, aetiology. Twelve of the 16 patients in whom preoperative DPOAEs were measured in the present study demonstrated emission patterns consistent with an (at least partially) cochlear origin of hearing loss. This is consistent with previous studies that have reported 57-100% of vestibular schwannoma patients demonstrate cochlear dysfunction (Noguchi et al., 1998; Prasher et al., 1995; Telischi, 2000; Yokoyama et al., 1999). Notable exceptions include Case 14, who demonstrated present emissions from 2-8 kHz, despite a moderate sloping to severe hearing loss at these frequencies, thus suggesting that the hearing loss was retrocochlear in origin. An emission was elicited at 8 kHz in the presence of a pure-tone threshold of 85 dB HL in Case 9, again consistent with a retrocochlear loss. Interestingly, no emissions were present in this participant from 2-6 kHz, despite better thresholds at these frequencies. This indicates that cochlear losses were present at some frequencies and neural losses present at other frequencies.

The reduction of cochlear active mechanisms in vestibular schwannomas has been postulated to be the result of cochlear hypoxic injury resulting from IAA compression by the tumour mass growing within the IAC or at the CPA (Gouveris, Victor, & Mann, 2007). Gouveris et al. (2007) suggest that there is a considerable degree of compensation within the cochlea to this progressive tendency for reduced cochlear blood flow, as the observed changes in DPOAEs are not as drastic as would be predicted by experimental findings in animals. Such animal studies have demonstrated a strong and immediate influence of changes in cochlear blood supply on the amplitudes of DPOAEs (Kimura & Perlman, 1958; Widick et al., 1994). Animal studies would further suggest that high-frequency OAEs would be expected to be affected first by a reduction in cochlear blood flow, as this region is most sensitive to vascular occlusion (Kimura, 1986). However, Gouveris et al. (2007) found that amplitudes of DPOAEs were decreased at 1-2.8 kHz compared with the non-tumour ear in participants with no greater

than a mild hearing loss, whereas no significant difference was found in higher frequency DPOAEs. DPOAEs in our series of patients did not show a consistent pattern of presence or absence at any frequency band, suggesting more than one mechanism could be responsible for the degeneration of OHCs, perhaps dependent on the location and size of the tumour. However, the possibility of pre-existing OHC damage due to factors such as noise exposure or ototoxic drugs cannot be eliminated. One mechanism by which the tumour may cause degeneration of OHCs may be through a reduction in the efferent control of active mechanical tuning in the cochlea. Damage to the efferent fibres by similar mechanisms that cause the damage to afferent fibres may lead to the loss of sharp frequency selectivity, and later to the loss of both hearing sensitivity and evoked OAEs (Ferguson et al., 2001; Prasher et al., 1995).

In addition to OHC damage, histological investigations of temporal bones affected by unoperated vestibular schwannomas have demonstrated significant degeneration of the IHCs, the stria vascularis, and the spiral ligament (De Moura, 1967; Eckermeier et al., 1979; Mahmud et al., 2003; Suga & Lindsay, 1976). Evidence has also been found of endolymphatic hydrops and a high concentration of protein in the perilymphatic spaces (Eckermeier et al., 1979; Mahmud et al., 2003). Mahmud et al. (2003) further demonstrated that in the temporal bone specimens from patients in whom the speech discrimination score had been documented below 50%, there was always degeneration of the inner ear in addition to degeneration of neurons. Although there is no clear evidence of a functional impairment of IHCs, their dysfunction may be implied from abnormalities in ABR wave I recorded from ear with vestibular schwannomas. In three cases in this study, the latency of wave I was prolonged relative to that recorded from the contralateral ear. Click-evoked ABR at high stimulus levels, as was employed in this study, has been shown to be generated primarily by the basal portion of the cochlea. In the case of impairment of the IHCs in this portion of the cochlea, the response would be generated by functional IHCs more apically (Hall, 2006). The increased travel time along the basilar membrane required for a response to be elicited from the apical portion of the cochlea would necessarily result in a prolonged latency of wave I. This hypothesis is supported by the audiometric configuration in cases that demonstrated a delayed wave I, which all showed poorer thresholds in the higher frequencies, suggesting that cochlear impairment may be greater in the basal region. Alternatively, the prolongation of wave I latency, and in particular the absence of wave I, as was observed in seven cases, may indicate impaired neural conduction in the peripheral portion of the cochlear nerve.

4.3. Preoperative prognostic factors for hearing outcome

As previously stated, ABR morphology tends to be poorer with larger tumours, indicating greater damage to the cochlear nerve (Moffat et al., 1999). However, in the present study no clear relationship was present between preoperative ABR and tumour size. The prognostic value of preoperative ABR for hearing outcome, irrespective of tumour size, has been consistently demonstrated (Brackmann et al., 2000; Colletti et al., 1997; Dornhoffer et al., 1995; Josey, Glasscock, & Jackson, 1988; Moffat et al., 1999; Robinette et al., 1997). It has been proposed that the morphology of preoperative ABR is indicative of the physiological integrity of cochlear nerve fibres (Josey et al., 1988; Moffat et al., 1999). This theory suggests that ABR showing a normal morphology but increased peak latencies indicates compression or stretching of the cochlear nerve slowing neural conduction or disrupting synchronous firing, rather than invasion of the nerve by tumour cells. Tumour infiltration of the nerve would be expected to disrupt ABR morphology, representing an irreversible loss of neural fibres and predicting a poor hearing outcome (Moffat et al., 1999). In our series of patients, five showed normal morphology of wave V preoperatively, three of which were from the group of six whose hearing was preserved. This suggests some effect of ABR morphology on postoperative hearing results.

Of the 12 patients in whom hearing was lost and ABR was tested preoperatively, five had no reproducible ABR peaks at 80 dB nHL preoperatively. Two patients who had preserved hearing postoperatively had no identifiable preoperative ABR however, one of these patients (Case 15) underwent planned subtotal tumour removal, therefore a different relationship between preoperative auditory function and hearing outcome would be anticipated, as will be discussed later. Although poor morphology of preoperative ABR is a poor prognostic indicator for postoperative hearing outcome, as documented in the present study, several studies report the maintenance of functional hearing despite absence of all ABR waves before and after surgery (Cacace, Parnes, Lovely, & Kalathia, 1994; Mustain, al-Mefty, & Anand, 1992; Schlake et al., 2001). Roberson, Jackson, and McAuley (1999) reported that hearing preservation was achieved in seven of nine patients with an absent preoperative ABR, with four showing an improvement in hearing postoperatively. No objective measures of cochlear function were included in the Roberson et al. (1999) study; however it is probable that the origin of hearing loss in the patients with poor ABR and preserved hearing was primarily neural. The pressure on the tumour would be expected to be released following its removal in

these patients, resulting in an improvement in neural conduction, and thus hearing, where the vascular supply to the cochlea was maintained.

Better preoperative hearing status, defined by pure-tone thresholds and maximum speech discrimination score, has been well established as a positive prognostic variable for hearing preservation (Brackmann et al., 2000; Fischer et al., 1992; Khrais & Sanna, 2006; Robinette et al., 1997; Samii et al., 2006; Yang et al., 2008). In particular, a strong relationship between preoperative speech discrimination scores and postoperative hearing has been consistently demonstrated (Josey et al., 1988; Nadol, 1993). This relationship possibly occurs because better preoperative hearing indicates a greater likelihood that the cochlear nerve is morphologically intact and distinct from the tumour, reducing the need for surgical manipulation (Umezu & Aiba, 1994). Umezu and Aiba (1994) point out that serviceable postoperative hearing may be retained more frequently in patients whose preoperative hearing is relatively good, primarily because hearing rarely improves and usually declines after surgery. Patients with better hearing preoperatively therefore can afford a greater degree of loss before hearing is no longer measurable. However, there are studies which have failed to find a significant relationship between pre- and postoperative hearing levels (Colletti et al., 1997; Dornhoffer et al., 1995; Glasscock, McKennan, & Levine, 1987; Shelton, Brackmann, House, & Hitselberger, 1989). In the current study, there was no significant difference in preoperative PTA and WRS results between those patients who suffered anacusis postoperatively and the patients in whom hearing was preserved. Although it is quite possible that the small sample size in this study influenced these results.

No relationship was evident between preoperative DPOAEs and hearing outcome in this study. In the group in which hearing was preserved, DPOAEs were absent at all the frequencies tested in three of the five patients tested preoperatively, and were present at all frequencies only in Case 13. In contrast, DPOAEs were absent at all frequencies tested in only one of the eleven patients who underwent preoperative DPOAE testing and suffered from postoperative anacusis. Three patients in the anacusis group had DPOAEs present at all frequencies tested preoperatively, indicating good OHC function. These results are consistent with several studies investigating the prognostic value of preoperative OAEs to hearing preservation following vestibular schwannoma surgery, which have failed to show any significant correlation between the presence of OAEs preoperatively and hearing outcome (Robinette et al., 1997; Stidham & Roberson, 2001). However, there is some evidence that

patients with TEOAEs present in all frequency bands tested (1-4 kHz) were more likely to have successful hearing preservation (Kim et al., 2006). Although Kim et al. (2006) found that robust TEOAEs were a favourable predictor for hearing preservation, there was no statistically significant predictive value if responses were absent in any band. Given that absent OAEs indicate a hearing loss that is at least partially cochlear in origin, it would be expected that hearing in these cases would not recover following surgery. Patients with all DPOAEs present preoperatively in the present study tended to have better pure-tone thresholds than patients in whom all DPOAEs were absent. In the regression analysis performed in the Kim et al. (2006) study, present OAEs were found to have predictive value alone, however the authors suggest that the power may be enhanced when other variables such as tumour size and preoperative hearing, were factored in.

4.4. Nerve of tumour origin

Recent studies have found that vestibular schwannomas originate from the IVN with at least twice the frequency of the SVN (Fiscina et al., 2007; Gjuric et al., 2007; Jacob et al., 2007; Komatsuzaki & Tsunoda, 2001). Our data contradicts these findings, as in the ten cases in which a vestibular nerve of origin could be identified, eight tumours originated from the SVN and two from the IVN. Jacob et al. (2007) suggest that as the cochlear nerve is immediately adjacent to the IVN in the IAC, tumours arising from the IVN may also infiltrate the cochlear nerve directly and attempts at separation can damage more auditory fibres. This theory has been supported by the higher rate of hearing preservation for patients with SVN tumours documented by Jacob et al. (2007). More data is needed to clarify the issues of the rates of occurrence of SVN compared to IVN tumours, and whether the nerve of tumour origin has any effect on hearing preservation rates following tumour removal via the retrosigmoid approach.

Four tumours in the current study were found to originate from the facial nerve. Approximately 80% of CPA tumours have been previously reported to be vestibular schwannomas (Brunori et al., 1997; Grey et al., 1996), with schwannomas (as opposed to tumours not originating from the Schwann cells) involving other cranial nerves constituting 2-3% of all CPA tumours (Grey et al., 1996). Cases in which the tumour originated from the facial nerve were included in our analyses based on the assertion that many of the risk factors for hearing were the same as those resulting from a tumour of the vestibular nerve. The fact

that three patients with facial nerve schwannomas lost their hearing immediately postoperatively, two in the presence of an apparently anatomically preserved cochlear nerve, suggests this assumption is correct. Given the statistics on the reported rate of occurrence of facial schwannomas, the high prevalence of facial schwannomas in our series is unusual, and may have impacted overall hearing preservation results in a way not seen in other studies.

4.5. Postoperative hearing preservation

Of the six patients in this study in whom hearing was measurable postoperatively, all demonstrated at least some decline in hearing from their preoperative level. This is consistent with the results of several large series of patients in which postoperative hearing function has been found to be worse than preoperative hearing in most patients, even in cases where hearing is considered preserved (Harner et al., 2000; Nadol et al., 1992; Samii & Matthies, 1997). The mean decrease in PTA from the preoperative assessment to the final postoperative assessment for each patient was 17.0 dB HL and the mean decrease in maximum word recognition score was 25.2%. The mean change in PTA does not completely reflect the change in the audiogram of each patient, as several of the patients showed a greater loss of hearing in the high frequencies than at the frequencies at which the PTA was calculated. Two patients maintained their preoperative hearing class, whereas a drop of at least one class was observed in the other four patients. Further, according to the AAO-HNS guidelines, only three of the six patients with hearing postoperatively had what is considered serviceable hearing. However, hearing could be classified as serviceable in just four of the six patients preoperatively, the other two demonstrated Class D hearing.

As discussed with regard to preoperative hearing, there is controversy regarding what degree of hearing is useful to a patient, and what constitutes “preserved” hearing. The present results highlight the variation that may be introduced between studies when different criteria for reported hearing preservation are used. In this study, the hearing preservation rate may be calculated as 32% if the criterion for hearing preservation is any measurable hearing, but falls to 16% if the criterion is only patients with serviceable hearing postoperatively. Similar results have been found by others when different reporting criteria are used (Magnan et al., 2002; Samii & Matthies, 1997). For example, Lassaletta et al. (2003) found that 39% of their 33 patients had measurable hearing postoperatively, whereas 15% demonstrated serviceable hearing. However, only patients with serviceable hearing preoperatively were included in this

study. Similarly, Moffat et al. (1999) reported that of their 50 patients, all with serviceable hearing preoperatively, hearing was measurable postoperatively in 18%, but was serviceable in only 8%. Hearing preservation rates using the retrosigmoid approach range from 8% to 65% (Arriaga, Chen, & Fukushima, 1997; Darwish et al., 2005; Ferber-Viart, Laoust, Boulud, Duclaux, & Dubreuil, 2000; Harner et al., 2000; Hecht et al., 1997; Lassaletta et al., 2003; Magnan et al., 2002; Moffat et al., 1999; Staecker, Nadol, Ojeman, Ronner, & McKenna, 2000), with much of the variation accounted for by variations in patient selection criteria and schemes for classifying postoperative hearing outcomes. These differences make it difficult to compare the total hearing preservation rate in our study to others, in particular due to the lack of other studies that are comparable in their use of the retrosigmoid surgical approach for patients with tumours of any size and any degree of measurable preoperative hearing.

The decrease in hearing from its preoperative level documented in all cases of hearing preservation suggests that further damage to the cochlea, the cochlear nerve, or the vasculature of either structure, was instigated during surgery. In the two cases in which ABR was recorded intraoperatively and hearing was preserved, wave I was measurable throughout surgery, whereas deterioration of waves after wave I was documented. This suggests neural damage that occurred to the proximal portion of the cochlear nerve. The presence of high levels of noise and artefact during recording makes it impossible to determine the point at which these later peaks were lost, as it may be that noise obscured these waves, rather than that they deteriorated.

The analysis of all auditory responses recorded from each of the patients with postoperative hearing provides an indication of the likely site of impairment. The exception is Case 15 in which the aetiology of hearing loss induced during surgery could not be determined due to an absence of preoperative and postoperative electrophysiological responses. In this case of subtotal tumour removal from the facial nerve, the patient demonstrated a complete loss of speech discrimination and very limited residual hearing from 0.75 to 1.5 kHz only. It is interesting that in this case residual hearing was confined to the mid-frequencies. High frequency impairments following vestibular schwannoma removal may be expected, based on the tonotopic organisation of the cochlear nerve making the superficial high-frequency fibres more vulnerable to mechanical insult (Hatayama et al., 1999). In addition, the increased vulnerability of the basal portion of the cochlea to transient ischemia makes high-frequency hearing loss more likely than low-frequency loss (Kimura & Perlman, 1958). The audiometric

configuration in this case is suggestive of two mechanisms of damage to hearing: one of the above mechanisms resulting in high-frequency loss, and another mechanism resulting in the low-frequency hearing loss.

One possibility is that the decrease in thresholds at the low frequencies is the result of endolymphatic hydrops, which typically first affects the apex of the cochlea, and thus low frequency hearing. Cases of postoperative endolymphatic hydrops in the ipsilateral ear immediately following vestibular schwannoma removal could not be found in the literature. However, Walsted, Salomon, Thomsen, and Tos (1991) found a postoperative threshold increase in the contralateral ear in 40 of 60 their patients, which they attributed to endolymphatic hydrops. This hearing loss was greatest in the low frequencies in the week following surgery, included the high frequencies after the first week, and had normalised by three months postoperatively. The authors propose that this temporary endolymphatic hydrops, was triggered by the loss of cerebrospinal fluid (CSF) during surgery. They hypothesise that the loss of CSF results in a decreased CSF pressure that is transmitted to the perilymph via the cochlear aqueduct. Given that in normal conditions the pressures in the CSF, endolymph, and perilymph are equal (Marchbanks, Reid, Martin, Brightwell, & Bateman, 1987), the resulting perilymph depression was thought to have generated a compensatory expansion of the endolymphatic compartment and subsequent endolymphatic hydrops (Walsted et al., 1991). Presumably, a loss of CSF could affect the perilymph concentration in both ears, therefore this may be the mechanism responsible for the low-frequency loss in Case 15. Histological studies have repeatedly found evidence of an increased protein concentration in the cochlear fluids, particularly the perilymph, which is often associated with endolymphatic hydrops (Eckermeier et al., 1979; Mahmud et al., 2003; Morrison, Gibson, & Beagley, 1976; O'Connor, Luxon, Shortman, Thompson, & Morrison, 1982). However these studies have been performed on unoperated vestibular schwannomas and therefore the pathological findings are likely to be the result of preoperative tumour growth, rather than any surgical mechanism.

4.5.1. Neural origin of hearing deterioration

Case 5 also presented with a pre- and postoperative absence of ABR and DPOAEs indicating both a cochlear and a neural origin of hearing impairment preoperatively. Although it is not possible to determine the cause of further deterioration in hearing based on these results, tone

decay testing provides some evidence that the postoperative loss of hearing was a least partially neural in origin. Preoperative tone decay in this case was indicative of abnormal auditory adaptation, with an increase in presentation level of 25 dB HL required for the patient to maintain tone perception for 60 seconds. Postoperatively, the patient was unable to maintain tone perception for 60 seconds up to a maximum presentation level of 110 dB HL (40 dB SL). Given that abnormal adaptation is indicative of dysfunction of the cochlear nerve (Gerull et al., 1982), an increase in abnormal adaptation seems to suggest that further neural damage was sustained during surgery. No previous studies have investigated postoperative tone decay in vestibular schwannoma patients; however this case suggests that tone decay testing may be useful in assessing the origin of hearing impairment where ABR is absent.

Interestingly, Case 5 demonstrated preserved, although markedly decreased, hearing sensitivity at 0.5-1 kHz, with a profound loss of hearing at 0.25 and 1.5-6 kHz. Hearing was preserved at its preoperative level at 8 kHz. It is possible that the loss of neural fibres selectively at the low and mid-high frequencies was related to the specific location of the tumour. It seems likely that several mechanisms are responsible for such a pattern of loss, including some or all of cochlear damage, cochlear nerve damage, or endolymphatic hydrops. It is particularly unusual that high-frequency function appears to have been spared further damage during surgery, given that this was the frequency in which the greatest loss was seen in our other patients. Although the serial audiograms in this case appear to show some improvement in the low frequencies from postoperative day 1 to 2, given that the contralateral ear shows a similar improvement, this is most likely related to the patient's reduced ability to co-operate within the first 24 hours of surgery.

The two cases in which the smallest drop in hearing was noted both appear to have experienced some reduction in hearing through trauma to the cochlear nerve or its vasculature, with preservation of cochlear function. In Case 13, that of a patient with NF2, subtotal tumour removal was performed in order to reduce the risk of brainstem compression while maximising the chances of preserving facial and auditory nerve function. This surgery was successful in that there was no change postoperatively in pure-tone thresholds at any frequency, or in speech discrimination abilities. In addition, DPOAEs were present at all frequencies tested preoperatively, indicating maintenance of OHC function and thus preservation of the vascular supply to the cochlea. The maintenance of cochlear function is further evidenced by the postoperative presence of ABR wave I with no significant change in

latency or morphology. Despite no change in behavioural audiological responses, there was an immediate postoperative loss of all ABR waves beyond wave I in this case.

Similarly, in Case 8 injury to the cochlear nerve functioning is indicated by an increase in the latency of all waves beyond wave I. In this case, the only significant change in pure-tone thresholds was a drop of 20 dB at 8 kHz. No changes occurred to speech discrimination, DPOAEs, or ABR wave I latency. However, some recovery in latency of wave V was documented over the early postoperative period, the cause of which will be discussed later in section 4.5.3. The loss or increased latency of cochlear nerve responses proximal to the generator site of wave I in both of these cases is consistent with impaired neural function resulting from damage inflicted during surgery to the cochlear nerve or its vasculature. Damage to the proximal portion of the cochlear nerve sustained during direct or indirect surgical manipulation is the most likely cause of the deterioration in postoperative ABR in these two cases. However, given that speech discrimination abilities did not deteriorate with ABR, a sufficiently synchronised auditory signal must still have been transmitted, suggesting that any damage to the nerve must have been relatively minor.

4.5.2. Cochlear origin of hearing deterioration

In contrast to Cases 8 and 13, a primarily cochlear origin of hearing loss resulting from surgery occurred in Case 11. Although no DPOAEs were present bilaterally either pre- or postoperatively, wave I, which was present at a normal latency preoperatively, was lost immediately postoperatively. Cochlear dysfunction, depending on the severity, has been shown to increase the latency, attenuate, or cause the absence of ABR wave I (Legatt, 2002). Pure-tone testing in the case showed a decrease in hearing sensitivity from 0.25 to 2 kHz, and a total loss of hearing above 2 kHz. The patient had no remaining speech discrimination ability in the ipsilateral ear. The loss of hearing in the high frequencies is typical of transient cochlear ischemia (Morawski et al., 2004). Several studies have demonstrated that transient ischemia affects the higher frequencies more rapidly and more profoundly than the middle and low frequencies (Morawski et al., 2004; Morawski et al., 2003a; Morawski et al., 2003b). Given that the effects of ischemia on cochlear function are dependent on the severity and duration of the ischemic episode (Morawski et al., 2004), it seems probable that in a case such as this, ischemia was sufficiently brief so as to leave at least the lower frequency portions of the cochlea intact. Anacusis may result from the same type of damage, but a longer or more

severe episode. However, given the tonotopic arrangement of the cochlear nerve, with higher frequencies located more superficially (Sando, 1965), these frequencies are more vulnerable to the effects of mechanical disruption of the nerve itself during tumour removal (Hatayama et al., 1999). It is possible that the hearing loss in this case resulted from a combination of cochlear and neural effects. The improved ABR recordings by postoperative day 5 indicate improved neural conduction, most likely due to reduced pressure on the cochlear nerve following surgery. The reason for the delay of five days in this improvement in neural conduction becoming apparent may be consistent with presence and then subsidence of cochlear nerve oedema following surgery.

4.5.3. Improvement in ABR

A marked improvement in ABR was also seen in Case 17 (see Figure 32A and B in the Results section). Specifically, an improvement in the morphology of wave V and the return of wave III, which had been absent preoperatively, on postoperative day 2, was observed. However, the small wave I, which had been present preoperatively at 90 dB, was lost. No significant changes were documented in DPOAEs, pure-tone thresholds, or speech discrimination. The loss of ABR wave I suggests some damage to the cochlea, possibly restricted to the inner hair cells, as DPOAEs remained present from 2-4 kHz, or to the proximal portion of the cochlear nerve. However, this damage was insufficient to alter hearing sensitivity.

The improvement in ABR morphology in Case 17 is consistent with previous reports in the literature of cases of improved auditory function following tumour removal (Aoyagi et al., 1994; Cacace et al., 1994; Gardner & Robertson, 1988; Kveton, 1990). Matsunaga et al. (2000) suggest that if hearing loss is due to the conduction block associated with impaired microcirculation of the cochlear nerve, hearing may improve after pressure on the nerve is decreased by the tumour's removal. A case study described by Cacace et al. (1994) documented the emergence of additional ABR peaks following dural opening and cerebrospinal fluid drainage. The authors interpreted this as evidence that these surgical phases reduced tumour compression on the auditory nerve and brainstem, releasing the conduction block, and allowing neural transmission to occur (Cacace et al., 1994). This explanation seems plausible for the improvement in wave V in this case, but does not explain the emergence of wave III on postoperative day 2. It is possible that wave III was initially

blocked by the same mechanism as wave V, but was again disrupted immediately postoperatively due the presence of nerve oedema. The emergence and gradual increase of wave III over the early postoperative period may have coincided with the subsidence of this oedema, which Sekiya et al. (1990) have documented during the first two weeks after tumour removal. Recovery following compression injury to the cochlear nerve has been described (Hatayama et al., 1999), but this process proceeded over weeks to months, and is unlikely to result in such a marked improvement in ABR over five days. Hatayama and colleagues (1999) attribute the recovery of the nerve following compression to the resolution of a temporary conduction block that resulted from surgery. They suggest that for recovery to occur, the injury to the nerve must be mild enough that the continuity of the axons in the endoneurial sheath is preserved, a condition known as neuropraxia.

4.7. Postoperative anacusis

In five cases, immediate postoperative anacusis resulted from severance of the cochlear nerve during surgery. In all of these cases, dissection of the cochlear nerve was necessary in order to achieve complete tumour removal. The rate of 73.8% for anatomical preservation of the cochlear nerve in this series is similar to the rate of 75.8% reported in a large series by Samii et al. (2006). In the four patients who presented with no reproducible ABR preoperatively and suffered from postoperative anacusis, the cochlear nerve had been necessarily severed in all cases. In the fifth case in which the cochlear nerve could not be preserved, wave I was present at a normal latency preoperatively and wave V was absent. In the two other cases of a preoperative absence of wave V in the group that suffered anacusis, subtotal tumour removal was necessary. These results suggest that an absence of ABR wave V preoperatively may have indicated greater involvement of the cochlear nerve by the tumour, possibly indicating infiltration of the nerve by tumour cells, increasing the likelihood that dissection of the nerve during surgery would be necessary. This is consistent with previous studies suggesting that preoperative ABR is predictive of the physiological integrity of the cochlear nerve (Josey et al., 1988; Moffat et al., 1999).

4.7.1. Anacusis with anatomical preservation of the cochlear nerve

In four of the cases of severance of the cochlear nerve the loss of DPOAEs indicates that damage to the cochlea was also sustained. The most likely explanation is that the IAA was damaged as the cochlear nerve was severed, interrupting the blood supply to the cochlea. Complete preservation of the IAA is extremely difficult when the eighth nerve is severed (Shimamura et al., 2002). The exception is Case 10, in which the emission present at 8 kHz preoperatively remained robust postoperatively, indicating that the blood supply to the cochlea was maintained.

The remaining eight cases of anacusis occurred in the presence of apparent anatomical preservation of the cochlear nerve. The mechanisms of hearing loss despite anatomical preservation of the cochlear nerve are less well understood, and may result from any combination of direct trauma to the labyrinth or cochlear nerve, or disruption to the vascular supply to the labyrinth or auditory nerve (Colletti et al., 1997; Friedman, Brackmann, & Mills, 1998; Sekiya et al., 1986). In seven of the eight cases, all DPOAEs were absent postoperatively, suggesting a cochlear component to the hearing loss. Case 16, in which DPOAEs remained robust despite complete anacusis, will be discussed in detail later. In Case 7, DPOAEs were absent preoperatively, and in Case 4 the patient was unavailable for preoperative DPOAE testing. Therefore, it cannot be determined in these cases whether the cochlear structures were damaged further intraoperatively. Vascular compromise to either the cochlea or the cochlear nerve results from rupture, occlusion, or vasospasm of the IAA or smaller arterial vessels, either transiently or permanently (Colletti et al., 1997; Gouveris & Mann, 2009). It has been demonstrated that surgical manipulations within the CPA may cause vasospasm or an avulsion rupture of the IAA, resulting in a sudden loss of cochlear potentials (Levine, Bu-Saba, & Brown, 1993; Sekiya, Iwabuchi, Kamata, & Ishida, 1985; Sekiya & Møller, 1987). As the branches of the IAA distal to the fundus of the IAC are fixed within the bony cochlea, the branches of the IAA have been found to be particularly vulnerable at the fundus to traction forces derived from manipulation in the CPA (Sekiya & Møller, 1987).

In a study of the effect of various surgical manoeuvres on DPOAEs during vestibular schwannoma excision, Morawski et al. (2004) found that bipolar cautery close to the IAC structures had the greatest impact on DPOAE amplitude. The authors hypothesise that the cause of DPOAE reduction resulting from bipolar cautery may include vascular interruption from coagulation or vasospasm. Previous studies have shown that the severity of damage to

the spiral limbus, hair cells, and spiral ganglion cells during ischemic episodes depends on the degree and duration of ischemia (Morawski et al., 2003a; Morawski et al., 2003b; Perlman et al., 1959).

Despite the appearance of an apparently anatomically-preserved cochlear nerve at the conclusion of surgery, direct manipulation of the cochlear nerve during surgery, including stretching, compression, or heat injury, has been demonstrated to induce intraneural haemorrhage and axonal disruption (Sekiya & Møller, 1987). In all cases of anacusis, with the exception of Case 16, all ABR waves were absent immediately following surgery, which may be due to neural as well as cochlear damage. In particular, the cochlear nerve is vulnerable to direct damage at the Obersteiner-Redlich (O-R) zone where the central and peripheral portions of the cochlear nerve are connected (Sekiya & Møller, 1987; Sekiya et al., 1986). The microvasculature of the central portion of the cochlear nerve is sparser and more irregularly distributed relative to the longitudinal vessel network and rich anastomoses of the peripheral portion (Matsunaga et al., 1996). In addition, the central portion has a myelin sheath which is less compact than collagen-reinforced peripheral myelin (Lang, 1985). During manipulation in the CPA, the morphological differences between these sections results in pulling and avulsing of the nerve at the O-R zone where the sections are connected (Sekiya et al., 1986). The O-R zone itself is relatively avascular and therefore susceptible to ischemia and microtrauma (Sekiya & Møller, 1987; Sekiya et al., 1986). A series of animal experiments (Sekiya & Møller, 1987, 1988; Sekiya et al., 1986) and clinical studies (Fischer et al., 1992; Matthies & Samii, 1997; Watanabe, Schramm, Strauss, & Fahlbusch, 1989), suggest that cerebellar retraction may be particularly hazardous for the cochlear nerve. Sekiya, Møller, (1987) found that cerebellar retraction in monkeys altered auditory evoked potentials, leading to prolonged latency, amplitude reduction and sudden loss of potentials. In addition, Sekiya, Møller, and Jannetta (1986) found that compression of the cochlear nerve caused intraneural haemorrhaging and loss of the ultrastructural integrity of the nerve fibres, through disintegration of the myelin sheath.

It is of note that anacusis was the result in two of the four cases of subtotal tumour removal in this study. The goal of a planned subtotal tumour resection is to relieve compression caused by the tumour while minimising surgical morbidity, in particular the risk of facial nerve damage (Rosenberg, 2000). The disadvantages include the risk of recurrence, the need for continued monitoring for tumour growth and possible additional surgery (Rosenberg, 2000).

Post, Eisenberg & Catalano (1995) point out that due to the extreme vulnerability of the cochlear nerve, hearing is often impaired or lost in cases of subtotal removal (Post et al., 1995). This extreme vulnerability is illustrated in the two cases of subtotal removal and anacusis in this the present study. Interestingly, the two cases of anacusis were unplanned subtotal excisions, whereas the two cases of hearing preservation with subtotal tumour removal were planned. It is possible that a planned subtotal resection is approached differently to one that is adopted mid-surgery, thus altering the risk to hearing. The preoperative decision to perform subtotal tumour removal is based on the degree of hearing in the contralateral ear (a particular issue in cases of NF2) and any co-morbid health problems the patient has that increases the risks associated with a long surgery, or may inhibit their recovery and rehabilitation. During surgery, a decision to leave some residual tumour is usually based on the inability to preserve the facial nerve if the tumour is completely removed (P. Bird, personal communication, September 25, 2008).

4.7.1.1. Case 16

In contrast to the other cases of postoperative anacusis with anatomical preservation of the cochlear nerve, in Case 16 cochlear function was demonstrated immediately postoperatively. In this case, behavioural responses to auditory stimuli were absent postoperatively, beginning with the first test session, approximately 48 hours after surgery. The patient did report some self-perceived hearing in the ipsilateral ear immediately after surgery, but given that these reports persisted for three days, despite the audiogram showing total anacusis, it seems unlikely that measurable hearing was actually present. Robust DPOAEs were present bilaterally over the early postoperative period, and at follow-up 12 weeks later, indicating that OHC function was preserved. In addition to DPOAEs, ABR wave I was present at a normal latency immediately postoperatively, consistent with the functional integrity of the distal portion of the cochlear nerve. The absence of any waves beyond wave I, together with a loss of measurable hearing, is indicative of compromise of the proximal portion of the cochlear nerve during tumour removal. Sekiya and Møller (1988) propose that mechanical stress from CPA manipulations may injure the cochlear nerves where they pass through the fundus of the IAC, thus causing a nerve conduction block in the portion of the nerve that is proximal to the generator site of wave I, but leaving wave I intact. It is also possible that damage occurred at the O-R zone, which has repeatedly been shown to be a portion of the cochlear nerve that is

particularly vulnerable to stretching of the nerve or cerebellar retraction (Sekiya & Møller, 1987; Sekiya et al., 1986). It is not possible to determine whether the cause of this neural impairment was disturbance to the microvasculature of the cochlear nerve, or damage to the nerve fibres themselves due to direct surgical manipulation. The hearing loss in this case does not appear to have a cochlear component, given that DPOAEs and ABR wave I were both present immediately postoperatively.

Serial ABR recordings over the early postoperative period in Case 16 documented a gradual increase in the latency of wave I from a peak latency at 80 dB nHL of 1.88 ms on postoperative day 0, to 2.35 ms on postoperative day 5. In addition, the originally clear morphology of this peak also deteriorated so that it became more difficult to identify over the first five days postoperatively. On postoperative day 6, no reproducible wave I was present at 80 or 90 dB nHL. ABR testing 12 weeks postoperatively showed the continued absence of reproducible ABR from the ipsilateral side. This gradual loss of wave I indicates that although the peripheral portion of the cochlear nerve was initially functional following surgery, damage to this portion of the nerve ultimately transpired. This deterioration of ABR is suggestive of retrograde degeneration of the cochlear nerve, progressing from the operative site to the generator site of wave I at the distal cochlear nerve. Although delayed hearing loss was not demonstrated behaviourally, the progressive deterioration of ABR wave I parallels the pattern described by Strauss et al. (1991) in cases of delayed hearing loss. As Strauss and colleagues (1991) proposed, this suggests that a pathophysiological mechanism, whether direct damage to the cochlear nerve, or to its microvasculature, was initiated intraoperatively, and continued in the early postoperative period. It is important to note that we have been unable to find any previous study has measured OAEs together with ABR to determine cochlear function in these patients with delayed hearing loss. In Case 16, the data provide evidence against vasospasm or occlusion of the IAA as the cause of a delayed loss of ABR, at least in this case, as such an event would be expected to result in a complete loss of responses from the cochlear and cochlear nerve. IAA vasospasm or occlusion should also result in a sudden loss of the potentials, whereas in Case 16 the loss of wave I was clearly gradual.

In an effort to further clarify the site of impairment and mechanism responsible for the loss of ABR in Case 16, transtympanic ECoChG was performed 12 weeks postoperatively. Electrocochleograms elicited to tone-burst stimuli of 2 and 4 kHz indicated the presence of clear SP, however this potential was not measurable in response to stimuli of 0.5 and 1 kHz.

This does not necessarily indicate that the inner hair cells were functioning only in the mid-frequencies and not at lower frequencies, but may be a result of the position of the electrode with regard to the tonotopic organisation of the cochlea (Deans et al., 1996). Click-evoked ECoChG showed a clear SP with a small CAP. Taken together, the ECoChG results from all stimuli and the present DPOAEs suggest that the inner and OHCs remained functional and therefore an endocochlear potential and thus the blood supply to the cochlea must have been maintained.

An electrocochleogram demonstrating an SP to AP amplitude ratio of 30% or more in response to click stimuli is considered characteristic of endolymphatic hydrops (Coats, 1981) (Dauman & Charlet de Sauvage, 1984; Gibson, Moffat, & Ramsden, 1977; Gibson & Prasher, 1983; Gibson, Prasher, & Kilkenny, 1983). In this case, the SP/AP ratio of 70% is clearly consistent with the presence of hydrops if this criterion is used. However, as Conlon and Gibson (2000) point out, the SP/AP ratio is less useful diagnostically if the response amplitude is less than 10 μ V. A response of small amplitude may indicate a reduced ability of the cochlea or distal cochlear nerve to generate an electrical response, rather than showing a bias of basilar membrane responding suggestive of hydrops (Conlon & Gibson, 2000). Conlon and Gibson (1999) suggest that enhancement of the SP negativity in response to a 1 kHz tone burst provides a closer correlation with symptomatic Ménière's disease than SP/AP ratio to click. The enhanced negative SP in cases of endolymphatic hydrops is thought to result from asymmetrical basilar membrane movement caused by the pressure build-up in the endolymphatic fluid in scala media displacing the basilar membrane towards scala tympani (Durrant & Dallos, 1974). This asymmetry results in a change to the operating point of the OHCs which is thought to add a DC shift to the OHC receptor current causing an "OHC SP" which, when added to the IHC SP, results in the SP enhancement seen in the ECoChG recordings of patients with hydrops (Gibson et al., 1977).

In Case 16, no SP was measurable in response to tone-burst stimuli of 0.5 and 1 kHz, and broad SPs in the absence of CAPs were elicited by 2 and 4 kHz tone-bursts. The absence of a detectable CAP response to a 0.5 kHz stimulus is not surprising, given that due to the slow travelling wave in the apex of the cochlea, the CAP arising from stimuli at frequencies below 1 kHz are poorly synchronised and provide responses that are difficult to identify (Gibson & Arenberg, 1990). Electrocochleograms evoked by tone-bursts of 1 kHz are considered the most sensitive for detecting hydrops (Conlon & Gibson, 2000). In normal ears, the polarity of

the SP is dependent on the position of the active electrode relative to the portion of the cochlea generating the response (Deans et al., 1996). Conlon and Gibson suggest that the advantage of the 1 kHz tone burst results from the neutral position of the 1 kHz region of the cochlea relative to the electrode on the promontory. This results in a small amplitude SP in most normal ears (Arenberg et al., 1992), making any tendency to basilar membrane displacement easier to detect at this frequency (Conlon & Gibson, 2000). Given the absence of an SP in response to a 1 kHz tone-burst in Case 16, the presence of endolymphatic hydrops seems unlikely. The presence of normal DPOAEs implies normal outer hair cell function. If we assume that the patient in Case 16 had a solely retrocochlear pathology, and otherwise intact inner hair cell function, we could predict an SP amplitude of $-1.9 \mu\text{V}$ and $-2.3 \mu\text{V}$ at 2 and 4 kHz respectively, based on the means provided by Gibson et al. (1993). Although the SP responses to 2 and 4 kHz tone-bursts in Case 16 were larger than the mean amplitude seen in normal ears, the response amplitudes did not reach the diagnostic criterion for endolymphatic hydrops, which Gibson et al. (1993) give as $-9 \mu\text{V}$.

The most plausible explanation for the large SP/AP ratio in Case 16, given the absence of an enhanced negative SP to tone-burst stimuli, is that the high ratio resulted from the very small CAP, rather than a large SP. This is consistent with the loss of responding neural fibres observed through the gradual deterioration of ABR wave I in this case. As ECochG was only performed postoperatively, and only in the ear ipsilateral to the tumour, it is not possible to determine whether the SP was enhanced in amplitude or whether the response was of normal morphology, relative to what would be expected for this patient. Ideally, ECochG would have been performed for the contralateral ear, and also preoperatively, so the responses could be compared. Previous studies of ECochG in patients following vestibular schwannoma excision have demonstrated the presence of a broad negative potential, thought to consist of an enhanced negative SP intermingled with the CAP (Ohashi et al., 1996; Ohashi et al., 2001). Indeed, the ECochG response to click stimuli in Case 16 is markedly broader than responses recorded from normal ears using the same equipment. The amplitude of the SP in this response is what would be expected based on the normative data, suggesting that the shape of the response is most likely due to the small CAP than any other mechanism.

As previously discussed, histological studies of unoperated vestibular schwannomas have provided evidence of changes in the cochlear fluid composition, in particular an increase in the protein concentration of the perilymph, and the presence of endolymphatic hydrops

(Eckermeier et al., 1979; Mahmud et al., 2003; Morrison et al., 1976; O'Connor et al., 1982). These changes in the cochlea may be responsible for the broadening of the ECochG response that has been observed in vestibular schwannoma patients. Alternatively, it has been hypothesised that the abnormal response is the result of impairment of the efferent system (Takeda, Kitahara, & Sawada, 1992). Takeda et al. (1992) found that inactivation of the efferent system, induced by the application of lidocaine, a local anaesthetic to the root exit zone of the vestibular nerve, resulted in an increase in SP amplitude and broadening of the waveform without altering the amplitude of the CAP. The authors suggest that the broad ECochG waveform observed in cases of vestibular schwannoma is caused by enhanced negative SP due to inactivation of efferent cochlear fibres (Takeda et al., 1992). Efferent fibres would be expected to be particularly vulnerable during both tumour growth and excision, given that they travel within the vestibular nerve. It is possible that the disruption of the efferent cochlear fibres, either pre- or postoperatively, in Case 16 was the mechanism responsible for the slightly enhanced SP to 2 and 4 kHz tone-bursts. Although, as stated earlier, whether these potentials are truly enhanced cannot be known without comparison to the response of the contralateral ear.

As N_1 of the CAP recorded in transtympanic ECochG is considered to be the response of the peripheral portion of the cochlear nerve (Colletti, Fiorino, Mocella, & Policante, 1998; Sabin, Prasher, Bentivoglio, & Symon, 1987), and wave I of the ABR is believed to be the far-field representation of this same response, it is interesting that a CAP was elicited in the absence of wave I. Similar results were found by Kaga et al. (1997), who documented the presence of a CAP response with mild threshold elevation despite the absence of ABR. In Kaga et al.'s (1997) case study, the vestibular schwannoma had not been excised and measurable hearing was present. They suggest that the clear CAP recorded via epitympanic ECochG was the response of the distal portion of the remaining cochlear nerve within the osseous spiral lamina, but that the ABR was not generated due to a block of signal conduction by the presence of the tumour at the proximal portion of the cochlear nerve. Histological examination of the temporal bone following the patient's death in that case supported the authors' hypothesis, showing that the majority of the central portion of the cochlear nerve within the IAC was replaced by the tumour and that the numbers of spiral ganglion cells and cochlear nerve fibres were decreased at each turn of the cochlea, most severely in the basal turn (Kaga et al., 1997). Ohashi et al. (2001) proposed a similar explanation for the presence of a CAP recorded from the promontory and the absence of ABR following vestibular

schwannoma removal in their patient. They posit that wave I of ABR reflects the activity of the medial part of the cochlear nerve whereas the CAP has a more peripheral origin, possibly within the cochlea (Dauman, Aran, & Portmann, 1988). Accordingly, it is assumed that a CAP will be recorded unless cochlear function is disrupted, most likely by damage to the vascular supply.

There is also evidence to suggest that the cochlear action *currents* pass through the resistive discontinuity of the *dura mater*, and that the action *potentials* generated here are measurable in the cochlea as the CAP, and from the scalp as ABR wave I (Brown & Patuzzi, 2008). With regard to this explanation, the results of Case 16 may be interpreted as evidence of a progressive injury to the cochlear nerve which prevented the far-field spread of the CAP to be recorded as wave I. A resistive discontinuity must have been maintained, as a CAP was measurable from the cochlea, but this discontinuity may not have been sufficient to generate a response that could be measured using far-field measurement techniques.

Given that the CAP measured in ECoChG was extremely small (9.2 μV), the most parsimonious explanation in this case is that wave I was still present, but was buried within the noise of the far-field recording of ABR. Transtympanic ECoChG records the response of the auditory nerve much closer to the generation site, therefore is able to detect even the very small potential that was present in this case. The magnitude of CAP- N_1 recorded from the promontory is larger across intensities than corresponding magnitudes measured from the earlobe or mastoid process (Ferraro & Krishnan, 1997). The presence of a CAP without wave I suggests that adequate nerve fibres in the distal portion of the nerve were spared degeneration so as to generate a CAP, but not of a sufficient amplitude to be detected from a far-field recording. Similarly, electrical ABR responses recorded from the promontory have been documented in cases where scalp-recorded ABR and behavioural responses to sound are absent following vestibular schwannoma removal (Friedman et al., 1998). Spoendlin and Suter (1976) found that following complete transection of the eighth nerve, approximately 90 - 95% of fibres degenerated and disappeared, leaving 5-10% that were still able to generate a CAP that was measurable at the promontory.

The presence of cochlear responses in the absence of responses from the medial and central auditory pathways has been proposed to be due to a neural conduction block which disconnects the peripheral from the central auditory pathways, causing persistence of peripheral auditory function but a lack of propagation of the input to the brainstem (Colletti et

al., 1998). Several cases of persistence of cochlear responses despite absent ABR and anacusis following vestibular schwannoma removal have been previously reported. Levine et al. (1984) reported a case of a patient with anacusis in whom large CM potentials were obtained 75 days after tumour removal, but neither CAP nor ABR were present at any time postoperatively. Similarly, Friedman and colleagues (1998) observed preservation of an ECoChG response in 8 of their 84 patients despite a complete loss of ABR and postoperative deafness, indicating a deafferentation of ascending auditory pathways together with an intact cochlea.

4.8. Retrograde degeneration of the cochlear nerve

The preservation of the cochlea in the absence of cochlear nerve function in Case 16 is consistent with studies showing that retrograde degeneration of the cochlear nerve following surgical transection spares the organ of Corti (Schuknecht & Woellner, 1953; Spöndlin & Suter, 1976). Animal experiments have demonstrated that this process of cochlear nerve retrograde degeneration following compression damage is complete within one week of the injury (Shimamura et al., 2002). This time course corresponds to the postoperative week in which wave I deteriorated in Case 16. However, Spöndlin and Suter (1976) propose that the process of degeneration of the cochlear nerve in humans is much slower. Their evidence suggests that although the process of degeneration begins immediately, it does not cease until approximately two months later when 90-95% of the nerve fibres have disappeared. In our case, the degeneration of nerve fibres in the first week postoperatively may have been sufficient to make ABR wave I undetectable, even though the degenerative process was not complete. Serial ECoChG recordings may have been more sensitive to this reduction in the number of fibres responding, and may have shown a gradual reduction in the amplitude of the CAP.

Two hypotheses that have been proposed as possible pathophysiological mechanisms of retrograde degeneration in delayed hearing loss may also apply in this case of delayed loss of ABR. It is possible that disturbances of microcirculation of the vasa nervorum of the cochlear nerve due to direct or indirect surgical manipulation, may be the initial insult that triggers nerve degeneration (Levine et al., 1984; Neu et al., 1999; Strauss et al., 2001; Strauss et al., 1991). Alternatively, the mechanism may be direct mechanical damage to the cochlear nerve resulting in a loss of continuity of the axons (Neu et al., 1999; Sekiya & Møller, 1988; Strauss

et al., 1991). It is not possible to determine which mechanism was responsible for the deterioration of ABR in Case 16. Regardless of initial insult, the disruption of the endoneurial vasa nervorum or plasma membrane associated with these events would have allowed a massive release of glutamate to enter the damaged neurons, causing an influx of calcium subsequent cell death (Choi, 1992; Shimamura et al., 2002).

Evidence of a gradual process of retrograde degeneration as the mechanism responsible for reported cases of delayed hearing loss has incited research into pharmacological therapies to prevent the degeneration following the initial insult. Such interventions should be initiated immediately postoperatively due to the narrow therapeutic window in which treatment may be effective in preventing the death of neurons (Bischoff, Romstöck, Fahlbusch, Buchfelder, & Strauss, 2008; Gouveris, Mewes, Maurer, & Mann, 2005). Given that excessive entry of calcium into injured cochlear neurons results in spiral ganglion cell death, preventing this influx of calcium by using calcium channel antagonists has been investigated as a countermeasure to cell death following trauma to the nerve (Sekiya et al., 2002). In particular, recent studies have provided evidence that nimodipine, a calcium channel blocker, administered postoperatively to patients identified by intraoperative ABR as being at risk of delayed hearing loss, can improve hearing outcome (Bischoff et al., 2008; Strauss et al., 2001). These studies also indicate that this treatment must be prophylactic – patients in whom anacusis is confirmed before treatment do not show an improvement in hearing (Bischoff et al., 2008). Thus intraoperative ABR is required to identify patients with a pattern of gradual reversible loss who are classified as at risk of delayed hearing loss, and is necessary to provide treatment to appropriate patients. In Case 16 we documented evidence of a gradual retrograde degeneration of the cochlear nerve in the week following surgery. Specifically, a significant change in the latency of wave I, presumably indicating that the process of degeneration had begun, was observed on postoperative day 3. It is possible that if treatment with a calcium channel blocker had been administered before day 3, this process of degeneration may have been halted. Although in this case, hearing would of course not have been preserved given the immediate postoperative anacusis, it is possible in cases in which a similar pattern of ABR is observed in the presence of measurable hearing, retrograde degeneration could be prevented.

5. SUMMARY OF MAIN FINDINGS

This study aimed to closely monitor auditory responses, using electrophysiological and behavioural techniques, in the early postoperative period following vestibular schwannoma excision. It was hoped that this data would identify patients presenting with a delayed loss of hearing in the early postoperative period, and thus would provide evidence as to the time course of hearing deterioration and whether the site of impairment responsible for this phenomenon is neural or cochlear in origin. It is essential that the causative mechanism of delayed hearing loss is identified in order to prevent delayed hearing loss in the future, either through alterations in surgical techniques or through postoperative pharmacological therapies. Unfortunately, no cases of delayed hearing loss were observed in a series of 19 patients who underwent removal of a vestibular schwannoma at Christchurch Public Hospital during the 11 month period of this study. However, valuable data was collected from 13 cases of immediate postoperative anacusis and six cases of hearing preservation. Given the rates of delayed hearing loss of 13% to 24% reported in the, albeit limited, literature, it is perhaps surprising that no cases were observed in the current series. This suggests that the stricter patient inclusion criteria used in previous reports of delayed hearing loss based on preoperative hearing, tumour size, or both, are likely to have increased the probability of documenting delayed hearing loss.

Although no patients in the present study experienced a delayed loss of behavioural auditory responses, one case of a delayed loss of responses from the cochlear nerve was documented. Case 16 demonstrated a gradual deterioration of ABR wave I over five days following surgery, but maintained evidence of cochlear function. A similar loss of wave I has been reported in cases of delayed hearing loss by Strauss et al. (1991). In contrast to Strauss et al.'s (1991) study, our data includes a measure of cochlear function, and provides the necessary time resolution to observe the gradual loss of cochlear nerve function. The gradual deterioration of ABR wave I together with a functional cochlea is consistent with retrograde degeneration of the cochlear nerve. This degeneration may have been triggered by an initial insult during surgery to the microcirculation of the cochlear nerve, or to the proximal portion of the nerve itself. The presence of a small CAP in the electrocochleogram recorded 12 weeks postoperatively is consistent with the presence of some functional nerve fibres at the extreme periphery of the cochlear nerve, however these were insufficient to generate the far-field spread of neural activity necessary to record ABR wave I. The similarities between the pattern

of ABR recorded in this case and that reported by Strauss et al. (1991) may indicate a common pathophysiological mechanism causing the loss of cochlear nerve function in both this case, and at least some cases of delayed hearing loss.

Of the 13 cases of immediate postoperative anacusis, five were due to transection of the cochlear nerve during surgery. In the remaining eight cases, hearing loss was at least partially due to cochlear impairment in seven cases, neural impairment in one case, and the cause of hearing loss could not be determined in the other two cases due to an absence of preoperative electrophysiological responses. The most probable cause of a loss of cochlear function is transient ischemia to the cochlea resulting from obstruction or vasospasm of the IAA due to surgical manipulation (Colletti et al., 1998). It is also possible that the integrity of the labyrinth was violated during drilling of the IAC, which would result in the loss of all potentials from the cochlea and cochlear nerve. As ABR was absent immediately postoperatively in seven of these eight patients, a concomitant neural origin of hearing loss cannot be ruled out. This may have resulted from direct or indirect trauma to the cochlear nerve causing a conduction block due to disruption of the continuity of the axons (Sekiya & Møller, 1988).

Although measurable hearing was retained postoperatively in six cases, all patients demonstrated a decrease in hearing following surgery, and only three patients had serviceable hearing postoperatively. In one case the loss was primarily of cochlear origin, four cases demonstrated a decrease on cochlear nerve function, and in one case the aetiology of hearing loss could not be identified due to absent electrophysiological responses preoperatively. Although this overall rate of preservation of serviceable hearing seems low, it is consistent with previous studies using the retrosigmoid approach, particularly when the philosophy of attempting hearing preservation in all cases, regardless of preoperative hearing or tumour size, is considered.

5.1. Clinical implications

The single subject design of this study prohibits generalisation of these results to clinical populations. It is, however, possible to draw some predictions from our data of probable clinical implications if our findings were replicated in a larger group study. In particular, the parallels between Case 16 and reports of ABR patterns in cases of delayed hearing loss by

Strauss et al. (1991) highlight the vulnerability of the cochlear nerve during vestibular schwannoma removal and the retrograde degeneration of cochlear nerve function that may result from intraoperative trauma to the nerve or its microvasculature. The gradual nature of this deterioration documented in our study is a positive prognostic factor for the success of vasoactive treatment in preventing the progressive spread of damage to the distal portion of the nerve following initial trauma. More critical than the prevention of nerve degeneration following surgical injury, may be the prevention of such injury occurring. This may be accomplished through changes in surgical techniques, or through monitoring of auditory function throughout surgery and using that information to provide surgeons with guidance as to the impact of their manipulations. Further research is needed to determine the types of modifications in surgical technique that may offer a greater chance of preservation of the cochlear nerve without compromising the primary goals of complete tumour removal with anatomical preservation of the facial nerve. Preservation of the anatomical and functional integrity of the cochlear nerve would also offer the future possibility of cochlear implantation in the affected ear if a hearing loss of cochlear origin was present.

5.2. Limitations

Early postoperative delayed hearing loss has been documented as occurring up to seven days following tumour removal (Neu et al., 1999; Strauss et al., 2001) and may occur later in cases that have not been reported. Many patients in our study were hospitalised, and thus monitored, for only five to six days following surgery, therefore there is a possibility that if a patient had experienced a delayed loss of hearing later than this, it would not have been identified in this study. However, if a gradual deterioration of hearing is responsible for delayed loss, as is proposed based on the results of Case 16, it would be expected that the patient would have shown at least some indication of deterioration of responses within the period of their hospitalisation. Although this may be a consideration in future research, in this study no patients who had initial preservation of hearing were reported to have lost this hearing following discharge from hospital. Ideally, the preservation of hearing, and in particular whether any changes in electrophysiological responses had occurred since discharge, would have been verified in a follow-up assessment approximately three months after surgery. Unfortunately, the large catchment area that Christchurch Hospital services for

vestibular schwannoma removal meant that many of our participants did not reside locally and follow-up was not possible.

The utility of intraoperative ABR data collected in this study was severely limited by the presence of high noise levels and interference in the operating theatre. Clearly, changes to the recording set-up, such as improved shielding of recording equipment, are needed in order to ensure better quality results are obtained. In many studies using intraoperative ABR, the monitoring forms an important function in guiding the surgeon as to when surgical manoeuvres are potentially damaging to the auditory structures. This may mean that positioning of equipment within the operating theatre is more optimal for recording clear responses, and the type of equipment used is better equipped to deal with this challenging recording environment.

A problem inherent in research of the present type is the difficulty in collecting the desired data from each patient at 24-hour intervals. In this study, in some patients data collection was limited by their co-operation or ability to participate, particularly in the first 72 hours postoperatively. Despite this, data was collected with sufficient time resolution that had delayed hearing loss occurred, it would have been detected. Although ideally the initial postoperative behavioural testing would have taken place 24 hours postoperatively to verify that hearing was absent immediately postoperatively, and had not deteriorated by the time the first test was conducted 48-72 hours later, most patients were able to accurately report the occurrence of immediate postoperative anacusis when it occurred. Previous studies, including those of Strauss et al. (1991), Strauss et al (2001) and Neu et al. (1999) used a click simulator to provide an estimate of whether some degree of hearing was present in the intensive care unit immediately postoperatively. Although this cannot provide any information on the configuration of hearing loss, it constitutes an effective way to reduce the problems associated with patient ability to participate in behavioural audiometry immediately after surgery, and may be a useful inclusion in future research.

In Case 16, transtympanic ECochG was used to verify the presence of cochlear function and provide further information to determine the likely site of origin of hearing impairment. Although the procedure was successful in obtaining this data, a preoperative ECochG to use for comparison would have allowed us to document changes in the morphology and amplitude of responses. In addition, repeated ECochG would have allowed more accurate identification of the time course of degeneration of the cochlear nerve in Case 16, given that

the CAP can evidently be recorded with fewer functional nerve fibres than the ABR. However, given the limited availability of a physician with the appropriate expertise to perform electrode placement, this limitation was difficult to address in the present study.

Clearly the absence of any cases of delayed hearing loss in the present study indicates that the small sample size relative to other studies that have reported delayed hearing loss was the primary limitation in fulfilling the aims of this study. This was unavoidable given that all patients presenting for retrosigmoid excision of a vestibular schwannoma for the duration of this study were included. Given the prevalence rate of vestibular schwannomas, and the proportion of these patients that undergo retrosigmoid removal of these tumours, a study lasting longer than this thesis allows is necessary to collect sufficient data. The small number of patients in this study also limited data analysis to a single case study approach. In order to generalise our findings and make recommendations for clinical practice, an analysis of group data is essential.

5.3. Directions for future research

As early postoperative delayed hearing loss was not observed in the present study, the objectives of identifying the time course and pathophysiological mechanisms of this phenomenon remain unachieved. Future research is needed to identify and closely monitor cases of delayed hearing loss in order to define the cause; a necessary precursor to developing successful preventative measures. The case of retrograde degeneration of the cochlear nerve that was documented in this study provides a possible parallel to the reported instances of delayed hearing loss, and supports the assertion of Strauss and colleagues (2001) that the site of origin of such a pattern of loss is neural rather than cochlear. As suggested earlier, differences in patient inclusion criteria most probably contributed to the absence of delayed hearing loss in our series of patients. Future research will most likely benefit not only from larger patient numbers, but from a greater number of patients with serviceable preoperative hearing. Although important data can be collected from patients with Class D hearing and large tumours, the chance of hearing preservation during surgery is low, thus the likelihood of postoperative delayed hearing loss is reduced.

Although defining the pathophysiological mechanisms of delayed hearing loss is essential in developing surgical techniques to reduce the occurrence of this pattern of hearing loss, it has

already been demonstrated that pharmacological therapies can be successful in preventing deterioration of hearing in a certain population of patients, even though the precise mechanism of such loss is unknown (Bischoff et al., 2008; Gouveris et al., 2005; Strauss et al., 2001). The continuation of this research is obviously important, particularly to determine the most beneficial types of treatment and exactly which populations are likely to benefit. Intraoperative monitoring of auditory function will continue to be a vital part of research in this field, both in identifying the surgical manoeuvres that most often trigger delayed hearing loss, and in more clearly identifying the patterns of intraoperative responses that make patients more likely to respond successfully to postoperative therapeutic treatments. Our study highlights the importance of monitoring both cochlear *and* cochlear nerve function in order to gain a complete understanding of the nature of hearing loss. In this respect, ECochG may be the ideal intraoperative and postoperative monitoring technique as it is capable of quickly providing measures of both cochlear and cochlear nerve responses. As was demonstrated in Case 16, transtympanic ECochG is also a more sensitive test of cochlear nerve function in cases of a reduction in the number of neural fibres responding.

Given the much higher proportion of patients with schwannomas originating from the facial nerve in this study than would be predicted based on the extant literature (Grey et al., 1996), further research on the prevalence of facial schwannomas appears necessary. A number of studies on vestibular schwannomas do not document the nerve of origin, while others note that in the case of large tumours several nerves are often involved making the identification of the initial nerve of origin impossible (Khrais et al., 2008). It may be that some of these cases are in reality facial nerve schwannomas. Further research in this area and the investigation of preoperative factors that allow a differential diagnosis to be made are necessary.

Irrespective of their absence from this study, it is clear from the literature that cases of delayed loss of hearing following vestibular schwannoma excision do exist. Surgeons and authors of future studies need to be aware of the possibility of delayed hearing loss and monitor for its occurrence. This awareness is necessary in order to identify and report cases of delayed hearing loss so its prevalence and characteristics may be more accurately defined.

REFERENCES

- Abdala, C. (1996). Distortion product otoacoustic emission (2f1-f2) amplitude as a function of f2/f1 frequency ratio and primary tone level separation in human adults and neonates. *The Journal of the Acoustical Society of America*, 100(6), 3726 - 3740.
- Abramson, M., Stein, B. M., Pedley, T. A., Emerson, R. G., & Wazen, J. J. (1985). Intraoperative BAER monitoring and hearing preservation in the treatment of acoustic neuromas. *Laryngoscope*, 95(11), 1318 - 1322.
- American Academy of Otolaryngology - Head and Neck Surgery (1995). Committee on Hearing and Equilibrium guidelines for the evaluation of hearing preservation in acoustic neuroma (vestibular schwannoma). *Otolaryngology - Head and Neck Surgery*, 113(3), 179-180.
- Anderson, D. E., Leonetti, J., Wind, J. J., Cribari, D., & Fahey, K. (2005). Resection of large vestibular schwannomas: facial nerve preservation in the context of surgical approach and patient-assessed outcome. *Journal of Neurosurgery*, 102(4), 643 - 649.
- Aoyagi, M., Yokota, M., Nakamura, T., Tojima, H., Kim, Y., Suzuki, Y., et al. (1994). Hearing preservation and improvement of auditory brainstem response findings after acoustic neuroma surgery. *Acta Oto-Laryngologica*, 511, 40 - 46.
- Arenberg, I. K., Gibson, W. P., Höhmann, D., & Mihalco, L. L. (1992). International standards for transtympanic electrocochleography. In D. Höhmann (Ed.), *ECoG, OAE and intraoperative monitoring* (pp. 115 - 118). Amsterdam: Klugler.
- Arriaga, M. A., & Chen, D. A. (2001). Facial function in hearing preservation acoustic neurons surgery. *Archives of Otolaryngology - Head and Neck Surgery*, 127(5), 343 - 346.
- Arriaga, M. A., Chen, D. A., & Fukushima, T. (1997). Individualizing hearing preservation in acoustic neuroma surgery. *Laryngoscope*, 107(8), 1043 - 1047.
- Arriaga, M. A., Long, S., & Nelson, R. (1993). Clinical correlates of acoustic neuroma volume. *The American Journal of Otology*, 14(5), 465 - 468.
- ASHA. (1990). Guidelines for screening for hearing impairments and middle ear disorders. *ASHA*, 32(Supp 2), 17 - 24.
- Avan, P., & Bonfils, P. (2005). Distortion-product otoacoustic emission spectra and high-resolution audiometry in noise-induced hearing loss. *Hearing Research*, 209(1-2), 68 - 75.
- Avezaat, C. J. J., & Pauw, B. K. H. (1998). Vestibular schwannomas. In P. J. Vinken, G. W. Bruyn & C. J. Veitch (Eds.), *Neuro-oncology, Part II* (pp. 421 - 464). Philadelphia: Elsevier.
- Axelsson, A., & Ryan, A. (2001). Circulation of the inner ear: comparative study of the vascular anatomy in the mammalian cochlea. In A. Jahn & J. Santos-Sacchi (Eds.), *Physiology of the ear* (pp. 301 - 320). San Diego, CA: Singular.
- Badie, B., Pyle, G. M., Nguyen, P. H., & Hadar, E. J. (2001). Elevation of internal auditory canal pressure by vestibular schwannomas. *Otology & Neurotology*, 22(5), 696 - 700.
- Baloh, R. (1995). Vertebrobasilar insufficiency and stroke. *Otolaryngology - Head and Neck Surgery*, 112(1), 114 - 117.
- Baloh, R., & Honrubia, V. (1990). *Clinical neurophysiology of the vestibular system* (2nd ed.). Philadelphia: FA Davis.
- Barker, F. G., & Ogilvy, C. S. (1996). Efficacy of prophylactic nimodipine for delayed ischemic deficit after subarachnoid hemorrhage: a metaanalysis. *Journal of Neurosurgery*, 84(3), 405 - 414.

- Bartholdi, D., & Schwab, M. E. (1995). Methylprednisolone inhibits early inflammatory processes but not ischemic cell death after experimental spinal cord lesion in the rat. *Brain Research*, 672(1-2), 177 - 186.
- Battaglia, A., Mastrodimos, B., & Cueva, R. (2006). Comparison of growth patterns of acoustic neuromas with and without radiosurgery. *Otology & Neurotology*, 27(5), 705 - 712.
- Bauch, C. D., & Olsen, W. O. (1990). Comparison of ABR amplitudes with TIPtrode and mastoid electrodes. *Ear and Hearing*, 11(6), 463 - 467.
- Beattie, R. C., Garcia, E., & Johnson, A. (1996). Frequency – specific auditory brainstem responses in adults with sensorineural hearing loss. *Audiology*, 35(4), 194 - 203.
- Betchen, S. A., Walsh, J., & Post, K. D. (2005). Long-term hearing preservation after surgery for vestibular schwannoma. *Journal of Neurosurgery*, 102(1), 6 - 9.
- Bird, P. A., & MacFarlane, M. R. (2007). Management of unilateral vestibular schwannoma/acoustic neuroma. *The New Zealand Medical Journal*, 120(1265), 1 - 4.
- Bischoff, B., Romstöck, J., Fahlbusch, R., Buchfelder, M., & Strauss, C. (2008). Intraoperative brainstem auditory evoked potential pattern and perioperative vasoactive treatment for hearing preservation in vestibular schwannoma surgery. *Journal of Neurology, Neurosurgery, and Psychiatry*, 79(2), 170 - 175.
- Bozorg, G. A., Kalamarides, M., Ferrary, E., Bouccara, D., El Gharem, H., Rey, A., et al. (2005). Conservative management versus surgery for small vestibular schwannomas. *Acta Oto-Laryngologica*, 125(10), 1063 - 1068.
- Brackmann, D. E., Owens, R. M., & Fayad, N. M. (2001). Intracanalicular acoustic neuroma. In M. L. Pensak (Ed.), *Controversies in Otolaryngology* (pp. 265 - 269). New York: Thieme.
- Brackmann, D. E., Owens, R. M., Friedman, R. A., Hitselberger, W. E., De la Cruz, A., House, J. W., et al. (2000). Prognostic factors for hearing preservation in vestibular schwannoma surgery. *The American Journal of Otology*, 21(3), 417 - 424.
- Brown, D. J., & Patuzzi, R. B. (2008, 17th February). *Evidence suggesting the cochlear compound action potential is a stationary potential generated across the dura mater*. Paper presented at the 31st MidWinter Meeting of the Association for Research in Otolaryngology, Phoenix, Arizona, USA.
- Brownell, W. E. (1990). Outer hair cell electromotility and otoacoustic emissions. *Ear and Hearing*, 11(2), 82 - 92.
- Brownell, W. E., Bader, C. R., Bertrand, D., & de Ribaupierre, Y. (1985). Evoked mechanical responses of isolated cochlear outer hair cells. *Science*, 227(4683), 194 - 196.
- Brunori, A., Scarano, P., & Chiappetta, F. (1997). Non-acoustic neuroma tumor (NANT) of the cerebello-pontine angle: a 15-year experience. *Journal of Neurosurgical Sciences*, 41(2), 159 - 168.
- Cacace, A. T., Parnes, S. M., Lovely, T. J., & Kalathia, A. (1994). The disconnected ear: phenomenological effects of a large acoustic tumor. *Ear and Hearing*, 15(4), 287 - 298.
- Callan, D. E., Lasky, R. E., & Fowler, C. G. (1999). Neural networks applied to retrocochlear diagnosis. *Journal of Speech and Hearing Research*, 42, 287 - 299.
- Carhart, R. (1957). Clinical determination of abnormal auditory adaptation. *Archives of Otolaryngology*, 65, 32 - 39.
- Cashman, M. Z., & Rossman, R. N. (1983). Diagnostic features of the auditory brainstem response in identifying cerebellopontine angle tumours. *Scandinavian Audiology*, 12(1), 35 - 41.

- Caye-Thomasen, P., Dethloff, T., Hansen, S., Stangerup, S. E., & Thomsen, J. (2007). Hearing in patients with intracanalicular vestibular schwannomas. *Audiology & Neuro-otology*, *12*(1), 1 - 12.
- Chertoff, M. E., Amani-Taleshi, D., Yuqing, G., & Burkard, R. (2002). The influence of inner hair cell loss on the instantaneous frequency of the cochlear microphonic. *Hearing Research*, *173*(1-2), 93 - 100.
- Choi, D. W. (1985). Glutamate neurotoxicity in cortical cell culture is calcium dependent. *Neuroscience Letters*, *58*(3), 293 - 297.
- Choi, D. W. (1992). Excitotoxic cell death. *Journal of Neurobiology*, *23*(9), 1261 - 1276.
- Coats, A. C. (1981). The summing potential and Meniere's disease. I. Summing potential amplitude in Meniere and non-Meniere ears. *Archives of Otolaryngology*, *107*(4), 199 - 208.
- Cohen, N. L., Lewis, W. S., & Ransohoff, J. (1993). Hearing preservation in cerebellopontine angle tumour surgery : The NYU experience 1974 - 1991. *American Journal of Otolaryngology*, *14*(5), 423 - 433.
- Colletti, V., Fiorino, F. G., Carner, M., & Tonoli, G. (1997). Mechanisms of auditory impairment during acoustic neuroma surgery. *Otolaryngology - Head and Neck Surgery*, *117*(6), 596 - 605.
- Colletti, V., Fiorino, F. G., Mocella, S., & Policante, Z. (1998). ECoChG, CNAP and ABR monitoring during vestibular Schwannoma surgery. *Audiology*, *37*(1), 27 - 37.
- Conlon, B. J., & Gibson, W. P. (1999). Meniere's disease: the incidence of hydrops in the contralateral asymptomatic ear. *Laryngoscope*, *109*(11), 1800 - 1802.
- Conlon, B. J., & Gibson, W. P. (2000). Electrocochleography in the diagnosis of Meniere's disease. *Acta Oto-Laryngologica*, *120*(4), 480 - 483.
- Da Cruz, M. J., Hardy, D. G., & Moffat, D. A. (2000). Clinical presentation of a group of NF2 patients to a tertiary referral skull base unit. *British Journal of Neurosurgery*, *14*, 101 - 104.
- Dallos, P. (1973). *The auditory periphery: biophysics and physiology*. New York: Academic Press.
- Dallos, P. (1992). The Active Cochlea. *Journal of Neuroscience*, *12*(12), 4575 - 4585.
- Dallos, P., Schoeny, Z. G., & Cheatham, M. A. (1972). Cochlear summing potentials. Descriptive aspects. *Acta Oto-Laryngologica*, *302*, 1 - 46.
- Danner, C., Mastrodimos, B., & Cueva, R. A. (2004). Comparison of direct eighth nerve monitoring and auditory brainstem response in hearing preservation surgery for vestibular schwannoma. *Otolaryngology & Neurotology*, *25*(5), 26 - 32.
- Darrow, K. N., Maison, S. F., & Liberman, M. C. (2007). Selective removal of lateral olivocochlear efferents increases vulnerability to acute acoustic injury. *Journal of Neurophysiology*, *97*(2), 1775 - 1785.
- Darwish, B. S., Bird, P. A., Goodisson, D. W., Bonkowski, J. A., & MacFarlane, M. R. (2005). Facial nerve function and hearing preservation after retrosigmoid excision of vestibular schwannoma: Christchurch Hospital experience with 97 patients. *ANZ Journal of Surgery*, *75*(10), 893 - 896.
- Dau, T., Wegner, O., Mellert, V., & Kollmeier, B. (2000). Auditory brainstem responses with optimized chirp signals compensating basilar-membrane dispersion. *The Journal of the Acoustical Society of America*, *107*(3), 1530 - 1540.
- Dauman, R., Aran, J. M., & Portmann, M. (1988). Limits of ABR and contribution of transtympanic electrocochleography in the assessment of cerebellopontine angle tumours. *Clinical Otolaryngology and Allied Sciences*, *13*(2), 107 - 114.

- Dauman, R., & Charlet de Sauvage, R. (1984). Continuous monitoring of SP and CAP during glycerol test in Menière's disease: preliminary results. *Revue de laryngologica - otologie - rhinologie*, *105*(2), 219 - 221.
- De Moura, L. F. (1967). Inner ear pathology in acoustic neurinoma. *Archives of Otolaryngology*, *85*(2), 125 - 133.
- De Ridder, D., Ryu, H., Møller, A. R., Nowe, V., Van de Heyning, P., & Verlooy, J. (2004). Functional anatomy of the human cochlear nerve and its role in microvascular decompressions for tinnitus. *Neurosurgery*, *54*(2), 381 - 388.
- Deans, J. A., Hill, J., Birchall, J. P., Davison, T., Fitzgerald, J. E., & Elliott, C. (1996). The effect of electrode position in electrocochleography. *Clinical Otolaryngology and Allied Sciences*, *21*(4), 317 - 323.
- Department of Neurosurgery, University of Florida (2008). Patient information: Acoustic neuroma. Retrieved December 15, 2008, from <http://www.neurosurgery.ufl.edu/Patients/acoustic.shtml>
- Desmedt, J. E. (1962). Auditory-Evoked Potentials from Cochlea to Cortex as Influenced by Activation of the Efferent Olivo-Cochlear Bundle. *The Journal of the Acoustical Society of America*, *34*(9b), 1478 - 1496.
- Dolan, D. F., Guo, M. H., & Nuttall, A. L. (1997). Frequency-dependent enhancement of basilar membrane velocity during olivocochlear bundle stimulation. *The Journal of the Acoustical Society of America*, *102*(6), 3587 - 3596.
- Dolan, D. F., & Nuttall, A. L. (1988). Masked cochlear whole-nerve response intensity functions altered by electrical stimulation of the crossed olivocochlear bundle. *The Journal of the Acoustical Society of America*, *83*(3), 1081 - 1086.
- Don, M., & Elberling, C. (1994). Evaluating residual background noise in human auditory brain-stem responses. *The Journal of the Acoustical Society of America*, *96* (5), 2746 - 2757.
- Don, M., & Kwong, B. (2002). Auditory Brainstem Response: Differential diagnosis. In J. Katz (Ed.), *Handbook of Clinical Audiology 5th ed* (pp. 274 - 297). Baltimore, MA: Lippincott Williams & Wilkins.
- Don, M., Ponton, C. W., Eggermont, J. J., & Masuda, A. (1994). Auditory brainstem response (ABR) peak amplitude variability reflects individual differences in cochlear response times. *The Journal of the Acoustical Society of America*, *96*(6), 3476 - 3491.
- Dorn, P. A., Konrad-Martin, D., Neely, S. T., Keefe, D. H., Cyr, E., & Gorga, M. P. (2001). Distortion product otoacoustic emission input/output functions in normal-hearing and hearing-impaired human ears. *The Journal of the Acoustical Society of America*, *110*(6), 3119 - 3131.
- Dornhoffer, J. L., Helms, J., & Hoehmann, D. H. (1995). Hearing preservation in acoustic tumor surgery: results and prognostic factors. *Laryngoscope*, *105*(2), 184 - 187.
- Durrant, J. D., & Dallos, P. (1974). Modification of DIF summing potential components by stimulus biasing. *The Journal of the Acoustical Society of America*, *56*(2), 562 - 570.
- Durrant, J. D., & Ferraro, J. A. (1991). Analog model of human click-elicited SP and effects of high-pass filtering. *Ear and Hearing*, *12*(2), 144 - 148.
- Durrant, J. D., Wang, J., Ding, D., & Salvi, R. J. (1998). Are inner or outer hair cells the source of summing potentials recorded from the round window? *The Journal of the Acoustical Society of America*, *104*(1), 370 - 377.
- Eckermeier, L., Pirsig, W., & Mueller, D. (1979). Histopathology of 30 non-operated acoustic schwannomas. *Archives of Oto-rhino-laryngology*, *222*(1), 1 - 9.
- Emerson, R. G., Brooks, E. B., Parker, S. W., & Chiappa, K. H. (1982). Effects of click polarity on brainstem auditory evoked potentials in normal subjects and patients:

- unexpected sensitivity of wave V. *Annals of the New York Academy of Sciences*, 388, 710 - 721.
- Enticott, J. C., O'Leary, S. J., & Briggs, R. J. (2005). Effects of vestibulo-ocular reflex exercises on vestibular compensation after vestibular schwannoma surgery. *Otology & Neurotology*, 26(2), 265 - 269.
- Fahlbusch, R., Neu, M., & Strauss, C. (1998). Preservation of Hearing in Large Acoustic Neurinomas Following Removal via Suboccipito-Lateral Approach. *Acta Neurochirurgica*, 140, 771 - 778.
- Ferber-Viart, C., Laoust, L., Boulud, B., Duclaux, R., & Dubreuil, C. (2000). Acuteness of preoperative factors to predict hearing preservation in acoustic neuroma surgery. *Laryngoscope*, 110(1), 145 - 150.
- Ferguson, M. A., O'Donoghue, G. M., & Owen, V. (2001). Contralateral suppression of transient evoked otoacoustic emissions in patients with cerebello-pontine angle tumor. *Ear and Hearing*, 22(3), 173 - 181.
- Ferraro, J. A., Best, L. G., & Arenberg, I. K. (1983). The use of electrocochleography in the diagnosis, assessment, and monitoring of endolymphatic hydrops. *Otolaryngologic Clinics of North America*, 16(1), 69 - 82.
- Ferraro, J. A., Blackwell, W. L., Mediavilla, S. J., & Thedinger, B. S. (1994). Normal summing potential to tone bursts recorded from the tympanic membrane in humans. *Journal of the American Academy of Audiology*, 5(1), 17 - 23.
- Ferraro, J. A., & Durrant, J. D. (2002). Electrocochleography. In J. Katz (Ed.), *Handbook of clinical audiology 5th ed* (pp. 249 - 273). Baltimore, MA: Lippincott Williams and Wilkins.
- Ferraro, J. A., & Durrant, J. D. (2006). Electrocochleography in the evaluation of patients with Ménière's disease/endolymphatic hydrops. *Journal of the American Academy of Audiology*, 17(1), 45 - 68.
- Ferraro, J. A., & Ferguson, R. (1989). Tympanic ECochG and conventional ABR: a combined approach for the identification of wave I and the I-V interwave interval. *Ear and Hearing*, 10(3), 161 - 166.
- Ferraro, J. A., & Krishnan, G. (1997). Cochlear potentials in clinical audiology. *Audiology & Neuro-otology*, 2(5), 241 - 256.
- Fex, J. (1962). Auditory activity in centrifugal and centripetal cochlear fibres in cat. A study of a feedback system. *Acta Physiologica Scandinavica. Supplementum*, 189, 1 - 68.
- Fex, J. (1963). Crossed cochlear efferents activated by sound through both ears. *Acta Physiologica Scandinavica*, 59, 41.
- Fex, J. (1967). Efferent inhibition in the cochlea related to hair-cell dc activity: study of postsynaptic activity of the crossed olivocochlear fibres in the cat. *The Journal of the Acoustical Society of America*, 41(3), 666 - 675.
- Fisch, U., Dobozi, M., & Greig, D. (1972). Degenerative changes of the arterial vessels of the internal auditory meatus during the process of aging. A histological study. *Acta Otolaryngology*, 73(2), 259 - 266.
- Fischer, G., Fischer, C., & Remond, J. (1992). Hearing preservation in acoustic neurinoma surgery. *Journal of Neurosurgery*, 76(6), 910 - 917.
- Fiscina, F., Gouveris, H., & Mann, W. (2007). Influence of nerve branch of origin and extracanalicular extension of the tumor on hearing after middle fossa removal of vestibular schwannoma. *Acta Oto-Laryngologica*, 127(10), 1058 - 1061.
- Fobel, O., & Dau, T. (2004). Searching for the optimal stimulus eliciting auditory brainstem responses in humans. *The Journal of the Acoustical Society of America*, 116(4), 2213 - 2222.

- Folsom, R. C., & Owsley, R. M. (1987). N1 action potentials in humans. Influence of simultaneous contralateral stimulation. *Acta Otolaryngology*, 103(3-4), 262 - 265.
- Forton, G. E., Cremers, C. W., & Offeciers, E. E. (2004). Acoustic neuroma ingrowth in the cochlear nerve: does it influence the clinical presentation? *Annals of Otolology, Rhinology & Laryngology*, 113(7), 582 - 586.
- Frerebeau, P., Benezech, J., Uziel, A., Coubes, P., Segnarbieux, F., & Malonga, M. (1987). Hearing preservation after acoustic neurinoma operation. *Neurosurgery*, 21(1), 197 - 200.
- Friedman, R. A., Brackmann, D. E., & Mills, D. (1998). Auditory-nerve integrity after middle-fossa acoustic-tumor removal. *Otolaryngology - Head and Neck Surgery*, 119(6), 588 - 592.
- Galambos, R. (1956). Suppression of auditory nerve activity by stimulation of efferent fibers to cochlea. *Journal of Neurophysiology*, 19(5), 424 - 437.
- Gardner, G., & Robertson, J. H. (1988). Hearing preservation in unilateral acoustic neuroma surgery. *The Annals of otology, Rhinology, and Laryngology*, 97(1), 55 - 66.
- Gaskill, S. A., & Brown, A. M. (1990). The behavior of the acoustic distortion product, 2f1-f2, from the human ear and its relation to auditory sensitivity *The Journal of the Acoustical Society of America*, 88(2), 821 - 839.
- Gertner, A. (1981). Site of lesion testing findings in a routine test battery. *American Journal of Otolaryngology*, 2, 219 - 222.
- Gerull, G., Morwinski, D., & Thoma, J. (1982). Diagnosis of abnormal hearing adaptation by brainstem potential's. *Scandinavian Audiology*, 11, 205 - 209.
- Gibson, W. P. (1993). A comparison of clicks versus tone bursts in the diagnosis of endolymphatic hydrops. In D. Höhmann (Ed.), *ECoG, OAE and Intraoperative Monitoring* (pp. 55 - 59). Amsterdam: Kluwer.
- Gibson, W. P., & Arenberg, I. K. (1990). Electrocochleography in the diagnosis of Ménière's disease: aspects of the summing potential using click stimuli. In I. K. Arenberg (Ed.), *Surgery of the Inner Ear*. Amsterdam: Kugler.
- Gibson, W. P., Moffat, D. A., & Ramsden, R. T. (1977). Clinical electrocochleography in the diagnosis and management of Meneère's disorder. *Audiology*, 16(5), 389 - 401.
- Gibson, W. P., & Prasher, D. K. (1983). Electrocochleography and its role in the diagnosis and understanding of Meniere's disease. *Otolaryngologic Clinics of North America*, 16(1), 59 - 68.
- Gibson, W. P., Prasher, D. K., & Kilkenny, G. P. (1983). Diagnostic significance of transtympanic electrocochleography in Menière's disease. *The Annals of Otolology, Rhinology, and Laryngology*, 92(2), 155 - 159.
- Gjuric, M., Mitrecic, M. Z., Greess, H., & Berg, M. (2007). Vestibular schwannoma volume as a predictor of hearing outcome after surgery. *Otology & Neurotology*, 28(6), 822 - 827.
- Glasscock, M. E., Hays, J. W., Minor, L. B., Haynes, D. S., & Carrasco, V. N. (1994). Preservation of hearing in surgery for acoustic neuromas. *Journal of Neurosurgery*, 80(1), 170 - 171.
- Glasscock, M. E., McKennan, K. X., & Levine, S. C. (1987). Acoustic neuroma surgery: the results of hearing conservation surgery. *Laryngoscope*, 97(7), 785 - 789.
- Goodhill, V. (1979). Progress in Otolology. *The Annals of Otolology, Rhinology, and Laryngology*, 88(5), 658 - 663.
- Gorga, M. P., Kaminski, J. R., Beauchaine, K. A., & Jesteadt, W. (1988). Auditory brainstem response to tone-bursts in normally hearing subjects. *Journal of Speech and Hearing Research*, 31, 87 - 97.

- Gorga, M. P., Neely, S. T., & Dorn, P. A. (1999). Distortion product otoacoustic emission test performance for a priori criteria and for multifrequency audiometric standards. *Ear and Hearing, 20*(4), 345 - 362.
- Gorga, M. P., Neely, S. T., Dorn, P. A., & Hoover, B. (2003). Further efforts to predict pure-tone thresholds from distortion product otoacoustic emission input/output functions. *The Journal of the Acoustical Society of America, 113*(6), 3275 - 3284.
- Gorga, M. P., Neely, S. T., Ohlrich, B., Hoover, B., Redner, J., & Peters, J. (1997). From laboratory to clinic: a large scale study of distortion product otoacoustic emissions in ears with normal hearing and ears with hearing loss. *Ear and Hearing, 18*(6), 440 - 455.
- Gouveris, H., & Mann, W. (2004). Increased Amplitudes of Distortion Product Otoacoustic Emissions in Patients with Unilateral Acoustic Neuroma. *Journal for Oto-Rhino - Laryngology and its Related Specialties, 66*(6), 302 - 305.
- Gouveris, H., & Mann, W. (2009). Association between surgical steps and intraoperative auditory brainstem response and electrocochleography waveforms during hearing preservation vestibular schwannoma surgery. *European Archives of Oto-Rhino-Laryngology, 266*(2), 225 - 229.
- Gouveris, H., Mewes, T., Maurer, J., & Mann, W. (2005). Steroid and Vasoactive Treatment for Acute Deafness after Attempted Hearing Preservation Acoustic Neuroma Surgery. *Journal for Oto - Rhino - Laryngology and Its Related Specialties, 67*(1), 30 - 33.
- Gouveris, H., Victor, A., & Mann, W. (2007). Cochlear origin of early hearing loss in vestibular schwannoma. *Laryngoscope, 117*(4), 680 - 683.
- Graamans, K., Van Dijk, J. E., & Janssen, L. W. (2003). Hearing deterioration in patients with a non-growing vestibular schwannoma. *Acta Oto-Laryngologica, 123*(1), 51 - 54.
- Grey, P. L., Moffat, D. A., & Hardy, D. G. (1996). Surgical results in unusual cerebellopontine angle tumours. *Clinical Otolaryngology and Allied Sciences, 21*(3), 237 - 243.
- Groff, J. A., & Liberman, M. C. (2003). Modulation of cochlear afferent response by the lateral olivocochlear system: activation via electrical stimulation of the inferior colliculus. *Journal of Neurophysiology, 90*(5), 3178 - 3200.
- Guinan, J. J. (2006). Olivocochlear efferents: anatomy, physiology, function, and the measurement of efferent effects in humans. *Ear and Hearing, 27*(6), 589 - 607.
- Guinan, J. J., Warr, W. B., & Norris, B. E. (1983). Differential olivocochlear projections from lateral versus medial zones of the superior olivary complex. *The Journal of Comparative Neurology, 221*(3), 358 - 370.
- Hall, J. W. (2000). *Handbook of Otoacoustic Emissions*. San Diego, CA: Singular Publishing.
- Hall, J. W. (2006). *Handbook for Auditory Evoked Responses*. New York: Allyn & Bacon.
- Harbert, F., & Young, I. M. (1964). Threshold auditory adaptation measured by tone decay and Bekesey audiometry. *Annals of Otolaryngology, Rhinology & Laryngology, 73*, 48 - 60.
- Harner, S. G., Fabry, D. A., & Beatty, C. W. (2000). Audiometric findings in patients with acoustic neuroma. *American Journal of Audiology, 21*(3), 405 - 411.
- Harris, F. P. (1990). Distortion-product otoacoustic emissions in humans with high frequency sensorineural hearing loss. *Journal of Speech and Hearing Research, 33*(3), 594 - 600.
- Hashikawa, T., & Kawamura, K. (1983). Retrograde labeling of ascending and descending neurons in the inferior colliculus. A fluorescent double labelling study in the cat. *Experimental Brain Research, 49*(3), 457 - 461.
- Hashimoto, S., Toshima, M., & Sakurada, T. (1991). Strategies for early diagnosis of acoustic neuroma. *Acta Oto-Laryngologica, 481*, 567 - 569.

- Hatayama, T., Sekiya, T., Suzuki, S., & Iwabuchi, T. (1999). Effect of compression on the cochlear nerve: a short- and long-term electrophysiological and histological study. *Neurological Research*, 21(6), 599 - 610.
- Hecht, C. S., Honrubia, V. F., Wiet, R. J., & Sims, H. S. (1997). Hearing preservation after acoustic neuroma resection with tumor size used as a clinical prognosticator. *Laryngoscope*, 107(8), 1122 - 1126.
- Hood, J. D. (1955). Auditory fatigue and adaptation in the differential diagnosis of end-organ disease. *Annals of Otolaryngology, Rhinology & Laryngology*, 64, 507 - 518.
- Hu, X., Evans, B. N., & Dallos, P. (1999). Direct visualisation of Organ of Corti kinematics in hemicochlea. *The Journal of Neurophysiology*, 82(5), 2798 - 2807.
- Hurd, L. B., Hutson, K. A., & Morest, D. K. (1999). Cochlear nerve projections to the small cell shell of the cochlear nucleus: the neuroanatomy of extremely thin sensory axons. *Synapse*, 33(2), 83 - 117.
- Hyde, M. L., & Blair, R. L. (1981). The auditory brainstem response in neuro-otology: perspectives and problems. *Journal of Otolaryngology*, 10(2), 117 - 125.
- Jackler, R. K. (2000). Audiologic diagnosis of acoustic neuroma. In *Neurotology* (pp. 743 - 785). New York: Mosby.
- Jackler, R. K., & Pitts, L. H. (2008). Selection of surgical approach to acoustic neuroma. *Neurosurgery clinics of North America*, 19(2), 217 - 238.
- Jacob, A., Robinson, L. L., Bortman, J. S., Yu, L., Dodson, E. E., & Welling, B. (2007). Nerve of origin, tumor size, hearing preservation, and facial nerve outcomes in 359 vestibular schwannoma resections at a tertiary care academic center. *Laryngoscope*, 117, 2087 - 2092.
- Jerger, J. F. (1960). Observations on auditory behavior in lesions of the central auditory pathways. *AMA Archives of Otolaryngology*, 71, 797 - 806.
- Jewett, D. L., Romano, M. N., & Williston, J. S. (1970). Human auditory evoked potentials: possible brain stem components detected on the scalp. *Science*, 167(24), 1517 - 1518.
- Josey, A. F. (1987). Audiologic manifestations of tumors of the VIIIth nerve. *Ear and Hearing*, 8(4), 19s - 21s.
- Josey, A. F., Glasscock, M. E., & Jackson, C. G. (1988). Preservation of hearing in acoustic tumor surgery: audiologic indicators. *The Annals of Otolaryngology, Rhinology, and Laryngology*, 97(6), 626 - 630.
- Junius, D., & Dau, T. (2005). Influence of cochlear travelling wave and neural adaptation on auditory brainstem responses. *Hearing Research*, 205(1), 53 - 67.
- Kaga, K., Iwasaki, S., Tamura, A., Suzuki, J., & Haebara, H. (1997). Temporal bone pathology of acoustic neuroma correlating with presence of electrocochleography and absence of auditory brainstem response. *The Journal of Laryngology and Otolaryngology*, 111(10), 967 - 972.
- Kawase, T., & Liberman, M. C. (1993). Antimasking effects of the olivocochlear reflex. I. Enhancement of compound action potentials to masked tones. *Journal of Neurophysiology*, 70(6), 2519 - 2532.
- Kaylie, D. M., Gilbert, E., Horgan, M. A., Delashaw, J. B., & McMenomey, S. O. (2001). Acoustic Neuroma Surgery Outcomes. *Otolaryngology & Neurotology*, 22(5), 686 - 689.
- Kemp, D. T. (1978). Stimulated acoustic emissions from within the human auditory system. *The Journal of the Acoustical Society of America*, 64(5), 1386 - 1391.
- Kentala, E., & Pyykko, I. (2001). Clinical picture of vestibular schwannoma. *Auris Nasus Larynx*, 28(1), 15 - 22.
- Khrais, T., Romano, G., & Sanna, M. (2008). Nerve origins of vestibular schwannoma: A prospective study. *Journal of Laryngology & Otolaryngology*, 122(2), 128 - 131.

- Khrais, T., & Sanna, M. (2006). Hearing preservation surgery in vestibular schwannoma. *The Journal of Laryngology & Otology*, 120, 366 - 370.
- Kim, A. H., Edwards, B. M., Telain, S. A., Kileny, P. R., & Arts, H. A. (2006). Transient evoked otoacoustic emissions pattern as a prognostic indicator for hearing preservation in acoustic neuroma surgery. *Otology & Neurotology*, 27(3), 372 - 379.
- Kimura, R. (1986). Animal models of inner ear vascular disturbances. *American Journal of Otolaryngology*, 7(2), 130 - 139.
- Kimura, R., & Perlman, H. B. (1958). Arterial obstruction of the labyrinth. I. Cochlear changes. *The Annals of Otology, Rhinology, and Laryngology*, 67(1), 5 - 24.
- Kimura, R., & Wersall, J. (1962). Termination of the olivo-cochlear bundle in relation to the outer hair cells of the organ of Corti in guinea pig. *Acta Oto-Laryngologica*, 55, 11 - 32.
- Komatsuzaki, A., & Tsunoda, A. (2001). Nerve origin of the acoustic neuroma. *Journal of Laryngology & Otology*, 115, 376 - 379.
- Koos, W. T., & Perneczky, A. (1985). Suboccipital approach to acoustic neurinomas with emphasis on preservation of facial nerve and cochlear nerve function. In R. W. Rand (Ed.), *Microneurosurgery* (pp. 335 - 365). St Louis: Mosby Co.
- Kujawa, S. G., & Liberman, M. C. (1997). Conditioning-related protection from acoustic injury: effects of chronic deafferentation and sham surgery. *Journal of Neurophysiology*, 78(6), 3095 - 3106.
- Kulecki, S., Terlemez, S., Ciprut, A., & Akdus, F. (2007). 500 Hz logon versus click ABR maturation. *International Journal of Pediatric Otolaryngology*, 71(5), 775 - 779.
- Kveton, J. F. (1990). Delayed spontaneous return of hearing after acoustic tumor surgery: evidence for cochlear nerve conduction block. *Laryngoscope*, 100(5), 473 - 476.
- Lambert, T. R., & Ruth, R. A. (1988). Simultaneous recording of noninvasive ECoG and ABR for use in intraoperative monitoring. *Otolaryngology - Head and Neck Surgery*, 98(6), 575 - 580.
- Lang, J. (1985). Anatomy of the brainstem and the lower cranial nerves, vessels, and surrounding structures. *The American Journal of Otology*, 6(6), 1 - 19.
- Lapsiwala, S. B., Pyle, G. M., Kaemmerle, A. W., Sasse, F. J., & Badie, B. (2002). Correlation between auditory function and internal auditory canal pressure in patients with vestibular schwannomas. *Journal of Neurosurgery*, 96(5), 872 - 876.
- Lassaletta, L., Fontes, L., Melcon, E., Sarria, M. J., & Gavilan, J. (2003). Hearing preservation with the retrosigmoid approach for vestibular schwannoma: Myth or reality? *Otolaryngology - Head and Neck Surgery*, 129(4), 397 - 401.
- Le Prell, C. G., Halsey, K., Hughes, L. F., Dolan, D. F., & Bledsoe, S. C. (2005). Disruption of lateral olivocochlear neurons via a dopaminergic neurotoxin depresses sound-evoked auditory nerve activity. *Journal of The Association for research in Otolaryngology*, 6(1), 48 - 62.
- Le Prell, C. G., Shore, S. E., Hughes, L. F., & Bledsoe, S. C. (2003). Disruption of lateral efferent pathways: functional changes in auditory evoked responses. *Journal of the Association for Research in Otolaryngology*, 4(2), 276 - 290.
- Legatt, A. D. (2002). Mechanisms of intraoperative brainstem auditory evoked potential changes. *Journal of Clinical Neurophysiology*, 19(5), 396 - 408.
- Legatt, A. D., Arezzo, J. C., & Vaughan, H. G. (1988). The anatomic and physiologic bases of brain stem auditory evoked potentials. *Neurologic Clinics*, 6(4), 681 - 704.
- Lenarz, T., & Ernst, A. (1992). Intraoperative monitoring by transtympanic electrocochleography and brainstem electrical response audiometry in acoustic neuroma surgery. *European Archives of Oto-Rhino-Laryngology*, 249, 257 - 262.

- Levine, R. A., Bu-Saba, N., & Brown, M. C. (1993). Laser-Doppler measurements and electrocochleography during ischemia of the guinea pig cochlea: implications for hearing preservation in acoustic neuroma surgery. *The Annals of Otology, Rhinology, and Laryngology*, 102(2), 127 - 136.
- Levine, R. A., Ojemann, R. G., Montgomery, W. W., & McGaffigan, P. M. (1984). Monitoring auditory evoked potentials during acoustic neuroma surgery. Insights into the mechanism of the hearing loss. *Annals of Otology, Rhinology & Laryngology*, 93(2), 116 - 123.
- Lieberman, M. C. (1991). The olivocochlear efferent bundle and susceptibility of the inner ear to acoustic injury. *Journal of Neurophysiology*, 65(1), 123 - 132.
- Lieberman, M. C., & Brown, M. C. (1986). Physiology and anatomy of single olivocochlear neurons in the cat. *Hearing Research*, 24(1), 17 - 36.
- Lieberman, M. C., Dodds, L. W., & Pierce, S. (1990). Afferent and efferent innervation of the cat cochlea: quantitative analysis with light and electron microscopy. *The Journal of Comparative Neurology*, 301(3), 443 - 460.
- Lightfoot, G. R. (1992). ABR screening for acoustic neuroma: the role of rate-induced latency shift measurements. *British Journal of Audiology*, 26, 217 - 227.
- Magnan, J., Barbieri, M., Mora, R., Murphy, S., Meller, R., Bruzzo, M., et al. (2002). Retrosigmoid approach for small and medium-sized acoustic neuromas. *Otology & Neurotology*, 23(2), 141 - 145.
- Mahmud, M. R., Khan, A. M., & Nadol, J. B. (2003). Histopathology of the inner ear in unoperated acoustic neuroma. *The Annals of Otology, Rhinology, and Laryngology*, 112(11), 979 - 986.
- Maison, S. F., & Liberman, M. C. (2000). Predicting vulnerability to acoustic injury with a noninvasive assay of olivocochlear reflex strength. *The Journal of Neuroscience*, 20(12), 4701 - 4707.
- Marchbanks, R. J., Reid, A., Martin, A. M., Brightwell, A. P., & Bateman, D. (1987). The effect of raised intracranial pressure on intracochlear fluid pressure: three case studies. *British Journal of Audiology*, 21(2), 127 - 130.
- Martin, W., & Shi, B. Y. (2006). Auditory Evoked Potentials Monitoring. In R. F. Burkard, J. J. Eggermont & M. Don (Eds.), *Auditory Evoked Potentials* (pp. 355 - 384). Philadelphia: Lippincott Williams & Wilkins.
- Martini, A., & Prosser, S. (2003). Disorders of the inner ear in adults. In L. Luxton, J. M. Furman, A. Martini & D. Stephens (Eds.), *Textbook of Audiological Medicine: Clinical Aspects of Hearing and Balance* (pp. 451 - 476). London: Martin Dunitz.
- Massager, N., Nissim, O., Delbrouck, C., Devriendt, D., David, P., Desmedt, F., et al. (2006). Role of intracanalicular volumetric and dosimetric parameters on hearing preservation after vestibular schwannoma radiosurgery. *International Journal of Radiation Oncology, Biology, Physics*, 64(5), 1331 - 1340.
- Matsunaga, T., & Kanzaki, J. (2000). Morphological evidence that impaired intraneural microcirculation is a possible mechanism of eighth nerve conduction block in acoustic neuromas. *European Archives of Oto-Rhino-Laryngology*, 257(8), 412 - 417.
- Matsunaga, T., Kanzaki, J., & Hosoda, Y. (1996). The vasculature of the peripheral portion of the human eighth cranial nerve. *Hearing Research*, 101(1-2), 119 - 131.
- Matsunaga, T., Kanzaki, J., & Igarashi, M. (1995). The limitations of hearing preservation in acoustic neuroma surgery: histological study of the interface between the eighth cranial nerve and the tumor. *Acta Oto-Laryngologica*, 115(2), 269 - 272.
- Matthies, C., & Samii, M. (1997). Management of vestibular schwannomas (acoustic neuromas): the value of neurophysiology for intraoperative monitoring of auditory function in 200 cases. *Neurosurgery*, 40(3), 459 - 466.

- Maurer, J., Hinni, M., Beck, A., & Mann, W. (1995). Effects of contralateral white noise stimulation on transitory evoked otoacoustic emissions in patients with acoustic neuroma. *Otolaryngology - Head and Neck Surgery*, *112*(3), 369 - 374.
- McElveen, J. T., Wilkins, R. H., Erwin, A. C., & Woldford, R. D. (1991). Modifying the translabyrinthine approach to preserve hearing during acoustic tumour surgery. *The Journal of Laryngology and Otology*, *105*(1), 34 - 37.
- Meyer, T. A., Canty, P. A., Wilkinson, E. P., Hansen, M. R., Rubinstein, D., & Gantz, B. J. (2006). Small acoustic neuromas: surgical outcomes versus observation or radiation. *Otology & Neurotology*, *27*(3), 380 - 392.
- Moffat, D. A., Baguley, D. M., Von Blumenthal, H., Irving, R. M., & Hardy, D. G. (1994). Sudden deafness in vestibular schwannoma. *The Journal of Laryngology and Otology*, *108*(2), 116 - 119.
- Moffat, D. A., da Cruz, M. J., Baguley, D. M., Beynon, G. J., & Hardy, D. G. (1999). Hearing preservation in solitary vestibular schwannoma surgery using the retrosigmoid approach. *Otolaryngology - Head and Neck Surgery*, *121*(6), 781 - 788.
- Mohr, G., Sade, B., Dufour, J. J., & Rappaport, J. M. (2005). Preservation of hearing in patients undergoing microsurgery for vestibular schwannoma: degree of meatal filling. *Journal of Neurosurgery*, *102*(1), 1 - 5.
- Møller, A. R. (2000). *Hearing: its physiology and pathophysiology*. New York: Academic Press.
- Møller, A. R., & Jannetta, P. J. (1983). Monitoring auditory functions during cranial nerve microvascular decompression operations by direct recording from the eighth nerve. *Journal of Neurosurgery*, *59*(3), 493 - 499.
- Mom, T., Telischi, F. F., Martin, G. K., & Lonsbury-Martin, B. L. (1999). Measuring the cochlear blood flow and distortion-product otoacoustic emissions during reversible cochlear ischemia: a rabbit model. *Hearing Research*, *133*(1-2), 40 - 52.
- Morales-Garcia, C., & Hood, L. J. (1972). Tone decay test in neuro - otology diagnosis. *Archives of Otolaryngology*, *96*, 231 - 247.
- Morawski, K., Namyslowski, G., Lisowska, G., Bazowski, P., Kwiek, S., & Telischi, F. F. (2004). Intraoperative monitoring of cochlear function using distortion product otoacoustic emissions (DPOAEs) in patients with cerebellopontine angle tumors. *Otology & Neurotology*, *25*(5), 818 - 825.
- Morawski, K., Telischi, F. F., Merchant, F., Abiy, L. W., Lisowska, G., & Namyslowski, G. (2003a). Role of mannitol in reducing postischemic changes in distortion-product otoacoustic emissions (DPOAEs): a rabbit model. *Laryngoscope*, *113*(9), 1615 - 1622.
- Morawski, K., Telischi, F. F., Merchant, F., Namyslowski, G., Lisowska, G., & Lonsbury-Martin, B. L. (2003b). Preventing internal auditory artery vasospasm using topical papaverine: an animal study. *Otology & Neurotology*, *24*(6), 918 - 926.
- Morlet, T., Dubreuil, C., Duclaux, R., & Ferber-Viart, C. (2003). Preoperative Speech and Pure-Tone Audiometry in Four Types of Patients with Acoustic Neuroma. *American Journal of Otolaryngology*, *24*(5), 297 - 305.
- Morrison, A. W., Gibson, W. P., & Beagley, H. A. (1976). Transtympanic electrocochleography in the diagnosis of retrocochlear tumours. *Clinical Otolaryngology and Allied Sciences*, *1*(2), 153 - 167.
- Moulin, A., Bera, J. C., & Collet, L. (1994). Distortion product otoacoustic emissions and sensorineural hearing loss. *Audiology*, *33*(6), 305 - 326.
- Musiek, F. E., & Baran, J. A. (2007). *The Auditory System, Anatomy, Physiology and Clinical Correlates*. Boston, MA: Allyn & Bacon.

- Mustain, W. D., al-Mefty, O., & Anand, V. K. (1992). Inconsistencies in the correlation between loss of brain stem auditory evoked response waves and postoperative deafness. *Journal of Clinical Monitoring*, 8(3), 231 - 235.
- Nadol, J. B. (1993). Hearing loss. *The New England Journal of Medicine*, 329(15), 1092 - 1102.
- Nadol, J. B., Chiong, C. M., Ojemann, R. G., McKenna, M. J., Martuza, R. L., Montgomery, W. W., et al. (1992). Preservation of hearing and facial nerve function in resection of acoustic neuroma. *Laryngoscope*, 102(10), 1153 - 1158.
- Nadol, J. B., Diamond, P. F., & Thornton, A. R. (1996). Correlation of hearing loss and radiologic dimensions of vestibular schwannomas (acoustic Neuromas). *The American Journal of Otology*, 17(2), 312 - 316.
- Nadol, J. B., Levine, R. A., Ojemann, R. G., Martuza, R. L., Montgomery, W. W., & De Sandoval, P. K. (1987). Preservation of hearing in surgical removal of acoustic neuromas of the internal auditory canal and cerebellar pontine angle. *Laryngoscope*, 97(11), 1287 - 1294.
- Nager, G. T. (1985). Acoustic Nerinomas. *Acta Oto-Laryngologica*, 99(3-4), 245 - 261.
- Neff, B. A., Ting, J., Dickinson, S. L., & Welling, D. B. (2005). Facial nerve monitoring parameters as a predictor of postoperative facial nerve outcomes after vestibular schwannoma resection. *Otology & Neurotology*, 26(4), 728 - 732.
- Nestor, J. J., Korol, H. W., Nutik, S. L., & Smith, R. (1988). The incidence of acoustic neuromas. *Archives of Otolaryngology - Head and Neck Surgery*, 114(6), 680.
- Neu, M., Strauss, C., Romstock, J., Bischoff, B., & Fahlbusch, R. (1999). The prognostic value of intraoperative BAEP patterns in acoustic neurinoma surgery. *Clinical Neurophysiology*, 110(11), 1935 - 1941.
- Noguchi, Y., Komatsuzaki, A., & Nishida, H. (1998). Cochlear microphonic potentials in patients with vestibular schwannomas. *ORL: Journal for Oto-Rhino-Laryngology*, 60(5), 283 - 290.
- O'Connor, A. F., Luxon, L. M., Shortman, R. C., Thompson, E. J., & Morrison, A. W. (1982). Electrophoretic separation and identification of perilymph proteins in cases of acoustic neuroma. *Acta Oto-Laryngologica*, 93(3-4), 195 - 200.
- O-Uchi, T., Kanzaki, J., Ogata, A., Inoue, T., Mashino, H., Yoshihara, S., et al. (1994). Pathophysiology of hearing impairment in acoustic neuroma with profound deafness: analysis by evoked otoacoustic emission and promontory stimulation test. *Acta Oto-Laryngologica*, 514, 95 - 100.
- Ogawa, K. J., Ogawa, S., Yamamoto, M., Ikeda, S., & O-Uchi, T. (1991). Audiological findings in acoustic neuroma. *Acta Oto-Laryngologica*, 487, 125 - 132.
- Ohashi, T., Kenmochi, M., Kinoshita, H., Ochi, K., Yoshino, K., & Komatsuzaki, A. (1996). Abnormal electrocochleography after excision of acoustic neuroma. *Acta Oto-Laryngologica*, 522(17 - 21).
- Ohashi, T., Ochi, K., Kinoshita, H., Kenmochi, M., Kikuchi, H., Nishino, H., et al. (2001). Electrocochleogram after transection of vestibulo-cochlear nerve in a patient with a large acoustic neurinoma. *Hearing Research*, 154(1 - 2), 26 - 31.
- Olsen, W. O., & Noffsinger, D. (1974). Comparison of one new and three old tests of auditory adaptation. *Archives of Otolaryngology*, 99, 94 - 99.
- Paludetti, G., Maurizi, M., & Ottaviani, F. (1983). Effects of stimulus repetition rate on the auditory brain stem responses (ABR). *American Journal of Otology*, 4(3), 226 - 234.
- Palva, T. (1964). Auditory adaptation. *Acta Oto-Laryngologica*, 57, 207 - 215.
- Palva, T., Troupp, H., & Jauhiainen, T. (1985). Hearing preservation in acoustic neurinoma surgery. *Acta Oto-Laryngologica*, 99(1-2), 1 - 7.

- Patuzzi, R. B., Yates, G. K., & Johnstone, B. M. (1989). The origin of the low-frequency microphonic in the first cochlear turn of guinea-pig. *Hearing Research*, 39(1-2), 177 - 188.
- Peake, W. T., & Kiang, N. Y. (1962). Cochlear responses to condensation and rarefaction clicks. *Biophysical journal*, Jan(2), 23 - 34.
- Pensak, M. L., Glasscock, M. E., Josey, A. F., & Jackson, C. G. (1985). Sudden hearing loss and cerebello-pontine angle tumours. *Laryngoscope*, 95, 1183 - 1193.
- Perlman, H. B., Kimura, R., & Fernandez, C. (1959). Experiments on temporary obstruction of the internal auditory artery. *Laryngoscope*, 69(6), 591 - 613.
- Perre, J., Viala, P., & Foncin, J. F. (1990). Involvement of cochlear nerve in acoustic tumours. *Acta Oto-Laryngologica*, 110, 245 - 252.
- Piccirillo, E., Hiraumi, H., Hamada, M., Russo, A., De Stefano, A., & Sanna, M. (2008). Intraoperative Cochlear Nerve Monitoring in Vestibular Schwannoma Surgery - Does It Really Affect Hearing Outcome? *Audiology & Neurotology*, 13, 58 - 64.
- Pickles, J. O. (2008). *An introduction to the physiology of hearing* (3rd ed.). Bingley, United Kingdom: Emerald Group Publishing.
- Picton, T. W., Durieux-Smith, A., & Moran, L. M. (1994). Recording auditory brainstem responses from infants. *International Journal of Pediatric Otolaryngology*, 28, 93 - 110.
- Portmann, M., Sterkers, J. M., Charachon, R., & Chouard, C. H. (1975). *The internal auditory meatus: anatomy, pathology, and surgery*. New York: Churchill Livingstone.
- Post, K. D., Eisenberg, M. B., & Catalano, P. J. (1995). Hearing preservation in vestibular schwannoma surgery: what factors influence outcome? *Journal of Neurosurgery*, 83(2), 191 - 196.
- Prasher, D. K., Tun, T., Brookes, G. B., & Luxon, L. M. (1995). Mechanisms of hearing loss in acoustic neuroma: an otoacoustic emission study. *Acta Oto-Laryngologica*, 115(3), 375 - 381.
- Prell, J., Rampp, S., Romstock, J., Fahlbusch, R., & Strauss, C. (2007). Train time as a quantitative electromyographic parameter for facial nerve function in patients undergoing surgery for vestibular schwannoma. *Journal of Neurosurgery*, 106(5), 826 - 832.
- Rasmussen, G. L. (1946). The olivary peduncle and other fiber projections of the superior olivary complex. *The Journal of Comparative Neurology*, 84(2), 141 - 219.
- Rasmussen, G. L. (1960). Efferent fibers of the cochlear nerve and cochlear nucleus. In G. L. Rasmussen & P. R. Windle (Eds.), *Neural mechanisms of the auditory and vestibular systems* (pp. 105-115). Springfield, IL: Thomas.
- Rebillard, G., & Lavigne-Rebillard, M. (1992). Rebillard & Lavigne-Rebillard, 1992. *Hearing Research*, 62(2), 142 - 148.
- Reisser, C., & Schuknecht, H. F. (1991). The anterior inferior cerebellar artery in the internal auditory canal. *Laryngoscope*, 101(7), 761 - 766.
- Reiter, E. R., & Liberman, M. C. (1995). Efferent-mediated protection from acoustic overexposure: relation to slow effects of olivocochlear stimulation. *Journal of Neurophysiology*, 73(2), 506 - 514.
- Roberson, J. B., Jackson, L. E., & McAuley, J. R. (1999). Acoustic neuroma surgery: absent auditory brainstem response does not contraindicate attempted hearing preservation. *Laryngoscope*, 109(6), 904 - 910.
- Robinette, M. S., Bauch, C. D., Olsen, W. O., Harner, S. G., & Beatty, C. W. (1997). Nonsurgical factors predictive of postoperative hearing for patients with vestibular schwannoma. *The American Journal of Otology*, 18(6), 738 - 745.

- Romani, G. L., Williamson, S. J., & Kaufman, L. (1982). Tonotopic organisation of the human auditory cortex. *Science*, 216(4552), 1339 - 1340.
- Rosenberg, S. I. (2000). Natural history of acoustic neuromas. *Laryngoscope*, 110(4), 497 - 508.
- Rubinstein, D., Sandberg, E. J., & Cajade-Law, A. G. (1996). Anatomy of the facial and vestibulocochlear nerves in the internal auditory canal. *American Journal of Neuroradiology*, 17(6), 1099 - 1105.
- Ruckenstein, M. J., Harris, J. P., Cueva, R. A., Prioleau, G., & Alksne, J. (1996). Pain subsequent to resection of acoustic neuromas via suboccipital and translabyrinthine approaches. *American Journal of Otology*, 17(4), 620 - 624.
- Ruggero, M. A. (1992). Physiology and coding of sound in the auditory nerve. In A. N. Popper & R. R. Fay (Eds.), *The mammalian auditory pathway: neurophysiology, Springer Handbook of Auditory Research* (Vol. 2, pp. 34 - 93). New York: Springer.
- Ruth, R. A., Lambert, P. R., & Ferraro, J. A. (1988). Electrocochleography: methods and clinical applications. *The American Journal of Otology*, 9, 1 - 11.
- Sabin, H. I., Prasher, D. K., Bentivoglio, P., & Symon, L. (1987). Preservation of cochlear potentials in a deaf patient fifteen months after excision of an acoustic neuroma. *Scandinavian Audiology*, 16(2), 109 - 111.
- Saleh, E. A., Aristegui, M., Naguib, M. B., Cokesser, Y., Landolfi, M., & Sanna, M. (1996). Normal hearing in acoustic neuroma patients: a critical evaluation. *American Journal of Otolaryngology*, 17(1), 127 - 132.
- Samii, M., Gerganov, V., & Samii, A. (2006). Improved preservation of hearing and facial nerve function in vestibular schwannoma surgery via the retrosigmoid approach in a series of 200 patients. *Journal of Neurosurgery*, 105(4), 527 - 535.
- Samii, M., & Matthies, C. (1995). Hearing preservation in acoustic tumour surgery. *Advance and Technical Standards in Neurosurgery*, 22, 343 - 373.
- Samii, M., & Matthies, C. (1997). Management of 1000 vestibular schwannomas (acoustic neuromas): hearing function in 1000 tumor resections. *Neurosurgery*, 40(2), 248 - 260.
- Samii, M., Matthies, C., & Tatagiba, M. (1997). Management of vestibular schwannomas (acoustic neuromas): auditory and facial nerve function after resection of 120 vestibular schwannomas in patients with neurofibromatosis 2. *Neurosurgery*, 40(4), 696 - 705.
- Sando, I. (1965). The Anatomical Interrelationships of the cochlear nerve fibers. *Acta Otolaryngology*, 59, 417 - 436.
- Satar, B., Yetiser, S., & Ozkaptan, Y. (2003). Impact of tumor size on hearing outcome and facial function with the middle fossa approach for acoustic neuroma: a meta-analytic study. *Acta Oto-Laryngologica*, 123(4), 499 - 505.
- Schlake, H. P., Milewski, C., Goldbrunner, R. H., Kindgen, A., Riemann, R., Helms, J., et al. (2001). Combined intra-operative monitoring of hearing by means of auditory brainstem responses (ABR) and transtympanic electrocochleography (ECochG) during surgery of intra- and extrameatal acoustic neurinomas. *Acta Neurochirurgica*, 143(10), 985 - 995.
- Schmiedt, R. A., & Adams, J. C. (1981). Stimulated acoustic emissions in the ear canal of the gerbil. *Hearing Research*, 5(2-3), 295 - 305.
- Schuknecht, H. F. (1993). *Pathology of the ear*. Philadelphia: Lea & Febiger.
- Schuknecht, H. F., & Woellner, R. C. (1953). Hearing losses following partial section of the cochlear nerve. *Laryngoscope*, 63(6), 441 - 465.

- Schuknecht, H. F., & Woellner, R. C. (1955). An experimental and clinical study of deafness from lesions of the cochlear nerve. *The Journal of Laryngology and Otology*, 69(2), 75 - 97.
- Sekiya, T., Iwabuchi, T., Kamata, S., & Ishida, T. (1985). Deterioration of auditory evoked potentials during cerebellopontine angle manipulations. An interpretation based on an experimental model in dogs. *Journal of Neurosurgery*, 63(4), 598 - 607.
- Sekiya, T., & Møller, A. R. (1987). Cochlear nerve injuries caused by cerebellopontine angle manipulations. An electrophysiological and morphological study in dogs. *Journal of Neurosurgery*, 67(2), 244 - 249.
- Sekiya, T., & Møller, A. R. (1988). Effects of cerebellar retractions on the cochlear nerve: an experimental study on rhesus monkeys. *Acta Neurochirurgica*, 90(1-2), 45 - 52.
- Sekiya, T., Møller, A. R., & Jannetta, P. J. (1986). Pathophysiological mechanisms of intraoperative and postoperative hearing deficits in cerebellopontine angle surgery: an experimental study. *Acta Neurochirurgica*, 81(3-4), 142 - 151.
- Sekiya, T., Shimamura, N., Suzuki, S., & Hatayama, T. (2001). Methylprednisolone ameliorates cochlear nerve degeneration following mechanical injury. *Hearing Research*, 151(1-2), 125 - 132.
- Sekiya, T., Suzuki, S., & Iwabuchi, T. (1990). Changes in intracochlear and intracanalicular nerves after acoustic neuroma excision confirmed by magnetic resonance imaging. *Neurosurgery*, 27(4), 587 - 591.
- Sekiya, T., Yagihashi, A., Asano, K., & Suzuki, S. (2002). Nimodipine ameliorates trauma-induced cochlear neuronal death. *Neurological Research*, 24(8), 775 - 780.
- Selesnick, S. H., & Jackler, R. K. (1992). Clinical manifestations and audiologic diagnosis of acoustic neuromas. *Otolaryngologic Clinics of North America*, 25(3), 521 - 551.
- Selesnick, S. H., Jackler, R. K., & Pitts, L. W. (1993). The changing clinical presentation of acoustic tumors in the MRI era. *Laryngoscope*, 103(4), 431 - 436.
- Selesnick, S. H., Liu, J. C., Jen, A., & Newman, J. (2004). The incidence of cerebrospinal fluid leak after vestibular schwannoma surgery. *Otology & Neurotology*, 25(3), 387 - 393.
- Selters, W. A., & Brackmann, D. E. (1977). Acoustic tumor detection with brain stem electric response audiometry. *Archives of Otolaryngology*, 103(4), 181 - 187.
- Shelton, C., Brackmann, D. E., House, W. F., & Hitselberger, W. E. (1989). Acoustic tumor surgery. Prognostic factors in hearing conservation. *Archives of Otolaryngology - Head and Neck Surgery*, 115(10), 1213 - 1216.
- Shimamura, N., Sekiya, T., Yagihashi, A., & Suzuki, S. (2002). Temporal pattern of cochlear nerve degeneration following compression injury: a quantitative experimental observation. *Journal of Neurosurgery*, 97(4), 929 - 934.
- Silverstein, H., Norrell, H., Haberkamp, T., & McDaniel, A. B. (1986). The unrecognized rotation of the vestibular and cochlear nerves from the labyrinth to the brain stem: its implications to surgery of the eighth cranial nerve. *Otolaryngology - Head and Neck Surgery*, 95(5), 543 - 549.
- Simmons, D. D., & Liberman, M. C. (1988). Afferent innervation of outer hair cells in adult cats: I. Light microscopic analysis of fibers labeled with horseradish peroxidase. *Journal of Comparative Neurology* 270(1), 132 - 144.
- Slattery, W. H., Brackmann, D. E., & Hitselberger, W. E. (1997). Middle fossa approach for hearing preservation with acoustic neuromas. *American Journal of Otolaryngology*, 18(5), 596 - 601.
- Solares, C. A., & Panizza, B. (2008). Vestibular Schwannoma: An Understanding of growth should influence management decisions. *Otology & Neurotology*, 29(6), 829 - 834.

- Soumekh, B., Levine, S. C., Haines, S. J., & Wulf, J. A. (1996). Retrospective study of postcraniotomy headaches in suboccipital approach: diagnosis and management. *American Journal of Otology*, 17(4), 617 - 619.
- Spoendlin, H. (1975). Retrograde degeneration of the cochlear nerve. *Acta Oto-Laryngologica*, 79(3-4), 266 - 275.
- Spoendlin, H., & Schrott, A. (1989). Analysis of the human auditory nerve. *Hearing Research*, 43(1), 25 - 38.
- Spoendlin, H., & Suter, R. (1976). Regeneration in the VIII nerve. *Acta Oto-Laryngologica*, 81(3 - 4), 228 - 236.
- Staecker, H., Nadol, J. B., Ojeman, R., Ronner, S., & McKenna, M. J. (2000). Hearing preservation in acoustic neuroma surgery: middle fossa versus retrosigmoid approach. *The American Journal of Otology*, 21(3), 399 - 404.
- Stangerup, S. E., Tos, M., Caye-Thomasen, P., Tos, T., Klokke, M., & Thomsen, J. (2004). Increasing annual incidence of vestibular schwannoma and age at diagnosis. *The Journal of Laryngology and Otology*, 118(8), 622 - 627.
- Starr, A., Sininger, Y. S., & Pratt, H. (2000). The varieties of auditory neuropathy. *Journal of basic and clinical physiology and pharmacology*, 11(3), 215 - 230.
- Sterkers, J. M., & Bowdler, D. A. (1987). The origin of acoustic neuromas. *Acta Oto-Laryngologica*, 103, 427 - 431.
- Sterkers, J. M., Morrison, G. A., Sterkers, O., & El-Dine, M. M. (1994). Preservation of facial, cochlear, and other nerve functions in acoustic neuroma treatment. *Otolaryngology - Head and Neck Surgery*, 110(2), 146 - 155.
- Stidham, K. R., & Roberson, J. B. (2001). Hearing improvement after middle fossa resection of vestibular schwannoma. *Otology & Neurotology*, 22(6), 917 - 921.
- Stipkovits, E. M., Graamans, K., & Van Dijk, J. E. (2001). Vestibular schwannoma: negative growth and audiovestibular features. *European Archives of Oto-Rhino-Laryngology*, 258(9), 467 - 471.
- Stipkovits, E. M., Van Dijk, J. E., & Graamans, K. (1998). Profile of hearing in patients with unilateral acoustic neuromas: the importance of the contralateral ear. *The American Journal of Otology*, 19(6), 834 - 839.
- Stover, L., Gorga, M. P., Neely, S. T., & Montoya, D. (1996). Toward optimising the clinical utility of distortion product otoacoustic emission measurements. *Journal of the Acoustical Society of America*, 100(2), 956 - 967.
- Strauss, C., Bischoff, B., Neu, M., Berg, M., Fahlbusch, R., & Romstock, J. (2001). Vasoactive treatment for hearing preservation in acoustic neuroma surgery. *Journal of Neurosurgery*, 95(5), 771 - 777.
- Strauss, C., Fahlbusch, R., Romstock, J., Schramm, J., Watanabe, E., Taniguchi, M., et al. (1991). Delayed hearing loss after surgery for acoustic neurinomas: clinical and electrophysiological observations. *Neurosurgery*, 28(4), 559 - 565.
- Suga, F., & Lindsay, J. R. (1976). Inner ear degeneration in acoustic neurinoma. *The Annals of Otology, Rhinology, and Laryngology*, 85(3), 343 - 358.
- Sugita, M., Masutani, H., Moriguchi, M., Matsunaga, K., & Nakai, Y. (1991). Distribution of arteries from brain stem to inner ear around the internal auditory canal. *Acta Oto-Laryngologica*, 486, 45 - 52.
- Suzuki, J., & Yamane, H. (1982). The choice of stimulus in the auditory brainstem response test for neurological and audiological examinations. *Annals of the New York Academy of Sciences*, 388, 731 - 736.
- Takeda, T., Kitahara, M., & Sawada, I. (1992). Pathogenesis of widened AP-SP complex in cases of cerebellopontine angle tumors. *ORL: Journal for Oto-rhino-laryngology*, 54(1), 15 - 20.

- Tanaka, F., Tsukasaki, N., Nakao, Y., Shigeno, K., & Kobayashi, T. (1999). Electrocochleographic evaluation of hearing loss in acoustic neuromas. *The American Journal of Otolaryngology*, 20(4), 479 - 483.
- Tasaki, I., Polley, E. H., & Orrego, F. (1954). Action potentials from individual elements in cat geniculate and striate cortex. *Journal of Neurophysiology*, 17(5), 454 - 474.
- Tasaki, I., & Spyropoulos, C. S. (1959). Stria vascularis as source of endocochlear potential. *Journal of Neurophysiology*, 22(2), 149 - 155.
- Telischi, F. F. (2000). An objective method of analyzing cochlear versus noncochlear patterns of distortion-product otoacoustic emissions in patients with acoustic neuromas. *Laryngoscope*, 110(4), 553 - 562.
- Telischi, F. F., Mom, T., Agrama, M., Stagner, B., Ozdamar, O., Bustillo, A., et al. (1999). Comparison of the auditory – evoked brainstem response wave I to distortion – product otoacoustic emissions resulting from changes to inner ear blood flow. *Laryngoscope*, 109(2), 186 - 191.
- Telischi, F. F., Roth, J., Stagner, B. B., Lonsbury-Martin, B. L., & Balkany, T. J. (1995). Patterns of Evoked Otoacoustic Emissions Associated With Acoustic Neuromas. *Laryngoscope*, 105, 675 - 682.
- Telischi, F. F., Stagner, B., Widick, M. P., Balkany, T. J., & Lonsbury-Martin, B. L. (1998). Distortion – product otoacoustic emission monitoring of cochlear blood flow. *Laryngoscope*, 108(6), 837 - 842.
- The Virtual Medical Centre (2007). Anatomy of the ear. Retrieved May 22, 2008, from <http://www.virtualmedicalcentre.com/anatomy.asp?sid=29&title=Ear>
- Thomsen, J., & Tos, M. (1988). Diagnostic strategies in search for acoustic neuromas. Findings in 300 acoustic neuroma patients. *Acta Oto-Laryngologica*, 452, 16 - 25.
- Thornton, A. R., & Coleman, M. J. (1975). The adaptation of cochlear and brainstem auditory evoked potentials in humans. *Electroencephalography and Clinical Neurophysiology*, 39, 399 - 406.
- Tierney, P. A., Chitnavis, B. P., Sherriff, M., Strong, A. J., & Gleeson, M. J. (1998). The relationship between pure tone thresholds and the radiological dimensions of acoustic neuromas. *Skull Base Surgery*, 8(3), 149 - 151.
- Tos, M., Charabi, S., & Thomsen, S. (1999). Incidence of vestibular schwannomas. *Laryngoscope*, 109(5), 736 - 740.
- Turner, R. G., Shepard, N.T., & Frazer, G. J. (1984). Clinical performance of audiological and related diagnostic tests. *Ear & Hearing*, 5, 187-194.
- Umezumi, H., & Aiba, T. (1994). Preservation of hearing after surgery for acoustic schwannomas: correlation between cochlear nerve function and operative findings. *Journal of Neurosurgery*, 80(5), 844 - 848.
- Van Dijk, J. E., Duijndam, J., & Graamans, K. (2000). Acoustic Neuroma deterioration of speech discrimination related to thresholds in pure-tone audiometry. *Acta Oto-Laryngologica*, 120(5), 627 - 632.
- Van Leeuwen, J. P., Cremers, C. W., Thewissen, N. P., Harhangi, B. S., & Meijer, E. (1995). Acoustic neuroma: correlation among tumor size, symptoms, and patient age. *Laryngoscope*, 105(7), 701 - 707.
- Vinck, B. M., Van Cauwenberge, P. B., Leroy, L., & Corthals, P. (1999). Sensitivity of transient evoked and distortion product otoacoustic emissions to the direct effects of noise on the human cochlea. *Audiology*, 38(1), 44 - 52.
- Von Békésy, G. (1960). *Experiments in Hearing*. NY: McGraw Hill.
- Waddington, M. (1974). *Atlas of human intracranial anatomy*. Boston: Little, Brown and Company.

- Walsted, A., Salomon, G., Thomsen, J., & Tos, M. (1991). Hearing decrease after loss of cerebrospinal fluid. A new hydrops model? *Acta Oto-Laryngologica*, *111*(3), 468 - 476.
- Warr, W. B. (1980). Efferent components of the auditory system. *Annals of Otolology, Rhinology & Laryngology*, *89*(5-2), 114 - 120.
- Warr, W. B. (1992). Organization of olivocochlear efferent systems in mammals. In W. D.B., P. A.N. & F. R.R. (Eds.), *The mammalian auditory pathway: Neuroanatomy*. New York: Springer Verlag.
- Warr, W. B., & Guinan, J. J. (1979). Efferent innervation of the organ of corti: two separate systems. *Brain Research*, *173*(1), 152 - 155.
- Watanabe, E., Schramm, J., Strauss, C., & Fahlbusch, R. (1989). Neurophysiologic monitoring in posterior fossa surgery. II. BAEP-waves I and V and preservation of hearing. *Acta Neurochirurgica*, *98*(3-4), 118 - 128.
- Whitfield, I. C., & Ross, H. F. (1965). Cochlear-microphonic and Summating Potentials and the Outputs of Individual Hair-cell generators. *The Journal of the Acoustical Society of America*, *38*, 126 - 131.
- Widick, M. P., Telischi, F. F., Lonsbury-Martin, B. L., & Stagner, B. B. (1994). Early effects of cerebellopontine angle compression on rabbit distortion-product otoacoustic emissions: a model for monitoring cochlear function during acoustic neuroma surgery. *Otolaryngology - Head and Neck Surgery*, *111*(4), 407 - 416.
- Wilson, D. F., Hodgson, R. S., Gustafson, M. F., Hogue, S., & Mills, L. (1992). The sensitivity of auditory brainstem response testing in small acoustic neuromas. *Laryngoscope*, *102*(9), 961 - 964.
- Yacullo, W. S. (1996). *Clinical masking procedures*. Massachusetts: Allyn & Bacon.
- Yang, J., Graveli, A. B., Barylyak, R., Elgarem, H., Kalamarides, M., Ferrary, E., et al. (2008). Functional outcome of retrosigmoid approach in vestibular schwannoma surgery. *Acta Oto-Laryngologica*, *128*, 881 - 886.
- Yates, P. D., Jackler, R. K., Satar, B., Pitts, L. H., & Oghalai, J. S. (2003). Is it worthwhile to attempt hearing preservation in larger acoustic neuromas? *Otology & Neurotology*, *24*(3), 460 - 464.
- Ylikoski, J., Collan, Y., & Palva, T. (1979). Functional and histological findings in acoustic neuroma. *ORL: Journal for Oto-Rhino-Laryngology*, *41*(1), 33 - 39.
- Ylikoski, J., Palva, T., & Collan, Y. (1978). Eighth nerve in acoustic neuromas. Special reference to superior vestibular nerve function and histopathology. *Archives of Otolaryngology*, *104*(9), 532 - 537.
- Yokoyama, K., Nishida, H., Noguchi, Y., & Komatsuzaki, A. (1999). Hearing impairment in patients with acoustic neuroma-analysis by electrocochleography. *Auris Nasus Larynx*, *26*(4), 401 - 409.
- Yong, R. L., Westerberg, B. D., Dong, C., & Akagami, R. (2008). Length of tumor-cochlear nerve contact and hearing outcome after surgery for vestibular schwannoma. *Journal of Neurosurgery*, *108*(1), 105 - 110.
- Yoshie, N. (1971). Clinical cochlear response audiometry by means of an average response computer: non-surgical technique and clinical use. *Revue de Laryngologica - Otologie - Rhinologie*, *92*, 646 - 672.

APPENDIX A

Ethical approval letter from the Upper South Island Ethics Committee

Ethical approval letter from the Human Ethics Committee

Research information form

Consent form

22 May 2007

Mr P. A. Bird
Dept of Otolaryngology
Christchurch Public Hospital
Private Bag 4710
Christchurch

Dear Mr Bird,

Patterns of hearing loss during and following the removal of acoustic neuroma
Investigators: Mr P Bird, Dr A Scarlett, Dr G O'Beirne, Mr M MacFarlane, Ms M Feldman
Locality: Christchurch Hospital
Ethics ref: URA/07/03/017

The above study has been given ethical approval by the **Upper South A** Ethics Committee. A list of members of this committee is attached.

Approved Documents

Information sheet and consent form version 2 dated 16 April 2007

Certification

The Committee is satisfied that this study is not being conducted principally for the benefit of the manufacturer or distributor of the medicine or item in respect of which the trial is being carried out.

Accreditation

The Committee involved in the approval of this study is accredited by the Health Research Council and is constituted and operates in accordance with the Operational Standard for Ethics Committees, April 2006.

Progress Reports

The study is approved until 1 June 2009. The Committee will review the approved application annually and notify the Principal Investigator if it withdraws approval. It is the Principal Investigator's responsibility to forward a progress report covering all sites prior to ethical review of the project in June 2008. The report form is available on <http://www.newhealth.govt.nz/ethicscommittees>. Please note that failure to provide a progress report may result in the withdrawal of ethical approval. A final report is also required at the conclusion of the study.

Requirements for SAE Reporting

The Principal Investigator will inform the Committee as soon as possible of the following:

- Any related study in another country that has stopped due to serious or unexpected adverse events
- withdrawal from the market for any reason
- all serious adverse events occurring during the study in New Zealand which result in the investigator or sponsor breaking the blinding code at the time of the SAE or which result in hospitalisation or death.
- all serious adverse events occurring during the study worldwide which are considered related to the study medicine. Where there is a data safety monitoring board in place, serious adverse events occurring outside New Zealand may be reported quarterly.

All SAE reports must be signed by the Principal Investigator and include a comment on whether he/she considers there are any ethical issues relating to this study continuing due to this adverse event. If the adverse event is local and does not have the sponsor's report attached, an opinion on whether the event is thought to be related to the study should be given along with any other pertinent information. It is assumed by signing the report, the Principal Investigator has undertaken to ensure that all New Zealand investigators are made aware of the event.

Amendments

All amendments to the study must be advised to the Committee prior to their implementation, except in the case where immediate implementation is required for reasons of safety. In such cases the Committee must be notified as soon as possible of the change.

Please quote the above ethics committee reference number in all correspondence.

It should be noted that Ethics Committee approval does not imply any resource commitment or administrative facilitation by any healthcare provider within whose facility the research is to be carried out. Where applicable, authority for this must be obtained separately from the appropriate manager within the organisation.

We wish you well with your study.

Yours sincerely

Alieke Dierckx
Upper South A Ethics Committee Administrator

Email: alieke_dierckx@moh.govt.nz

List of members of the Upper Region A Ethics Committee, March 2007

Carolyn Mason (Chair)	Ethicist/Philosopher Lay member	Female
Carolynn Bull	Legal representative, Maori representative Lay member	Female
John Horwood	Biostatistician Lay member	Male
Jane Kerr	Researcher Health Professional Member	Female
Alison Luckey	Health Practitioner Health Professional member	Female

Tom Marshall	Clinical Psychologist Health Professional member	Male
Ellen McCrae	Pharmacist Health Professional member	Female
Edie Moke	Maori representative Lay member	Female
Nicky Murray	Community Representative Lay member	Female
Elizabeth Richards	Consumer Representative Lay member	Female
Russell Scott	Health Practitioner Health Professional member	Male

Carolynn Bull and Edie Moke were not present at the meeting on 26 February 2007.

Alieke Dierckx (Administrator)

Date

Ref: HEC 2008/44

16 June 2008

Ms Melissa Babbage
Department of Communication Disorders
UNIVERSITY OF CANTERBURY

Dear Melissa

The Human Ethics Committee advises that your research proposal “Patterns of hearing loss during and following the removal of vestibular Schwannoma.” has been considered and approved.

Please note that this approval is subject to the incorporation of the amendments you have provided in your email of 6 June 2008.

Best wishes for your project.

Yours sincerely

Dr Michael Grimshaw
Chair, Human Ethics Committee

INFORMATION FORM

PATTERNS OF HEARING LOSS DURING AND FOLLOWING THE REMOVAL OF ACOUSTIC NEUROMA

February 2007

Introduction

You are invited to take part in this study during your surgery for removal of an acoustic neuroma. Your decision to take part can be made at any time between reading this form and the day of your operation. You do not have to take part in this study. If you do agree to take part you are free to withdraw from the study at any time, without having to give a reason and this will in no way affect your future/continuing health care. All people undergoing surgery to remove an acoustic neuroma with possible hearing preservation over the next two years will be asked to participate in this study. This will involve approximately 25 to 40 people.

Why is this study being done?

With the use of magnetic resonance imaging (MRI), people are presenting earlier with acoustic neuromas than previously. Subsequently many people still have a reasonable level of hearing prior to the removal of the acoustic neuroma. Unfortunately one of the risks of surgery includes reduction/loss in functional hearing. This study will monitor the patients hearing before, during and following surgery in order to determine the stage at which hearing is lost (if at all). The results from this study will be used to help surgeons understand why people can lose their hearing following acoustic neuroma surgery. If it can be established at which point during the operation hearing is lost (if at all), then more research can be aimed at changes in the techniques/approaches that surgeons use, in order to reduce the risks of hearing loss.

What do we plan to do during the study?

A variety of methods will be used to assess your hearing prior to surgery, all of which will cause no discomfort to you. Most of the assessments are routine prior to surgery regardless of your involvement in the study. During the operation when you are under a general anaesthetic your brain will still respond to sounds the same as when you are awake. We can pick up this activity from your brain using “electrodes” (wires connected from a computer to an adhesive patch which is placed on your skin). This technique of monitoring hearing is not usually performed in routine removal of an acoustic neuroma. Following the surgery hearing assessments will be made every hour for the first six hours then twice daily until you are discharged from hospital. Involvement in this study will not delay your recovery or discharge from hospital. Usually following surgery you would undergo such tests on one occasion, however for the purposes of this study, such tests will be repeated more frequently. Although your hearing will be monitored immediately following surgery, this will only require you to be involved physically in the assessments (eg listening for sounds etc), if you are awake and happy to participate. If your hearing is lost during the postoperative period, a specialized test will be carried out following the

operation. This would involve a drop of medicine to numb a part of your ear drum and then a tiny needle would be inserted into the eardrum. This would detect whether the inner ear is picking up any sound even if you are unable to subjectively hear anything. This test is not usually routine. Although no extra visits to the department will be required, the tests will take extra time during routine follow ups. The hearing tests will be carried out by Ms Babbage, an audiology Masters student.

Is there any risk to me to be involved in this study?

We do not anticipate any increased risk from being involved in this study over and above the risks involved with removal of an acoustic neuroma. The only hearing assessment which can be slightly uncomfortable is the specialized test which requires a drop of anaesthetic onto the ear drum which will be done if hearing is lost in the period following the operation.

Will this study help me?

This study will not directly help you but may help people in the future undergoing a similar operation, to preserve their hearing. If we can detect when hearing loss occurs, methods may be developed to prevent it from occurring.

Everyone who participates in this study will receive feedback as to how the study has gone in the future.

No material which could personally identify you will be used in any reports on this study.

It is a requirement that all health research data must be stored for 10 years in the case of adults.

This study has received ethical approval from the Upper South A Regional Ethics Committee and the University of Canterbury Human Ethics Committee.

If you have any queries or concerns regarding your rights as a participant under this study you may wish to contact a Health and Disability Advocate, telephone

- South Island except Christchurch 0800 377 766
- Christchurch 03 377 7501

In the unlikely event of a physical injury as a result of your participation in this study, you may be covered by ACC under the Injury Prevention, Rehabilitation and Compensation Act. ACC cover is not automatic and your case will need to be assessed by ASS according to the provisions of the 2002 Injury Prevention Rehabilitation and Compensation Act. If your claim is accepted by ACC, you still might not get any compensation. This depends on a number of factors such as whether you are an earner or non-earner. ACC usually provides only partial reimbursement of costs and expenses and there may be no lump sum compensation payable. If you have ACC cover, generally this will affect your right to sue the investigations. If you have any questions about ACC, contact your nearest ACC office or the investigator.

If you have further questions or would like to discuss the research further, please do not hesitate to contact the researchers

Phil Bird, Otolaryngologist
Department of Otolaryngology
Christchurch Hospital
Private Bag 4710
Christchurch
(03) 355 7963

Angela Scarlett
Surgical Registrar
RMO Unit
Christchurch Hospital
Private Bag 4710
Christchurch
(03)03640 640

Martin McFarlane, Neurosurgeon
Department of Neurosurgery
Christchurch Hospital
Private Bag 4710
Christchurch
(03)3640 640

Dr Greg O'Beirne
Lecturer in Audiology
03 364 2987 ext. 7085

Miss Melissa Babbage
Audiology Masters Student
03 364 2987 ext. 7085

CONSENT FORM

PATTERNS OF HEARING LOSS DURING AND FOLLOWING THE REMOVAL OF ACOUSTIC NEUROMA

May 2007

REQUEST FOR INTERPRETER

English	I wish to have an interpreter	Yes	No
Maori	E hiahia ana ahau ki tetahi kaiwhakamaori/kaiwhaka pakeha korero.	Ae	Kao
Samoan	Ou te manaó ia I ai se faámatala upu.	Ioe	Leai
Tongan	Oku ou fiema'u ha fakatonulea.	Ioe	Ikai
Cook Island	Ka inangaro au I tetai tangata uri reo.	Ae	Kare
Niuean	Fia manako au ke fakaaoga e taha tagata fakahokohoko kupu.	E	Nakai
Mandarin	我需要 一个 翻译	对	不对
Japanese	通訳の人を希望します。	はい。	いいえ。
Korean	통역관이 필요합니다	네네	아아니오

- 1 I have read and I understand the information sheet for volunteers taking part in the study designed to investigate patterns of hearing loss during and following the removal of an acoustic neuroma. I have had the opportunity to discuss this study. I am satisfied with the answers I have been given.
- 2 I have had the opportunity to use whanau support or a friend to help me ask questions and understand the study.
- 3 I understand that taking part in this study is voluntary (my choice) and that I may withdraw from the study at any time without having to give a reason and this will in no way affect my continuing health care
- 4 I have had this project explained to me by the principal investigator Mr Phil Bird.
- 5 I understand that my participation in this study is confidential and that no material which could identify me will be used in any reports in this study.
- 6 I understand that the investigation will be stopped if it should appear harmful to me.
- 7 I have had time to consider whether to take part yes/no
- 8 I know who to contact if I have any side effects to the study yes/no
- 9 I know who to contact if I have any questions about the medication or the study.

- 10 I wish to receive a copy of the results yes/no
- 11 I would like the researcher to discuss the outcomes of the study with me
yes/no
- 12 I agree to my GP or other current provider being informed of my participation in this
study yes/no

I(full name) hereby consent to take part in this study
to investigate patterns of hearing loss during and following the removal of an acoustic
neuroma

SignatureDateTime

Study explained and consent witnessed by(full name)

SignatureDateTime

APPENDIX B

Pre- and postoperative behavioural and electrophysiological results for:

Case 1

Case 2

Case 3

Case 4

Case 5

Case 6

Case 7

Case 9

Case 12

Case 14

Case 15

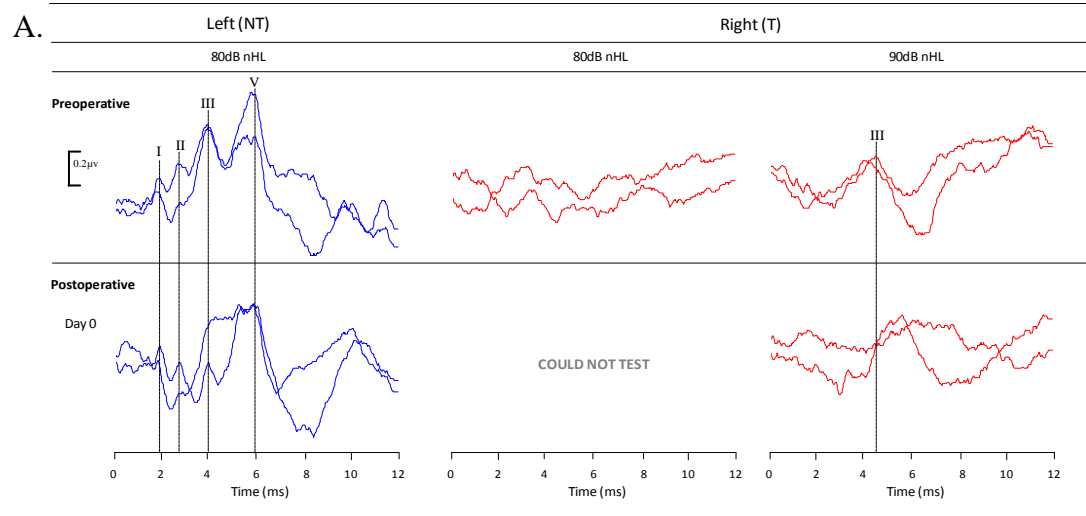
Case 18

Case 19

Intraoperative ABR for Case 19

Data is presented in chronological order; Case 1-19, irrespective of hearing outcome.

Case 1: Pre- and postoperative audiological test results. Part A shows ABR results and Part B shows the latencies of waves present in the ABR traces. Serial pure-tone and speech discrimination results are shown in Part C and Part D shows contralateral and ipsilateral DPOAEs.



B. Contralateral (left) peak latencies (ms)

Day	I	II	III	IV	V
Preop	1.77	2.75	3.90	-	5.95
Postop 0	1.75	2.73	3.92	-	5.98

Ipsilateral (right) peak latencies (ms)

Day	80 dB nHL					90 dB nHL				
	I	II	III	IV	V	I	II	III	IV	V
Preop	No identifiable peaks					-	-	4.62	-	-
Postop 0	Could not test					No identifiable peaks				

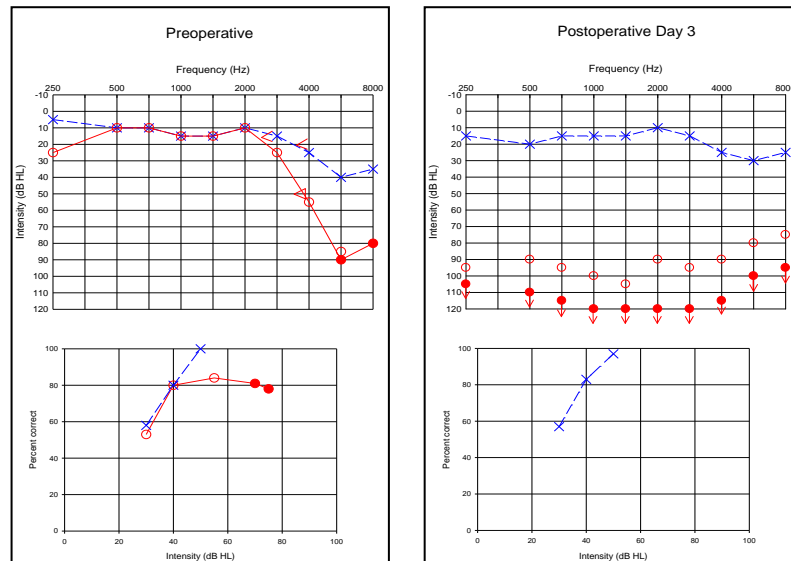
C. Contralateral (left) DPOAEs

Day	f_2 frequency (Hz)				
	2000	3000	4000	6000	8000
Preop	+	+	+	-	-
Postop 0	+	+	+	-	-
Postop 3	+	+	+	-	-

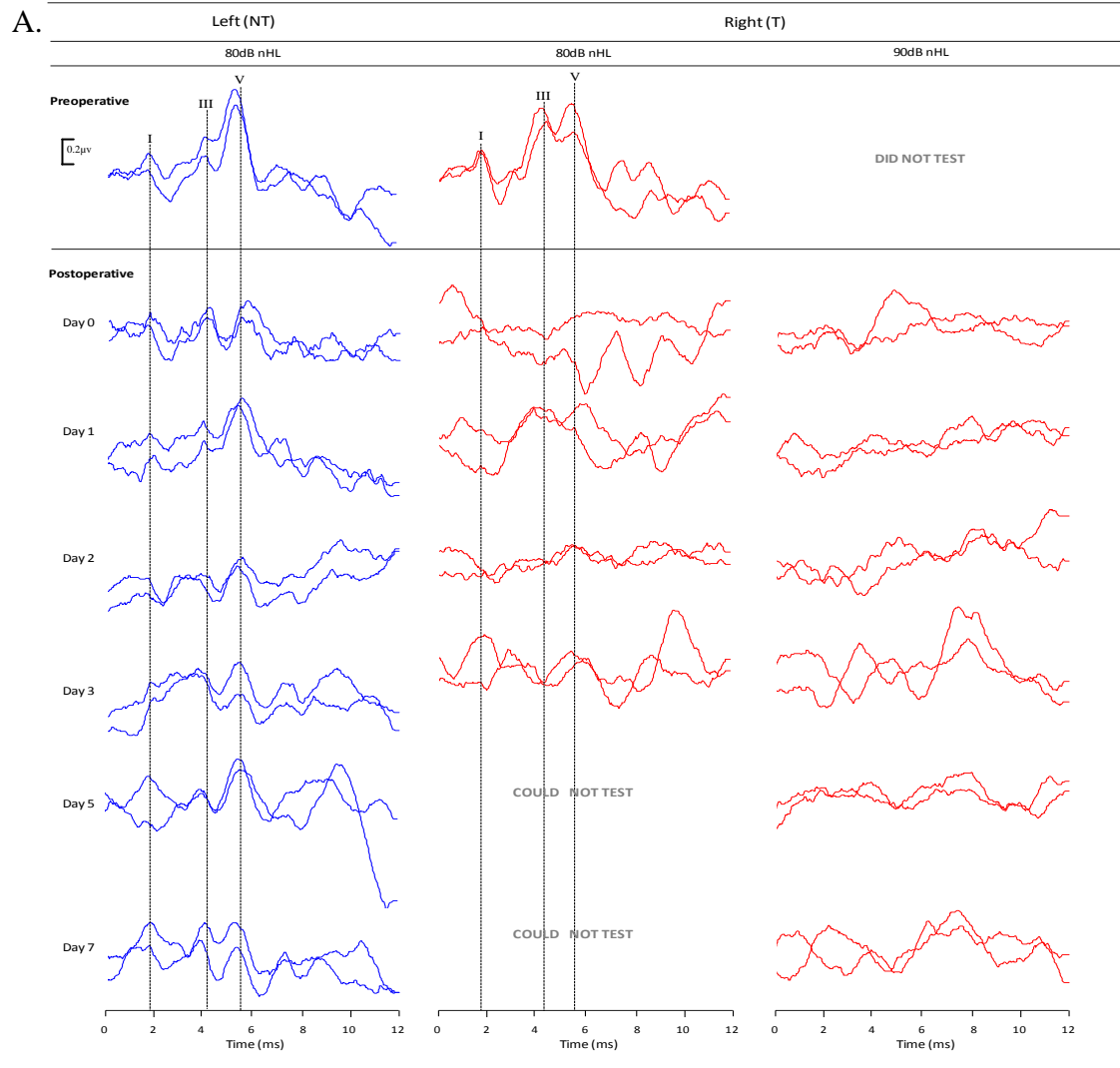
Ipsilateral (right) DPOAEs

Day	f_2 frequency (Hz)				
	2000	3000	4000	6000	8000
Preop	+	+	-	-	-
Postop 0	-	-	-	-	-
Postop 3	-	-	-	-	-

D.



Case 2: Pre- and postoperative electrophysiological audiology test results. Part A shows ABR results and Part B shows the latencies of waves present in the ABR traces. Part C shows contralateral and ipsilateral DPOAES.



B. Contralateral (left) peak latencies (ms)

Day	I	II	III	IV	V
Preop	1.65	-	4.05	-	5.35
Postop 0	1.71	-	4.08	-	5.50
Postop 1	1.68	-	3.95	-	5.45
Postop 2	1.70	-	3.98	-	5.40
Postop 3	1.72	-	3.89	-	5.38
Postop 5	1.65	-	3.93	-	5.45
Postop 7	1.66	-	3.90	-	5.34

Ipsilateral (right) peak latencies (ms)

Day	80 dB nHL					90 dB nHL				
	I	II	III	IV	V	I	II	III	IV	V
Preop	1.75	-	4.28	-	5.63	Did not test				
Postop	No identifiable peaks					No identifiable peaks				

C. Contralateral (left) DPOAEs

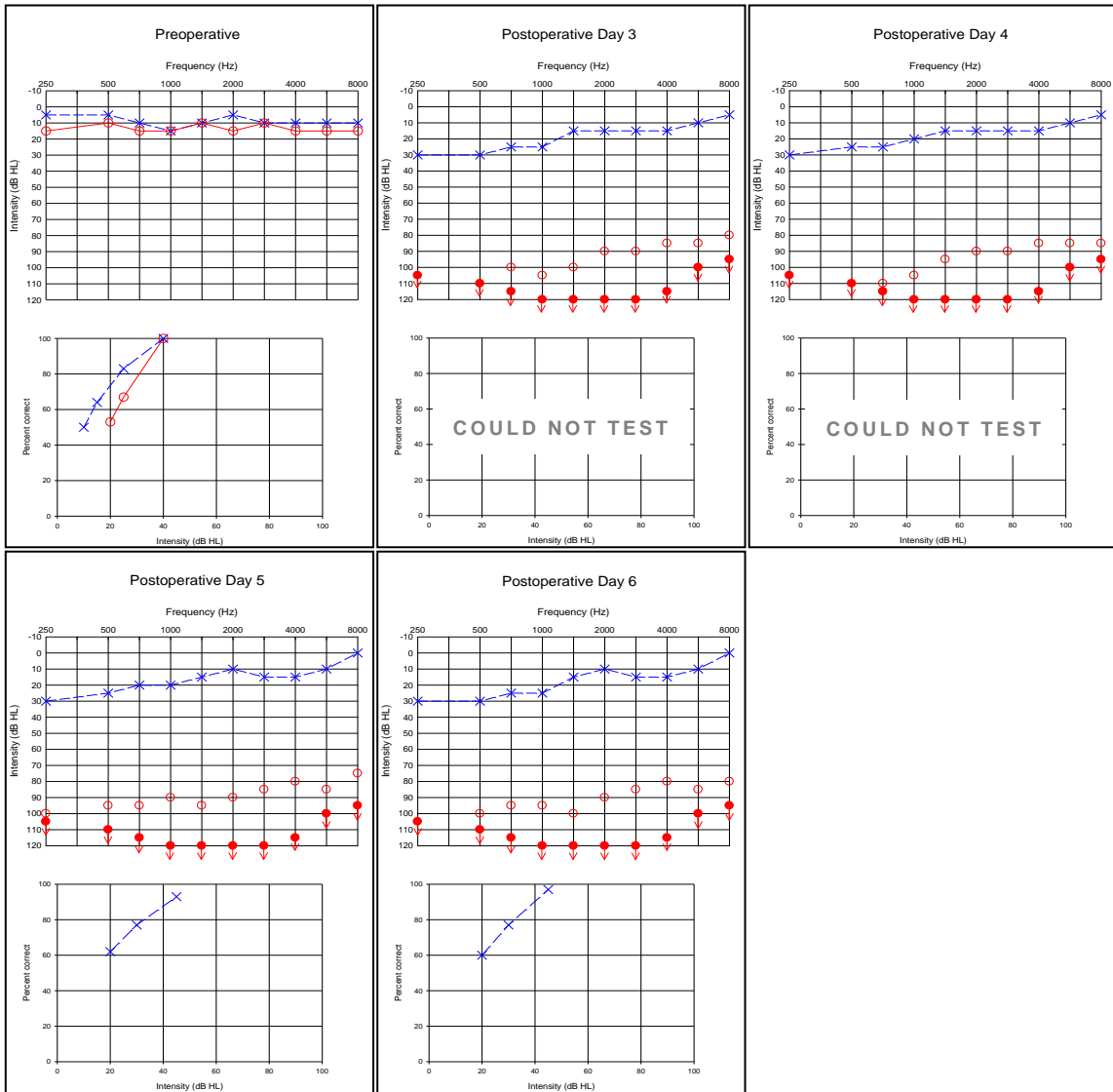
Day	f_2 frequency (Hz)				
	2000	3000	4000	6000	8000
Preop	+	+	+	+	+
Postop 0	+	+	+	-	+
Postop 1	+	+	+	-	+
Postop 2	+	+	+	-	+
Postop 3	+	+	+	-	+
Postop 5	+	+	+	-	+
Postop 7	+	+	+	-	+

Ipsilateral (right) DPOAEs

Day	f_2 frequency (Hz)				
	2000	3000	4000	6000	8000
Preop	+	+	+	+	+
Postop 0	-	-	-	-	-
Postop 1	-	-	-	-	-
Postop 2	-	-	-	-	-
Postop 3	-	-	-	-	-
Postop 5	-	-	-	-	-
Postop 7	-	-	-	-	-

Case 2: Pre- and postoperative behavioural audiology test results. Part A shows pure-tone and speech discrimination test results and Part B shows tone decay test results.

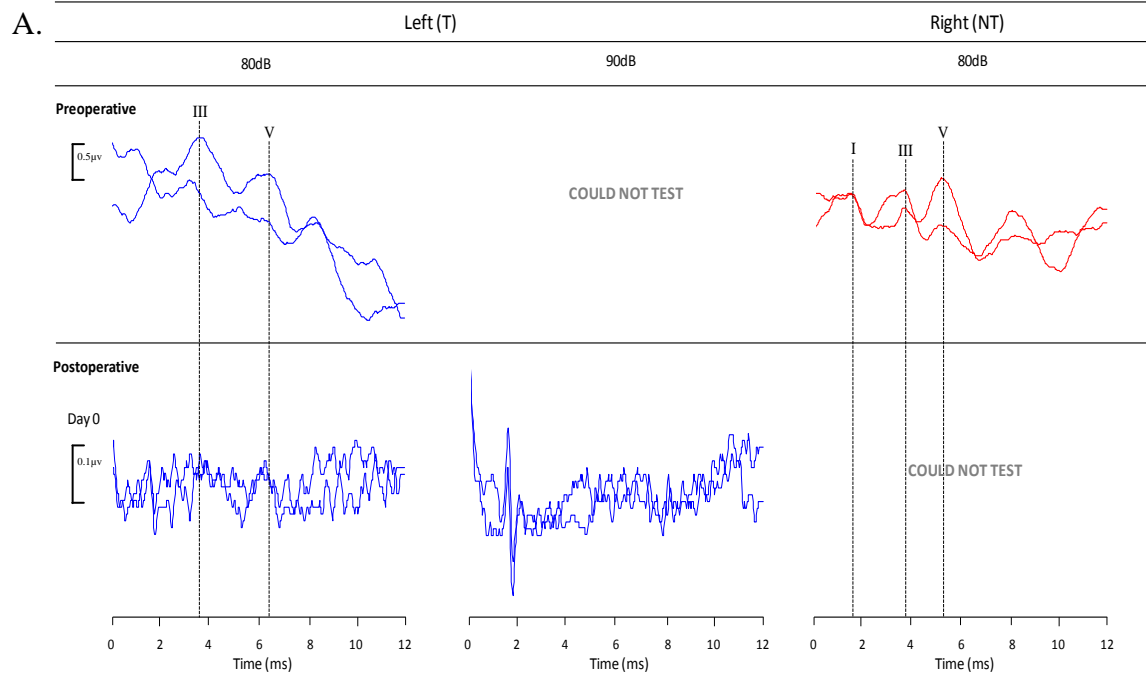
A.



B.

Preoperative tone decay		
Ear tested	Tone intensity (dB HL)	Tone duration (s)
Left (NT)	15	60
Right (T)	15	60

Case 3: Pre- and postoperative electrophysiological audiology test results. Part A shows ABR results and Part B shows the latencies of waves present in the ABR traces. Part C shows contralateral and ipsilateral DPOAES.



B. Ipsilateral (left) peak latencies (ms)

Day	80 dB nHL					90 dB nHL				
	I	II	III	IV	V	I	II	III	IV	V
Preop	-	-	3.80	-	6.35	Could not test				
Postop	No identifiable peaks					No identifiable peaks				

Contralateral (right) peak latencies (ms)

Day	I	II	III	IV	V
Preop	1.55	-	3.70	-	5.38
Postop	Could not test				

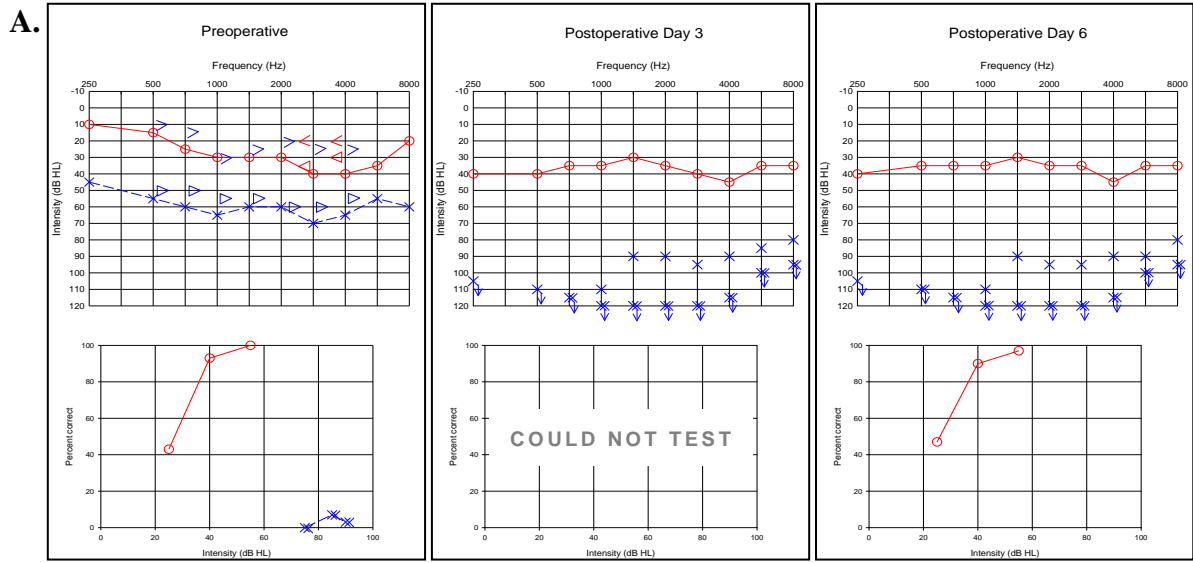
C. Ipsilateral (left) DPOAEs

Day	f_2 frequency (Hz)				
	2000	3000	4000	6000	8000
Preop	-	-	-	-	+
Postop 0	-	-	-	-	+
Postop 1	-	-	-	-	+
Postop 3	-	-	-	-	-
Postop 4	-	-	-	-	-
Postop 5	-	-	-	-	-
Postop 6	-	-	-	-	-

Contralateral (right) DPOAEs

Day	f_2 frequency (Hz)				
	2000	3000	4000	6000	8000
Preop	+	+	+	-	+
Postop 0	Could not test				
Postop 1	Could not test				
Postop 3	+	+	-	-	+
Postop 4	+	+	+	-	+
Postop 5	+	+	+	-	+
Postop 6	+	+	+	-	+

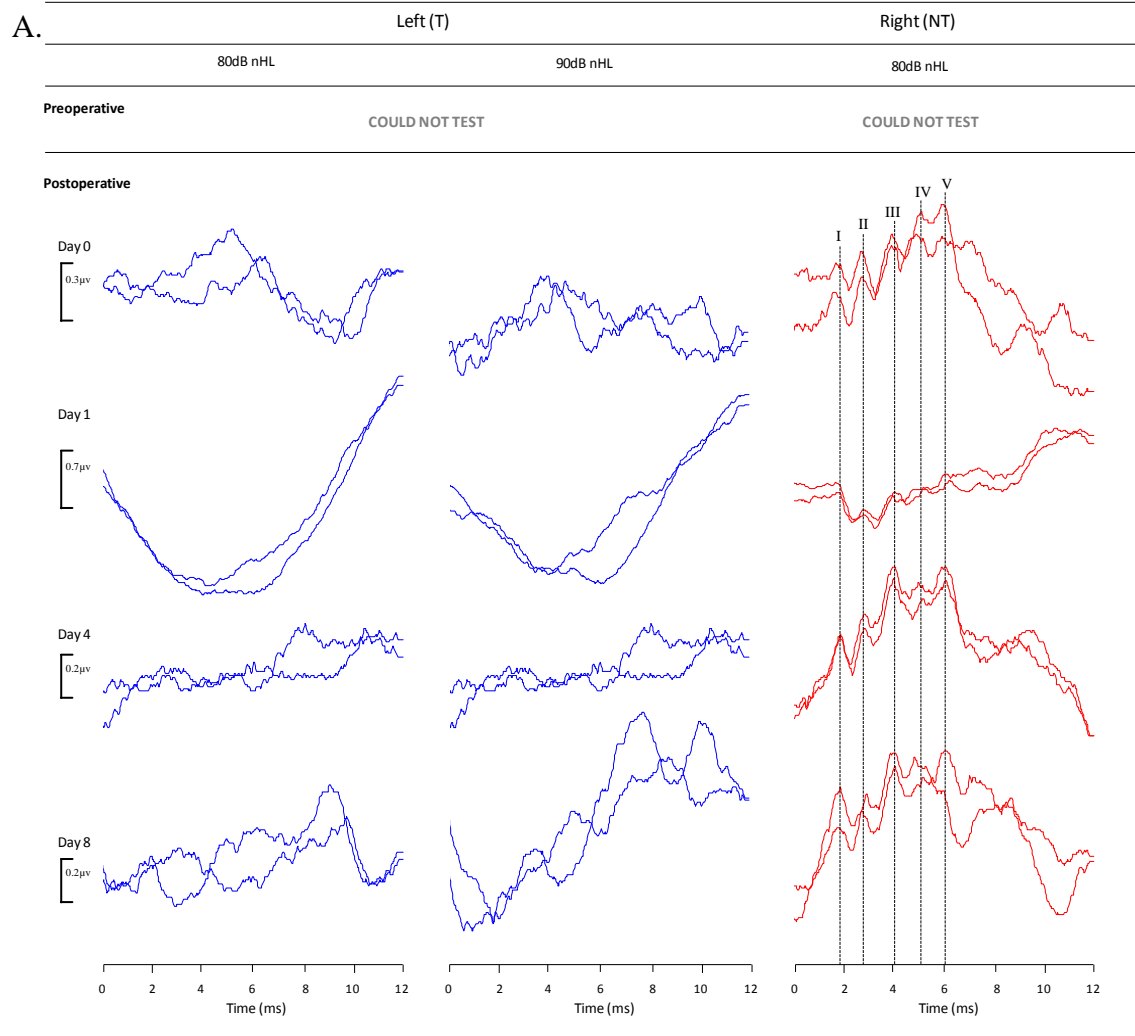
Case 3: Pre- and postoperative behavioural audiology test results. Part A shows pure-tone and speech discrimination test results and Part B shows tone decay test results.



B. Preoperative tone decay

Ear tested	Tone intensity (dB HL)	Tone duration (s)
Left (T)	65	0
	70	22
	75	60
Right (NT)	30	0
	35	18
	40	60

Case 4: Pre- and postoperative electrophysiological audiology test results. Part A shows ABR results and Part B shows the latencies of waves present in the ABR traces. Part C shows contralateral and ipsilateral DPOAES.



B. Ipsilateral (left) peak latencies (ms)

Day	80 dB nHL					90 dB nHL				
	I	II	III	IV	V	I	II	III	IV	V
Preop	Could not test					Could not test				
Postop	No identifiable peaks					No identifiable peaks				

Contralateral (right) peak latencies (ms)

Day	I	II	III	IV	V
Preop	Could not test				
Postop 0	1.85	2.92	3.95	5.25	5.80
Postop 1	1.82	2.83	3.92	5.22	-
Postop 4	1.85	2.83	3.95	5.13	5.87
Postop 8	1.83	2.88	4.00	5.17	5.87

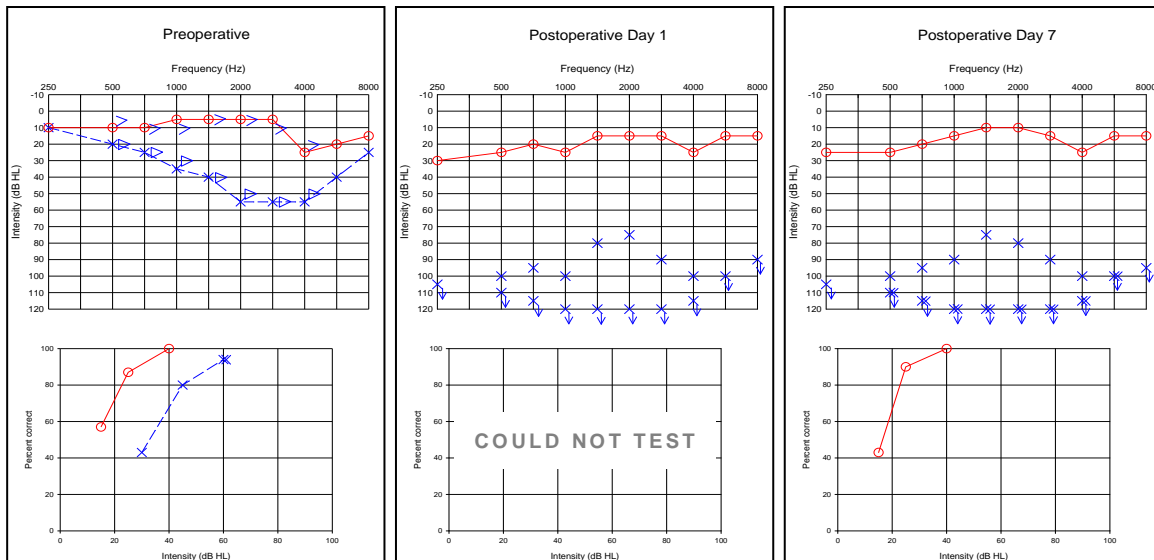
C. Ipsilateral (left) DPOAEs

Day	f_2 frequency (Hz)				
	2000	3000	4000	6000	8000
Preop	No data available				
Postop 0	+	-	-	-	-
Postop 1	+	-	-	-	-
Postop 4	-	-	-	-	-
Postop 8	-	-	-	-	-

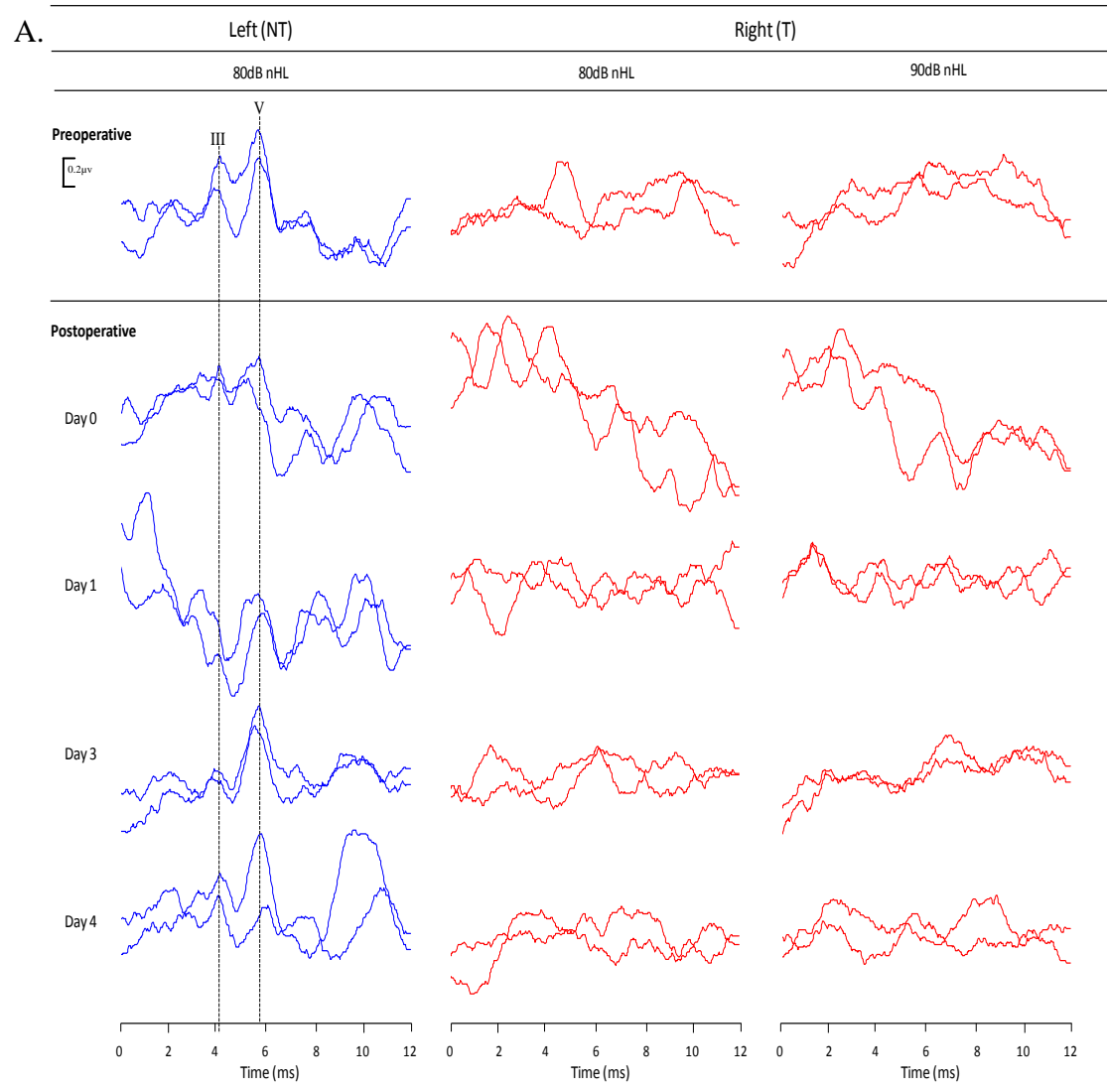
Contralateral (right) DPOAEs

Day	f_2 frequency (Hz)				
	2000	3000	4000	6000	8000
Preop	No data available				
Postop 0	+	+	+	+	+
Postop 1	+	+	+	+	+
Postop 4	+	+	+	+	+
Postop 8	+	+	+	+	+

Case 4: Pre- and postoperative pure-tone and speech discrimination test results.



Case 5: Pre- and postoperative electrophysiological audiology test results. Part A shows ABR results and Part B shows the latencies of waves present in the ABR traces. Part C shows contralateral and ipsilateral DPOAEs.



B. Contralateral (left) peak latencies (ms)

Day	I	II	III	IV	V
Preop	-	-	4.10	-	5.70
Postop 0	-	-	3.98	-	5.75
Postop 1	-	-	4.00	-	5.72
Postop 3	-	-	3.90	-	5.85
Postop 4	-	-	4.05	-	5.80

Ipsilateral (right) peak latencies (ms)

Day	80 dB nHL					90 dB nHL				
	I	II	III	IV	V	I	II	III	IV	V
Preop	No identifiable peaks					No identifiable peaks				
Postop	No identifiable peaks					No identifiable peaks				

C. Contralateral (left) DPOAEs

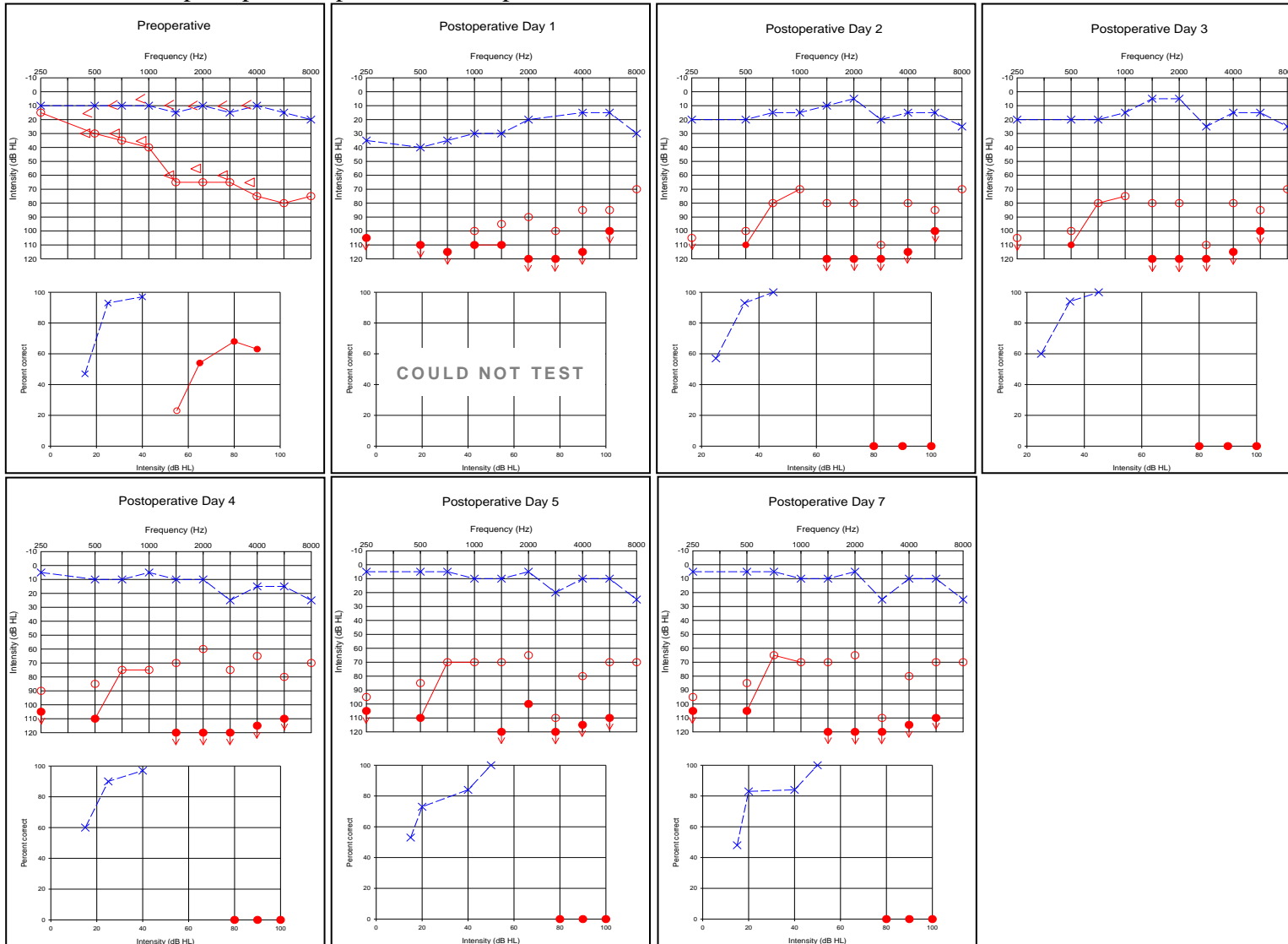
Day	f_2 frequency (Hz)				
	2000	3000	4000	6000	8000
Preop	+	+	+	-	+
Postop 0*	+	+	-	-	-
Postop 1	+	+	+	-	+
Postop 3	+	+	+	-	+
Postop 6	+	+	+	-	+
Postop 7	+	+	+	-	+

*High noise floor during testing

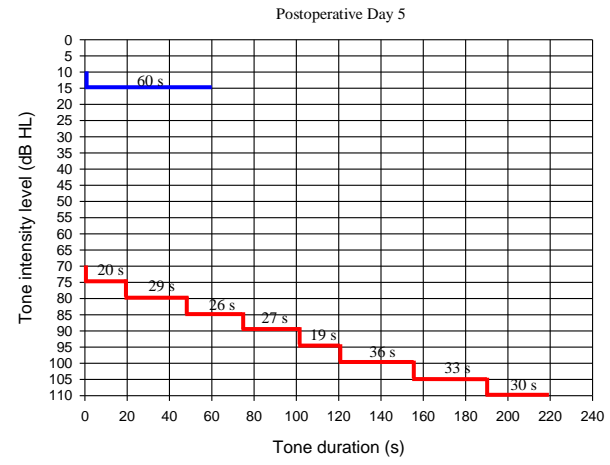
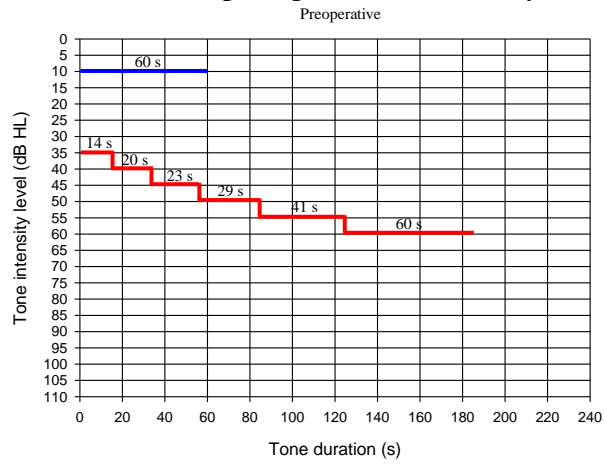
Ipsilateral (right) DPOAEs

Day	f_2 frequency (Hz)				
	2000	3000	4000	6000	8000
Preop	-	-	-	-	-
Postop 0*	-	-	-	-	-
Postop 1	-	-	-	-	-
Postop 3	-	-	-	-	-
Postop 6	-	-	-	-	-
Postop 7	-	-	-	-	-

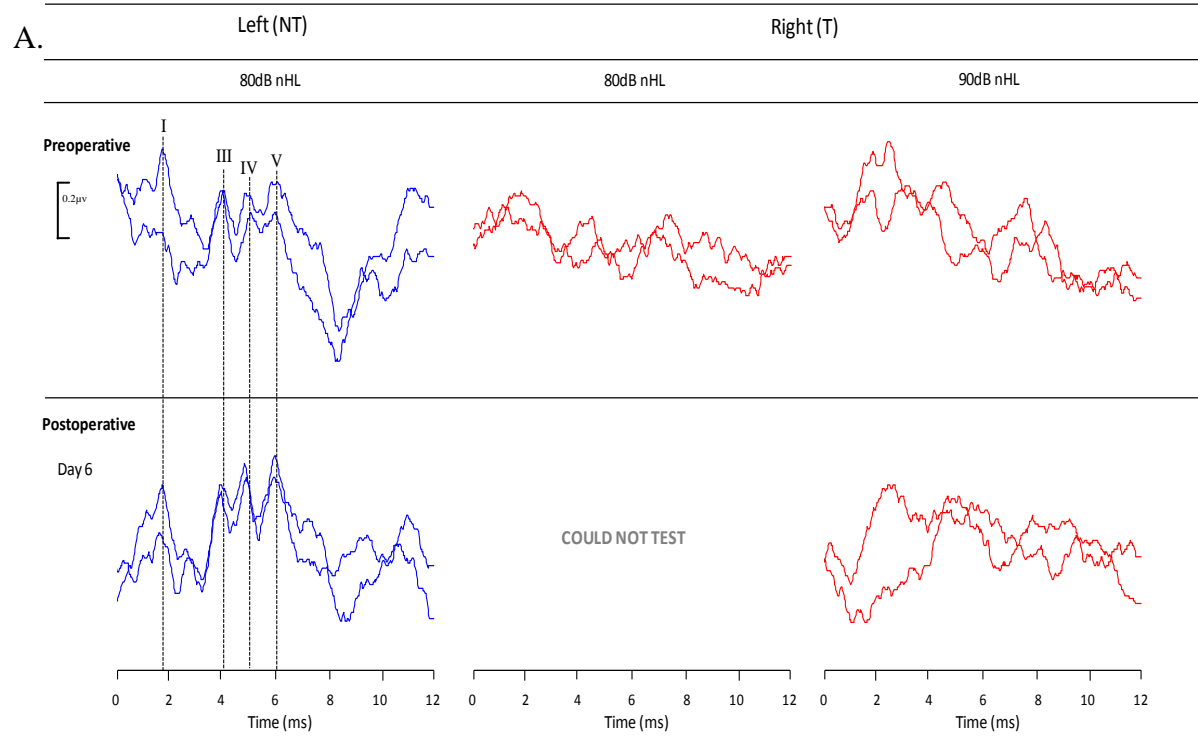
Case 5: Pre- and postoperative pure-tone and speech discrimination test results.



Case 5: Pre- and postoperative tone decay test results.



Case 6: Pre- and postoperative electrophysiological audiology test results. Part A shows ABR results and Part B shows the latencies of waves present in the ABR traces. Part C shows contralateral and ipsilateral DPOAES.



B. **Contralateral (left) peak latencies (ms)**

Day	I	II	III	IV	V
Preop	1.70	-	3.98	5.08	5.95
Postop 6	1.70	-	3.95	4.91	5.97

Ipsilateral (right) peak latencies (ms)

Day	80 dB nHL					90 dB nHL				
	I	II	III	IV	V	I	II	III	IV	V
Preop	No identifiable peaks					No identifiable peaks				
Postop 6	No identifiable peaks					No identifiable peaks				

C. **Contralateral (left) DPOAES**

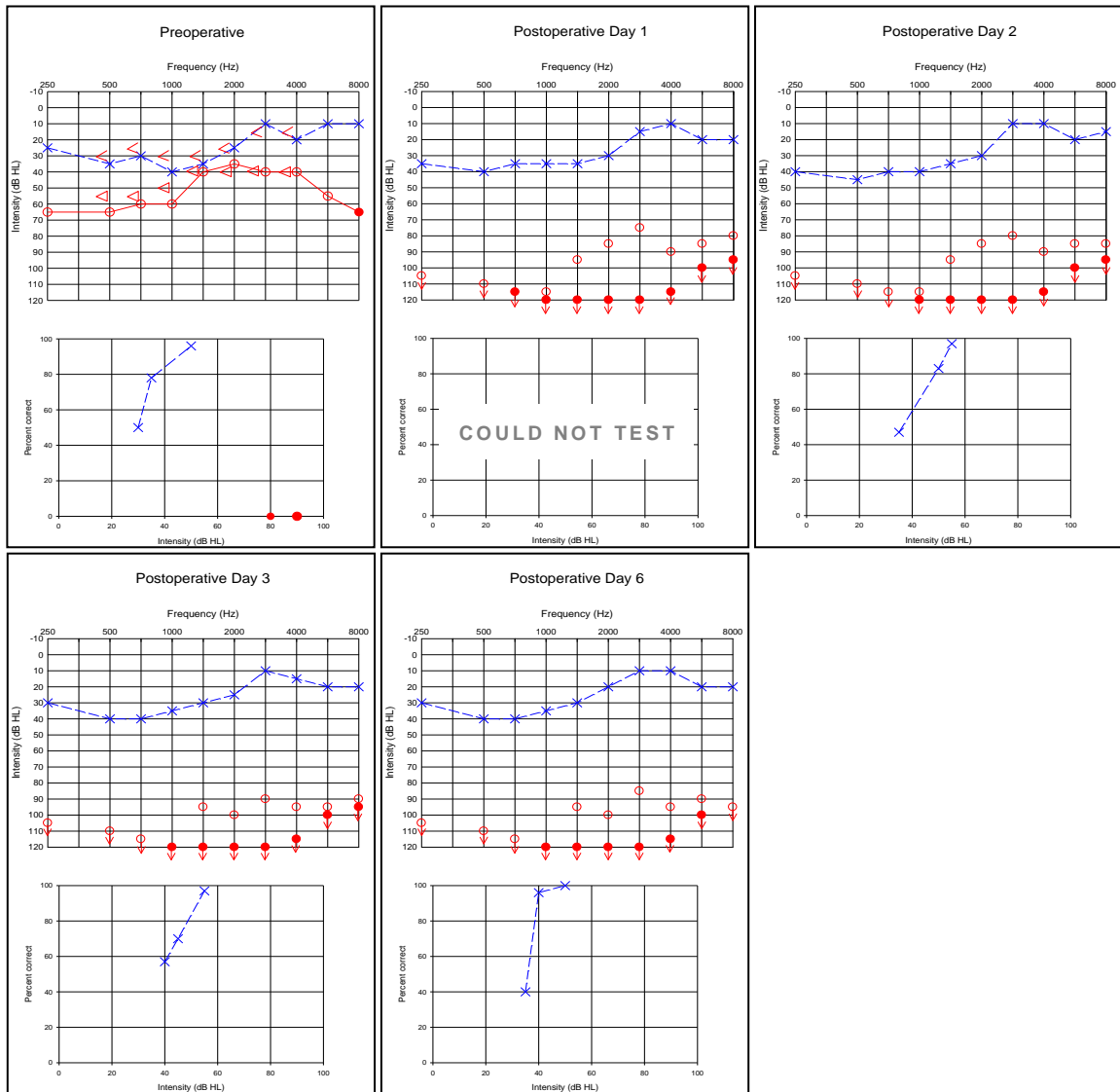
Day	f_2 frequency (Hz)				
	2000	3000	4000	6000	8000
Preop	+	+	+	+	-
Postop 0	Could not test				
Postop 1	+	+	+	+	-

Ipsilateral (right) DPOAES

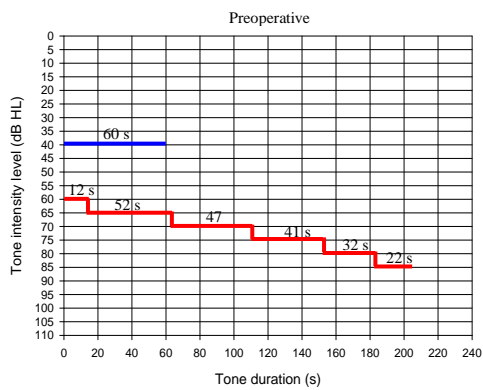
Day	f_2 frequency (Hz)				
	2000	3000	4000	6000	8000
Preop	+	+	+	-	-
Postop 0	-	-	-	-	-
Postop 1	-	-	-	-	-

Case 6: Pre- and postoperative behavioural audiology test results. Part A shows pure-tone and speech discrimination test results and Part B shows tone decay test results.

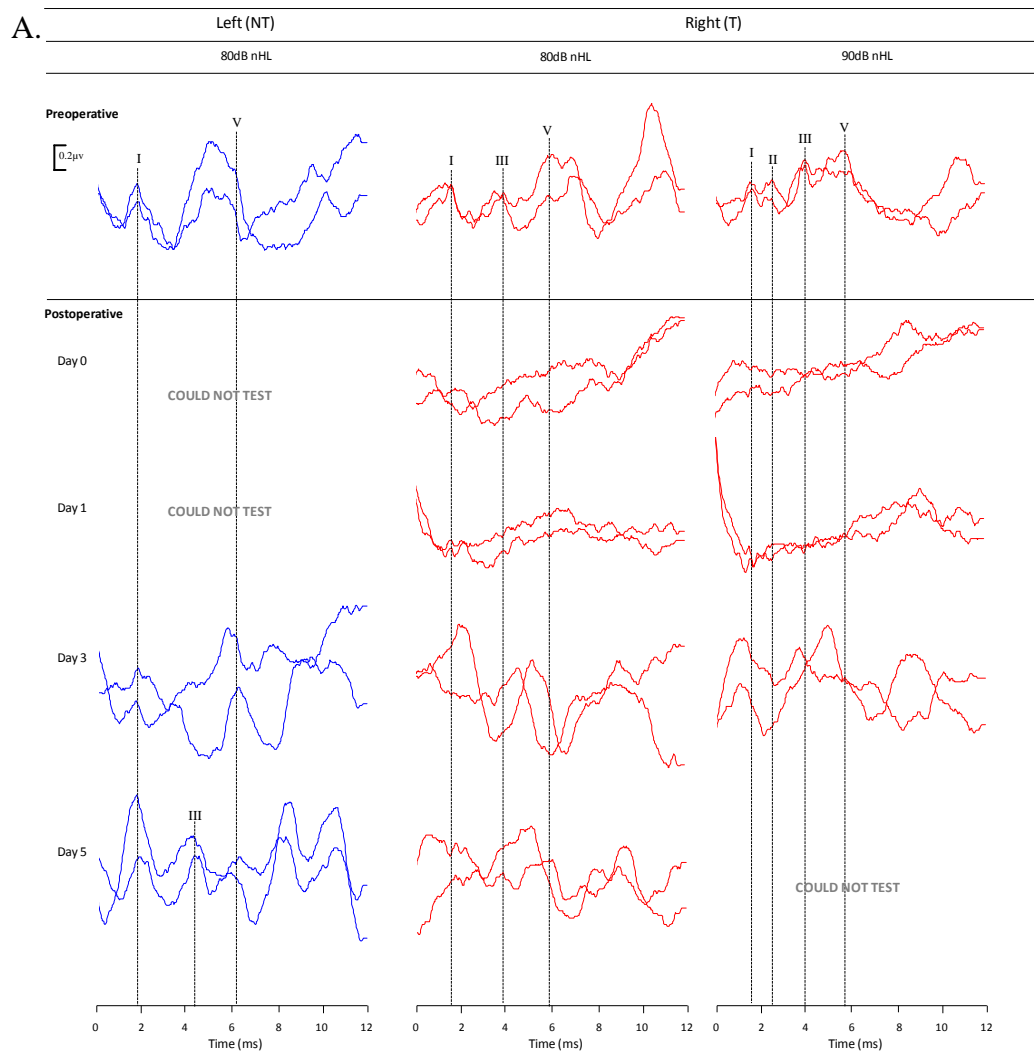
A.



B.



Case 7: Pre- and postoperative electrophysiological audiology test results. Part A shows ABR results and Part B shows the latencies of waves present in the ABR traces. Part C shows contralateral and ipsilateral DPOAES.



B. Contralateral (left) peak latencies (ms)

Day	I	II	III	IV	V
Preop	1.73	-	-	-	5.92
Postop 0	Could not test				
Postop 1	Could not test				
Postop 3	1.71	-	-	-	6.00
Postop 5	1.77	-	4.45	-	6.03

Ipsilateral (right) peak latencies (ms)

Day	80 dB nHL					90 dB nHL				
	I	II	III	IV	V	I	II	III	IV	V
Preop	1.63	-	3.85	-	6.10	1.60	2.52	3.98	-	5.92
Postop	No identifiable peaks					No identifiable peaks				

C. Contralateral (left) DPOAEs

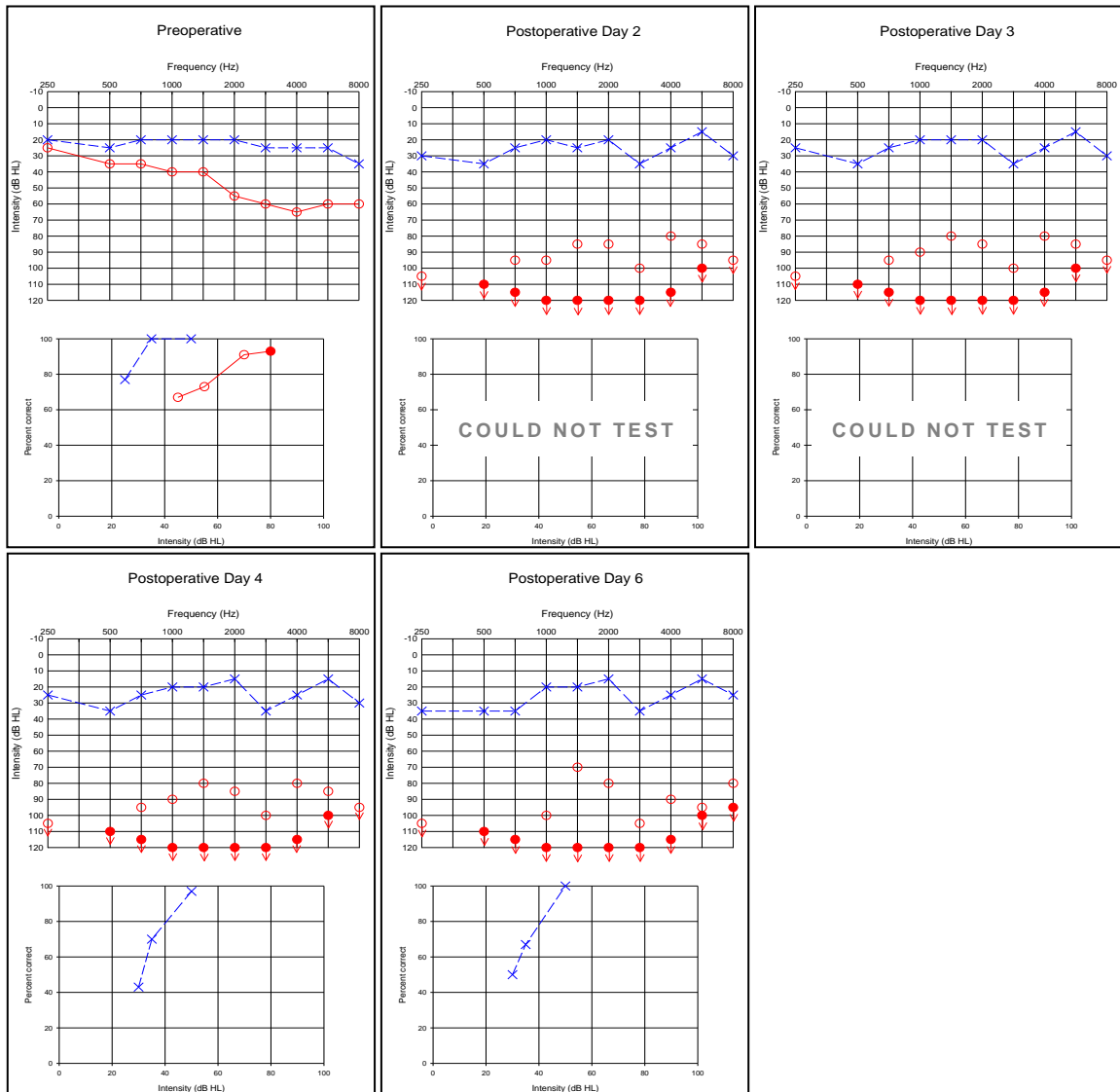
Day	f_2 frequency (Hz)				
	2000	3000	4000	6000	8000
Preop	+	+	-	-	-
Postop 0	Could not test				
Postop 5	+	+	-	-	-

Ipsilateral (right) DPOAEs

Day	f_2 frequency (Hz)				
	2000	3000	4000	6000	8000
Preop	-	-	-	-	-
Postop 0	-	-	-	-	-
Postop 5	-	-	-	-	-

Case 7: Pre- and postoperative behavioural audiology test results. Part A shows pure-tone and speech discrimination test results and Part B shows tone decay test results.

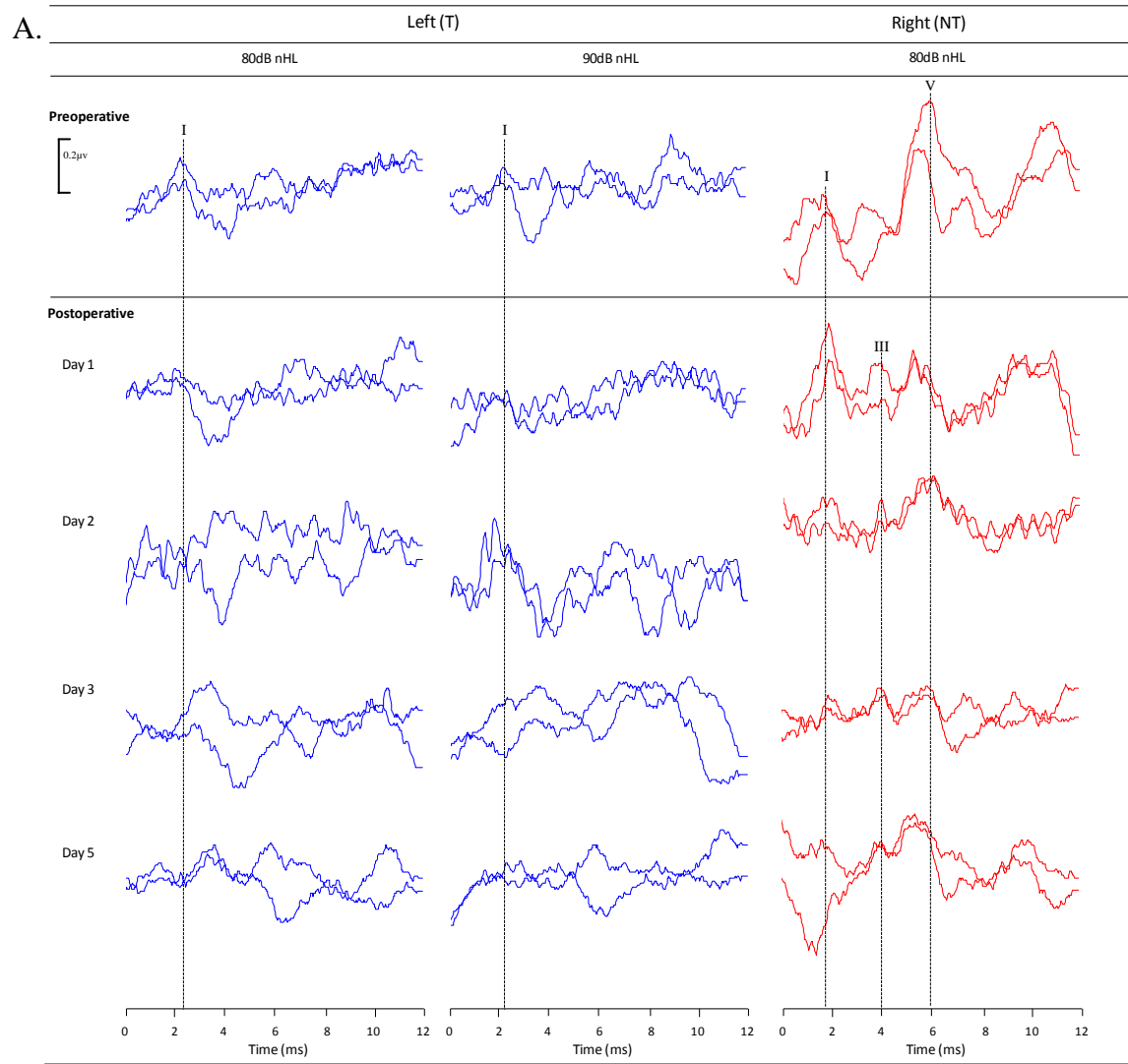
A.



B. Preoperative tone decay

Ear tested	Tone intensity (dB HL)	Tone duration (s)
Left (T)	20	60
Right (NT)	40	20
	45	60

Case 9: Pre- and postoperative electrophysiological audiology test results. Part A shows ABR results and Part B shows the latencies of waves present in the ABR traces. Part C shows contralateral and ipsilateral DPOAES.



B. Ipsilateral (left) peak latencies (ms)

Day	80 dB nHL					90 dB nHL				
	I	II	III	IV	V	I	II	III	IV	V
Preop	2.20	-	-	-	-	2.13	-	-	-	-
Postop	No identifiable peaks					No identifiable peaks				

Contralateral (right) peak latencies (ms)

Day	I	II	III	IV	V
Preop	1.67	-	-	-	5.80
Postop 1	1.83	-	4.10	-	5.79
Postop 2	1.75	-	3.98	-	5.92
Postop 3	1.85	-	4.08	-	5.97
Postop 5	-	-	3.95	-	5.79

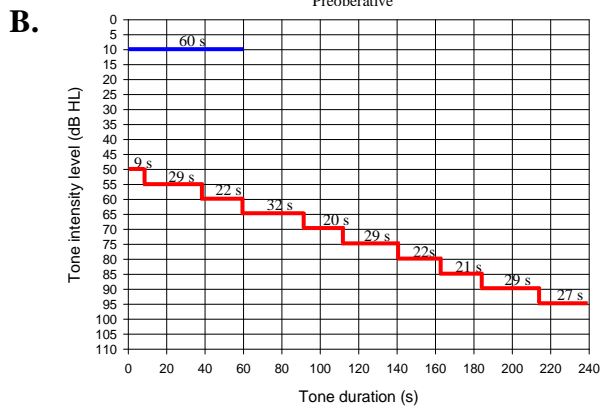
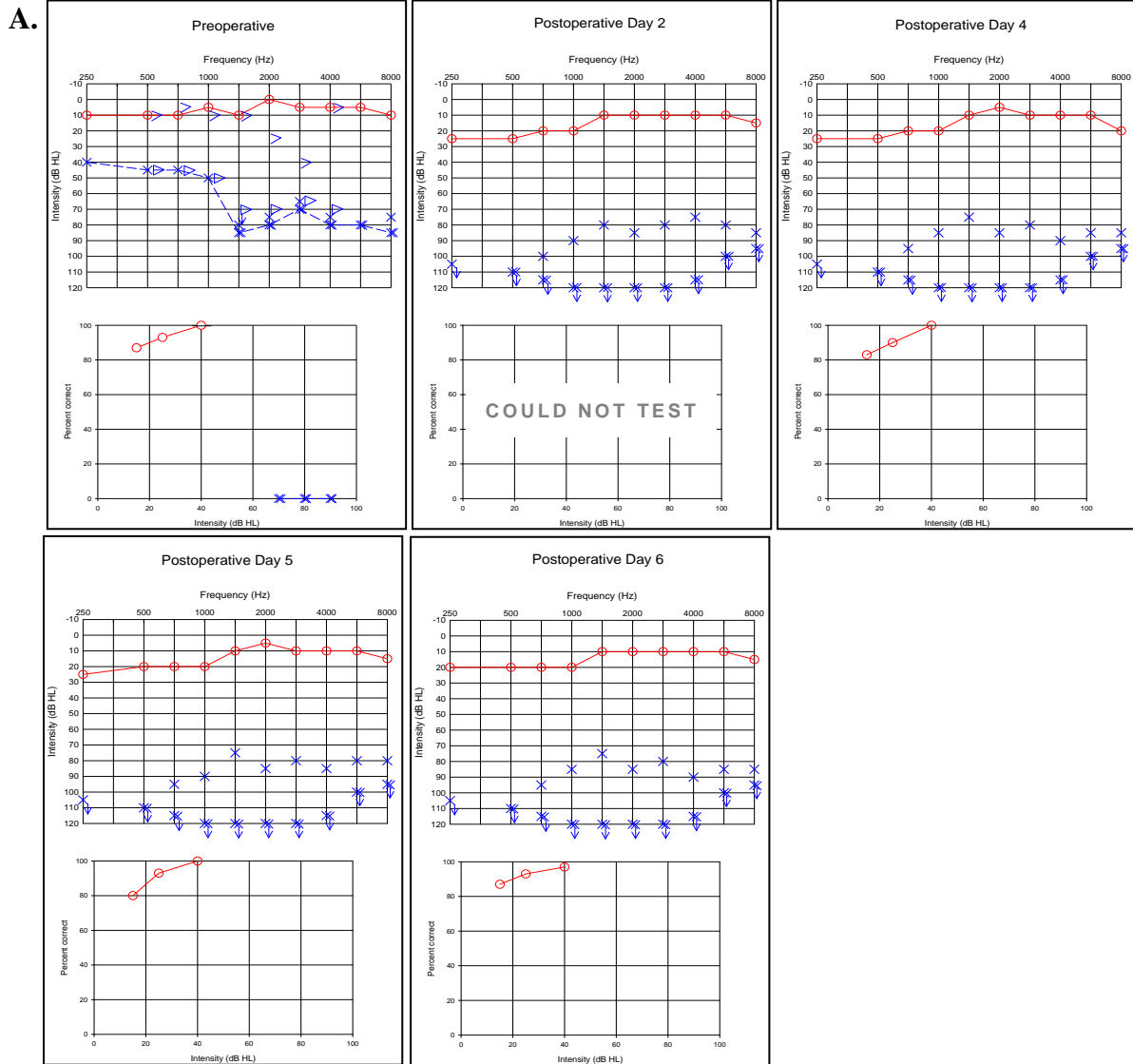
C. Ipsilateral (left) DPOAES

Day	f_2 frequency (Hz)				
	2000	3000	4000	6000	8000
Preop	-	-	-	-	+
Postop 1	-	-	-	-	-
Postop 2	-	-	-	-	-
Postop 5	-	-	-	-	-

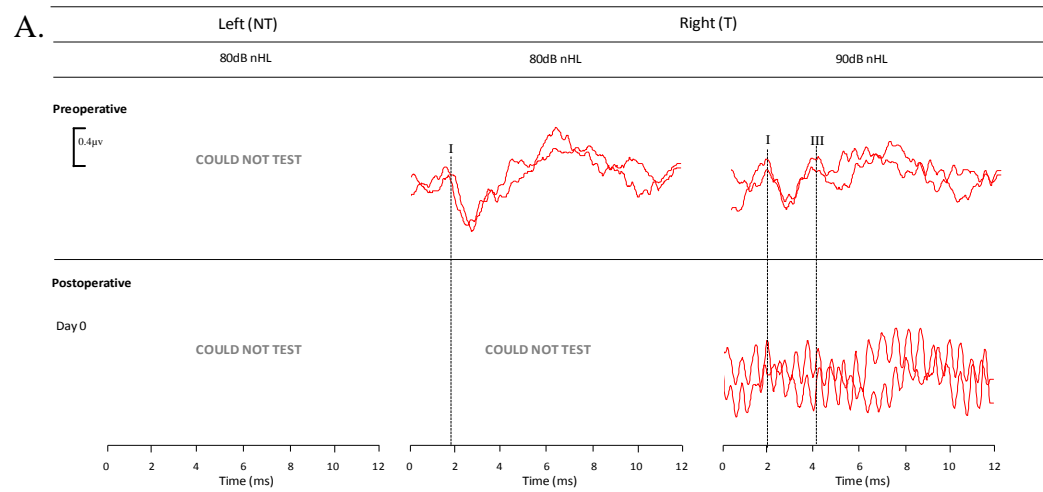
Contralateral (right) DPOAES

Day	f_2 frequency (Hz)				
	2000	3000	4000	6000	8000
Preop	+	+	+	+	+
Postop 1	Could not test				
Postop 2	+	+	+	+	+
Postop 5	+	+	+	+	+

Case 9: Pre- and postoperative behavioural audiology test results. Part A shows pure-tone and speech discrimination test results and Part B shows tone decay test results.



Case 12: Pre- and postoperative audiological test results. Part A shows ABR results and Part B shows the latencies of waves present in the ABR traces. DPOAE presence or absence is indicated in Part C. Preoperative pure-tone and speech discrimination results are shown in Part D and tone decay test results are presented in Part E.



B. Ipsilateral (right) peak latencies (ms)

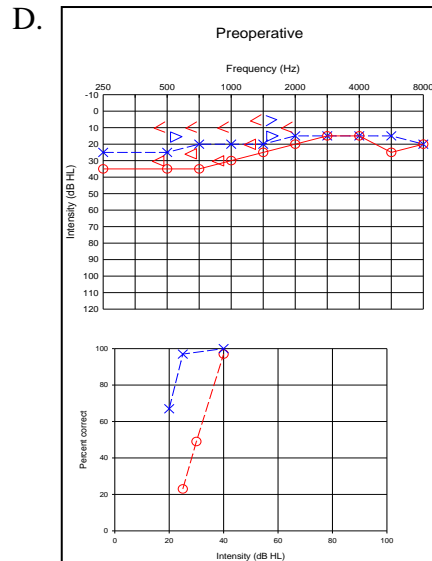
Day	80 dB nHL					90 dB nHL				
	I	II	III	IV	V	I	II	III	IV	V
Preop	1.70	-	-	-	-	1.63	-	3.90	-	-
Postop 0	Could not test					No identifiable peaks				

C. Contralateral (left) DPOAEs

Day	f_2 frequency (Hz)				
	2000	3000	4000	6000	8000
Preop	+	+	+	+	+
Postop 0	+	+	+	+	+
Postop 1	+	+	+	+	+

Ipsilateral (right) DPOAEs

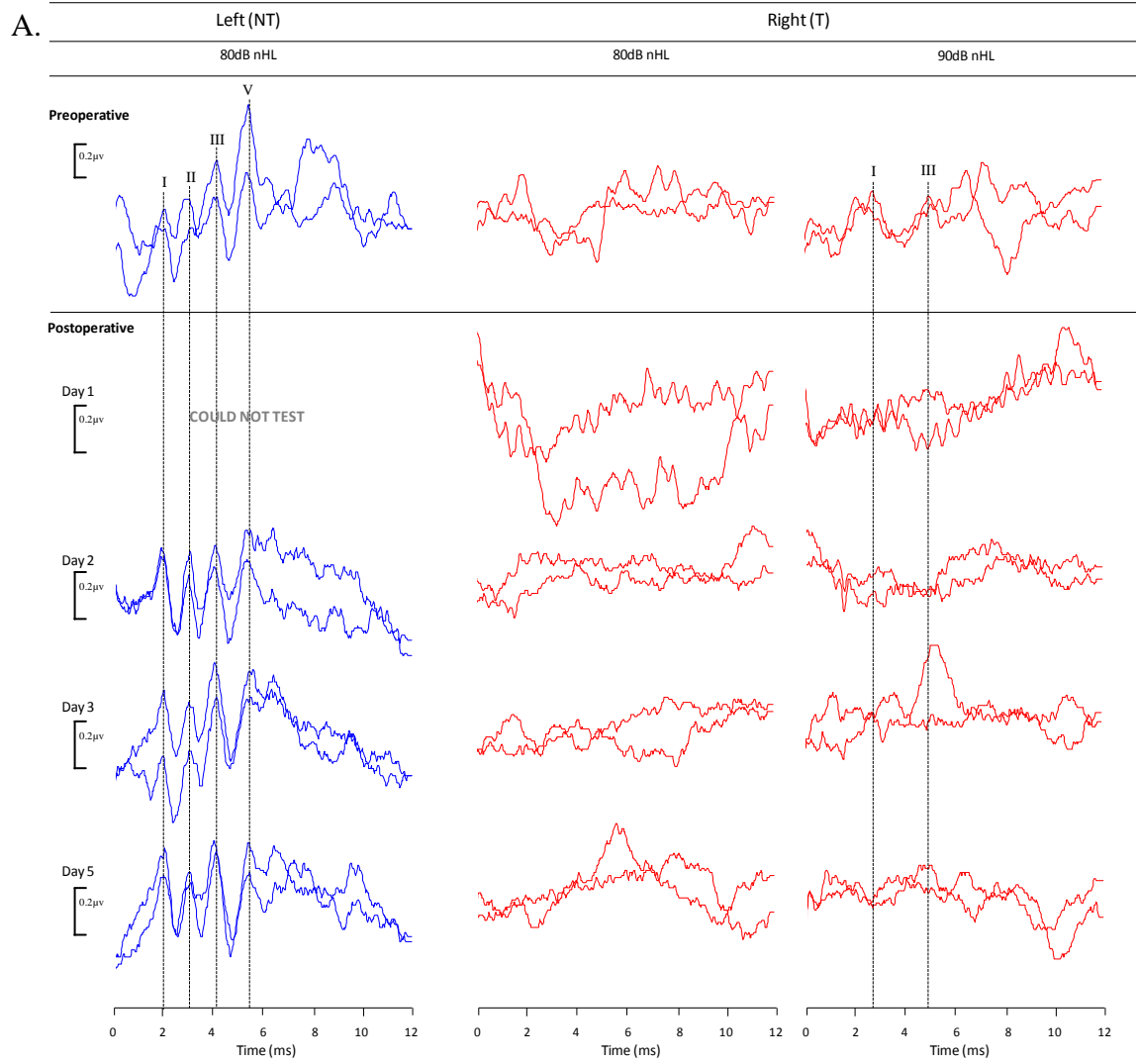
Day	f_2 frequency (Hz)			
	2000	3000	4000	8000
Preop	Could not test			
Postop 0	-	-	-	-
Postop 1	-	-	-	-



E. Preoperative tone decay

Ear tested	Tone intensity (dB HL)	Tone duration (s)
Left (NT)	20	60
Right (T)	30	60

Case 14: Pre- and postoperative electrophysiological audiology test results. Part A shows ABR results and Part B shows the latencies of waves present in the ABR traces. Part C shows contralateral and ipsilateral DPOAES.



B. Contralateral (left) peak latencies (ms)

Day	I	II	III	IV	V
Preop	1.99	3.00	4.10	-	5.38
Postop 1	Could not test				
Postop 2	1.93	3.00	4.03	-	5.42
Postop 3	1.93	3.02	4.00	-	5.53
Postop 5	1.98	3.00	4.03	-	5.42

Ipsilateral (right) peak latencies (ms)

Day	80 dB nHL					90 dB nHL				
	I	II	III	IV	V	I	II	III	IV	V
Preop	No identifiable peaks					2.55	-	5.30	-	-
Postop	No identifiable peaks					No identifiable peaks				

C. Contralateral (left) DPOAEs

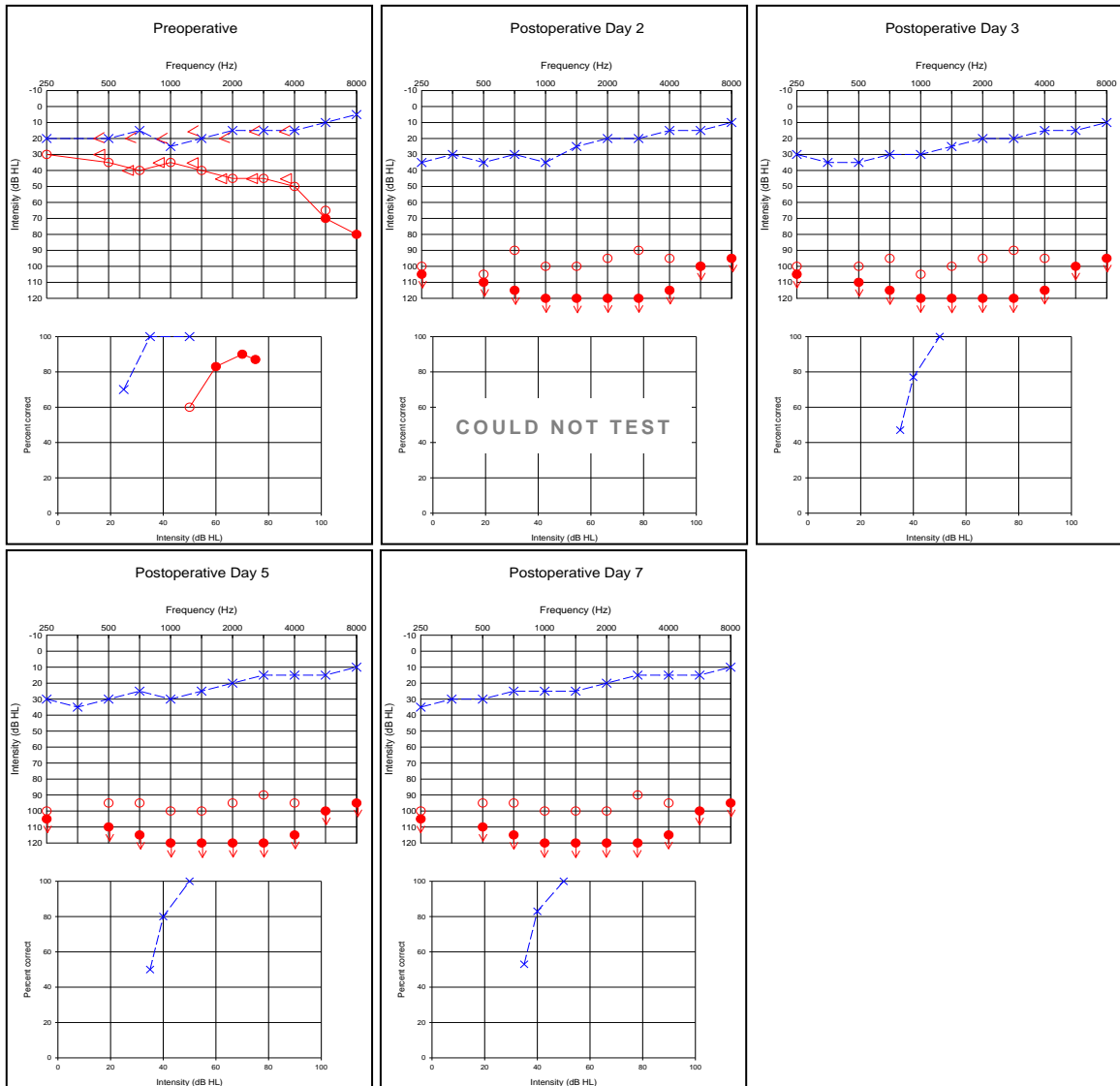
Day	f_2 frequency (Hz)				
	2000	3000	4000	6000	8000
Preop	+	+	+	+	+
Postop 1	+	+	+	+	+
Postop 2	+	+	+	+	+
Postop 3	+	+	+	+	+

Ipsilateral (right) DPOAEs

Day	f_2 frequency (Hz)				
	2000	3000	4000	6000	8000
Preop	+	+	+	+	+
Postop 1	-	-	-	-	-
Postop 2	-	-	-	-	-
Postop 3	-	-	-	-	-

Case 14: Pre- and postoperative behavioural audiology test results. Part A shows pure-tone and speech discrimination test results and Part B shows tone decay test results.

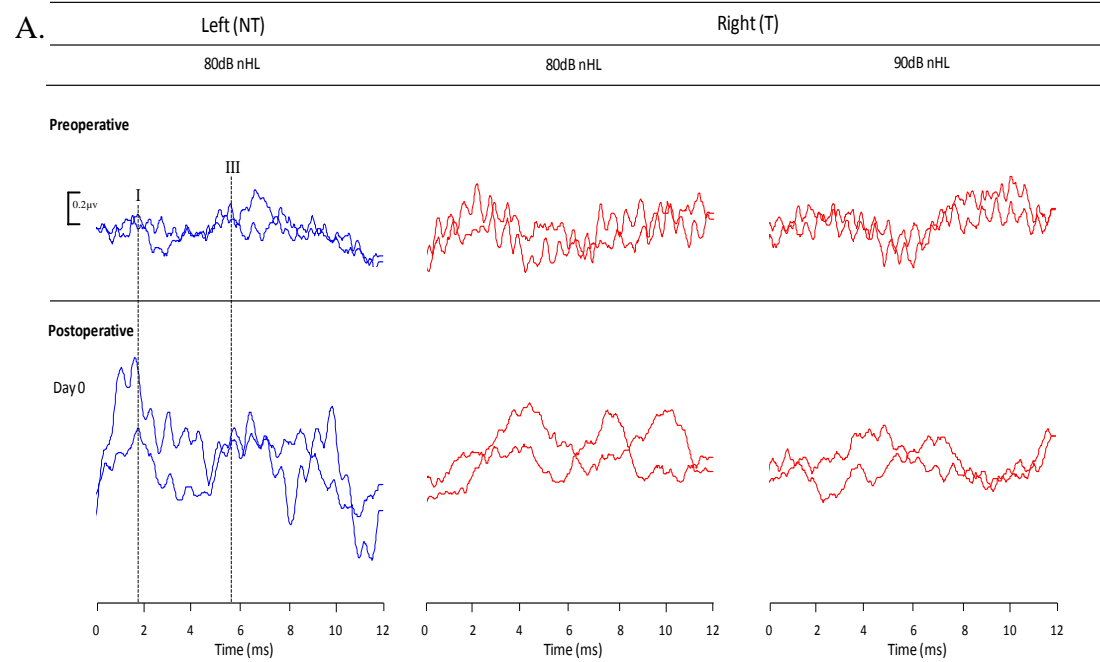
A.



B. Preoperative tone decay

Ear tested	Tone intensity (dB HL)	Tone duration (s)
Left (NT)	25	60
Right (T)	35	0
	40	48
	45	60

Case 15: Pre- and postoperative electrophysiological audiology test results. Part A shows ABR results and Part B shows the latencies of waves present in the ABR traces. Part C shows contralateral and ipsilateral DPOAEs.



B. Contralateral (left) peak latencies (ms)

Day	I	II	III	IV	V
Preop	1.77	-	-	-	5.63
Postop 1	1.70	-	-	-	5.78

Ipsilateral (right) peak latencies (ms)

Day	80 dB nHL					90 dB nHL				
	I	II	III	IV	V	I	II	III	IV	V
Preop	No identifiable peaks					No identifiable peaks				
Postop 1	No identifiable peaks					No identifiable peaks				

C. Contralateral (left) DPOAEs

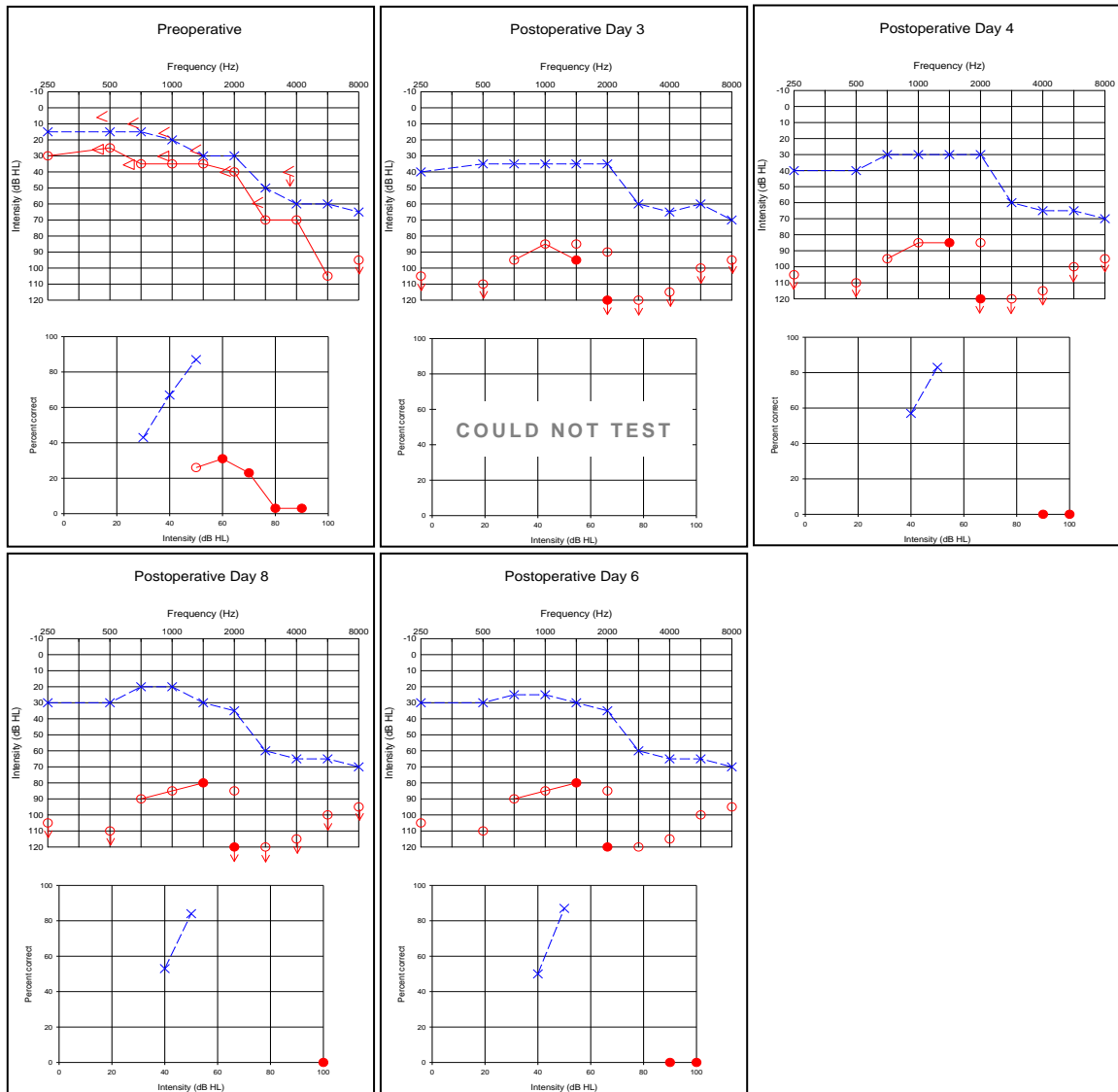
Day	f_2 frequency (Hz)				
	2000	3000	4000	6000	8000
Preop	-	-	-	-	-
Postop 1	-	-	-	-	-

Ipsilateral (right) DPOAEs

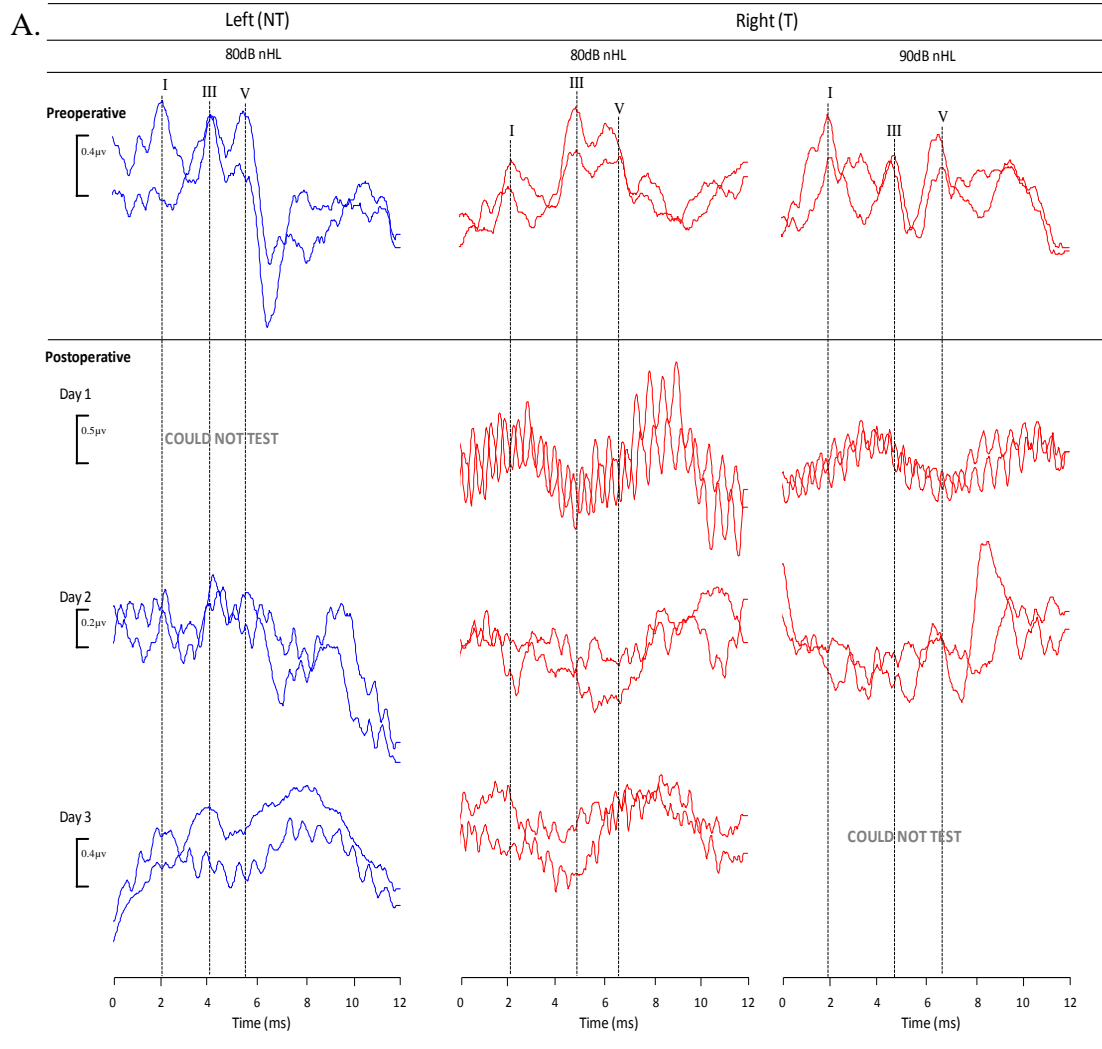
Day	f_2 frequency (Hz)				
	2000	3000	4000	6000	8000
Preop	-	-	-	-	-
Postop 1	-	-	-	-	-

Case 15: Pre- and postoperative behavioural audiology test results. Part A shows pure-tone and speech discrimination test results.

A.



Case 18: Pre- and postoperative electrophysiological audiology test results. Part A shows ABR results and Part B shows the latencies of waves present in the ABR traces. Part C shows contralateral and ipsilateral DPOAES.



B. Contralateral (left) peak latencies (ms)

Day	I	II	III	IV	V
Preop	1.95	-	4.12	-	5.70
Postop 1	Could not test				
Postop 2	2.02	-	4.27	-	-
Postop 3	-	-	4.08	-	-

Ipsilateral (right) peak latencies (ms)

Day	80 dB nHL					90 dB nHL				
	I	II	III	IV	V	I	II	III	IV	V
Preop	2.13	-	4.80	-	6.70	1.98	-	4.70	-	6.55
Postop	No identifiable peaks					No identifiable peaks				

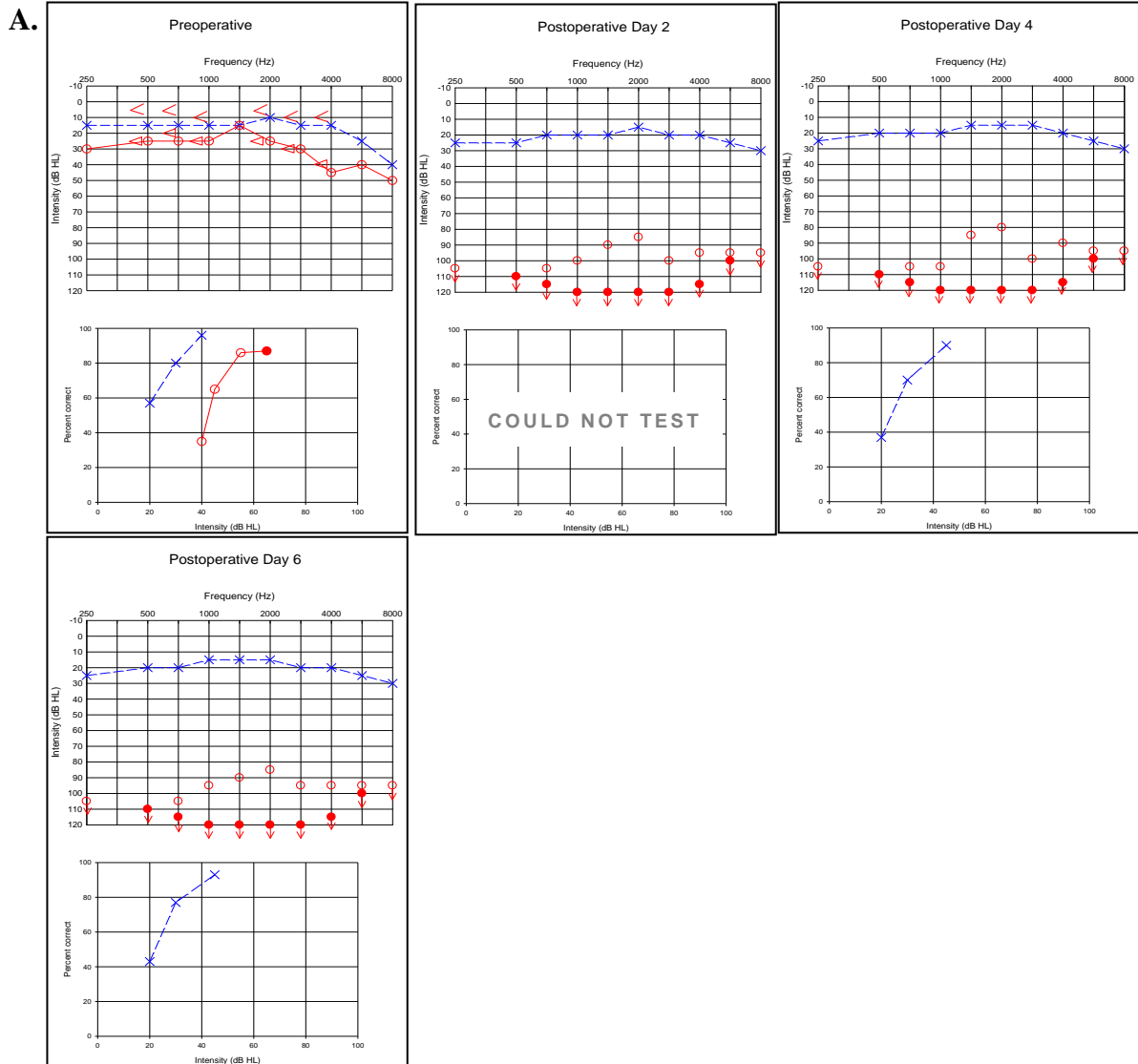
C. Contralateral (left) DPOAEs

Day	f_2 frequency (Hz)				
	2000	3000	4000	6000	8000
Preop	-	+	+	-	-
Postop 1	Could not test				
Postop 2	-	+	+	-	-
Postop 3	-	+	+	-	-

Ipsilateral (right) DPOAEs

Day	f_2 frequency (Hz)				
	2000	3000	4000	6000	8000
Preop	-	-	+	-	-
Postop 1	-	-	-	-	-
Postop 2	-	-	-	-	-
Postop 3	-	-	-	-	-

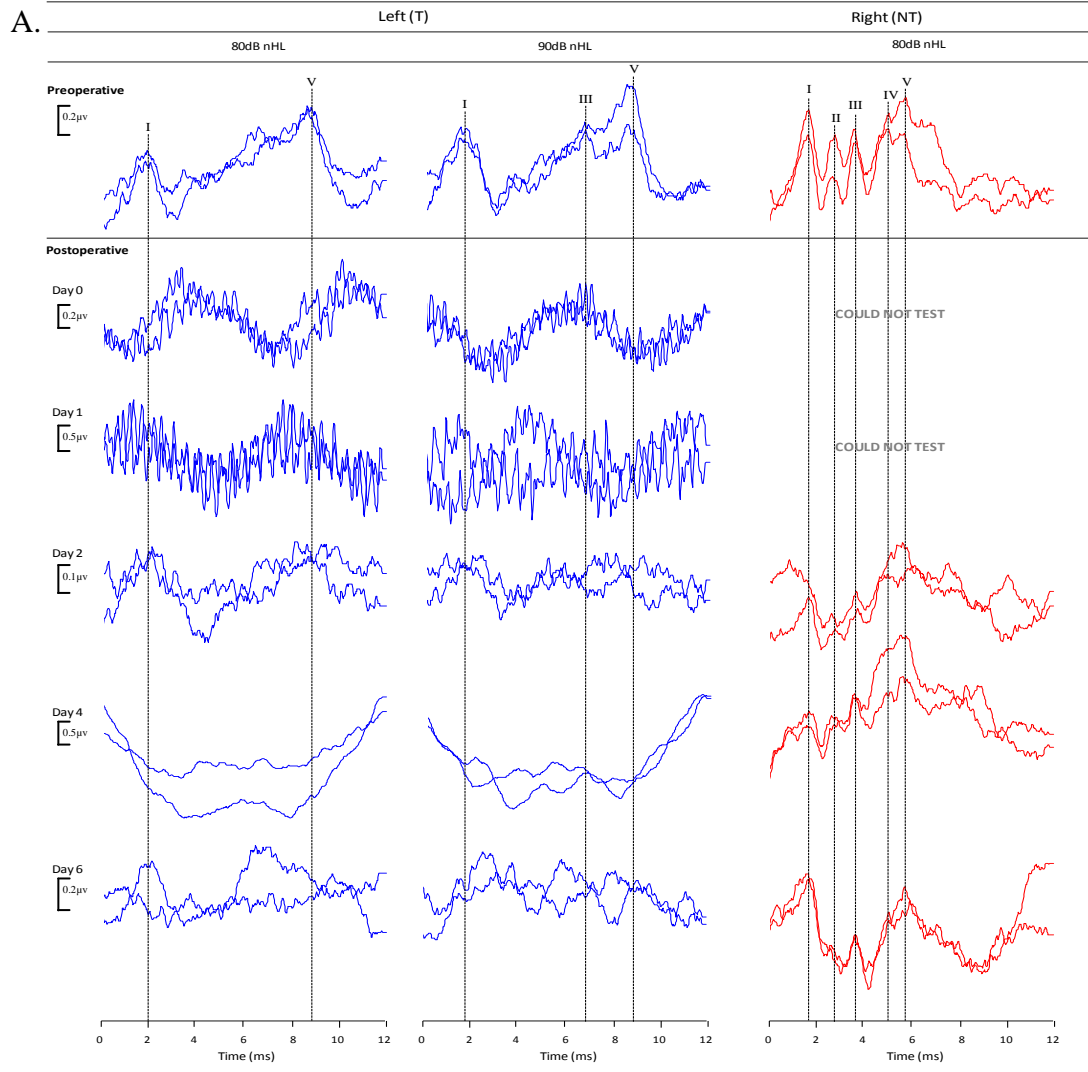
Case 18: Pre- and postoperative behavioural audiology test results. Part A shows pure-tone and speech discrimination test results and Part B shows tone decay test results.



B.

Preoperative tone decay		
Ear tested	Tone intensity (dB HL)	Tone duration (s)
Left (NT)	15	60
Right (T)	25	60

Case 19: Pre- and postoperative electrophysiological audiology test results. Part A shows ABR results and Part B shows the latencies of waves present in the ABR traces. Part C shows contralateral and ipsilateral DPOAEs.



B. Ipsilateral (left) peak latencies (ms)

Day	80 dB nHL					90 dB nHL				
	I	II	III	IV	V	I	II	III	IV	V
Preop	No identifiable peaks					No identifiable peaks				
Postop	No identifiable peaks					No identifiable peaks				

Contralateral (right) peak latencies (ms)

Day	I	II	III	IV	V
Preop	1.60	2.73	3.60	5.05	5.70
Postop 0	Could not test				
Postop 1	Could not test				
Postop 2	1.63	2.70	3.67	-	5.80
Postop 4	1.65	2.69	3.63	5.13	5.85
Postop 6	1.65	2.67	3.63	5.03	5.78

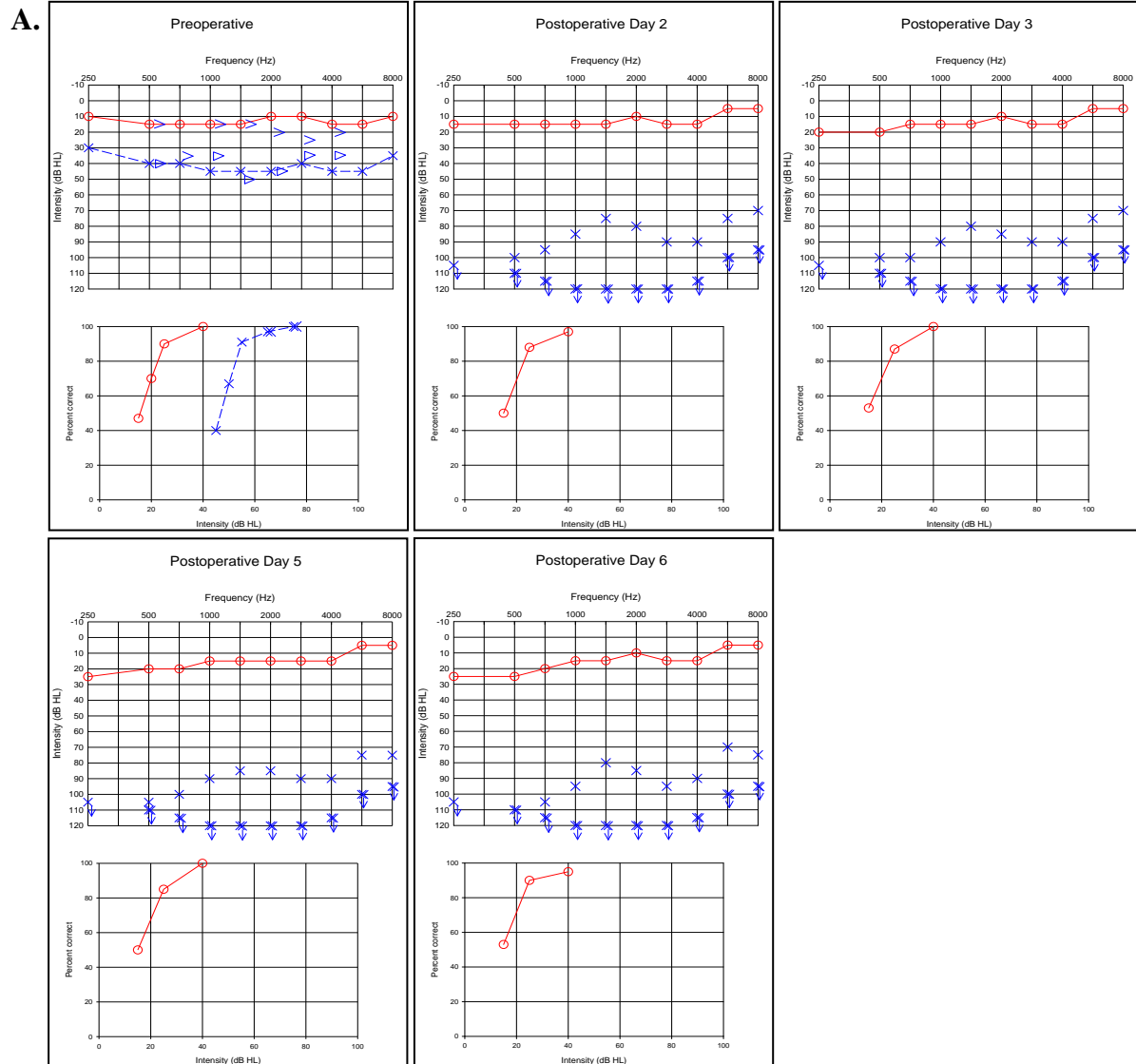
C. Ipsilateral (left) DPOAEs

Day	f_2 frequency (Hz)				
	2000	3000	4000	6000	8000
Preop	-	-	+	+	+
Postop 0	-	-	-	-	-
Postop 1	-	-	-	-	-
Postop 2	-	-	-	-	-
Postop 3	-	-	-	-	-
Postop 4	-	-	-	-	-
Postop 6	-	-	-	-	-

Contralateral (right) DPOAEs

Day	f_2 frequency (Hz)				
	2000	3000	4000	6000	8000
Preop	+	+	+	+	+
Postop 0	Could not test				
Postop 1	Could not test				
Postop 2	+	+	+	+	+
Postop 3	+	+	+	+	+
Postop 4	+	+	+	+	+
Postop 6	+	+	+	+	+

Case 19: Pre- and postoperative behavioural audiology test results. Part A shows pure-tone and speech discrimination test results and Part B shows tone decay test results.



B. Preoperative tone decay

Ear tested	Tone intensity (dB HL)	Tone duration (s)
Left (T)	45	60
Right (NT)	15	60

Case 19: ABR recorded from the ipsilateral ear at important points during vestibular schwannoma surgery. The dark traces show the waveforms following smoothing using a 21-point running average, and light traces show the raw data

