

Improvement of endothelial function early after thrombolytic therapy in patients with prosthetic heart valve thrombosis

Protez kalp kapak trombozu olan hastalarda trombolitik tedavinin hemen sonrasında endotel fonksiyonlarında gözlenen iyileşme

İD Beytullah Çakal, M.D.,¹ **İD** Macit Kalçık, M.D.,² **İD** Ahmet Güner, M.D.,³ **İD** Mahmut Yesin, M.D.,⁴
İD Mustafa Ozan Gürsoy, M.D.,⁵ **İD** Sabahattin Gündüz, M.D.,⁶ **İD** Süleyman Karakoyun, M.D.,⁴
İD Emrah Bayam, M.D.,⁷ **İD** Semih Kalkan, M.D.,⁶ **İD** Mehmet Özkan, M.D.⁸

¹Department of Cardiology, İstanbul Medipol University Hospital, İstanbul, Turkey; ²Department of Cardiology, Hitit University Faculty of Medicine, Çorum, Turkey; ³Department of Cardiology, Mehmet Akif Ersoy Thoracic and Cardiovascular Surgery Training and Research Hospital, İstanbul, Turkey; ⁴Department of Cardiology, Kafkas University Faculty of Medicine, Kars, Turkey; ⁵Department of Cardiology, İzmir Katip Çelebi University Atatürk Training and Research Hospital, İzmir, Turkey; ⁶Department of Cardiology, Kartal Koşuyolu High Specialization Training and Research Hospital, İstanbul, Turkey; ⁷Department of Cardiology, Ümraniye Training and Research Hospital, İstanbul, Turkey; ⁸Division of Health Sciences, Ardahan University, Ardahan, Turkey

ABSTRACT

Objective: Prosthetic valve thrombosis (PVT) is a serious complication among patients with prosthetic heart valves. Thrombolytic therapy (TT) is now widely used as first-line treatment for PVT. Endothelial dysfunction has previously been reported in patients with PVT. The aim of this study was to investigate the changes in endothelial function soon after TT in PVT patients.

Methods: The study group included 85 patients with PVT [female: 53 (62.3%); age: 48.7±13.9 years] who were evaluated prospectively before and shortly after TT. All of the patients were evaluated using transthoracic and transesophageal echocardiography. TT was administered in all cases with a low-dose, ultra-slow infusion regimen. Endothelial function was evaluated using a noninvasive measurement of flow-mediated dilatation (FMD) of the brachial artery during reactive hyperemia.

Results: The study population included 38 (44.7%) obstructive and 47 (55.3%) non-obstructive PVT patients. The obstructive PVT patients had lower baseline FMD values than the non-obstructive PVT group (5.31±0.76% vs. 5.87±0.84%; p=0.003). TT was successful in 79 patients (92.9%). FMD was significantly increased in the successfully thrombolyzed patients after TT (5.65±0.86% vs. 7.13±1.26%; p<0.001). There was no significant difference in the FMD values after TT in patients who were unresponsive to TT (5.07±0.61% vs. 5.38±0.95%; p=0.371). There was a significant increase in FMD values after TT in patients with obstructive PVT (5.31±0.76% vs. 8.22±1.15%; p<0.001). However, this difference was not statistically significant for patients with non-obstructive PVT (5.87±0.84% vs. 6.11±0.95%; p=0.276).

Conclusion: This study demonstrated that successful TT may contribute to improvement of impaired endothelial function in patients with obstructive PVT.

ÖZET

Amaç: Protez kapak trombozu (PKT) gelişimi protez kalp kapaklı hastalarda ciddi bir komplikasyondur. Son zamanlarda trombolitik tedavi (TT) PKT tedavisinde ilk tercih olarak yaygın olarak kullanılmaktadır. Daha önceki çalışmalarda PKT hastalarında endotel disfonksiyonunun varlığı bildirilmiştir. Bu çalışmada, PKT hastalarında TT sonrasında endotel fonksiyonlarında olan değişiklikleri araştırmayı amaçladık.

Yöntemler: Bu çalışmaya TT öncesi ve sonrası prospektif olarak takip edilen 85 PKT hastası [kadın: 53 (%62,3), ortalama yaş: 48,7±13,9 yıl] dahil edildi. Tüm hastalar transtoraksik ve transözofajiyal ekokardiyografi ile değerlendirildi. Tüm hastalarda düşük doz ultra yavaş infüzyon rejimine göre TT uygulandı. Endotel fonksiyonları reaktif hipereminin neden olduğu akım aracılı genişleme (Flow Mediated Dilatation, FMD) ölçülmesi ile değerlendirildi.

Bulgular: Çalışmaya 38 (%44,7) tıkalı ve 47 (%55,3) tıkalı olmayan PKT hastası alındı. Tıkalı PKT hastaları tıkalı olmayan PKT hastalarına göre daha düşük bazal FMD değerlerine sahiptiler (%5,31±0,76 ve %5,87±0,84; p=0,003). TT 79 (%92,9) PKT hastasında başarılı idi. Ortama FMD değerleri başarılı TT grubunda TT sonrasında anlamlı olarak yükseldi (%5,65±0,86 ve %7,13±1,26; p<0,001). Başarısız TT grubunda TT sonrası FMD değerlerinde anlamlı değişiklik izlenmedi (%5,07±0,61 ve %5,38±0,95; p=0,371). Tıkalı PKT olan hastalarda TT sonrasında FMD değerleri anlamlı olarak yükseldi (%5,31±0,76 ve %8,22±1,15; p<0,001). Fakat, tıkalı olmayan PKT hastalarında TT sonrası FMD değerlerinde anlamlı değişiklik izlenmedi (%5,87±0,84 ve %6,11±0,95; p=0,276).

Sonuç: Bu çalışmada, tıkalı PKT hastalarında başarılı TT'nin bozulan endotel fonksiyonlarının düzelmesine katkı sunabildiği gösterilmiştir.

Received: February 18, 2020 Accepted: April 14, 2020

Correspondence: Dr. Macit Kalçık. Hitit Üniversitesi Tıp Fakültesi, Kardiyoloji Anabilim Dalı, Çorum, Turkey.

Tel: +90 364 - 222 11 00 e-mail: macitkalcik@yahoo.com

© 2020 Turkish Society of Cardiology



The development of prosthetic valve thrombosis (PVT) represents one of the most important causes of morbidity and mortality in patients with prosthetic heart valves.^[1] The annual incidence of left-sided PVT may vary from 0.5% to 8% per patient^[2] and even reach 20% for mechanical prostheses in the tricuspid position.^[3] The most common cause of PVT is inadequate anticoagulant therapy.^[4] The presenting clinical picture ranges from the absence of symptoms to cardiogenic shock. The traditional treatment of this complication has been emergency surgery, but thrombolytic therapy (TT), which has been available for many years, is considered first-line treatment in the current guidelines.^[5] There have been reports from several trials regarding the safety and efficacy of TT regimens with a low-dose and slow infusion of tissue-type plasminogen activator (t-PA) in PVT patients, including pregnant patients.^[6,7] More recently, results of the PROMETEE trial (PROsthetic MEchanical valve Thrombosis and the prEdictors of outcome) demonstrated that an ultra-slow (25 hours) infusion of low-dose (25 mg) t-PA without a bolus appears to be associated with considerably lower rates of non-fatal complications and mortality for PVT patients without a loss of effectiveness.^[8]

Vascular endothelium secretes numerous factors that regulate cell growth, vascular tone, platelet and leukocyte interactions, and thrombogenicity. It has been recognized that endothelium takes part in some pathological processes during inflammation. The incremental role of inflammatory processes in PVT development was highlighted in a study reporting increased inflammatory parameters in patients with PVT.^[9]

Endothelial dysfunction has been associated with various cardiovascular disorders.^[10] Endothelial function had previously been investigated in patients with PVT, and it was reported that patients with PVT had endothelial dysfunction, which might contribute to the development of PVT.^[11] However, an association between endothelial dysfunction and PVT does not necessarily indicate causality. It is unclear whether endothelial dysfunction causes PVT or vice versa. Hence, this study was planned to investigate the reversibility of endothelial dysfunction in patients with PVT after successful TT.

METHODS

Study population

A total of 85 PVT patients [female: 53 (62.3%); mean age: 48.7±13.9 years] who underwent TT with a regimen of an ultra-slow infusion of low-dose t-PA were enrolled in this single-center study. Patients with end-stage liver or renal disorders, excessive alcohol consumption, active infection, acute coronary syndrome, renal insufficiency, pregnancy, chronic inflammatory disease, deep vein thrombosis, coagulopathy, or malignancies were excluded. A complete blood count and blood chemistry panel were completed for all of the patients at the time of admission. All of the patients provided written, informed consent and the study protocol was approved by the local ethics committee of Kartal Kosuyolu Training and Research Hospital, Istanbul, Turkey on October 20, 2014 (no: 2014.3/15). The research was conducted in accordance with the Declaration of Helsinki and The Guideline of Good Clinical Practice.

Abbreviations:

2D	Two-dimensional
FMD	Flow-mediated dilatation
PVT	Prosthetic valve thrombosis
RT 3D	Real-time three-dimensional
TEE	Transesophageal echocardiography
t-PA	Tissue-type plasminogen activator
TT	Thrombolytic therapy
TTE	Transthoracic echocardiography

Echocardiography

Transthoracic echocardiography (TTE) and 2-dimensional (2D) and real-time 3-dimensional (RT 3D) transesophageal echocardiography (TEE) were performed for each patient using an X7-2t transducer on an iE33 ultrasound machine (Philips Healthcare, Inc., Andover, MA, USA). Parasternal long-axis and short-axis views and the apical 5-chamber view were used during the TTE evaluation. Transmitral gradients and the effective orifice area were measured with 2D TTE according to the current guidelines.^[12] A TEE study was scheduled when there was an echocardiographic and/or clinical suspicion of PVT. A thrombus was recognized as a homogeneous, mobile, or fixed mass with similar echo density to the myocardium located at the valve occluder and/or valve struts and was visualized in all of the patients with PVT using echocardiography^[13] (Fig. 1). PVT was classified according to the identification of an obstructive or non-obstructive thrombus. The presence of an obstruction was defined on the basis of Doppler echocardiographic measure-

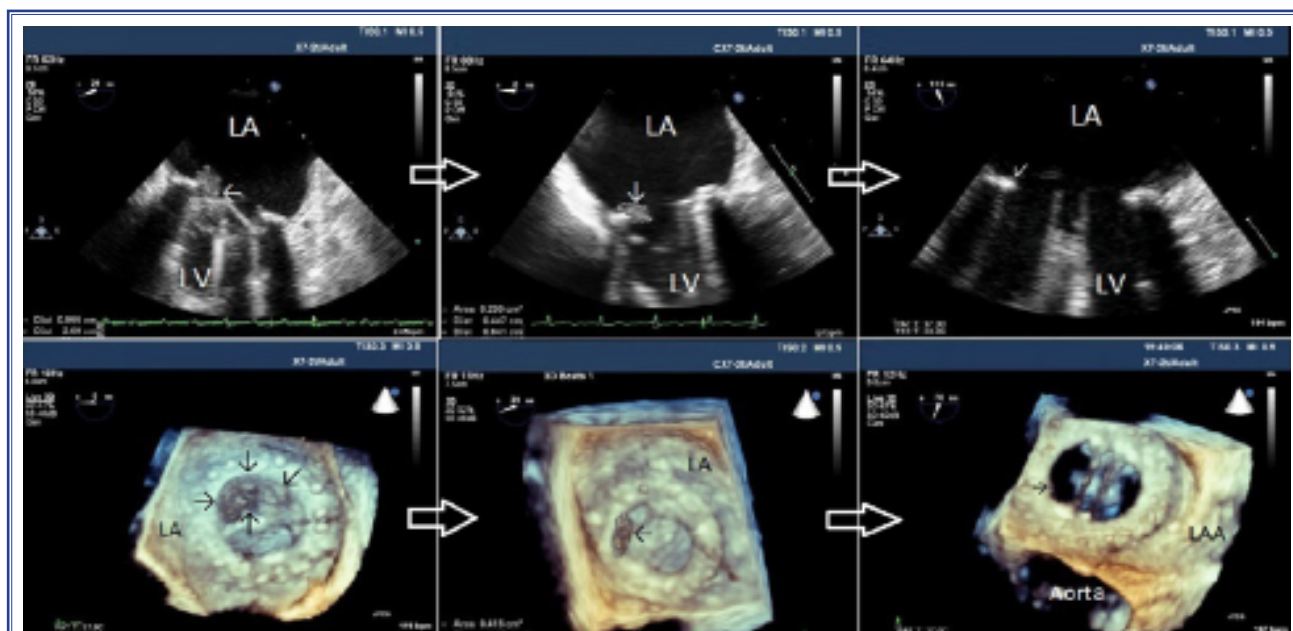


Figure 1. Serial 2-dimensional and real-time 3-dimensional transesophageal echocardiography images of obstructive prosthetic mitral valve thrombosis that was successfully treated with a low-dose ultra-slow infusion of tissue-type plasminogen activator. After 2 sessions of thrombolytic therapy, the thrombus burden was remarkably reduced. LA: Left atrium; LAA: Left atrium appendage; LV: Left ventricle.

ments (peak velocity, mean gradient, effective orifice area, dimensionless index, and acceleration time, as appropriate). The cut-off values for these Doppler parameters were defined based on recent recommendations.^[14]

The largest thrombus area was measured with 2D TEE between 0° and 180° where there was less interference from acoustic shadowing. In the presence of a single mass, the thrombus was traced. In cases of multiple thrombi, each was traced separately and the thrombus areas were summed.^[6–8]

Rationale for thrombolytic therapy

Based on previous reports regarding the safety and efficacy of a low-dose, ultra-slow infusion TT protocol^[4,8,15,16] in the absence of contraindications, a low-dose and ultra-slow TT regimen with a 25-hour infusion of 25 mg t-PA without a bolus (repeat up to 8 times if needed, maximum total dose of 200 mg) was administered as first-line therapy to all of the patients with obstructive PVT and those with non-obstructive PVT with a thrombus diameter of ≥ 10 mm according to the protocol described previously.^[17] Anticoagulation with intravenous unfractionated heparin was withheld during the t-PA infusion due to the increased risk of bleeding. All of the patients underwent serial

TTE and TEE examination between each TT session.

(A) Doppler documentation of complete improvement in valve hemodynamics and complete normalization of leaflet mobility, (B) reduction in major diameter and/or area of the thrombus by 75%, and (C) symptomatic improvement were considered the major criteria for TT success in patients with obstructive PVT in the absence of fatal and non-fatal major adverse events. For the patients with non-obstructive PVT, the only criterion for TT success was the complete lysis of the mobile component of the thrombus and an overall reduction in thrombus burden of $>50\%$.^[8]

Vascular assessment of flow-mediated dilatation

All of the patients were assessed at least 12 hours after their most recent meal, according to standard protocol.^[18] Patients were placed in the supine position for 10 minutes at rest before measurement. Right arm was fixed in an extended, relaxed position to provide correct analysis of the brachial artery 2–5 cm above the antecubital fossa. Next, the brachial artery was monitored longitudinally via a 17–5 MHz linear array ultrasound transducer (Vivid 5; GE Healthcare, Inc. Chicago, IL, USA). The brachial artery was scanned in the longitudinal section, the focus zone was set to optimize images of the lumen-arterial wall interface,

and the machine operating parameters were not altered for the remainder of the study. Measurements were taken from anterior to posterior M line at end-diastole, incident with the R wave on the electrocardiography. Three cardiac cycles (7 cardiac cycles in patients with atrial fibrillation) were analyzed for each scan, and the measurements were averaged. A baseline brachial artery diameter was evaluated and a cuff placed around the forearm distal to the scanned artery segment was inflated to about 30 mmHg above systemic systolic arterial pressure for 5 minutes. A maximal brachial artery diameter was established from 6 enrollments taken every minute after the cuff release. Percentage FMD was calculated using the formula of $FMD (\%) = (\text{maximum diameter} - \text{baseline diameter}) / \text{baseline diameter} \times 100$. Assessment of FMD values in the PVT patients was performed just before TT and repeated 6 hours after TT.

Statistical analysis

Statistical analyses were performed using IBM SPSS Statistics for Windows, Version 19.0 (IBM Corp., Armonk, NY, USA). Descriptive statistics were reported as mean \pm SD for continuous variables with normal distribution and median (25th-75th percentiles) values for continuous variables without normal distribution. Frequency with percentage was used for the categorical variables. The Shapiro-Wilk test was used to test the normality of the distribution of continuous variables. Since the data were from the same patients and paired before and after TT, the Wilcoxon signed rank or a paired sample t-test was used to analyze these results, as appropriate. Continuous variables for independent samples were compared between groups using the Student's t-test or the Mann-Whitney U test, as appropriate. Categorical variables were compared using a chi-square test. Correlational analyses were performed using Pearson, Kendall's tau or Spearman's correlation tests, as appropriate. The significance level was accepted as $p < 0.05$ in all of the statistical analyses.

RESULTS

Baseline demographic, clinical, and echocardiographic parameters of the study population are presented in Table 1. Laboratory parameters are included in Table 2. Study population was composed of 38 (44.7%) obstructive and 47 (55.3%) non-obstructive PVT patients. There were 22 aortic, 49 mitral, 11

aortic+mitral, and 3 tricuspid valve patients. The majority of the patients (69.4%) had subtherapeutic anticoagulation within the previous 3 months. The mean thrombus area was 0.9 cm² (range: 0.6–1.6 cm²) and the mean t-PA dose was 50 mg (range: 25–90 mg). TT was successful in 79 patients (92.9%) and failed in 6 patients. Two of those 6 patients underwent redo

Table 1. Baseline demographic, clinical, and echocardiographic characteristics of the study population

	PVT patients (n=85)
Age, (years)	48.7 \pm 13.9
Gender, n (%)	Male: 32 (37.7) Female: 53 (62.3)
Prosthetic valve position, n (%)	Mitral: 49 (57.7) Aortic: 22 (25.9) Aortic+mitral: 11 (12.9) Tricuspid: 3 (3.5)
Leaflet status, n (%)	Monoleaflet: 12 (14.1) Bileaflet: 73 (84.9)
Valve type, n (%)	St. Jude Medical: 29 (34.1) Carbomedics: 21 (24.7) Sorin-Bicarbon: 7 (8.2) Medtronic Hall: 12 (14.1) ATS Medical: 14 (16.5) Omnicarbon: 2 (2.4)
Elapsed time since valve surgery, (months)	61 (28–122)
Atrial fibrillation, n (%)	27 (36)
Left ventricular ejection fraction, (%)	51.8 \pm 5.3
Left atrial diameter, (mm)	42.6 \pm 5.1
New York Heart Association Functional Class, n (%)	I-II: 69 (81.1) III-IV: 16 (18.9)
Recent subtherapeutic anticoagulation, n (%)	59 (69.4)
Thrombus type, n (%)	OT: 38 (44.7) NOT: 47 (55.3)
Thrombus area, (cm ²)	1.3 (0.9–1.7)
Thrombolytic therapy outcome, n (%)	Successful: 79 (92.9) Failed: 6 (7.1)
Tissue type plasminogen activator dose, (mg)	50 (25–90)

NOT: Non-obstructive thrombus; OT: Obstructive thrombus; PVT: Prosthetic valve thrombosis.

surgery and 4 were followed up under strict anticoagulation. Complications of TT included 2 gastrointestinal bleeds (not requiring transfusion) and 2 transient ischemic attacks.

Data from comparisons of baseline and reactive

Table 2. Baseline laboratory characteristics of the study population

Laboratory parameters	PVT patients (n=85)
White blood cell ($\times 10^9/\mu\text{L}$)	6.7 (5.6–7.9)
Hemoglobin (g/dL)	11.2 \pm 1.3
Platelet ($\times 10^9/\text{mL}$)	214 (185–324)
Glucose (mg/dL)	102.5 (89–116)
Urea (mg/dL)	31.5 (27–41)
Creatinine (mg/dL)	0.8 (0.7–1.1)
Uric acid (mg/dL)	6.4 \pm 1.5
Aspartate aminotransferase (U/L)	28 (20–39)
Alanine aminotransferase (U/L)	17 (13–29)
Sodium (mEq/L)	138 (134–141)
Potassium (mEq/L)	4.2 (4.1–4.4)
Total bilirubin (mg/dL)	0.9 (0.5–1.2)
Erythrocyte sedimentation rate (mm/h)	29 (8.3–42)
C-reactive protein (mg/dL)	0.8 (0.3–1.7)
International normalized ratio on admission	1.8 (1.4–2.1)
Triglyceride (mg/dL)	135 (94–178)
Total cholesterol (mg/dL)	212 (174–235)
High-density lipoprotein (mg/dL)	46 (43–52)
Low-density lipoprotein (mg/dL)	124 (104–153)

PVT: Prosthetic valve thrombosis.

hyperemia-induced parameters between patients with obstructive and non-obstructive PVT can be seen in Table 3. The patients with obstructive PVT had lower baseline FMD values than the non-obstructive PVT group (5.31 \pm 0.76% vs. 5.87 \pm 0.84%; $p=0.003$). The impact of TT on endothelial parameters in obstructive PVT patients was more distinctive than that seen in the non-obstructive PVT group (Fig. 2).

Baseline and reactive hyperemia-induced endothelial parameters before and after TT in different subgroups of PVT patients are compared in Table 4. FMD was significantly increased in successfully thrombolysed patients after TT (5.65 \pm 0.86% vs. 7.13 \pm 1.26%; $p<0.001$) (Fig. 3a). There was no significant difference between FMD values before and after TT in patients who were unresponsive to TT (5.07 \pm 0.61% vs. 5.38 \pm 0.95%; $p=0.371$). There was a significant increase in FMD values after TT in patients with obstructive PVT (5.31 \pm 0.76% vs. 8.22 \pm 1.15%; $p<0.001$) (Fig. 3b). However, the difference was not significant in the non-obstructive PVT patients (5.87 \pm 0.84% vs. 6.11 \pm 0.95%; $p=0.276$) (Fig. 3c).

Correlation analysis yielded a statistically significant moderate and negative correlation between thrombus area and baseline FMD values in patients with PVT ($r=-0.573$; $p<0.001$) (Fig. 4a). Furthermore, there was a moderate positive correlation between the magnitude of change in FMD values and thrombus area (Fig. 4b).

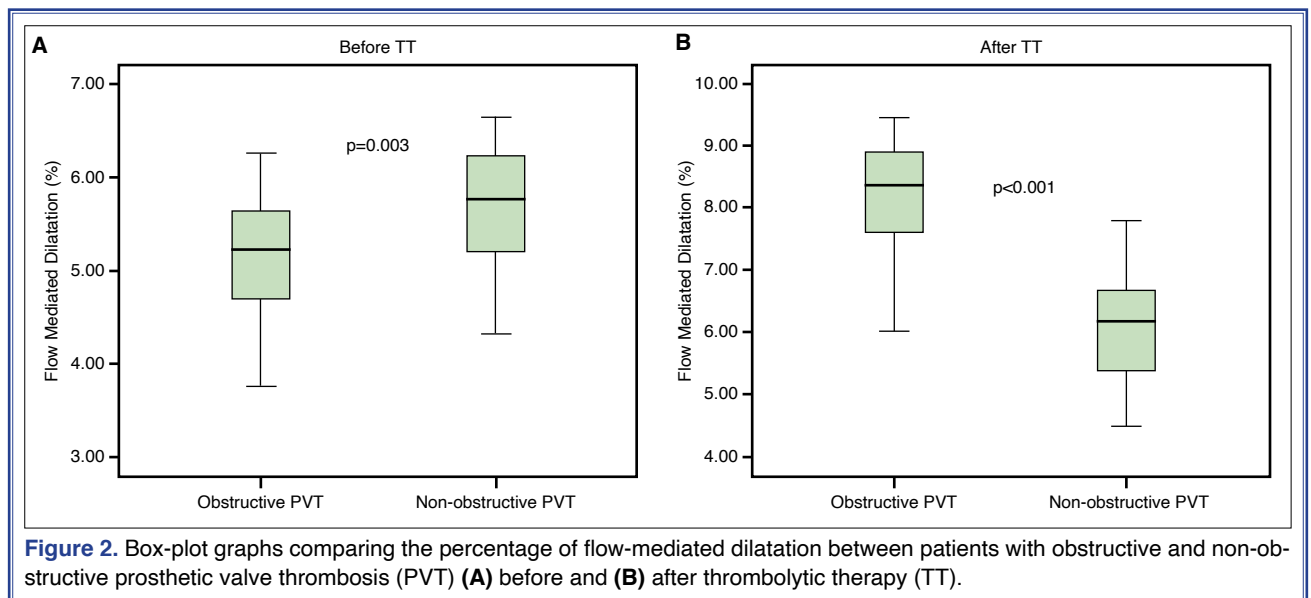
DISCUSSION

In this single-center study, we focused on the reversibility of the endothelial dysfunction after TT in pa-

Table 3. Comparison of baseline and reactive hyperemia-induced parameters between patients with obstructive and non-obstructive PVT

	Parameters	Obstructive PVT (n=38)	Non-obstructive PVT (n=47)	p value
Before TT	Baseline brachial artery diameter (mm)	3.51 \pm 0.73	3.44 \pm 0.55	0.661
	Reactive hyperemia-induced diameter (mm)	3.69 \pm 0.78	3.64 \pm 0.58	0.742
	Flow-mediated dilatation (%)	5.31 \pm 0.76	5.87 \pm 0.84	0.003
After TT	Baseline brachial artery diameter (mm)	3.56 \pm 0.84	3.48 \pm 0.71	0.658
	Reactive hyperemia-induced diameter (mm)	3.85 \pm 0.91	3.69 \pm 0.76	0.408
	Flow-mediated dilatation (%)	8.22 \pm 1.15	6.11 \pm 0.95	<0.001

PVT: Prosthetic valve thrombosis; TT: Thrombolytic therapy.



tients with PVT. TT with a low-dose and ultra-slow infusion of t-PA was performed with a considerable success rate in patients with PVT. Endothelium-dependent, reactive hyperemia-induced FMD in the brachial arteries significantly increased after successful TT in patients with obstructive PVT.

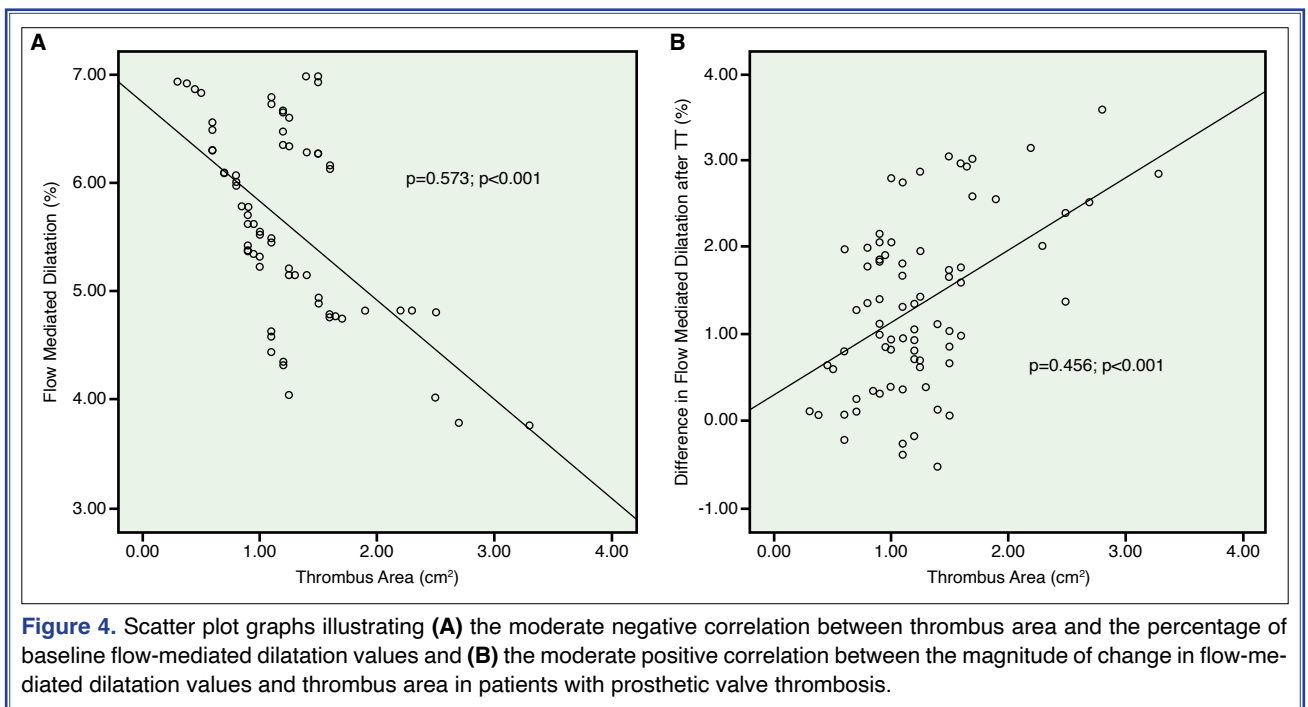
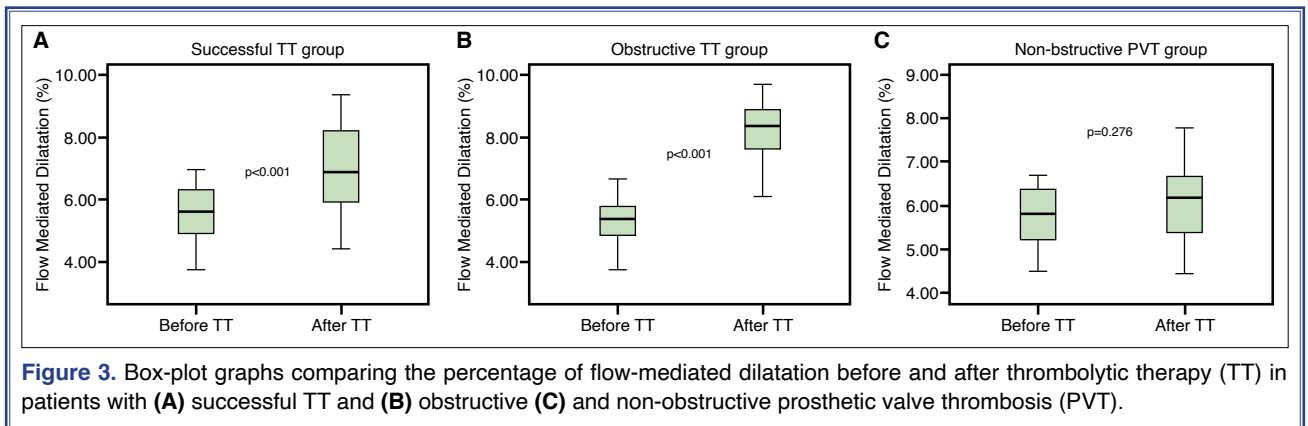
PVT is a rare complication of valvular replacement surgery that is associated with high mortality

and morbidity.^[19] TTE, 2D and RT-3D TEE, and multi-detector cardiac computed tomography play an important role in the diagnosis of PVT.^[20–22] Despite the technological advancements, prosthetic valves are still thrombogenic as a result of foreign body reaction and endothelial damage. Effective anticoagulation is crucial for preventing PVT and its complications. Although subtherapeutic anticoagulation is the most

Table 4. Comparison of baseline and reactive hyperemia-induced endothelial parameters before and after thrombolytic therapy in PVT subgroups

Patient groups	Parameters	Before TT	After TT	<i>p</i> value
All patients (n=85)	Baseline brachial artery diameter (mm)	3.46±0.63	3.51±0.77	0.267
	Reactive hyperemia-induced diameter (mm)	3.66±0.67	3.77±0.83	0.042
	Flow-mediated dilatation (%)	5.62±0.85	7.04±1.18	<0.001
Successful TT group (n=79)	Baseline brachial artery diameter (mm)	3.45±0.65	3.51±0.79	0.173
	Reactive hyperemia-induced diameter (mm)	3.65±0.68	3.76±0.85	<0.001
	Flow-mediated dilatation (%)	5.65±0.86	7.13±1.26	<0.001
Failed TT group (n=6)	Baseline brachial artery diameter (mm)	3.58±0.18	3.63±0.25	0.542
	Reactive hyperemia-induced diameter (mm)	3.80±0.21	3.86±0.27	0.393
	Flow-mediated dilatation (%)	5.07±0.61	5.38±0.95	0.371
Obstructive PVT group (n=38)	Baseline brachial artery diameter (mm)	3.51±0.73	3.59±0.85	0.232
	Reactive hyperemia-induced diameter (mm)	3.69±0.78	3.88±0.92	0.015
	Flow-mediated dilatation (%)	5.31±0.76	8.22±1.15	<0.001
Non-obstructive PVT group (n=47)	Baseline brachial artery diameter (mm)	3.43±0.55	3.50±0.72	0.335
	Reactive hyperemia-induced diameter (mm)	3.63±0.58	3.71±0.76	0.291
	Flow-mediated dilatation (%)	5.87±0.84	6.11±0.95	0.276

PVT: Prosthetic valve thrombosis; TT: Thrombolytic therapy.



prominent cause of PVT development, several esoteric causes, such as genetic mutations,^[23] elevated fibrinogen,^[24] anti-cardiolipin antibodies,^[25] anti-tissue plasminogen activator antibodies,^[26] increased heparanase levels,^[27] and ABO blood groups,^[28] may play a role in the aggravation of thrombus formation despite effective anticoagulation.

Treatment options for PVT include intensified anticoagulation, TT, and redo valve surgery. Until recently, surgery was recommended as first-line treatment for left-sided PVT, despite high morbidity and mortality rates.^[4,19,29] TT is now increasingly performed in the treatment of PVT. Complications like hemorrhage and thromboembolism have been reduced with-

out compromising success rates with low-dose and slow-infusion protocols.^[6-8] Following recent studies, the 2017 American College of Cardiology/American Heart Association valve disease guideline was revised and TT has been recommended in PVT therapy with an indication of class 1b and, alternatively, equivalent to emergency surgery.^[5]

The endothelium is a large paracrine organ that secretes a variety of factors for regulation of vascular tone, cell growth, platelet and leukocyte interactions, and thrombogenicity.^[10] The endothelium can sense and respond to numerous internal and external stimuli via cell membrane receptors and signal transduction mechanisms, leading to the synthesis and release of

various vasoactive, thromboregulatory, and growth factor substances. A noninvasive technique has been widely used to evaluate flow-mediated vasodilation, an endothelium-dependent function, in the brachial artery.^[18] In this technique, a reactive hyperemia-induced nitric oxide release is provoked, and the subsequent vasodilation is imaged and quantitated as an index of endothelial function.

Endothelial dysfunction plays an important role in the development of cardiovascular diseases, including atherosclerosis, hypertension, and heart failure.^[10,30,31] In a previous study, it was demonstrated that patients with PVT had significantly lower levels of FMD compared with an age- and sex-matched control group of patients with normally functioning prosthetic valves.^[11] However, the study could not determine whether endothelial dysfunction is the cause or the effect. In the current study, we focused on the reversibility of endothelial dysfunction after TT in patients with PVT. Persistence of the thrombus burden in the failed TT group resulted in no significant change in FMD values. However, significantly increased FMD values after successful TT in patients with PVT have revealed that endothelial dysfunction was predominantly the consequence of the presence of PVT.

It has been recognized that the endothelium participates in some pathological processes during inflammation and that inflammation may affect endothelial function.^[32] The incremental role of inflammatory processes in PVT development was highlighted in a previous study reporting increased inflammatory parameters in patients with PVT. The difference in inflammatory parameters was more significant in cases of obstructive PVT, indicating more serious inflammation in these patients.^[9] Consistent with the results of earlier studies, our research also indicated that endothelial dysfunction resolved more significantly in patients with obstructive PVT. This may be explained by the association between the thrombus burden, inflammation, and endothelial functions.

It was reported in an experimental animal study that endothelial exposure to thrombus formation significantly decreased endothelium-dependent vasorelaxation. Furthermore, TT with urokinase was superior to thrombectomy in preserving endothelial functions.^[33] In another study, Kashyap et al.^[34] studied rats with an infrarenal aortic occlusion created with a clip ligature to induce arterial thrombosis. They

reported that acute arterial thrombosis caused endothelial dysfunction without causing endothelial cell loss and that supplementing TT with urokinase ameliorated the endothelial dysfunction seen after acute thrombosis. Blum et al.^[35] compared the FMD values of patients with sickle cell anemia during and after sickle cell crises characterized by increased adherence of sickle cell erythrocytes to vascular endothelial cells. The FMD values were significantly lower during the crises. Peng et al.^[36] investigated the effects of TT and anticoagulation on the functions of vascular endothelial cells and observed that TT and anticoagulation therapies were beneficial in protecting the functions of vascular endothelial cells in patients with a pulmonary thromboembolism. In the current study, we aimed to investigate the reversibility of endothelial dysfunction after TT in patients with PVT. Successful TT was found to improve endothelial function in PVT patients.

Conclusion

This study demonstrated that endothelial dysfunction was reversible in patients with PVT. Successful TT may contribute to the improvement of impaired endothelial function in patients with obstructive PVT proportional to the thrombus burden. TT with a low-dose and ultra-slow infusion of t-PA may be performed with considerable safety and efficacy in patients with PVT.

Financial disclosure: This research received no specific grant from any funding agency, commercial or not-for-profit sectors.

Ethical statement: The study protocol was approved by the local ethics committee of Kartal Kosuyolu Training and Research Hospital, Istanbul, Turkey on October 20, 2014 (no: 2014.3/15).

Peer-review: Externally peer-reviewed.

Conflict-of-interest: None.

Authorship contributions: Concept: B.Ç., M.K., M.Ö.; Design: B.Ç., M.K., A.G.; Supervision: M.Ö., S.G.; Materials: M.Y., E.B., M.O.G.; Data: A.G., E.B., S.K.; Analysis: M.K., S.K.; Literature search: A.G., M.Y., S.G.; Writing: B.Ç., M.K., A.G., M.O.G.; Critical revision: M.Ö.

REFERENCES

1. Cáceres-Lóriga FM, Pérez-López H, Santos-Gracia J, Morlans-Hernandez K. Prosthetic heart valve thrombosis: pathogenesis, diagnosis and management. *Int J Cardiol* 2006;110:1–

- 6.
2. Lengyel M. Diagnosis and treatment of left-sided prosthetic valve thrombosis. *Expert Rev Cardiovasc Ther* 2008;6:85–93.
3. Cáceres-Lóriga FM, Morais H. Thrombotic obstruction in left-side prosthetic valves: Role of thrombolytic therapy. *Indian Heart J* 2015;67S10–S2. [[CrossRef](#)]
4. Gürsoy MO, Kalçık M, Yesin M, Karakoyun S, Bayam E, Gündüz S, et al. A global perspective on mechanical prosthetic heart valve thrombosis: Diagnostic and therapeutic challenges. *Anatol J Cardiol* 2016;16:980–9. [[CrossRef](#)]
5. Nishimura RA, Otto CM, Bonow RO, Carabello BA, Erwin JP 3rd, Fleisher LA, et al. 2017 AHA/ACC Focused Update of the 2014 AHA/ACC Guideline for the Management of Patients With Valvular Heart Disease: A Report of the American College of Cardiology/American Heart Association Task Force on Clinical Practice Guidelines. *Circulation* 2017;135:e1159–e95. [[CrossRef](#)]
6. Özkan M, Gündüz S, Biteker M, Astarcioglu MA, Çevik C, Kaynak E, et al. Comparison of different TEE-guided thrombolytic regimens for prosthetic valve thrombosis: the TROIA trial. *JACC Cardiovasc Imaging* 2013;6:206–16. [[CrossRef](#)]
7. Özkan M, Çakal B, Karakoyun S, Gürsoy OM, Çevik C, Kalçık M, et al. Thrombolytic therapy for the treatment of prosthetic heart valve thrombosis in pregnancy with low-dose, slow infusion of tissue-type plasminogen activator. *Circulation* 2013;128:532–40. [[CrossRef](#)]
8. Özkan M, Gündüz S, Gürsoy OM, Karakoyun S, Astarcioglu MA, Kalçık M, et al. Ultraslow thrombolytic therapy: A novel strategy in the management of PROsthetic MEchanical valve Thrombosis and the prEdictors of outcomE: The Ultra-slow PROMETEE trial. *Am Heart J* 2015;170:409–18. [[CrossRef](#)]
9. Gürsoy OM, Karakoyun S, Kalçık M, Gökdeniz T, Yesin M, Gündüz S, et al. Usefulness of novel hematologic inflammatory parameters to predict prosthetic mitral valve thrombosis. *Am J Cardiol* 2014;113:860–4. [[CrossRef](#)]
10. Verma S, Anderson TJ. Fundamentals of endothelial function for the clinical cardiologist. *Circulation* 2002;105:546–9.
11. Kaya H, Ozkan M, Yildiz M. Relationship between endothelial dysfunction and prosthetic heart valve thrombosis: a preliminary investigation. *Eur Rev Med Pharmacol Sci* 2013;17:1594–8.
12. Zoghbi WA. New recommendations for evaluation of prosthetic valves with echocardiography and doppler ultrasound. *Methodist Debakey Cardiovasc J* 2010;6:20–6. [[CrossRef](#)]
13. Ozkan M, Kaymaz C, Kirma C, Sönmez K, Ozdemir N, Balkanay M, et al. Intravenous thrombolytic treatment of mechanical prosthetic valve thrombosis: a study using serial transesophageal echocardiography. *J Am Coll Cardiol* 2000;35:1881–9. [[CrossRef](#)]
14. Lancellotti P, Pibarot P, Chambers J, Edvardsen T, Delgado V, Dulgheru R, et al. Recommendations for the imaging assessment of prosthetic heart valves: a report from the European Association of Cardiovascular Imaging endorsed by the Chinese Society of Echocardiography, the Inter-American Society of Echocardiography, and the Brazilian Department of Cardiovascular Imaging. *Eur Heart J Cardiovasc Imaging* 2016;17:589–90. [[CrossRef](#)]
15. Gündüz S, Özkan M, Yesin M, Kalçık M, Gürsoy MO, Karakoyun S, et al. Prolonged Infusions of Low-Dose Thrombolytics in Elderly Patients With Prosthetic Heart Valve Thrombosis. *Clin Appl Thromb Hemost* 2017;23:241–7. [[CrossRef](#)]
16. Kalçık M, Gürsoy OM, Astarcioglu MA, Özkan M. A serial fluoroscopy-guided thrombolytic therapy of a mechanical tricuspid prosthetic valve thrombosis with low-dose and ultra-slow infusion of tissue-type plasminogen activator. *Turk Kardiyol Dern Ars* 2014;42:478–81. [[CrossRef](#)]
17. Guner A, Kalcik M, Gursoy MO, Gunduz S, Ozkan M. How to perform and manage low-dose and slow/ultra-slow tissue type plasminogen activator infusion regimens in patients with prosthetic valve thrombosis. *J Thromb Thrombolysis* 2018;46:399–402. [[CrossRef](#)]
18. Corretti MC, Anderson TJ, Benjamin EJ, Celermajer D, Charbonneau F, Creager MA, et al. Guidelines for the ultrasound assessment of endothelial-dependent flow-mediated vasodilation of the brachial artery: a report of the International Brachial Artery Reactivity Task Force. *J Am Coll Cardiol* 2002;39:257–65. [[CrossRef](#)]
19. Castilho FM, De Sousa MR, Mendonça AL, Ribeiro AL, Cáceres-Lóriga FM. Thrombolytic therapy or surgery for valve prosthesis thrombosis: systematic review and meta-analysis. *J Thromb Haemost* 2014;12:1218–28. [[CrossRef](#)]
20. Gürsoy OM, Karakoyun S, Kalçık M, Özkan M. The incremental value of RT three-dimensional TEE in the evaluation of prosthetic mitral valve ring thrombosis complicated with thromboembolism. *Echocardiography* 2013;30:E198–E201.
21. Ozkan M, Gürsoy OM, Astarcioglu MA, Gündüz S, Cakal B, Karakoyun S, et al. Real-time three-dimensional transesophageal echocardiography in the assessment of mechanical prosthetic mitral valve ring thrombosis. *Am J Cardiol* 2013;112:977–83. [[CrossRef](#)]
22. Gündüz S, Özkan M, Kalçık M, Gürsoy OM, Astarcioglu MA, Karakoyun S, et al. Sixty-Four-Section Cardiac Computed Tomography in Mechanical Prosthetic Heart Valve Dysfunction: Thrombus or Pannus. *Circ Cardiovasc Imaging* 2015;8:e003246. [[CrossRef](#)]
23. Kalcik M, Gursoy MO, Karakoyun S, Yesin M, Astarcioglu MA, Ozkan M. Potential inherited causes of recurrent prosthetic mitral valve thrombosis in a pregnant patient suffering from recurrent miscarriage. *Korean Circ J* 2014;44:268–70.
24. Aykan AC, Gökdeniz T, Gündüz S, Astarcioglu MA, Gürsoy OM, Ertürk E, et al. Value of serum fibrinogen levels in the assessment of mechanical prosthetic valve thrombosis. *J Heart Valve Dis* 2014;23:222–7.
25. Aykan AÇ, Gökdeniz T, Kalçık M, Astarcioglu MA, Gündüz S, Karakoyun S, et al. Role of anticardiolipin antibodies in the pathogenesis of prosthetic valve thrombosis: An observa-

- tional study. *Herz* 2015;40:528–33. [CrossRef]
26. Özkan M, Kalçık M, Gürsoy MO, Öcal L, Griffini S, Karakoyun S, et al. Assessment of Anti-Tissue Type Plasminogen Activator Antibodies in Patients With Prosthetic Heart Valve Thrombosis: The ATA Trial. *J Cardiovasc Pharmacol Ther* 2016;21:372–80. [CrossRef]
 27. Bayam E, Kalçık M, Gürbüz AS, Yesin M, Güner A, Gündüz S, et al. The relationship between heparanase levels, thrombus burden and thromboembolism in patients receiving unfractionated heparin treatment for prosthetic valve thrombosis. *Thromb Res* 2018;171:103–10. [CrossRef]
 28. Astarcioglu MA, Kalçık M, Yesin M, Gürsoy MO, Şen T, Karakoyun S, et al. ABO blood types: impact on development of prosthetic mechanical valve thrombosis. *Anatol J Cardiol* 2016;16:820–3. [CrossRef]
 29. Lengyel M, Horstkotte D, Völler H, Mistiaen WP; Working Group Infection, Thrombosis, Embolism and Bleeding of the Society for Heart Valve Disease. Recommendations for the management of prosthetic valve thrombosis. *J Heart Valve Dis* 2005;14:567–75.
 30. Laurent S, Lacolley P, Brunel P, Laloux B, Pannier B, Safar M. Flow-dependent vasodilation of brachial artery in essential hypertension. *Am J Physiol* 1990;258:H1004–H11. [CrossRef]
 31. Celermajer DS, Sorensen KE, Gooch VM, Spiegelhalter DJ, Miller OI, Sullivan ID, et al. Non-invasive detection of endothelial dysfunction in children and adults at risk of atherosclerosis. *Lancet* 1992;340:1111–5. [CrossRef]
 32. Stenvinkel P. Endothelial dysfunction and inflammation-is there a link?. *Nephrol Dial Transplant* 2001;16:1968–71.
 33. Reil TD, Moore WS, Kashyap VS, Nene SS, Gelabert HA, Quinones-Baldrich WJ. The effects of thrombus, thrombectomy and thrombolysis on endothelial function. *Eur J Vasc Endovasc Surg* 2000;19:162–8. [CrossRef]
 34. Kashyap VS, Reil TD, Moore WS, Hoang TX, Gelabert HA, Byrns RE, et al. Acute arterial thrombosis causes endothelial dysfunction: a new paradigm for thrombolytic therapy. *J Vasc Surg* 2001;34:323–9. [CrossRef]
 35. Blum A, Yeganeh S, Peleg A, Vigder F, Kryuger K, Khatib A, et al. Endothelial function in patients with sickle cell anemia during and after sickle cell crises. *J Thromb Thrombolysis* 2005;19:83–6. [CrossRef]
 36. Peng K, Wang C, Pang BS, Yang YH. Effects of thrombolysis and anticoagulation on the functions of vascular endothelial cells and coagulation and fibrinolysis in patients with pulmonary thromboembolism. [Article in Chinese] *Zhonghua Jie He He Hu Xi Za Zhi* 2005;28:596–9.

Keywords: Echocardiography; endothelial functions; flow-mediated dilatation; prosthetic valve thrombosis; transesophageal echocardiography.

Anahtar sözcükler: Ekokardiyografi; endotel fonksiyonları; akım aracılı dilatasyon; protez kapak trombozu; transözofajiyal ekokardiyografi.