

# Cerebrospinal Fluid Leak after Repair of Congenital Spinal Pathologies, Incidence and Management

BILAL KHAN<sup>1</sup>, USMAN HAQQANI<sup>2</sup>, RIZWAN ULLAH KHATTAK<sup>3</sup>  
KHALID KHAN KHANZADA<sup>1</sup>, SHAFAT HUSSAIN<sup>4</sup>, SAJJAD ULLAH<sup>1</sup>

Department of Neurosurgery, <sup>1</sup>Lady Reading Hospital, <sup>2</sup>Qazi Hussain Ahmad Medical Complex, Nowshera, <sup>3</sup>Hayatabad Medical Complex, Peshawar, <sup>4</sup>DHQ Hospital, KDA, Kohat, – Pakistan

DOI: 10.36552/pjns.v24i3.469

## ABSTRACT

**Objective:** To know the incidence of CSF leak and role of tincture benzoyl in the management of CSF leak after the repair of congenital spinal deformities like myelomeningocele, meningocele and tethered cord syndrome.

**Materials and Methods:** All patients who were operated for congenital spinal surgeries in the form of MMC, Meningocele and TCS by a single surgeon were followed for a minimum of 3 months. Patients with already CSF leak/ruptured MMC prior to surgery were not part of the study. The particulars like gender and type of surgery, days since first surgery, associated infection, hydrocephalus and type of management were noted on a proforma.

**Results:** A total of 73 patients with spinal dysraphism were operated during the study period and of them about 13 patients returned with problems of the CSF leak. The mean duration and duration since the CSF leak was from 6 days to 16 days. Among them, 10 patients had an MMC repair and one patient had TCS release, while 2 patients were having meningocele repair. The patients were stitched and one patient was re-operated two times for repair of CSF leak. Two patients had a CSF leak along with post op signs of HCP that settled by placing a shunt along with primary repair of the wound reinforced with tincture benzoyl in a single setting. Two other patients had signs of HCP without CSF leak after skin reinforcement stitches reinforced by tincture benzoyl and underwent shunt placement later.

**Conclusion:** CSF leak is a common complication following repair of spinal dysraphism and most patients can be managed with the application of tincture benzoyl alone or after simple skin reinforcement.

**Keywords:** Cerebrospinal fluid (CSF), Myelomeningocele (MMC), Tether cord syndrome (TCS), Ventriculo peritoneal shunt (VP shunt).

**Abbreviations:** CSF: Cerebrospinal Fluid. MMC: Myelomeningocele. TCS: Tether Cord Syndrome. VP Shunt: Ventriculo Peritoneal Shunt. CT: Computed Tomography. MRI: Magnetic Resonance Imaging.

## INTRODUCTION

This study was focused to know the incidence of CSF leak and role of tincture benzoyl in the management of CSF leak after the repair of congenital spinal deformities like myelomeningocele, meningocele and tethered cord syndrome.

Spinal dysraphism involves a variety of congenital abnormalities which results in a defective neural arch through which meninges or neural elements get

herniated and leads to a variety of clinical manifestations, and can either be aperta (visible lesion) and occulta (with no external lesion).<sup>1</sup> This can result in different abnormalities like Meningocele, Myelomeningocele, Lipomeningomyelocele, Myeloschisis and Rachischisis. The prevalence of these conditions is high in the developing world due to the poor nutrition and maternal health care it has an estimated prevalence of about 2-4/1000 population.<sup>2</sup>

There are many associated anomalies with this anomaly which includes bladder dysfunction, foot anomalies, cardiac problems and anomalies of the central nervous system in the form of hydrocephalus.<sup>3</sup> Repair of these anomalies is important for the nursing care and to avoid complications like meningitis or progressive weakness.<sup>4</sup> However, the surgery is not without complications and CSF leak, wound dehiscence and infection are one of the leading complications of this surgery. It may further leads to the morbidity of the patient. Furthermore, these patients are quite at risk for other surgeries like VP shunt due to the associated hydrocephalus.<sup>5</sup>

Spinal dysraphism is not a very uncommon condition in the developing nations like Pakistan and we perform quite a large number of these surgeries, so we decided to follow all these patients to know about the rate of the CSF leak in them, and the way they were managed subsequently, any need for further surgery and type of surgery performed.

## MATERIALS AND METHODS

### Study Design and Setting

This cross sectional study was performed in the Department of Neurosurgery, MTI Lady Reading Hospital, Peshawar, Pakistan from January 2018 to November 2019.

### Patients

All patients who were operated for congenital spinal surgeries in the form of MMC, Meningocele and TCS by a single surgeon were followed for a minimum of 03 months upon return for their follow up or earlier in case of any leak. Patients with already CSF leak/ruptured MMC prior to surgery were not part of the study. Patients had undergone investigations in the form of Magnetic Resonance Imaging (MRI) of the spine and computed tomography (CT) scans of the brain pre-operatively.

### Data Collection

The particulars like gender and type of surgery, days since first surgery, associated infection, hydrocephalus and type of management were noted on a proforma and the type of management done either conservative with application of paste of tincture benzoyl, refreshment of the wound edges and new stitches or re-operation in the form of Ventriculoperitoneal shunt

(VP) or repair of the dural leaking site. The data was entered and analyzed using SPSS version 22 and was expressed in the form of tables and charts.

## RESULTS

### General Clinical Information

A total of 73 patients with spinal dysraphism were operated during the study period and of them 13 patients returned with problems of CSF leak. They were about 7 males and 6 females. The age range was from 3 months to 4.5 years.

### CSF Leaks

The mean duration and time from surgery to the CSF leak was from 6 to 16 days. Among them, 10 patients had MMC repair and one patient (1.3%) had TCS release, while 2 (2.6%) patients underwent meningocele repair. Three patients responded to application of tincture twice daily, parents were educated about the application of the solution. In 9 patients, the skin reinforcement stitches were taken under light sedation and they were advised to do dressing in the post-operative period with tincture benzoyl. This strategy worked in almost all of the said patients. There was an associated infection in two patients, culture and sensitivity were taken and antibiotics were started which resolved. One patient who had a tethered cord syndrome release done, was re-operated two times for repair of CSF leak, had an infection after the second surgery and an expansile duraplasty was undertaken for the third time, which

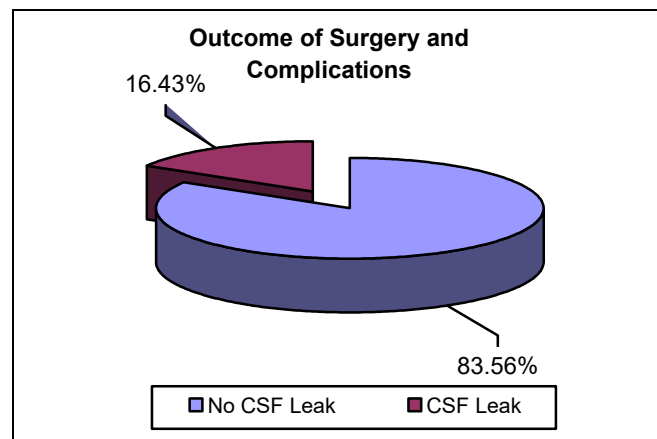


Fig. 1: This shows the percentage of patients who had a CSF leak among those operated for spinal dysraphism surgery.

worked well. The shunt was placed in 4 patients subsequently, they had hydrocephalus. Two patients had a CSF leak along with post op signs of Hydrocephalus that settled by placing a shunt along with primary repair of the wound reinforced with tincture benzoyl in a single setting. Two other patients had signs of Hydrocephalus without CSF leak after skin reinforcement stitches reinforced by tincture benzoyl and underwent shunt placement later.

made and the children are operated earlier in life but in a developing country like ours, the patients are presented late to neurosurgeons and more over early surgery is not encouraged by the surgeons due to anesthesia risks that can be difficult to manage because of lack of resources and anesthesia related expertise, In our series the incidence of spinal dysraphism in male and female was almost equal, that was 1.1:1 whereas in a study conducted in north India incidence was higher among male patients with a ratio

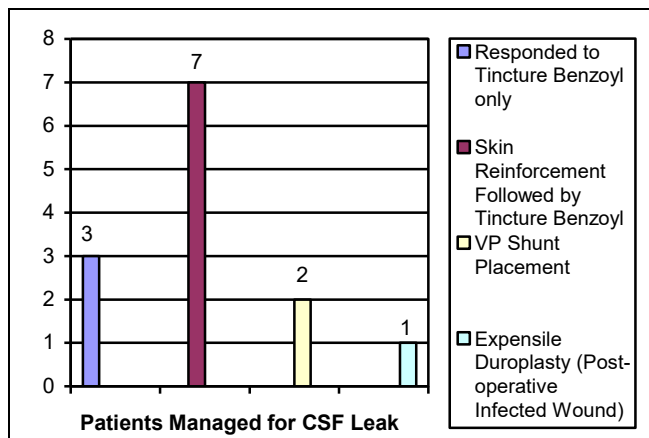


Fig. 2: This shows the number of patients that responded to given modality of treatment.

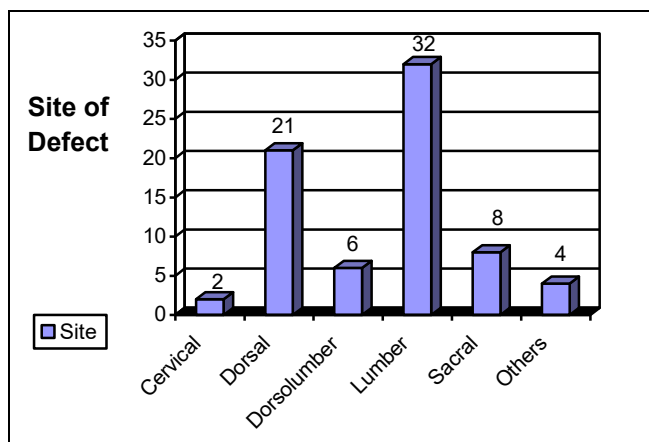


Fig. 3: It shows the stratification of patients on the basis of site of defect.

**DISCUSSION**

Incidence of Spinal dysraphism varies between countries and regions. At birth spina bifida can be apparent or obscure/unrecognizable to the family of the child, generally in a developed country immediately after birth, a neurosurgery consultation is

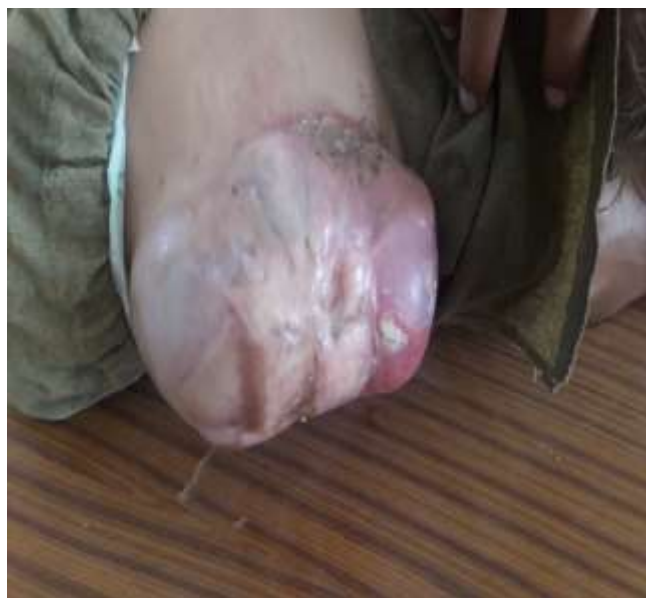

Fig. 4: Pre-operative Myelomeningocele.

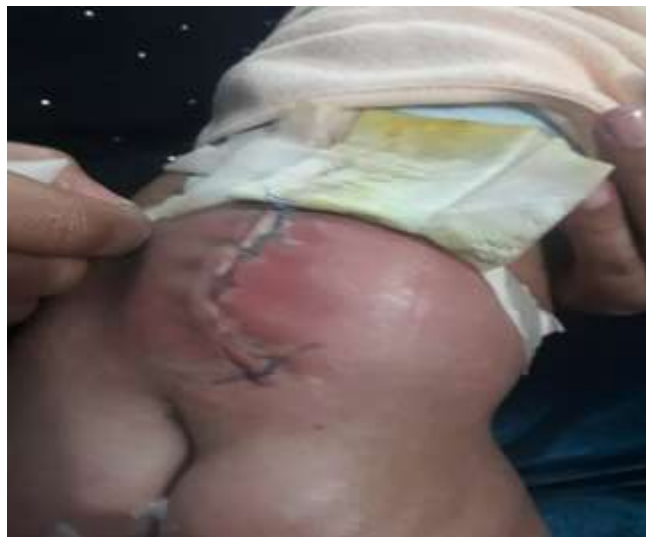

Fig. 5: Post-operative Wound Infection and CSF Leak.

\*The images were used with permission of Patient.

of 1.5 to 1.<sup>6</sup> Post-operative infection and CSF leak are the biggest post-operative complications for spinal dysraphism surgery and the incidence of CSF leak varies from 8% to 30% in different studies,<sup>6,7</sup> in our study, we reported post op CSF leak rate of 16.4%, most of these patients responded to simple skin reinforcement sutures along with post op benzoyl tincture application, another study conducted by Marino R also encouraged and appreciated the use of tincture benzoyl for CSF leak.<sup>8</sup> Benzoyl tincture is a natural compound, its use for fissures, leaks and discharge has been there for very long but it is also considered to cause allergic reactions and contact dermatitis at wound site, a study by Scardamaglia et al, reported that benzoyl may not be responsible for any allergic reaction itself, it is the cross reaction of other elements as a mixture of the tincture compound that are added and less than 30 benzoyl related dermatitis cases were reported, none in last decade at dermatitis clinic he worked in.<sup>9</sup> In our study, only one patient required expansile duraplasty due to recurrent infections and leak. Another complication of spinal dysraphism case is the tethering of the cord where adhesion may develop at the repair site and patient presents with neurological manifestations later, but no such complication was noted probably because of the short duration of follow-up.

## CONCLUSION

CSF leak is a common complication following repair of spinal dysraphism, most patient can be managed with application of tincture benzoyl alone or after simple skin reinforcement stitches.

## Additional Information

**Disclosures:** Authors report no conflict of interest.

**Ethical Review Board Approval:** The study was conformed to the ethical review board requirements.

**Human Subjects:** Consent was obtained by all patients/participants in this study.

## Conflicts of Interest:

In compliance with the ICMJE uniform disclosure form, all authors declare the following:

**Financial Relationships:** All authors have declared that they have no financial relationships at present or within the previous three years with any organizations that might have an interest in the submitted work.

**Other Relationships:** All authors have declared that there are no other relationships or activities that could appear to have influenced the submitted work.

## REFERENCES

1. Harwood-Nash DC, McHugh K. Diastematomyelia in 172 children: the impact of modern neuroradiology. *Pediatric Neurosurgery*, 1990; 16 (4-5): 247-51.
2. Laurence KM. A declining incidence of neural tube defects in the U.K. *Zeitschrift fur Kinderchirurgie: organ der Deutschen, der Schweizerischen und der Osterreichischen Gesellschaft fur Kinderchirurgie = Surgery in infancy and childhood*, 1989; 44: 1: 51.
3. Sgouros S. Spinal dysraphism. *Child's nervous system: ChNS: official journal of the International Society for Pediatric Neurosurgery*, 2013; 29 (9): 1415-6.
4. Rodrigues AB, Krebs VL, Matushita H, de Carvalho WB. Short-term prognostic factors in myelomeningocele patients. *Child's nervous system: ChNS: official journal of the International Society for Pediatric Neurosurgery*, 2016; 32 (4): 675-80.
5. Kim I, Hopson B, Aban I, Rizk EB, Dias MS, Bowman R, et al. Treated hydrocephalus in individuals with myelomeningocele in the National Spina Bifida Patient Registry. *Journal of Neurosurgery Pediatrics*, 2018; 22 (6): 646-51.
6. Kumar R, Singh SN. Spinal dysraphism: trends in northern India. *Pediatric Neurosurgery*, 2003; 38 (3): 133-45.
7. Jindal A, Mahapatra AK, Kamal R. Spinal dysraphism. *Indian Journal of Pediatrics*, 1999; 66 (5): 697-705.
8. Marino Junior R. Multiple use of benzoin as an aid in neurosurgical practice: the watertight benzoin dressing. *Arquivos de neuro-psiquiatria*. 1979; 37 (4): 373-9.
9. Scardamaglia L, Nixon R, Fewings J. Compound tincture of benzoin: a common contact allergen? *The Australasian Journal of Dermatology*, 2003; 44 (3): 180-4.

*Address for Correspondence: Usman Haqqani*

*Department of Neurosurgery, Qazi Hussain Ahmad Medical Complex, Nowshera – Pakistan*

*Email: usmanhaqqani1@gmail.com*

**AUTHORS CONTRIBUTIONS**

<b>Name</b>	<b>Intellectual Contribution to Paper in Terms of:</b>
Bilal Khan	Data Collection, Initial Write-up, discussion writing and final review. Background Writing
Usman Haqqani	Data Collection, Proforma, Literature Review and References, Data Collection.
Rizwan Ullah Khattak	Literature Review and Discussion Writing.
Khalid khan Khanzada	Initial Write-up, discussion writing Data Collection.
Shafaat Hussain	Literature Review and References.
Sajjad Ullah	Interpretation of Results Via Graphs and Charts.

Date of Submission: 24-3-2020

Date of Revision: 20-8-2020

Date of Online Publishing: 25-09-2020

Date of Print: 30-09-2020