

Outcome of Surgical Treatment for Lumbar Disc Herniation Causing Painful Incomplete Foot-Drop

MUSAWER KHAN, AKRAMULLAH, ADNAN AHMED, MUMTAZ ALI, MANSOOR AHMAD

Department of Neurosurgery, Lady Reading Hospital, Peshawar – Pakistan

DOI: 10.36552/pjns.v24i3.398

ABSTRACT

Objective: To determine the outcome of surgical treatment for lumbar disc herniation causing the painful incomplete foot drop.

Material and Methods: This retrospective observational study was conducted at the Department of Neurosurgery Lady Reading Hospital, Peshawar. Both Male and female patients with lumbar disc disease causing unilateral incomplete painful foot drop were included in our study. Patients with complete or painless foot drop, bilateral foot-drop, Multiple level disc prolapse, cauda equina syndrome or sciatic neuropathy due to injection injury were excluded. Patients were followed post-operatively in terms of power in foot dorsiflexion, medical research council (MRC) grade and pain relief on a Visual Analogue Scale (VAS) after 1 month and then after 6 months.

Results: Total number of patients included were 43. Age was ranging from 18 years to 54 years and mean age was 33 years. Before surgery, power of MRC grade 3 or less, but greater than 1 in dorsiflexion was noted in all patients. The pain was scaled using VAS. Post operatively, at 1 month follow up, the foot-drop improved to MRC grade 4 or 5 along with pain relief of ≥ 2 points on VAS in 81. 4% ($n = 35$) patients and at 6 month follow-up, the figure rose to 93% ($n = 40$).

Conclusion: Lumbar disc disease can cause a debilitating foot-drop and pain. Improving or restoring a neurology early surgical intervention has proven benefits.

Keywords: Discectomy, cauda equina syndrome, Lumbar disc herniation, Visual Analogue Scale.

Abbreviations: VAS: Visual Analogue Scale. MRC: Medical Research Council.

INTRODUCTION

Lumbar disc prolapse with associated sequelae is one of the most common neurosurgical entities, which comparatively affects the male population more than the female population.¹ MRI is the investigation choice for the diagnosis of lumbar disc herniation.² L4 – L5 and L5 – S1 are most commonly involved sites with disc herniation mainly affecting L5 and S1 nerve roots respectively.³ Motor impairment of L5 nerve root affects the big toe extension and patient usually can not use his/her heel effectively while walking hence, causing foot drop. S1 motor nerve root impairment results in weak plantar flexion and there is weakness in foot eversion.

Foot drop means weakness in or absence of ankle and toe dorsiflexion. It occurs due to underlying neurological, muscular or anatomical problems, but mostly a neurological cause is implicated. The neurological cause may be central i.e., motor neuron disease and parasagittal lesions involving cortex or subcortical area or peripherally, lumbar radiculopathy or mononeuropathies of the common peroneal nerve or its deepest branch or sciatic nerve.^{4,5,6} Weakness in dorsiflexion is mainly caused by disc prolapse at L4 – L5 level and L5 nerve root is mainly implicated.⁷ Electrical stimulation conducted by McCulloch showed that tibialis anterior and extensor hallucis longus muscles are innervated by L5 nerve

Outcome of Surgical Treatment for Lumbar Disc Herniation Causing Painful Incomplete Foot-Drop

root along with adjacent L4 and S1 roots.⁸ Hence, an intervertebral disc at L4 – L5 level or L5 – S1 level can cause foot drop. Microdiscectomy being introduced in 1977 is considered to be the surgery of choice for lumbar disc prolapse with radicular symptoms.⁹ The efficacy of this surgery in terms of improvement in foot drop is widely accepted with lesser complication rate than the older conventional procedures. Certain factors influence the outcome after this surgery. Studies show the degree of preoperative

weakness of tibialis anterior muscle and duration of weakness to be important prognostic factors in predicting power improvement after surgery.^{10,11} Guiguietal found that along with other factors, duration of foot drop < 6 weeks is associated with better outcome.¹² Preoperative gradation of tibialis anterior muscle strength also affects the post-operative recovery in foot drop after surgery.¹⁰

In the current study, we retrospectively evaluated the effectiveness of lumbar disc surgery in terms of

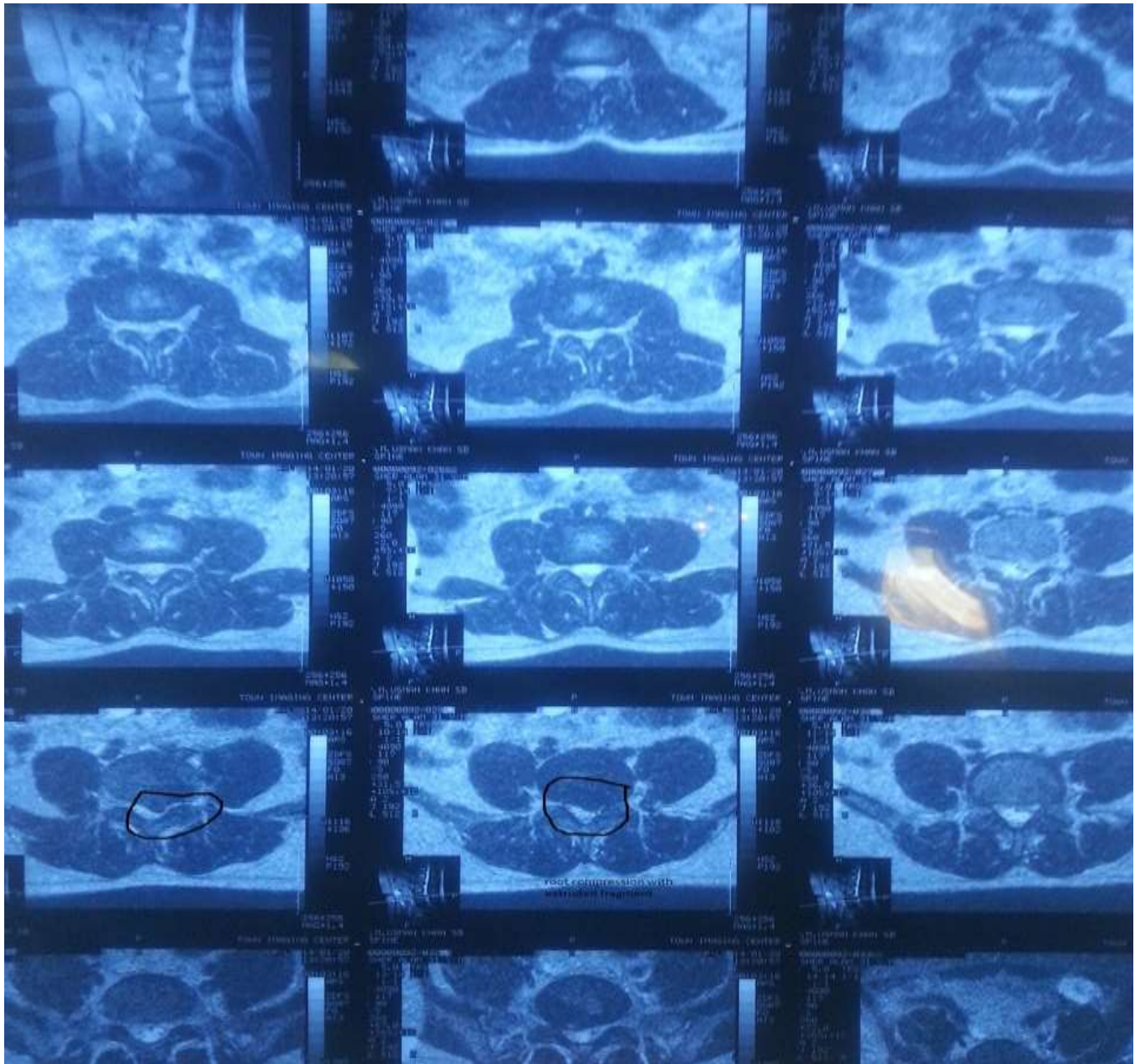


Fig. 1: Middle age male with disc prolapse at L4 – L5 level on left side. Patient had a painful weakness (on MRC scale) in foot dorsiflexion.

improvement in the motor deficit of tibialis anterior muscle and radicular pain, when the foot drop is still partial and painful and its duration is less than 1 month.

MATERIAL AND METHODS

Study Setting

This study was performed in Neurosurgery Department, Lady Reading Hospital, Peshawar. The study type was retrospective observational one. The study was conducted for five years (Jul 2013 to June 2018). A total of 43 patients enlisted in consecutive nonprobability manner.

Inclusion Criteria

The patients with unilateral partial painful foot drop (MRC grade 2 and grade 3) with MRI findings of single level lumbar disc prolapse were included.

Exclusion Criteria

The patients with complete foot drop (MRC grade 1), painless foot drop, bilateral foot drop, multiple level disc prolapse, caudaequina syndrome and patients with foot drop due to ischemic limb or sciatic neuropathy due to injection injury were excluded from the study.

Clinical Management

After getting approval from hospital ethical committee and taking the informed consents, medical record of the 43 patients were evaluated. All the patients were having MRC grade 3 or less but more than 1 power in the tibialis anterior muscle on the painful foot drop side. All the patients were operated within 1 month of the onset of symptom. Post operative followup was done at 1st and 6th month duration. Postoperative improvement to MRC grade 4 or 5 with improvement in pain on a visual analog scale (VAS) of 2 or more were taken as a good outcome (improvement). Postoperative MRC grade less than 4 and/or no improvement of pain on the VAS of at least two points was regarded as no improvement. Any worsening of MRC grade or pain from the preoperative assessment was taken as poor outcome. All the information was entered on a specially designed proforma for this purpose.

Surgical Steps

Fenestration discectomy was the surgical procedure performed in all the patients. In this procedure under general anesthesia patient was put in prone position, specially designed horse shoe shaped pillows were

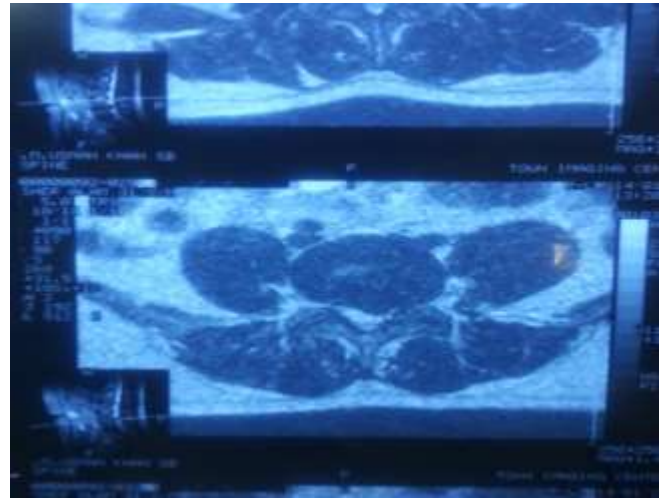


Fig. 2: Same patient with left sided prolapse disc (L4 L5). The diagnostic axial cut is selected.

used to support the chest and abdomen of the patient without compromising the patient's chest expansion during ventilation and avoiding exerting excessive abdominal pressure. Lumbar area was clean and draped. Mid line incision was given in skin, subcutaneous tissue and lumbar fascia. On the affected side unilateral muscle dissection was done. Fenestration was then performed of the two laminae avoiding the facet joints. Ligamentum flavum was then removed under a loop or microscope and lumbar root was retracted medially. The size-11 blade was used to give incision in the annulus of the offending disc and was removed with pituitary rongeur. Thorough wash was done with normal saline and the wound was closed in reverse order.

RESULTS

Age Range

The total number of patients were 43. Patients' age ranged between 18 years and 54 years with mean of 33 years.

Gender Distribution

There were 25 (58%) male patients and 18 (42%)

Table1: Level of Disc Herniation & Outcome after Surgery.

Total Patients	Level Involved		Improvement after 1 Month	Improvement after 6 Months	Complications
	L4 – L5	L5 – S1			
43	88.4% (n = 38)	11.6% (n = 5)	81.4% (n = 35)	93% (n = 40)	Nil

female patients.

Clinical Presentation

Figure 1 shows the frequency of right or left foot involved. 62.79% (n = 27) patients were operated within two weeks time of onset of symptoms while the other 37.21% (n = 16) patients were operated between 2 weeks and one month time of onset of foot drop. Frequency of disc prolapse level and recovery in foot drop in terms of power (to MRC grade ≥ 4) and pain (≥ 2 points decrease on visual analogue score) at 1 month and 6 month are presented in tabulated form below. There was no worsening of foot drop or increase in pain noted in any of patients 1 and 6 months after surgery.

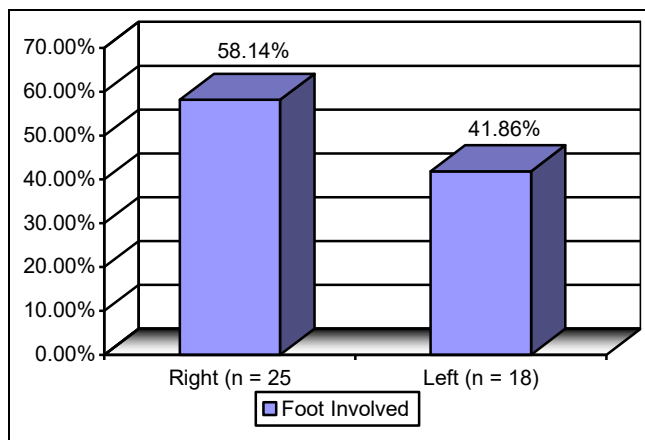


Fig. 3: Prevalence of Foot Involved.

DISCUSSION

Lumbar disc prolapse is one of the most common neurosurgical disorder. Males are comparatively more prone to this condition than females due to excessive exposure of their spine to heavy workload. Smoking is another contributing factor to this.^{13,14} Male to female ratio in a local study was 1.42:1 with an average age of 36 years while in our study this ratio is 1.39:1 with an average age of 33 years.² Lumbar disc prolapse is more common at L4 – L5 and L5 – S1 level.^{1.5}

Lower backache radiating to lower limb causing foot drop can be the presenting symptom of lower lumbar disc prolapse. **Tibialis anterior** muscle weakness, called as foot drop, is due to lumbar nerve root defect, and compression or inflammation due to stenosis caused by herniated disc is one of the cause.¹⁶ Painful foot drop presents to a neurosurgeon comparatively earlier than the painless one. Hence, the cause is usually an acute one and the damage is resultantly partial. Controversy exists about the time of operation and resultant outcome. Postacchini et al¹⁰ and Aono et al¹¹ found that amount of weakness pre-operatively is directly associated to duration of foot-drop. Similarly, Guigui et al¹² found single nerve root involvement, and < 6 weeks duration of weakness results in good recovery; they failed to identify an association between severity of weakness and recovery. On the other hand, Iizuka et al¹⁷ found relationship between pre-operative strength on dorsiflexion and post-operative recovery but no association with the duration of weakness.

In our study, foot drop was due to intervertebral disc prolapse at L4 – L5 level in the majority of cases (88.4%) which is consistent with findings in study conducted by Liu K et al.¹⁸ We found good results in terms of improvement in Tibialis anterior muscle strength after surgery when the patients present with short duration of symptoms and the foot-drop are painful. Our patients presented to us with partial foot drop, when its MRC grade was equal to or less than 3 and more than 1 and hence our results showed that it was salvageable. Same results are shown with study conducted by Bhargava et al,¹⁶ in which 89% patient showed complete recovery of foot drop who presented within 4 weeks of onset of symptoms. He also showed that good pre-operative strength of Tibialis anterior muscle is also associated with improved post-operative outcome. While our study included patients with duration of foot drop of one month or less, Takenaka et al¹⁹ showed the least favorable outcome for patients having a duration of foot-drop of more than 1 month. He also showed a probability estimate of improvement in MRC grade to 3 or more of 94% if the pre-operative

duration of the partial foot-drop was less than a month, which is consistent with our findings. We also concluded in our study that 81.4% of patients showed post-operative recovery of foot drop to MRC grade ≥ 4 , and improvement in VAS of ≥ 2 points after 1 month while it was 93% after 6 month follow-up. This was consistent with the findings of Bhargava et al,¹⁶ which showed significant improvement after 6 months of surgery.

Recommendations for Study

Lumbar disc surgery is one of the most frequently performed surgeries worldwide. A lot of research work has been done on its efficacy. In our unit, our research team opted for conducting a thorough study on the efficacy of lumbar disc surgery in terms of improving neurology. Since acute cases of foot drop with associated pain is selected as our study target group.

CONCLUSION

Foot drop can be a debilitating consequence of lumbar disc herniation. Its early diagnosis and timely management are the key to recovery. Pain is a blessing in this case, hence it signifies the shorter duration of the nerve root malfunction and most of the time the foot drop is partial. MRI is the investigation of choice to diagnose lumbar disc prolapse. Considering all these facts while managing a foot drop case significantly favors the surgical outcome and improves the patient's quality of life.

Limitations of Study

A significant number of patients should be included in study to generalize our study results. Long duration of study was required to collect required pool of patients presenting with painful foot drop.

REFERENCES

1. Ahmad N, Mahmood A, Ahmad I, Shafi K, Aziz A. Immediate relief of lumbar redicular pain after surgical excision of prolapsed intervertebral disc. *JPOA*. 2010; 22 (1): 1-6.
2. Khatak A, Rehman L, Haider A, Ali M, Mushtaq and Ilyas. Surgical outcome of lumber disc surgery in 250 patients. *Pak J. of Neurol. Surg.* 2008; 12 (2): 27-31.
3. Moore KL, Agur AMR. *Essential clinical anatomy*. 3rd ed. Philadelphia, PA: Lippincott Williams & Wilkins; 2007: p. 692.
4. Masakado Y, Kawakami M, Suzuki K, Abe L, Ota T et

- al. Clinical neurophysiology in the diagnosis of peroneal nerve palsy. *Keio J Med.* 2008; 57: 84-89. Doi: 10.2302/kjm.57.84. PubMed:18677088.
5. Stewart JD. Foot drop: where, why and what to do? *Prac Neurol.* 2008; 8: 158-169. Doi: 10.1136/jnnp.2008.149393.
6. Voermans NC, Koetsveld AC, Zwartz MJ. Segmental overlap: foot drop in S1 radiculopathy. *Acta Neurochir.* 2006; 148: 809-813. Doi: 10.1007/s00701-006-0754-0. PubMed:16523224.
7. Aono H, Iwasaki M, Ohwada T, Okuda S, Hosono N et al. Surgical outcome of drop foot caused by degenerative lumbar diseases. *Spine*, 2007; 32: E262–E266. Doi: 10.1097/01.brs.0000251884.94821.c0. PubMed:17426622.
8. McCulloch JA, Waddell G. Variation of the lumbosacral myotomes with bony segmental anomalies. *J Bone Joint Surg Br.* 1980; 62: 475–480. Pub Med: 7430228.
9. Hijikata SA. A method percutaneous nuclear extraction. *Journal of Toden Hospital*, 1975; 5: 39-42.
10. Postacchini F, Giannicola G, Cinotti G. Recovery of motor deficits after microdiscectomy for lumbar disc herniation. *J Bone Joint Surg Br.* 2002; 84: 1040–1045.
11. Aono H, Iwasaki M, Ohwada T. et al. Surgical outcome of drop foot caused by degenerative lumbar diseases. *Spine*, 2007; 32: E262–E266.
12. Guigui P, Benoist M, Delecourt C, Delhoume J, Deburge A. Motor deficit in lumbar spinal stenosis: a retrospective study of a series of 50 patients. *J Spinal Disord.* 1998; 11: 283-288.
13. Alamgir, Ali M, Sharafat S, Khan Z, Khan KM, Usman M, et al. Analysis of patients operated for lumber disc herniation. *Pak J. of Neurol. Surg.* 2009; 13 (2): 103-07.
14. Michael A, Adams, Peter J and Roughly. What is intervertebral Disc Degeneration and what causes it? *Spine*, 2006; 14 (2): 101-08.
15. Tureyen K. One level one sided lumber disc surgery with and without microscopic assistance: 1 year outcome in 114 conservative patients. *J Neurosurg.* 2003; 99: 247-50.
16. Bhargava D, Sinha P, Odak S, Tyagi A, Towns G, Pal D. Surgical outcome for foot drop in lumbar degenerative disease. *Global Spine J.* 2012; 2: 125–128.
17. Iizuka Y, Iizuka H, Tsutsumi S, et al. Foot drop due to lumbar degenerative conditions: mechanism and prognostic factors in herniated nucleus pulposus and lumbar spinal stenosis. *J Neurosurg Spine*, 2009; 10: 260–264.
18. Liu K, Zhu W, Shi J, Jia L, Shi G, Wang Y, Liu N. Foot drop caused by lumbar degenerative disease: clinical features, prognostic factors of surgical outcome and clinical stage. *PLoSOne*, 2013; 8: e80375.
19. Takenaka, S. & Aono, H. *Clin Orthop Relat Res.* 2017; 475: 872. Doi: 10.1007/s11999-016-5180-x.

Additional Information

Disclosures: Authors report no conflict of interest.

Ethical Review Board Approval: The study was conformed to the ethical review board requirements.

Human Subjects: Consent was obtained by all patients/participants in this study.

Conflicts of Interest:

In compliance with the ICMJE uniform disclosure form, all authors declare the following:

Financial Relationships: All authors have declared that they have no financial relationships at present or within the previous three years with any organizations that might have an interest in the submitted work.

Other Relationships: All authors have declared that there are no other relationships or activities that could appear to have influenced the submitted work.

Address for Correspondence:
Musawer Khan
Neurosurgery department, Mardan Medical Complex, Mardan
Email: modestgaze@yahoo.com

AUTHORS CONTRIBUTIONS

Sr.#	Author's Full Name	Intellectual Contribution to Paper in Terms of:
1.	Musawer Khan	1. Study design and methodology.
2.	Musawer Khan	2. Paper writing, referencing, data calculations and
3.	Mumtaz Ali	3. Data collection and calculations
4.	Adnan Ahmed	4. Analysis of data and interpretation of results etc.
5.	Mansoor Ahmad	5. Literature review and manuscript writing
6.	Akramullah	6. Analysis of data and quality insurer

Date of Submission: 24-02-2020

Date of Revision: 16-6-2020

Date of Online Publishing: 25-09-2020

Date of Print: 30-09-2020