

## Primary Reading Epilepsy

Tamio OTA\*, Akio MIZUKI\*,  
Syuhei KAWASAWA\*, Yoshitsugu NAKAMURA\*,  
Michio YAMADA\*, Yukiko SAMURA\*\*  
Jiro SHIBATA\*\* and Kazuo SUIZU\*\*

\*Department of Neuropsychiatry, Yamaguchi  
University School of Medicine, Ube.

\*\*Hofu Hospital, Hofu.

(Received April 23, 1979)

### ABSTRACT

Primary reading epilepsy belongs to a group of seizures precipitated by sensory input. A possible case of the disease is presented. The patient, a 30-year-old man, developed while reading several seizures emanating from the tongue, jaw, and throat followed by generalized convulsions. The seizures were not provoked by activities other than reading.

The baseline EEG was normal with a minimum intermingled theta activity. Seizures could not be provoked by reading at the out-patient clinic. Accordingly, it was not possible to record abnormal EEG patterns that accompany the seizures. The CT scanning showed a slight temporal lobe atrophy, which was more prominent in the nondominant hemisphere. The occipital cortex showed no marked changes.

*Key Words: reading epilepsy; EEG; CT; psychotic state*

### INTRODUCTION

In 1956, Bickford et al.<sup>1)</sup> reported patients who had seizures precipitated by reading. These patients had generalized convulsions provoked by reading, preceded by curious sensations and twitching around the jaw, mouth, and the throat. Reading epilepsy is usually divided into two groups, primary and secondary. Primary reading epilepsy is defined as a type of epilepsy in which generalized convulsions occur only during reading. Secondary reading epilepsy is characterized by spontaneous seizures as well as those precipitated by reading and also photic stimulation or overbreathing.

The number of the patients with primary reading epilepsy reported in the literature is still small. None has been described in Japan. The present paper deals with such a patient. Possible correlation of the

disease with other epileptic and psychotic diseases will be discussed.

### CASE REPORT

A 30-year-old, right handed male patient was an employee of a balance shop. On Feb. 18, 1976, he visited the outpatient clinic of Hofu Hospital, complaining of vague bodily discomfort. He had had some difficulty in his human relationships in the preceding few years. In crowded places, he felt uneasy, irritable, and restless. His motor activities slowed and he talked to himself occasionally. He also complained of insomnia.

His family history showed no neurological, psychiatric, or convulsive disorders. He graduated from an agricultural high school and was employed for a few years in a textile factory and then an electric industry. He did not smoke and had no alcoholic habituation.

Since three years, he had had several convulsive seizures. The first seizure occurred while he was in bed, reading a book. He first noticed some clonic movement of the tongue, then the jerky movement spread to the throat and the jaw. When the seizure occurred, he tried to cry out for help, but he could not. Then he lost consciousness. The loss of consciousness lasted between a few minutes and half an hour. Severe headache always accompanied the return of consciousness. There were no sphincter disturbances during the seizures. Two weeks after the first visit, he had a twitching movement confined to the tongue and the jaw. However, generalized convulsions did not occur. Treatment consisting of prescription of anticonvulsant drugs was begun on Feb. 18, 1978 at the outpatient clinic of Hofu Hospital. Thereafter, the seizures tended to occur only when the drug was not taken. Even after the medication began, he still complained of hypersensitivity to the environment.

He had an obsessive character and also complained of difficulty in his human relations at the workshop. Reading books concerning his work did not precipitate seizures, while comic books with pornographic content tended to provoke the seizures.

#### Physical Examinations

His bodily constitution was athletic. The extremities were long and the phalanges were well developed. The head was slightly smaller than normal. Deep tendon reflexes were not remarkable. No pathological reflexes were elicited anywhere in the body. No other signs of malformation or dysgenesis were observed.

#### Psychological Evaluations

Kraepelin's Test;  $M_1 : M_2 = 59.5 : 66.5$ . Slightly poor rest effect.

Type a<sup>2</sup>. Rorschach's Ink Blot Test; reaction time is slower than normal. Otherwise unremarkable: Wechsler's Intelligent Scale for Adult; verbal I.Q., 95, performance I.Q., 95. The lower border of the normal range. MMPI; Code 8-7, a nervous and neurotic patient. Electroencephalogram

Examination on Jan. 25, 1978, the EEG showed medium to slightly high voltage diffuse alpha activities with trace of medium voltage theta activity (Fig. 1). Re-examination seven months later showed low to medium voltage slow alpha activity with occasional dysrhythmic bursts while he attempted to read. No clearly demonstrable seizure activity or clinical grand mal seizure was observed. No pathological findings were induced by overbreathing or photostimulation (Fig. 2).

#### CT Scanning

An EMI CT 1010 scanner was used in the contrast enhancement. A slight temporal lobe atrophy was observed bilaterally. The lateral ventricles were also slightly enlarged, especially in the right side (Figs. 3, 4). These findings suggest either old damage due to convulsive seizures or a congenital defect in the central nervous system. No localized abnormality was observed.

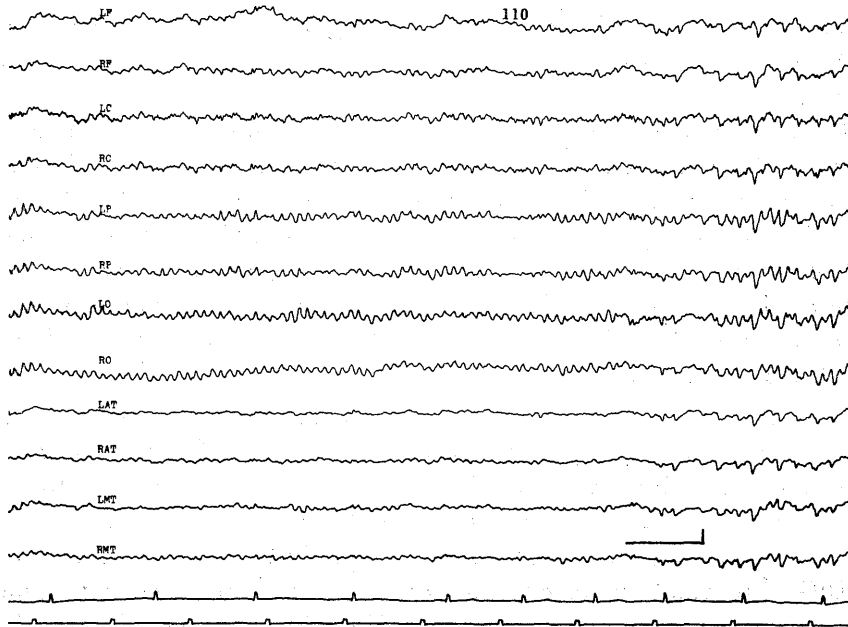


Fig. 1. EEG at rest with closed eyes. Occasional appearance of theta activities.

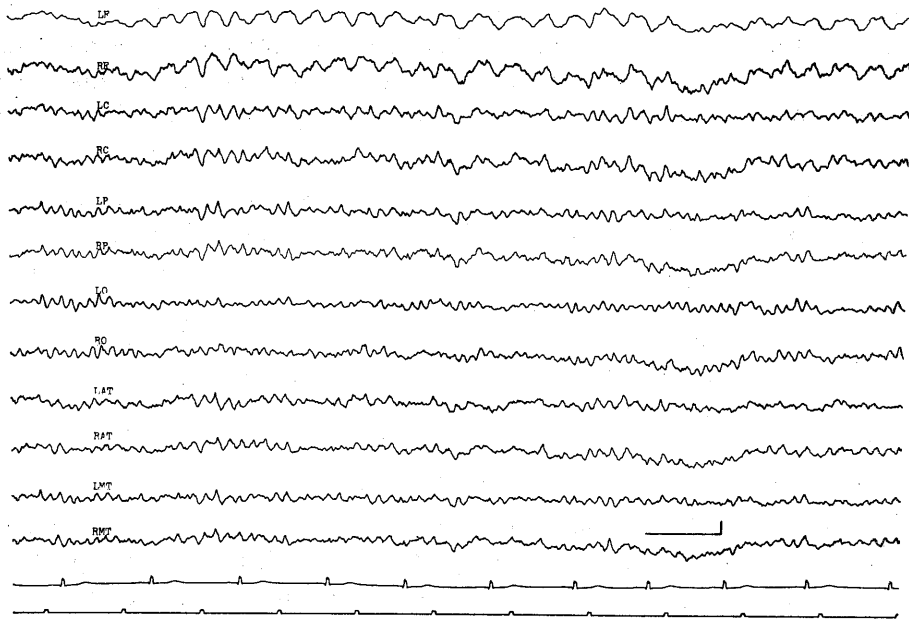


Fig. 2. EEG while reading. Poor alpha attenuation with slightly dysrhythmic patterns.

### COMMENT

Several cases of primary reading epilepsy have been reported in the literature<sup>1-3</sup>). In Japan, however, no case of the disease has been reported.

Jerky movement in our case is not the typical jaw clenching or clicking (Matthews et al.<sup>5</sup>). We have not yet seen the seizure firsthand. Clearly demonstrable seizure activity was not recorded by the EEG. Although more follow-up may be necessary in establishing the diagnosis, we believe that this case belongs to the category of primary reading epilepsy. His history, his jaw movements and subsequent loss of consciousness, and the slight slowing of the basic activity in the EEG all suggest the diagnosis.

The mechanism of reading epilepsy is still obscure. Some authors stress the importance of pattern vision and the on-off effect of pattern stimuli<sup>2</sup>). Photic stimulation was ineffective in our patient. Within the limited period of examination in the outpatient clinic, reading comic books failed to produce abnormal seizure activity while monitoring by the EEG. Stevens<sup>3</sup>) reported a patient with primary reading epilepsy whose seizures occurred when reading Hebrew, and were more slowly precipitated by reading aloud. Spike discharges were more striking in

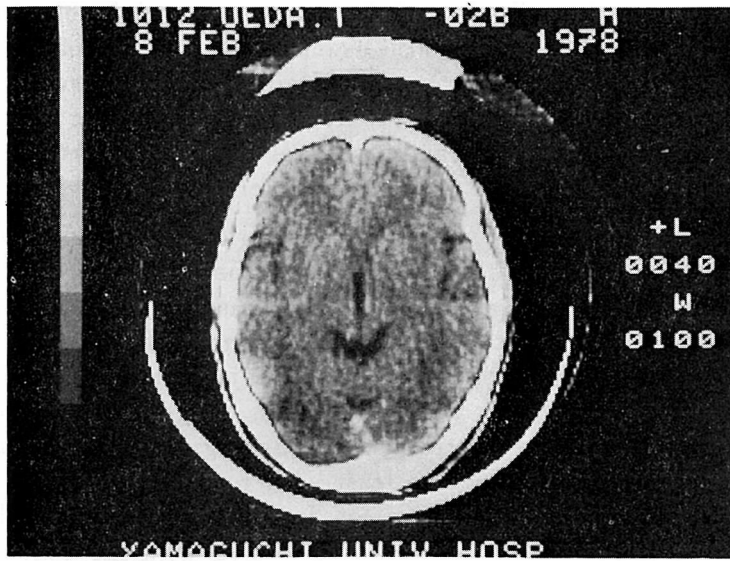


Fig. 3. CT scanning figure, showing minimal dilatation of the third ventricle and right Sylvian fissure.

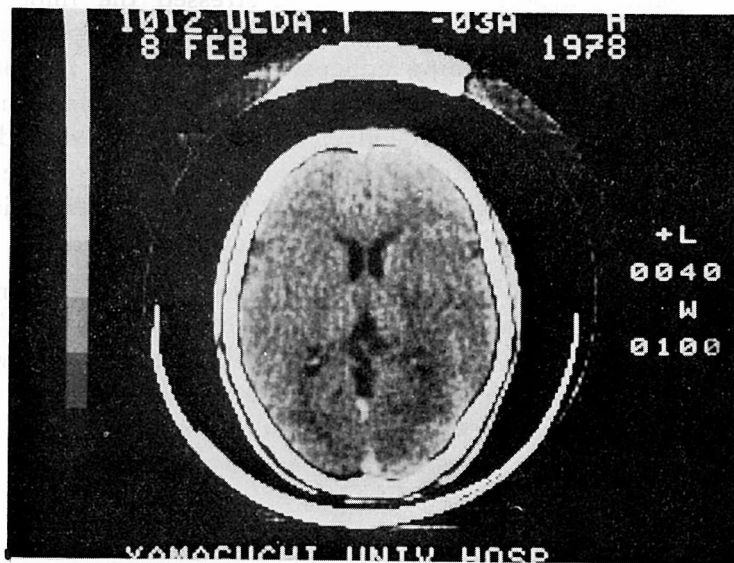


Fig. 4. CT scanning figure, showing minimal sulcal widening in the right insular lobe.

the anterior than in the posterior leads, a finding in contrast to Bickford et al.<sup>1)</sup> who stressed the importance of concentration and continuous right to left scanning in reading Hebrew. Norbury's EEG findings<sup>2)</sup>

showed left central small spike and slow activity while his 23-year-old male patient was reading. He also examined an 18-year-old patient with primary reading epilepsy who while reading showed several bursts of slow and spike waves in the alpha voltage range appearing synchronously in all leads. This patient's grandfather was in a mental hospital. Norbury stresses also the importance of genetic factors.

As for the mechanism of primary reading epilepsy, Critchley<sup>8)</sup> postulated that it is a cumulative effect of a number of mechanisms activated in an excited state in a person already predisposed to epilepsy. Other authors suspect that the proprioceptive discharges from the eye muscles, and also possibly from the muscles of the jaw, tongue, and throat in people who "mouth" words when they read, trigger the seizures. In our case, no marked changes were observed during photic stimulation. He was not severely handicapped at least with respect to his job. His seizures occurred during free time, not during work. The books which precipitate seizures are not of the kind related with his business.

Takahashi<sup>9)</sup> reported that on-and-off stimuli produced abnormal EEG activity in 22 out of 312 epileptics studied. Within these 22 cases, he found 13 of pattern hypersensitivity and he stressed the importance of on-and-off stimuli using geometrical figures. Hosokawa<sup>4)</sup> presented possible case of a secondary reading epilepsy. The EEG of the patient at rest showed intermingled slow activity. Intravenous megitimide administration and photic stimulation provoked multiple spike and wave discharges. Jaw clicking was not observed. The chief complaint of the patient was occasional obscure vision while reading. However, generalized convulsions and the loss of consciousness were never observed.

Matthews and Wright<sup>5)</sup> documented the occurrence of primary reading epilepsy in a mother and her daughter. Two of Lasater's cases<sup>7)</sup> were sisters and he suggested that a genetically determined low activation threshold of the nonspecific reticular system is probably an essential condition in the occurrence of primary reading epilepsy. In our case, there was no other family member with epilepsy or other neurological deficits.

The CT scanning in our case failed to identify a marked organic defect in the central nervous system. The only abnormality detected was a slight widening of the Sylvian fissures, especially in the right hemisphere. The occipital cortex showed no demonstrable sulcal widening or other unusual findings. The patient complained of difficulties in his human relations within the working environment. Schizophrenic disease was suspected. However, psychological tests failed to prove it. Low in-

telligence, a finding unusual in cases of primary reading epilepsy, was probably an important element in the determination of his overall mental constitution.

## REFERENCES

- 1) Bickford, R.G., Whelan, J.L., Klass, D.W.Z. and Corbin, K.R.: Reading epilepsy. Clinical and electroencephalographic studies of new syndrome. *Trans. Amer. Neurol. Ass.*, 81 : 100-102, 1956.
- 2) Norbury, F.B. and Dennis Loeffler, J.D.: Primary reading epilepsy. *JAMA*, 184 : 661-662, 1963.
- 3) Stevens, H.: Reading epilepsy. *N. Engl. J. Med.*, 257 : 165-170, 1957.
- 4) Hosokawa, K., Yoshioka, H. and Yamamoto, M.: One case of "reading epilepsy" (in Japanese). *Clinical Psychiatry*, 7 : 71-76, 1965.
- 5) Matthews, M.B. and Wright, F.K.: Hereditary primary reading epilepsy. *Neurology*, 17 : 919-921, 1967.
- 6) Geschwind, N. and Sherwin, I.: Language-induced epilepsy. *Arch. Neurol.*, 16 : 25-31, 1967.
- 7) Lasater, G.M.: Reading epilepsy. *Arch. Neurol.*, 6 : 492-495, 1962.
- 8) Critchley, N., Cobb, W. and Sears, T.A.: On reading epilepsy. *Epilepsia*, 1 : 403-417, 1959-1960.
- 9) Takahashi, T.: Study of visual epilepsy. On-off activation and clinical EEG findings (in Japanese). *Clin. Neurol.*, 13 : 156-165, 1973.