

Underdiagnosis of enamel defects in Family Health Centres of Talca city, Chile.

Sub-diagnóstico de defectos del esmalte en Centros de Salud Familiar de la ciudad de Talca, Chile.

Carla Orellana-Herrera.¹

Karla Bascuñan-Yañez.¹

Karla Gambetta-Tessini.²

Vidal Pérez-Valdés.¹

Affiliations:

¹Department of Pediatric Stomatology, University of Talca, Chile.

²Department of Oral Rehabilitation, University of Talca, Chile.

Corresponding author: Vidal Pérez-Valdés. Universidad de Talca. Avda. Lircay s/n, Talca, Chile. **Phone:** (55-71) 2203026. **E-mail:** vperez@utalca.cl

Receipt : 10/04/2019 **Revised:** 05/26/2020
Acceptance: 08/24/2020

Abstract: Enamel defects (i.e. hypoplasia, diffuse and demarcated opacities), in particular Molar Incisor Hypomineralization (MIH), are alterations of dental enamel with underlying implications in affected children. A proper diagnosis and clinical dental records are needed to improve clinical management of enamel defects in primary health setting. This cross-sectional study aimed to determine the prevalence of enamel defects in 6-year-old children attending to Family Health Centres in Talca city and comparing the clinical diagnosis with that registered by general dental practitioners (GDPs) on the clinical dental records. Children (n=318) were evaluated by a calibrated examiner using the modified DDE index criteria. Almost half of children had enamel defects (47.5%; n=151). The proportion of children affected by demarcated opacities (36.8%; n=117) was higher than those effected by hypoplasia (13.8%; n=44) and diffuse opacities (12.6%; n=40). MIH prevalence was 19.8% (n=63) and 22% (n=14) of MIH-affected children presented the severe form. Clinical dental records registered by GDPs recorded 6.6% (n=10) of enamel defects, but the type of defect was not consistent with the clinical examination undertaken by the calibrated examiner. These findings suggest that enamel defects are prevalent in the studied population, but only few cases were registered in clinical dental records. To achieve diagnosis consensus, the registration section for enamel defects in the clinical dental record at Family Health Centres may need some improvement. Further diagnostic training for GDPs working in the public sector may also be necessary.

Keywords: Dental enamel hypoplasia; dental enamel; dental records; children; public health dentistry; public sector.

Resumen: Los defectos del esmalte (hipoplasia, opacidades difusas y demarcadas), en particular la hipomineralización incisiva molar (MIH), son alteraciones del esmalte dental con implicaciones subyacentes en los niños afectados. Se necesita un diagnóstico y registros dentales clínicos adecuados para mejorar el tratamiento clínico de los defectos del esmalte en el entorno de atención primaria. Este estudio transversal tuvo como objetivo determinar la prevalencia de defectos del esmalte en niños de 6 años que acuden a los Centros de Salud Familiar de la ciudad de Talca y comparar el diagnóstico clínico con el registrado por los odontólogos generales (OGs) en la historia clínica odontológica. Los niños (n=318) fueron evaluados por un examinador calibrado utilizando los criterios del índice DDE modificado. Casi la mitad de los niños tenían defectos del esmalte (47,5%; n=151). La proporción de niños afectados por opacidades demarcadas (36,8%; n=117) fue mayor que los afectados por hipoplasia (13,8%;

Cite as:

Orellana-Herrera C, Bascuñan-Yañez K, Gambetta-Tessini K & Pérez-Valdés V. Underdiagnosis of enamel defects in Family Health Centres of Talca city, Chile. *J Oral Res* 2020; 9(3):195-201. **Doi:**[10.17126/joralres.2020.036](https://doi.org/10.17126/joralres.2020.036)

n=44) y opacidades difusas (12,6%; n=40). La prevalencia de MIH fue del 19,8% (n=63) y el 22% (n=14) de los niños afectados con MIH presentaron la forma grave. Los registros dentales clínicos registrados por los OGs mostraron el 6,6% (n=10) de los defectos del esmalte, pero el tipo de defecto no fue consistente con el examen clínico realizado por el examinador calibrado. Estos hallazgos sugieren que los defectos del esmalte son prevalentes en la población estudiada, pero solo unos pocos casos fueron registrados

en los registros dentales clínicos. Para lograr un consenso en el diagnóstico, la sección de registro de defectos del esmalte en la historia clínica dental de los Centros de Salud Familiar puede necesitar algunas mejoras. También puede ser necesaria un mayor entrenamiento diagnóstico para los OGs que trabajan en el sector público.

Palabra Clave: *Hipoplasia del esmalte dental; esmalte dental; registros odontológicos; niño; odontología en salud pública; sector público.*

INTRODUCTION.

Enamel defects are developmental dental defects that originate before the teeth erupt in the mouth. These defects have become very relevant amongst researchers and paediatric dentists because their high prevalence and significant implications for children's oral health.¹

Children with enamel defects may experience pain, post-eruptive enamel breakdown and increased risk of extensive carious lesions, which makes the restoration of affected teeth a clinical challenge.¹⁻³ Enamel defects comprise a variety of alterations in the quality and quantity of dental enamel which are caused by disruption and/or damage of the enamel organ.⁴ In general terms, these defects can be classified as hypoplasia (*i.e.*, lack of enamel with soft edges), diffuse opacities (*e.g.*, some types of dental fluorosis) and demarcated opacities.⁵

In the last 20 years, demarcated opacities have become the centre of attention for many researchers and paediatric dentists due to a particularly frequent clinical presentation that affects 1 in 6 children worldwide.^{1,6}

When demarcated opacities affect first permanent molars, it is called Molar Hypomineralization. Sometimes, incisors may also be affected although less frequently and in this case, the condition is named Molar Incisor Hypomineralization (MIH).^{1,7}

A similar defect can also be observed in primary second molars, namely Hypomineralised Second Primary Molars (HSPM).⁸ In some children MIH and HSPM can be observed simultaneously, and the evidence suggests that HSPM is a significant predictor for MIH development. In Chile, the prevalence rates for MIH have been reported in Temuco (16.8%), Santiago (12.7%) and Talca (15.8%) city.^{1,9,11} HSPM has been explored in a single study reporting a prevalence of 5% in 6-to-12-year old schoolchildren.⁹

Traditional preventive and restorative management for normal teeth may not be effective on teeth affected

by MIH/HSPM.¹² Therefore, early diagnosis and frequent clinical check-ups are key steps when treating MIH-affected children.¹³

Moreover, in severe cases, the extraction of MIH-affected molars is a plausible treatment option, which makes this condition an economic burden for families, as the subsequent orthodontic treatment is necessary to recover the occlusal function.¹²⁻¹⁴

Despite an individualised clinical management has been recommended to treat MIH-affected children, clinical guidelines are useful to standardise treatment protocols. Yet, specific clinical guidelines to treat patients affected by MIH are unavailable in Chile.

As the aetiology of most enamel defects remain obscure, early diagnosis is important for ongoing improvement in paediatric oral care.¹⁵ In Chile, a comprehensive dental program for 6-year-old children exists, named the "GES Program" (explicit guarantees in health; GES by its acronym in Spanish).

This program prioritises free dental treatment at Public Family Health Centres until children's four permanent molars erupt.¹⁶ The GES clinical dental records comprise a section to register enamel defect presence per child. However, a classification of enamel defects and MIH/HSPM presence are not detailed in the GES records.¹⁷ Therefore, is it unknown if general dental practitioners (GDPs) are correctly recording and classifying enamel defects as a significant oral health predictor in early stages. Despite most of GDPs working in Family Health Centres in Chile appear to be clinically familiarised with these conditions.¹⁸ Unfortunately, there is no standardised method to record enamel defects, and this has contributed greatly to the wide variations in prevalence rates reported worldwide.¹⁵ The aim of the present study is to determine the prevalence of enamel defects in 6-year-old children attending the dental service at Family Health Centres of Talca city.

A secondary aim is to contrast the clinical diagnosis obtained during the present study with the diagnosis registered on dental records by GDPs of the GES Program.

MATERIALS AND METHODS.

A cross-sectional study approved by the Scientific Ethics Committee of the University of Talca (N° 2014-035-CO) was conducted.

Participants included 6-year-old children attending the GES Program from five Family Health Centres in Talca city. Children presenting four fully erupted first permanent molars and four second primary molars were included in the study. A sample calculation was performed assuming a 95% confidence interval and a 5% error with an expected prevalence of 17%.¹¹

The number of children needed to calculate prevalence of enamel defects was 217. The present study used a cluster sample derived from the selection of Family Health Centres, a design effect of 1.2 was estimated for this sample,¹⁹ giving a sample size of N=260 children. To allow the calculated final sample size and considering a 25% rejection rate, 325 children and their families were invited to participate.

Before initiation of the study, a single examiner(KB) carried out a training exercise in enamel defect diagnosis (based on the modified developmental defect of enamel index; DDE index),²⁰ with the aid of an experienced paediatric dentist (CO) at the Dental School of the University of Talca.

Subsequently, children were examined in two attempts separated by 30min. Kappa value was 0.74 for enamel defects and 0.72 for MIH for intra-examiner measures representing substantial agreement.^{20,21}

The clinical examinations were performed from November 2014 to January 2015. Prior to the check-up, teeth were brushed by participants and then dried with gauze by the examiner. After that, enamel defects were registered in a written examination sheet especially designed for the present study.

In the demarcated opacities category, those with or without post-eruptive enamel breakdown were included. Children with demarcated opacities in their first permanent molars were categorised as MIH cases.⁷

Severity of MIH was classified by the presence of post-eruptive enamel breakdown [*i.e.*, a) mild: without breakdown and b) severe: with breakdown].

Immediately after recording the above information, and in every child examined, the examiner inspected the clinical dental records filled by the GDP of the GES Program which was compared with the clinical diagnosis recorded in the present study.

Statistical analyses included descriptive information regarding the prevalence of enamel defects. Comparisons between clinical diagnosis and clinical dental records were calculated by Fisher's exact test.

The *p*-values lower than 0.05 were considered significant. The analyses were computed by SPSS version 25 (IBM, NY, USA)

Figure 1. Percentage distribution of the severity of molar incisor hypomineralization(MIH) amongst patients diagnosed with MIH.

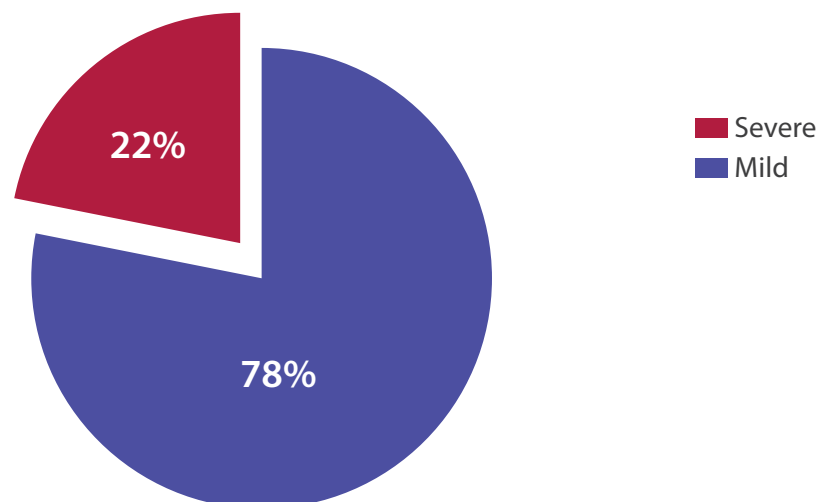


Table 1. Enamel defects distribution in 6-year-old children examined at Family Health Centres in Talca, Chile.

Enamel defects		Total n (%)
		318 (100)
Presence	No-enamel defects	167 (52.5)
	Yes-enamel defects	151 (47.5)
Types	Hypoplasia	44 (13.8)
	Diffuse opacities	40 (12.6)
	Demarcated opacities	117 (36.8)
	MIH	63 (19.8)
	MIH severity	
	Mild	49 (15.4)
	Severe	14 (4.4)

MIH: molar incisor hypomineralization.

Table 2. Proportion of enamel defects registered and not registered by GDPs at Family Health Centres compared to those registered by the present study examiner.

Enamel defects		Not registered by GDPs. n (%)	Registered by GDPs. n (%)	Total Registered by study examiner. n (%)
		308 (100)	10 (100)	318 (100)
Presence of enamel defects**		141 (93.4)	10 (6.6)	151 (100)
Types	Hypoplasia*	39 (88.6)	5 (11.4)	44 (100)
	Diffuse opacities*	40 (12.6)	0	40 (100)
	Demarcated opacities*	109 (93.2)	8 (6.8)	117 (100)
	MIH*	57 (90.5)	6 (9.5)	63 (100)
	MIH severity			
	Mild	46 (93.6)	3 (6.1)	49 (100)
	Severe	11 (78.6)	3 (21.4)	14 (100)

**:*p*-value<0.001. *:*p*-value<0.05 calculated with Fisher's Exact Test. GDPs: general dental practitioners. MIH: molar incisor hypomineralization.

RESULTS.

From the total number of children examined (n=318), 47.5% (n= 151) presented enamel defects (Table 1). The most prevalent defects were demarcated opacities with or without post-eruptive enamel breakdown (36.8%; n=117) followed by hypoplasia (13.8%; n=44) and diffuse opacities (12.6%; n=40).

MIH prevalence was 19.8% (n=63) and most of children were diagnosed as mild MIH (15.4%; n=49). Fourteen children presented severe MIH (4.4%) which represented 22% of the total number of children diagnosed with MIH (Figure 1).

From 151 children with enamel defects, clinical dental records registered by GDPs of the GES Program recorded 10 patients with enamel defects (6.6%). Of the 44 patients with hypoplasia, five (11.4%) were registered by the GDP.

Patients with demarcated opacities were 117. Of those, eight (6.8%) were shown in the records. Six (9.5%) of the

63 MIH-affected patients were registered by the GDP. Clinical dental records filled by GDPs registered only a quarter of severe cases of MIH. All these differences were statistically significant (Table 2).

DISCUSSION.

Enamel defects are an oral-health problem worldwide.¹ Early diagnosis may help to improve prevention and therapeutic approaches directed to affected children. However, methods to register enamel defects on the clinical dental records usually lack of standardisation.¹⁵ This limitation is responsible for an underestimation of the condition in the recorded data, especially in Family Health Centres. The present study reported that almost half of the examined 6-year-old children presented enamel defects. More importantly, the clinical dental record used in Family Health Centres was unable to accurately register the prevalence of enamel defects in the studied population. This situation could also be influenced by

the limited awareness of GDPs of the GES Program regarding enamel defects.

The prevalence of enamel defects reported in the present study mirrors previous epidemiological studies undertaken in similar populations.^{9-11,22} The present findings demonstrated that demarcated opacities were nearly three times more prevalent than diffuse opacities and hypoplasia. These numbers are similar to those obtained in a Poland study of children from primary schools.²³ It has been reported that children presenting demarcated opacities and hypoplasia may be at risk of developing severe carious lesions while those affected by diffuse opacity usually present a lower likelihood for carious lesion progression.^{9,23}

Accurate diagnosis of children affected by enamel defects is needed to identify the population at high-caries-risk (due to "weak enamel") in order to plan early interventions to improve the clinical prognosis of these children. The prevalence of MIH in the studied population (19.8%) is the highest reported in Chile currently.⁹⁻¹¹

However, it is within the range of previous reports (*i.e.* From 2.8% to 40%).¹² As presented in Figure 1, one in five children with MIH were affected by a severe form of the condition.

This result is lower than previous study exploring MIH severity in Chile.¹¹ These differences in prevalence and severity of MIH in population of similar age may be explained by the diverse criteria in sample selection and indices used during the clinical examination. Therefore, future research is needed to standardize diagnostic methods in order to properly compare reported prevalence rates, as suggested.^{24,25}

It is relevant that the clinical dental record existing in the Family Health Centres was largely unable to accurately register the prevalence of enamel defects, as presented in Table 2.

Clinical dental records registered only 1 of 15 children affected by enamel defects, 1 of 10 cases of MIH and a small proportion of the severely MIH-affected children. A standardised data collection instrument is necessary to summarise enamel defects data obtained from clinical examination.

This standardisation would be useful to achieve comparable diagnostic outcomes and to plan individualised clinical management for children affected by enamel defects and MIH.¹⁵ The findings of the present study showed an evident underestimation of

the prevalence of enamel defects in the Family Health Centres in Talca. Despite this is a local study, the results can be extended to the entire country as all Family Health Centres use the same clinical dental record.

Consequently, it is possible that this diagnostic deficiency be accompanied with an under-treatment of enamel defects, as proper follow-up is unlikely. In case dentists were able to diagnose enamel defects properly, they are incapable to systematically register this information on the clinical dental record.

A previous study amongst Chilean dentists working in the public sector showed that diagnosis and management of enamel defect are considered challenging.¹⁸ These limitations make a comprehensive dental management of any enamel defects (*e.g.*, diagnosis, prevention, treatment and follow-up) difficult to achieve. Improving the diagnosis of enamel defects in public services is recommended by

1) Including an edited enamel defect section in the clinical dental records and,

2) planning continuing education programs directed to dentists working at Family Health Centres, in regards to diagnosis and treatment of enamel defects. The latest has been recently reported as key step to improve the ability of dental staff to diagnose the different types of enamel defects.^{9,26,27}

Currently, the clinical dental record at Family Health Centres allows a proper registration of carious lesions, periodontal health and soft tissue lesions. These registration methods have helped to develop public health measurements that have contributed to the consistent improvement of oral health in children attending the GES Program in Chile.¹⁶

However, it does not allow the complete registration of enamel defects using the current nomenclature. It was impossible to determine if the examined children were affected by hypoplasia, diffuse opacities, demarcated opacities or by MIH. In addition, it was difficult to define whether MIH-affected teeth suffered post-eruptive enamel breakdown or not.

To increase knowledge regarding the impact of enamel defects on our population's oral health, improvements in the registration systems are required. This knowledge will be useful to re-frame public policies and dental programs, as recommended in the literature.^{15,28}

With the data presented, a modification for the GES clinical dental record is proposed. This modification is based on methods proposed by Ghanim *et al.*,²⁹ in

2015. The suggested recording system is simple and easy to fill. For example, in every tooth, the presence of enamel defects could be coded as follows: hypoplasia (H), diffuse opacities (DiO) and demarcated opacities (DeO). For DeO, the colour of the defect (white; DeOW, Yellow/brown; DeOY) and the presence of post-eruptive enamel breakdown also needs to be registered as PEB.

When a tooth presents more than one enamel defect, the most severe should be registered. This proposed recording method will allow to longitudinally follow-up the defects' behaviour (e.g., tendency to post-eruptive enamel breakdown, carious lesion development) and to improve the epidemiological data existing in Chile.

This proposed section needs to be discussed amongst health policy makers and in the future could be added to the national clinical dental record. This modification also involves more training amongst GDPs aiming at obtaining a precise diagnosis of enamel defects.

This investigation has limitations, such as the sampling methods and diagnostic criteria, which should be considered when interpreting the results. Moreover, the GDP's knowledge about enamel defects was not assessed by the present study. Therefore, the assessment of the awareness regarding enamel defects is recommended along with testing the effect of continuing education in the diagnosis capacity of the GDPs working at the GES Program.

In conclusion, enamel defects are highly prevalent in the studied population. More importantly, there is an underdiagnosis of enamel defects in the GES Program at Family Health Centres in Talca city. The clinical dental record was unable to register accurately the type of enamel defects in the study sample. The implications of the detected limitations in the registration systems requires further discussion amongst policy makers and more research at primary health level.

Conflict of interests: Authors declare no conflict of interest.

Ethics approval: This Project was approved by the Ethical Committee of University of Talca (N° 2014-035-CO).

Funding: Authors acknowledge financial support from the Department of Pediatric Stomatology, University of Talca, Chile.

Authors' contributions: All the authors of this manuscript participated in its preparation.

Acknowledgements: None.

REFERENCES.

1. Hubbard MJ, Mangum JE, Perez VA, Nervo GJ, Hall RK. Molar Hypomineralisation: A Call to Arms for Enamel Researchers. *Front Physiol.* 2017;8:546.
2. Orellana C, Perez V. Modified glass ionomer and orthodontic band: An interim alternative for the treatment of molar incisor hypomineralization. A case report. *J Oral Res.* 2017;6(3):70-4.
3. Almuallem Z, Busuttil-Naudi A. Molar incisor hypomineralisation (MIH) - an overview. *Br Dent J.* 2018;225:601-9.
4. Lacruz RS, Habelitz S, Wright JT, Paine ML. Dental enamel formation and implications for oral health and disease. *Physiol Rev.* 2017;97(3):939-93.
5. Suckling GW. Developmental defects of enamel - historical and present-day perspectives of their pathogenesis. *Adv Dent Res.* 1989;3(2):87-94.
6. Barros de Alencar C, Cavalcanti A. Molar incisor hypomineralization - A challenge of Pediatric Dentistry ? *J Oral Res.* 2018;7(3):84-5.
7. Weerheijm KL, Jälevik B, Alaluusua S. Molar-incisor hypomineralisation. *Caries Res.* 2001;35(5):390-1.
8. Silva MJ, Scurrah KJ, Craig JM, Manton DJ, Kilpatrick N. Etiology of molar incisor hypomineralization - A systematic review. *Community Dent Oral Epidemiol.* 2016;44(4):342-53.
9. Gambetta-Tessini K, Marino R, Ghanim A, Calache H, Manton DJ. The impact of MIH/HSPM on the carious lesion severity of schoolchildren from Talca, Chile. *Eur Arch Paediatr Dent.* 2019;20(5):417-23.
10. Corral-Núñez C, Rodríguez H, Cabello R, Bersezio-Miranda C, Cordeiro RCL, Fresno-Rivas MC. Impacto de la hipomineralización incisivo molar en la experiencia de caries en escolares de 6-12 años en Santiago, Chile. *Rev Clin Periodoncia Implantol Rehab.* 2016;9:277-83.
11. Jans Muñoz A, Díaz Meléndez J, Vergara González C, Zaror Sánchez C. Frecuencia y Severidad de la Hipomineralización Molar Incisal en Pacientes Atendidos en las Clínicas Odontológicas de la Universidad de La Frontera, Chile. *Int J Odontostomatol.* 2011;5:133-40.
12. Almuallem Z, Busuttil-Naudi A. Molar incisor hypomineralisation (MIH) - an overview. *Br Dent J.* 2018; 225:601-9.
13. Lygidakis NA, Wong F, Jälevik B, Vierrou AM, Alaluusua S, Espelid I. Best Clinical Practice Guidance for clinicians dealing with children presenting with Molar-Incisor-Hypomineralisation (MIH). *Eur Arch Paediatr Dent.* 2010;11(2):75-81.
14. Eichenberger M, Erb J, Zwahlen M, Schätzle M. The timing of extraction of non-restorable first permanent molars: a systematic review. *Eur J Paediatr Dent.* 2015;16(4):272-8.
15. Elfrink ME, Ghanim A, Manton DJ, Weerheijm KL. Standardised studies on Molar Incisor Hypomineralisation (MIH) and Hypomineralised Second Primary Molars (HSPM): a need. *Eur Arch Paediatr Dent.* 2015;16(3):247-55.
16. Superintendencia-de-salud. Garantías Explícitas en Salud (GES) [Internet]. Santiago: Superintendencia de Salud; 2019 [cited 2020 May 23]. Available at: <http://www.supersalud.gob.cl/difusion/665/w3-article-597.html>.
17. MINSAL. Guía Clínica Urgencias odontológicas [Internet]. Santiago: Ministerio de Salud; 2011 [cited 2020 May 23]. Available from: <https://www.minsal.cl/portal/url/item/7222b6448161ecb1e04001011f013f94.pdf>.
18. Gambetta-Tessini K, Mariño R, Ghanim A, Calache H, Manton DJ. Knowledge, experience and perceptions regarding Molar-Incisor Hypomineralisation (MIH) amongst Australian and Chilean public oral health care practitioners. *BMC Oral Health.* 2016;16(1):75.
19. Gambetta-Tessini K, Mariño R, Ghanim A, Calache H, Manton D. Carious lesion severity and demarcated hypomineralized lesions of tooth enamel in schoolchildren from Melbourne, Australia. *Aus Dent J.* 2018;63(3):365-73.
20. A review of the developmental defects of enamel index (DDE Index). Commission on Oral Health, Research & Epidemiology. Report of an FDI Working Group. *Int Dent J.* 1992;42(6):411-26.
21. Landis JR, Koch GG. The measurement of observer agreement for categorical data. *Biometrics.* 1977;33(1):159-74.
22. Andrade NS, Dos Santos IT, Lima LMS, Lima CCB, Moura LFAD, Barros SSLV, Moura MS, Lima MDM. Impact of Developmental enamel defects on quality of life in 5-year-old children. *Int J Paediatr Dent.* 2019;29(5):557-565.
23. Opydo-Szymaczeka J, Gerreth K, Borysewicz-Lewicka M, Pawlaczyk-Kamieńska T, Torlińska-Walkowiak N, Śniatała R. Enamel defects and dental caries among children attending primary schools in Poznań, Poland. *Adv Clin Exp Med.* 2018;27(11):1535-40.
24. Glodkowska N, Emerich K. Molar Incisor Hypomineralization: prevalence and severity among children from Northern Poland. *Eur J Paediatr Dent.* 2019;20(1):59-66.
25. Ghanim A, Mariño R, Manton DJ. Validity and reproducibility testing of the Molar Incisor Hypomineralisation (MIH) Index. *Int J Paediatr Dent.* 2019;29(1):6-13.
26. Dabiri D, Eckert GJ, Li Y, Seow K, Schroth RJ, Warren J, Wright JT, Zhao S, Fontana M. Diagnosing Developmental Defects of Enamel: Pilot Study of Online Training and Accuracy. *Pediatr Dent.* 2018;40(2):105-109.
27. Jälevik B, Szgyarto-Matei A, Robertson A. Difficulties in identifying developmental defects of the enamel: a BITA study. *Eur Arch Paediatr Dent.* 2019; 20(5):481-88.
28. Ghanim A, Silva MJ, Elfrink MEC, Lygidakis NA, Mariño RJ, Weerheijm KL, Manton DJ. Molar incisor hypomineralisation (MIH) training manual for clinical field surveys and practice. *Eur Arch Paediatr Dent.* 2017;18(4):225-42.
29. Ghanim A, Elfrink M, Weerheijm K, Mariño R, Manton D. A practical method for use in epidemiological studies on enamel hypomineralisation. *Eur Arch Paediatr Dent.* 2015;16(3):235-46.