

This is a provisional PDF only. Copyedited and fully formatted version will be made available soon.



ISSN: 0015-5659

e-ISSN: 1644-3284

“Popliteofascial muscle” or rare variant of the tensor fasciae suralis?

Authors: Ł. Olewnik, B. Gonera, K. Kurtys, R. S. Tubbs, M. Polguj

DOI: 10.5603/FM.a2020.0138

Article type: CASE REPORTS

Submitted: 2020-07-21

Accepted: 2020-10-18

Published online: 2020-11-03

This article has been peer reviewed and published immediately upon acceptance.
It is an open access article, which means that it can be downloaded, printed, and distributed freely,
provided the work is properly cited.

Articles in "Folia Morphologica" are listed in PubMed.

“Popliteofascial muscle” or rare variant of the tensor fasciae suralis?

Popliteofascial muscle

Ł. Olewnik¹, B. Gonera¹, K. Kurtys¹, R.S. Tubbs^{2,3,4}, M. Polguj¹

¹Department of Normal and Clinical Anatomy, Chair of Anatomy and Histology, Medical University of Lodz, Poland

²Department of Neurosurgery, Tulane University School of Medicine, New Orleans, LA, USA

³Department of Neurosurgery and Ochsner Neuroscience Institute, Ochsner Health System, New Orleans, LA, USA

⁴Department of Anatomical Sciences, St. George’s University, Grenada

Address for correspondence: Ł. Olewnik, MD, PhD, Department of Normal and Clinical Anatomy, Interfaculty Chair of Anatomy and Histology, Medical University of Lodz, Poland, e-mail: lukasz.olewnik@umed.lodz.pl

Abstract

Anatomical variations are routinely encountered during dissections of muscles and in clinical practice, so anatomists and clinicians need to be aware of them. One such muscle is the tensor fascia suralis, a very rare muscle located in the popliteal fossa. It can originate from any of the hamstring muscles and it inserts into the fascia of the leg. This report presents a case of a variant muscle located very deep to the biceps femoris; it originated from the posterior surface of the femur and inserted into the fascia of the leg. It is unclear whether this is a rare variant of the tensor fascia suralis or a completely new muscle.

Key words: tensor fascia suralis muscle, variant muscle, supernumerary muscles, new muscle, hamstring tendon, semitendinosus muscle, semitendinosus tendon, biceps femoris

INTRODUCTION

Anatomical variations are commonly encountered, and although some have been described extensively in the literature, many are still being reported for the first time. Such

variations can include veins, arteries, innervation, muscles and even organs.

Although they are less common than variations in veins or arteries, muscle variants are nevertheless frequent and have been found to affect both lower and upper limbs and muscles of the chest, abdomen and back. These variants can include lack of a muscle, or the presence of supernumerary muscles, bifurcated muscles or tendons, deviation from the normal course, or a variable origin or insertion. They can affect routine clinical procedures or important and complex surgeries. For example, an additional head of the gastrocnemius muscle can cause pain syndromes or popliteal artery entrapment [10, 25], the variable course of the plantaris tendon has been associated with a higher risk of mid-portion Achilles tendinopathy [18, 28], and an atypical arrangement of the belly of the plantaris muscle is believed to apply pressure to the tibial nerve [20]. In addition, if a muscle of the forearm or the foot has multiple tendons, stenosing tenosynovitis can be triggered [3, 5, 11, 14, 19]. Anatomical variations in muscles typically have genetic causes and reflect our ancient origins. Some arise from anomalies in embryological development or the persistence of an embryological condition; however, most are benign.

The tensor fascia suralis muscle (TFS), also known as the ischioaponeuroticus, is a sporadic accessory muscle [2, 6, 9, 12, 22, 24, 27, 29]. It originates from the distal aspect of any of the hamstring muscles, typically the semitendinosus, and inserts into the sural fascia or the medial head of the gastrocnemius muscle or the calcaneal tendon [27].

This case report describes an extremely rare variant of the origin, insertion and course of the TFS, which could represent a completely a new lower limb muscle. Our findings highlight the importance of muscle variants in the popliteal region and are significant for radiologists, anatomists, physiotherapists and surgeons specializing in the knee region.

CASE REPORT

A male cadaver, 71 years old at death (height - 184 cm), was subjected to routine anatomical dissection for research and teaching purposes at the Department of Normal and Clinical Anatomy, Medical University of Lodz. The left thigh, knee and crural region were dissected using standard techniques according to a strictly-specified protocol [15, 16, 18, 21]. During the dissection of the right posterolateral region of the knee, an unusual tendon was found. It inserted to the deep fascia of the leg, close to the origin of the fibularis longus and the insertion of the biceps femoris. The tendon was cleaned and gently separated from the biceps femoris. The distal part of the biceps femoris was then removed to reveal the 'new muscle', the origin of which was found on the popliteal surface of the femur (Figs. 1, 2).

The next step was to obtain morphometric measurements using digital photographic images processed through MultiScanBase 18.03 (Computer Scanning System II, Warsaw, Poland). The length of the muscle belly was 33.1 mm, while the length of the tendon was 73.83 mm. The width at the origin was 7.51 mm. The width of the tendon was 5.63 mm at the myotendinous junction and 7.19 mm at the distal attachment. No other anatomical variations were identified.

Ethical approval and consent to participate

The cadaver belonged to the Department of Normal and Clinical Anatomy of the Medical University of Lodz.

DISCUSSION

Our case illustrates a potentially new structure of the popliteal region. It describes an accessory muscle (AM) located deep to the biceps femoris muscle, originating on the popliteal surface of the femur and inserting into the deep fascia of the leg, close to the origin of the fibularis longus and the insertion of the biceps femoris. On the basis of its origin, we propose the term “popliteofascial muscle” for this AM.

AMs and muscle variations are not uncommon in the lower and upper limbs. The most common AMs are accessory slips from the medial or lateral head of the gastrocnemius, accessory soleus, fibularis quartus and fibularis digiti quinti in the lower limb, and accessory lumbricals and extensor digitorum in the upper limb. In contrast, the TFS is one of the least frequently observed muscles in the lower limb. It has been identified using both sonography and MRI [4, 9, 12] and during anatomical studies [1, 2, 6, 22, 24, 26, 29], and its origin and insertion are morphologically highly variable (Table 1; Fig. 3).

Table 1. A comparison of case studies reporting the TFS

Study	Type of study	Origin	Insertion	Figure
Chason et al. (1995)	Radiological	Semitendinosus muscle	Achilles tendon	Fig. 3a
Montet et al. (2002)	Radiological	Semitendinosus muscle	Achilles tendon	Fig. 3a
Tubbs et al. (2006)	Anatomical	Semitendinosus muscle	Fascia of the leg	Fig. 3b

Padmalatha et al. (2010)	Anatomical	Semitendinosus muscle	Sural fascia	Fig. 3c
Kim et al. (2015)	Radiological	Lateral aspect of the semitendinosus muscle	Medial head of the GM	Fig. 3d
Rajendiran et al. (2016)	Anatomical	Medial side of the long head of the biceps femoris	Deep fascia over the gastrocnemius muscle	Fig. 3e
Bale et al. (2017)	Anatomical	Long head of the biceps femoris	On to the fascia of both heads of the GM	Fig. 3f

AMs are usually asymptomatic and encountered as incidental findings; however, some have been implicated as potential sources of clinical symptoms [17]. When it occurs, the TFS is clinically significant because it can cause swelling in the popliteal fossa [1, 12]. In addition, its location between the hamstring tendons in the popliteal region can mimic a Baker's cyst on physical examination [4, 12]. Moreover, as the TFS is located close to the neurovascular bundle, it can compress the popliteal vein, popliteal artery, sciatic nerve, tibialis or sural nerve [1, 9, 26, 27]; this can be mistaken for soft tissue tumors or aneurysms of the popliteal artery or abscesses [12]. Although no electrostimulation research has been carried out, it has been suggested that the TFS assists in flexion of the leg and places tension on the fascia of the posterior leg [29].

The TFS is located superficially in the popliteal fossa; it is found medially between the semitendinosus and semimebranosus muscles, and laterally between the semitendinosus and biceps femoris. This is quite different from the case we have described, in which the muscle is located very deep to the femoris biceps muscle and originates at the posterior surface of the femur. It possesses a short (33.1 mm) muscle belly, which is 7.51 mm wide at the femur; the muscle belly later becomes a tendon, 73.83 mm long, which inserts into the fascia of the leg at a point close to the head of the fibula and medially to the biceps femoris insertion (Fig. 1).

This muscle arrangement has not been described before, even as a variant of the TFS. We speculate that it assists in flexing the knee joint and in providing tension to the fascia of the leg; previous studies have attributed these functions to the TFS. Furthermore, in view of its atypical location, it could help to stabilize the posterolateral corner of the knee joint; this

has never been mentioned before. The presence of such a muscle in this location could be associated with clinical problems; for example, rupture of its distal part could be connected with femoris tendon biceps rupture. Owing to its close relationship with the fibular collateral ligament, injury to the ligament might affect the TFS and vice versa. In contrast to the ‘typical’ TFS described in earlier literature, it is doubtful that the muscle we have identified participates in compressing the tibial nerve or the popliteal vein and artery.

Other AMs have been reported in the area of the popliteal fossa [6, 13, 23, 26]. Somayaji et al. [26] describe an example originating by two slips, one from the semitendinosus and another from the biceps femoris muscle, which then connect to a common tendon and insert into the calcaneal tendon (Fig. 4a). A very similar case was described by Gupta et al. [6] in which the origin also consisted of two slips from the semitendinosus and biceps femoris; however, the common tendon formed was attached at the junction of the two heads of gastrocnemius muscle (Fig. 4b). Cases have been described of AMs running transversely from the biceps femoris tendon to the medial head of the gastrocnemius muscle, innervated from the common fibular nerve [13, 23]. Another supernumerary muscle in the popliteal fossa was found to originate from the biceps femoris tendon and insert into the medial head of the gastrocnemius muscle; innervation was from the lateral sural nerve, a branch of the common fibular nerve [8]. Interestingly, all cases describing the TFS muscle have been found in men [1, 4, 9, 12, 22, 24, 29]; although two cases of AMs have been found in women [8, 13], one had previously been found in a man [6], and the present case description also concerns a man.

The question arises as to whether these “accessory, variant muscles” are completely new muscles or rare variants of the TFS. Further studies are also needed to confirm whether the TFS muscle occurs only in men, and whether other AMs occur in the popliteal region in both men and women. The key question is whether this present case represents a new muscle or a rare variant of the TFS. Its close relationship with the biceps femoris and the locations of the insertion suggests that it is a rare TFS variant; however, its deep arrangement and attachment (origin), located on the popliteal surface of the femur, could suggest a new muscle.

The appearance of AMs can be explained by embryonic development. The muscles of the limbs develop from myogenic precursor cells that arise from the ventral dermomyotome of somites. In these precursor cells, muscle regulatory genes such as Pax 3 and Myf 5 are activated, resulting in the expression of transcription factors including Myo D, myogenin and myogenic regulatory factors. The fusion of myoblasts and myotubes leads to further growth of

the muscles and their subsequent investment by connective tissue. Additional variations in the muscle pattern can also be caused by alterations in the signalling or stimuli among mesenchymal cells [7, 24]. The final configuration of a muscle is achieved through several apoptosis and growth cycles of the muscle primordia, and the failure of these primordia to disappear results in the presence of an AM or even an additional muscle.

CONCLUSIONS

This case report describes a possible variant of the ‘tensor fascia suralis’, as indicated by its close relationship to the biceps femoris and the location of its insertion. However, the deep positioning of this muscle could indicate that it is in fact a new muscle; hence, if the latter, we propose the name “popliteofascial muscle”. Knowledge of such potential variations in the popliteal region is important for the surgeon when operating in and around the popliteal fossa, for the radiologist for correct radiological interpretations, and for the physiotherapist for correct diagnoses.

REFERENCES

1. Bale LSW, Herrin SO (2017) Bilateral Tensor Fasciae Suralis Muscles in a Cadaver with Unilateral Accessory Flexor Digitorum Longus Muscle. *Case Rep Med* 2017. doi: 10.1155/2017/1864272
2. Barry D, Bothroyd JS (1924) Tensor Fasciae Suralis. *J Anat* 58:382–383
3. Bravo E, Barco R, Bullón A (2010) Anatomic study of the abductor pollicis longus : A source for grafting material of the hand. *Clin Orthop Relat Res* 468:1305–1309. doi: 10.1007/s11999-009-1059-4
4. Chason DP, Schultz SM, Fleckenstein JL (1995) Tensor fasciae suralis: Depiction on MR images. *Am J Roentgenol* 165:1220–1221. doi: 10.2214/ajr.165.5.7572507
5. Fabrizio P, Clemente FR (1996) A Variation in the Organization of Abductor Pollicis Longus. *Clin Anat* 375:371–375. doi: 10.1002/(SICI)1098-2353(1996)9
6. Gupta R, Kumar BSS (2006) An anomalous muscle in the region of the popliteal fossa: A case report. *J Anat Soc India* 55:65–68
7. Ilayperuma I, Nanayakkara G, Palahepitiya N (2011) Incidence of Humeral Head of Biceps Brachii Muscle: Anatomical Insight. *Int J Morphol* 29:221–225. doi: 10.4067/s0717-95022011000100037
8. Kim DI, Kim HJ, Shin C, Lee KS (2009) An abnormal muscle in the superficial region of the popliteal fossa. *Anat Sci Int* 84:61–63. doi: 10.1007/s12565-008-0002-1
9. Kim KH, Shim JC, Lee GJ, Lee KE, Kim HK, Suh JH (2015) MR Imaging and Ultrasonographic Findings of Tensor Fasciae Suralis Muscle: A Case Report. *J Korean Soc Radiol* 73:249. doi: 10.3348/jksr.2015.73.4.249
10. Kwon YJ, Kwon T-W, Gwon JG, Cho Y-P, Hwang S-J, Go K-Y (2018) Anatomical popliteal artery entrapment syndrome. *Ann Surg Treat Res* 94:262. doi: 10.4174/astr.2018.94.5.262
11. Mahakkanukrauh P, Mahakkanukrauh C (2000) Incidence of a septum in the first dorsal compartment

- and its effects on therapy of de Quervain's disease. *Clin Anat* 13:195–198. doi: 10.1002/(SICI)1098-2353(2000)13:3<195::AID-CA6>3.0.CO;2-V
12. Montet X, Sandoz A, Mauget D, Martinoli C, Bianchi S (2002) Sonographic and MRI appearance of tensor fasciae suralis muscle, an uncommon cause of popliteal swelling. *Skeletal Radiol* 31:536–538. doi: 10.1007/s00256-002-0496-x
 13. Okamoto K, Wakebe T, Saiki K, Nagashima S (2004) An anomalous muscle in the superficial region of the popliteal fossa, with special reference to its innervation and derivation. *Ann Anat* 186:555–559. doi: 10.1016/S0940-9602(04)80106-7
 14. Olewnik Ł (2019) Is there a relationship between the occurrence of frenular ligaments and the type of fibularis longus tendon insertion? *Ann Anat* 224:47–53. doi: 10.1016/j.aanat.2019.03.002
 15. Olewnik Ł, Gonera B, Kurtys K, Podgórski M, Polguy M, Sibiński M, Topol M (2018) The anterolateral ligament of the knee: a proposed classification system. *Clin Anat* 1–2. doi: 10.1002/ca.23267
 16. Olewnik Ł, Podgórski M, Polguy M, Topol M (2018) The plantaris muscle-rare relations to the neurovascular bundle in the popliteal fossa The plantaris muscle-rare relations to the neurovascular bundle in the popliteal fossa. *Folia Morphol (Warsz)*. doi: 10.5603/FM.a2018.0039
 17. Olewnik Ł, Podgórski M, Ruzik K, Polguy M, Topol M (2019) New classification of the distal attachment of the fibularis brevis - anatomical variations and potential clinical implications. *Foot Ankle Surg*. doi: 10.10016/j.fas.2019.04.002
 18. Olewnik L, Wysiadecki G, Podgórski M, Polguy M, Topol M (2018) The Plantaris Muscle Tendon and Its Relationship with the Achilles Tendinopathy. *Biomed Res Int* 2018:1–2. doi: 10.1155/2018/9623579
 19. Olewnik Ł, Wysiadecki G, Polguy M, Podgórski M, Jezierski H, Topol M (2017) Anatomical variations of the palmaris longus muscle including its relation to the median nerve - A proposal for a new classification. *BMC Musculoskelet Disord* 18:1–9. doi: 10.1186/s12891-017-1901-x
 20. Olewnik, Podgórski M, Polguy M, Topol M (2018) The plantaris muscle - Rare relations to the neurovascular bundle in the popliteal fossa. *Folia Morphol* 77:785–788. doi: 10.5603/FM.a2018.0039
 21. Olewnik, Wysiadecki G, Polguy M, Topol M (2017) The report on the co-occurrence of two different rare anatomic variations of the plantaris muscle tendon on both sides of an individual. *Folia Morphol* 76:331–333. doi: 10.5603/FM.a2016.0069
 22. Padmalatha K, Prakash B, Mamatha Y, Ramesh B (2011) Ischioaponeuroticus / tensor fasciae suralis. *Int J Anat Var* 4:104–105
 23. Parsons FG (1920) Note on Abnormal Muscle in Popliteal Space. *J Anat* 54:170
 24. Rajendiran R, Murugesan A (2016) Unilateral tensor fasciae suralis: a case report. *Brunei Darussalam J Heal* 6:94–98
 25. Rodrigues V, Rao MK, Nayak S (2016) Multiple heads of gastrocnemius with bipennate fiber arrangement-a clinically significant variation. *J Clin Diagnostic Res* 10:AD01–AD02. doi: 10.7860/JCDR/2016/20094.8340
 26. Somayaji SN, Vincent R, Bairy KL (1998) An anomalous muscle in the region of the popliteal fossa: Case report [4]. *J Anat* 192:307–308. doi: 10.1017/S0021878297003257
 27. Sookur PA, Naraghi AM, Bleakney RR, Jalan R, Chan O, White LM (2008) Accessory Muscles: Anatomy, Symptoms, and Radiologic Evaluation. *RadioGraphics* 28:481–499. doi:

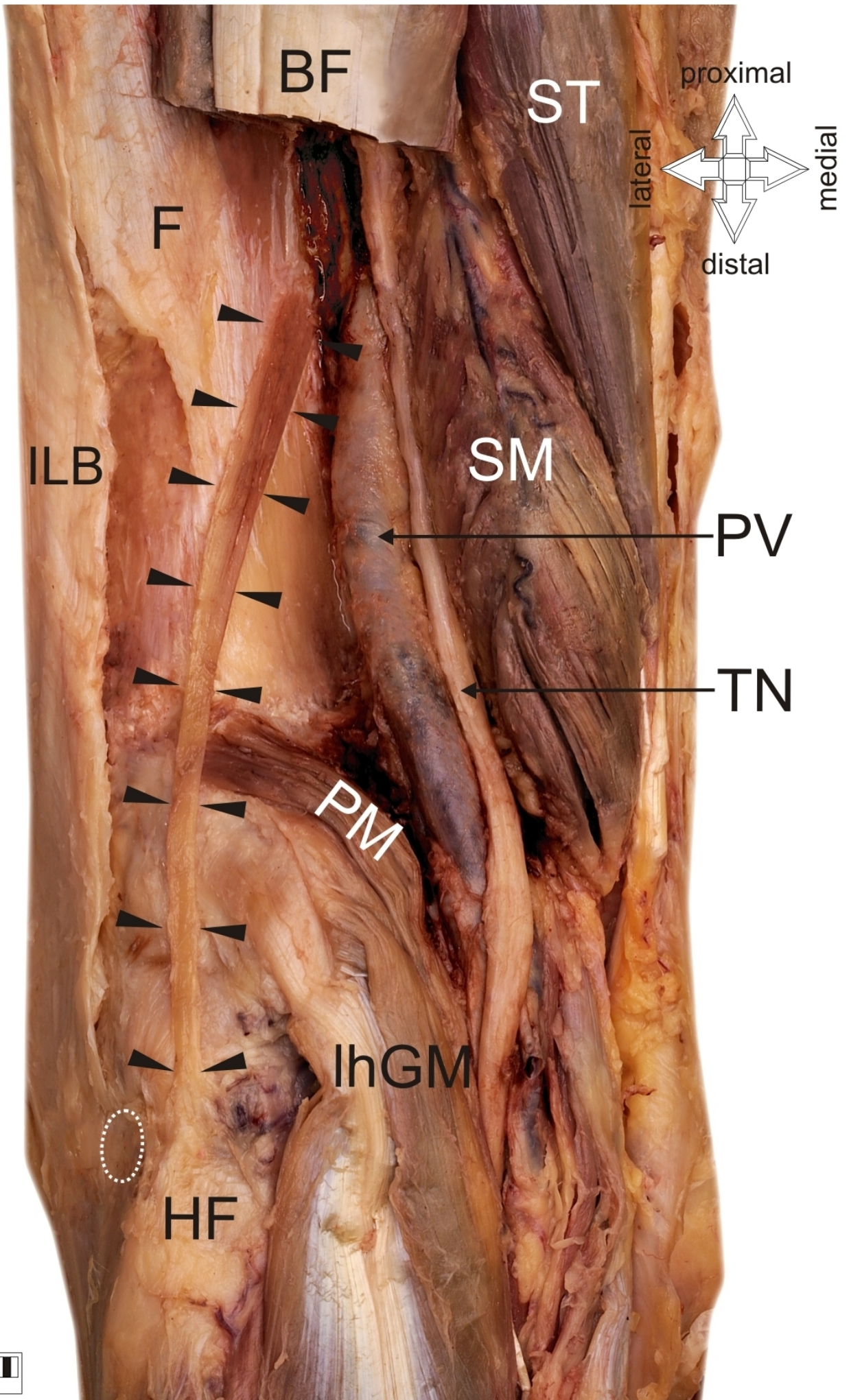
28. Van Sterkenburg MN, Kerkhoffs GMMJ, Kleipool RP, Niek Van Dijk C (2011) The plantaris tendon and a potential role in mid-portion Achilles tendinopathy: An observational anatomical study. *J Anat* 218:336–341. doi: 10.1111/j.1469-7580.2011.01335.x
29. Tubbs RS, Salter EG, Oakes WJ (2006) Dissection of a rare accessory muscle of the leg: The tensor fasciae suralis muscle. *Clin Anat* 19:571–572. doi: 10.1002/ca.20205

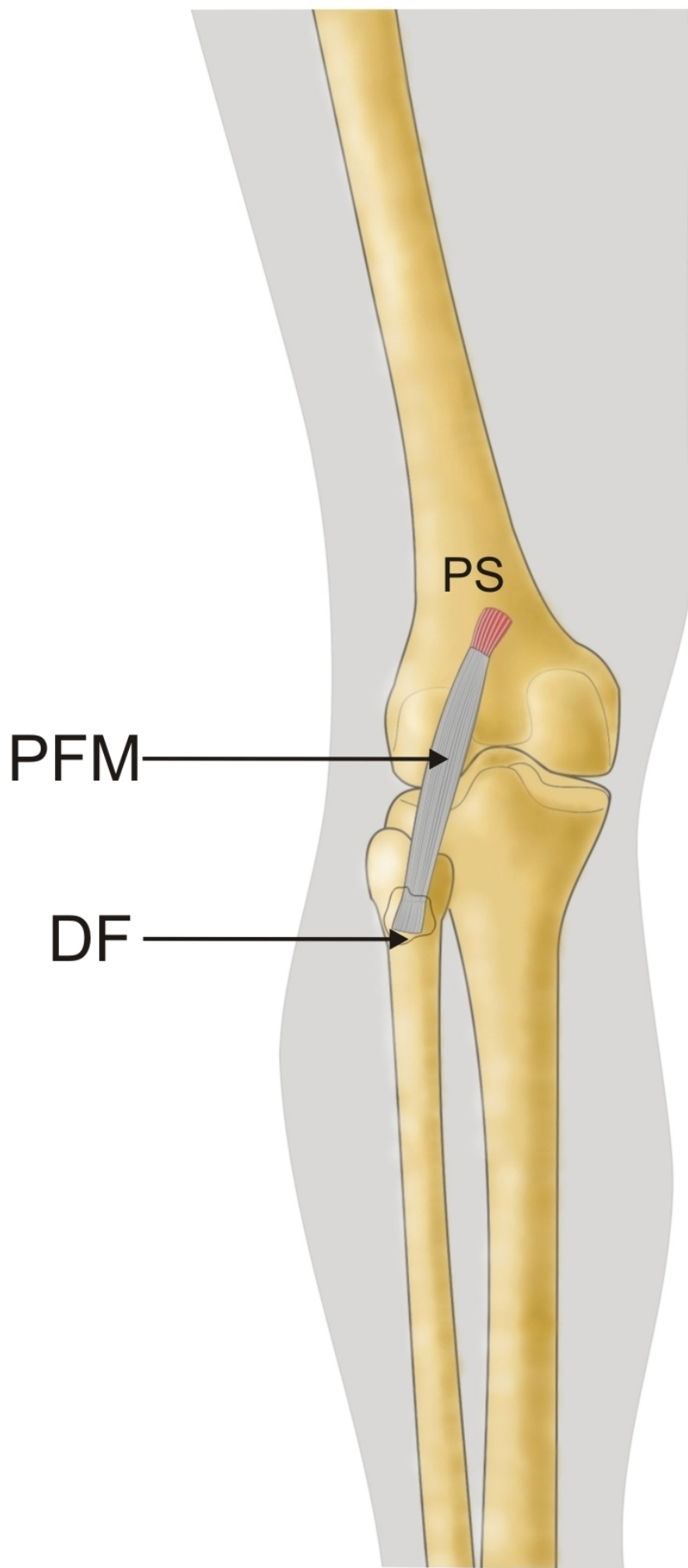
Figure 1. Rare anatomical type of tensor fascia suralis or new muscle. Left lower limb. *BF* biceps femoris muscle, *ST* semitendinosus muscle, *SM* semimebranosus muscle, *F* femur, *ILB* ilio-tibial band, *PV* popliteal vein, *TN* tibial nerve, *PM* plantaris muscle, *lhGM* lateral head of the gastrocnemius muscle, *HF* head of fibula; *white dashed line shows the insertion of the biceps femoris, black arrowheads indicate the new muscle.*

Figure 2. Schema of rare anatomical type of tensor fascia suralis or new muscle. Left lower limb. *PS* popliteal surface of the femur, *PFM* ‘popliteofascial muscle’, *DF* deep fascia.

Figure 3. Schema of rare anatomical types of tensor fascia suralis. *TFS* tensor fascia suralis, *BF* biceps femoris muscle, *ST* semitendinosus muscle, *SM* semimembranosus muscle, *Glh* lateral head of the gastrocnemius muscle, *Gmh* medial head of the gastrocnemius muscle, *AT* Achilles tendon, *DF* deep fascia of the leg.

Figure 4. Schema of variant muscle in the popliteal region. *AM* variant muscle, *BF* biceps femoris muscle, *ST* semitendinosus muscle, *SM* semimembranosus muscle, *Glh* lateral head of the gastrocnemius muscle, *Gmh* medial head of the gastrocnemius muscle, *AT* Achilles tendon.

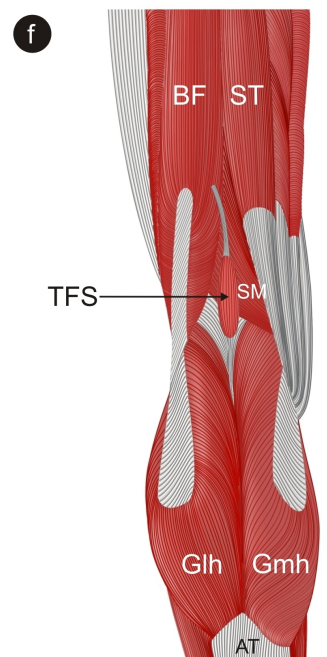
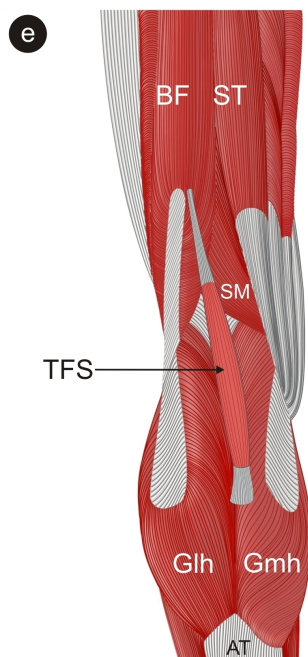
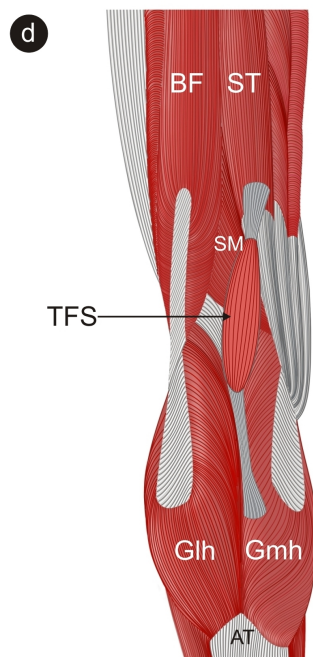
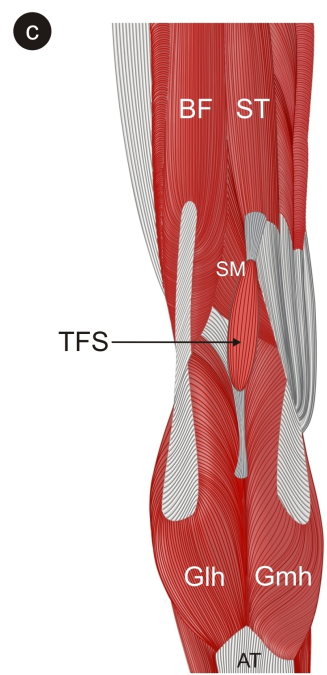
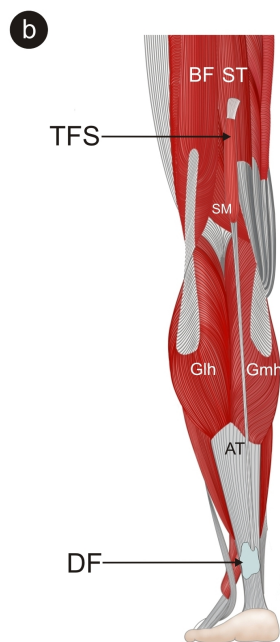
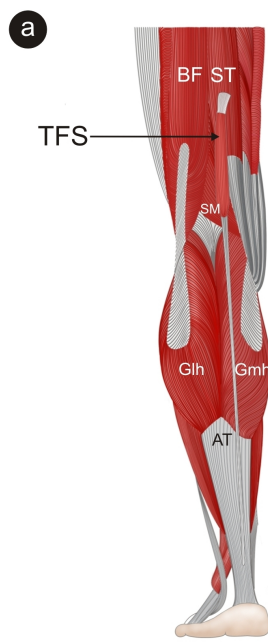




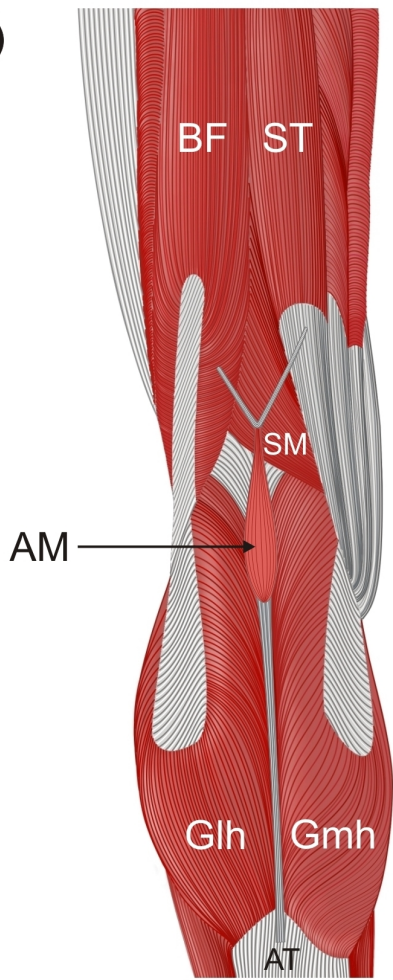
PS

PFM

DF



a



b

