

# A left main disease repeatedly treated with drug-coated balloon in a patient with poor adherence to medications

Song Lin Yuan<sup>1,2</sup>, Eun Jung Jun<sup>1</sup>, Moo Hyun Kim<sup>2</sup>, Scot Garg<sup>3</sup>, Eun-Seok Shin<sup>1</sup>

<sup>1</sup>Department of Cardiology, Ulsan Medical Center, Ulsan, South Korea

<sup>2</sup>Department of Cardiology, Dong-A University Hospital, Busan, South Korea

<sup>3</sup>East Lancashire Hospitals NHS Trust, Blackburn, Lancashire, United Kingdom

A 45-year-old male, heavy smoker, was admitted after a 1-week history of recurrent chest pain at minimal effort. His electrocardiography, cardiac enzyme and echocardiography showed normal. Coronary angiography showed a 95% left main (LM) stenosis with Thrombolysis in Myocardial Infarction (TIMI) grade 2 flow. He declined coronary artery bypass grafting (CABG) or stent implantation, but agreed to treatment with balloon angioplasty using a drug-coated balloon (DCB). He was carefully assessed and gave informed consent.

The lesion was dilated several times with a 3.5 × 10 mm scoring balloon at 12 atm and then a 3.5 × 20 mm DCB was inflated at 14 atm for 60 s. The final angiographic result was good. His angina symptoms were resolved. He remained well until presenting 6 months later with a recurrence of his symptoms. He admitted to discontinuing all his

medication, including dual antiplatelet therapy since discharge. Repeat angiography showed a 90% restenosis at the LM with TIMI grade 3 flow. He again declined CABG or stenting. Considering his poor drug compliance, repeat revascularization to the LM with DCB by same technique was performed. Again, the final angiographic result was good and 8 months later, follow-up angiographic and intravascular ultrasound confirmed excellent results (Fig. 1). He has been well without angina for 10 months now.

This case was repeatedly treated with DCB given concerns regarding the patient's poor compliance to medication including antiplatelets. These findings suggest that LM disease may be a potential alternative indication for DCB treatment, especially when patients are unsuitable for long-term antiplatelet therapy or unwilling to undergo CABG or stenting.

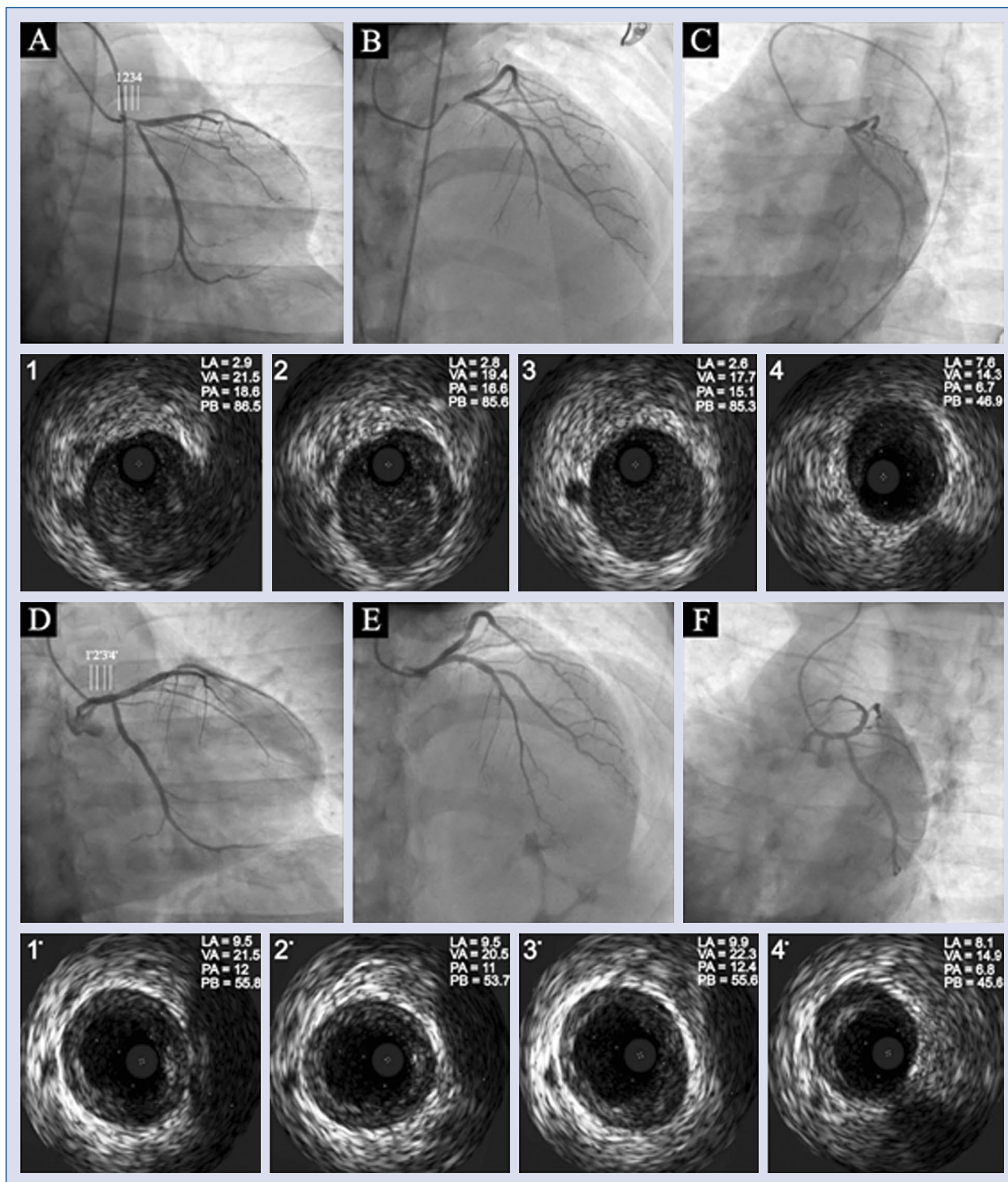
**Conflict of interest:** None declared

---

**Address for correspondence:** Eun-Seok Shin, MD, PhD, Department of Cardiology, Ulsan Medical Center, 13, Wolpyeong-ro, 171 beon-gil, Nam-gu, Ulsan, 44686, South Korea, tel: +82-52-259-5425, fax: +82-52-259-5117, e-mail: [sesim1989@gmail.com](mailto:sesim1989@gmail.com)

Received: 21.04.2020

Accepted: 5.05.2020



**Figure 1.** Pre-procedure (A–C), follow-up angiographic images (D–F) coupled to serial corresponding intravascular ultrasound (IVUS) images. At 8 months follow-up IVUS showed a much greater luminal area and decreased plaque burden in left main compared to baseline IVUS; LA — lumen area, mm<sup>2</sup>; VA — vessel area, mm<sup>2</sup>; PA — plaque area, mm<sup>2</sup>; PB — plaque burden, %.