

VICTORIA BLUE-NUCLEAR FAST RED STAIN FOR HBS ANTIGEN DETECTION

Yasuyuki MIYAKE, Toshiaki MANABE and Koshi YAMASHITA

*Department of Pathology, Kawasaki Medical School,
Kurashiki 701-01, Japan*

Accepted for Publication on June 15, 1981

Abstract

Six established methods for the detection of HBs antigens in paraffin section were compared in the reproducibility, staining property and recognition, specificity, complexity in preparation and staining procedure, and cost. The most reliable specificity was obtained by immunoperoxidase method; however, in its easy recognition, stability of dye solution and low cost, Victoria blue-nuclear fast red stain was considered the best procedure in the moderately busy laboratory.

INTRODUCTION

The presence of hepatitis B surface (HBs) antigens in paraffin embedded sections may be suspected as ground glass appearance of hepatocytes^{1,2)} when stained with hematoxylin and eosin. Rather specifically, they are identified by immunofluorescent and immunoperoxidase technique.³⁻⁸⁾ In addition, various staining techniques have been proved to be useful for the detection of HBs antigen. Included among them are Orcein stain, Weigert's resorsin-fuchsin stain, Victoria blue-nuclear fast red stain, Aldehyde-fuchsin stain and Aldehyde thionin stain. In our department, Orcein stain had been routinely used for this purpose. This staining, however, was unreliable in respect of its reproducibility. Generally, in the surgical pathology department of any hospitals, staining techniques with low cost, easy availability (stability of dye solution), short time for the staining, easy identification and good reproducibility are desired. For these reasons, we have compared six staining techniques for HBs antigen detection in above-mentioned points. Among these six ; namely Orcein (Shikata,^{9,10)} Senba & Itakura¹¹⁾, Victoria blue,^{12,13)} Gomori's Aldehyde fuchsin,^{14,15)} and Shikata's modified Aldehyde fuchsin stain¹⁶⁾ as well as immunoperoxidase (indirect method), Victoria blue proved most satisfactory in most points.

三宅康之, 真鍋俊明, 山下貢司

MATERIALS AND METHODS

Liver tissues from 42 autopsied cases with positive serum HBs antigen were used for this study. Tissues were fixed in 10% formalin, routinely processed and embedded in paraffin. Serial sections of 3-4 μ were obtained and were stained with Orcein stain of Shikata's modification, that of Senba and Itakura's, Victoria blue, Gomori's Aldehyde fuchsin, Shikata's modified Aldehyde fuchsin stain and immunoperoxidase (indirect method) in sequence. The same sequence of staining was repeated twice for each positive case to see the reproducibility. Staining methods were also compared in the cost, time consumption and staining property.

RESULTS

1) Positivity and reproducibility

Twenty-one out of 42 cases with positive serum HBs antigen were detected positive in tissue sections. HBs antigens were identified by all staining methods in these positive cases. Repeated series of the study gave exactly the same results, indicating a good reproducibility. Location of positive cells was in accordance in each preparation. It is, however, our impression that Orcein dye with different lot number may give a different result.

2) Staining property and recognition

HBs antigens were stained reddish purple in Shikata's modified Aldehyde-fuchsin, red purple in Gomori's Aldehyde fuchsin, dark blue in Victoria blue, and dark brown in Orcein and brown in immunoperoxidase method. In the first two staining methods the backgrounds were stained pink and light reddish purple respectively, which made the identification somehow difficult because of the tinctorial similarity. Rest of techniques gave a better contrast of the positive staining with the background.

In Orcein stain, the background was light brown and in Victoria blue light red. The best contrast was obtained in Victoria blue. In the indirect immunoperoxidase method, positive staining was usually weaker than the others.

3) Specificity

Immunoperoxidase method is considered specific when it is positive, although the negative result does not necessarily conclude the absence of the HBs antigen in the tissue section. Serial sections comparing the positivity in each staining procedure with that in immunoperoxidase method disclosed that the same cells were stained positive in any staining methods (Fig. 1a, b, c).

In staining methods other than immunoperoxidase elastic fibers, lipofuscin and bile pigments tend to be stained with similar tinctorial nature. Especially,

in Shikata's original staining procedure, degenerative as well as necrotic cells were also stained, making their differentiation difficult.

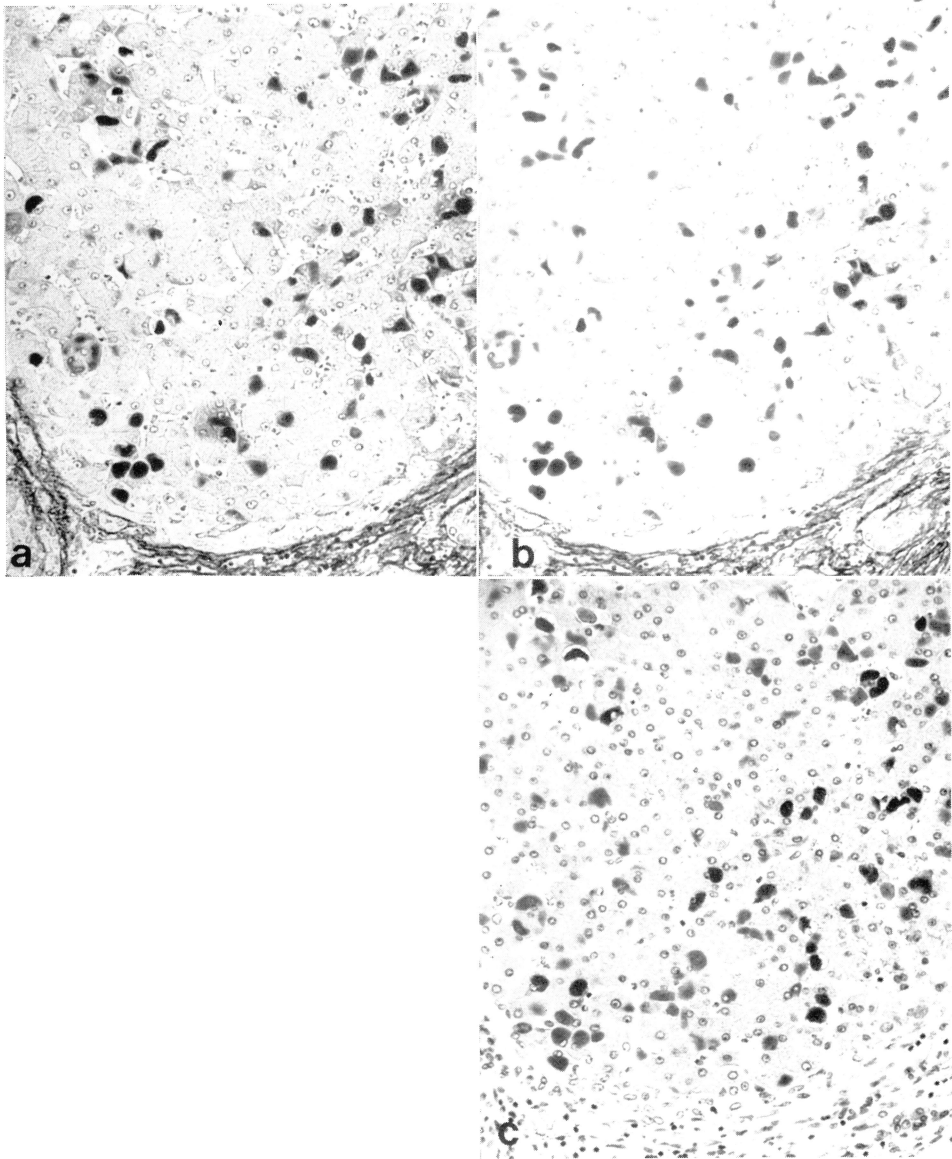


Fig. 1. HBs antigens stained by Orcein (a), Victoria blue nuclear fast red (b), and Immunoperoxidase (c). Note that each staining method demonstrates HBs antigens but Victoria blue shows highest contrast. Mag. (a), (b), (c) $\times 280$

4) Complexity in preparation and staining procedure, and cost

The time consumption for the preparation of staining solutions and the staining is listed in Table 1. The costs written in Table 1 were calculated as those used to stain up to 10 slides in 50 ml container each time. The duration of stain solutions to be used was not included here.

TABLE 1

staining methods	staining time (hrs)	cost (yen)	preparation of dye sol.	stability of dye sol.
1. Orcein (Shikata)	2—3.5	320	2 days	2 wks
2. Orcein (Senba & Itakura)	0.3—1	324	2 days	2 wks
3. Victoria blue-Nuclear fast red	24	303	2 wks	6-12 months
4. Aldehyde Fuchsin (Shikata)	1.3—1.6	230	3 days	1 wk
5. Aldehyde Fuchsin (Gomori)	0.5—1	150	3 days	1 wk
6. Immunoperoxidase(Indirect)	5—6	1000	—	—

DISCUSSION

Various staining methods are now available for the detection of HBs antigen in paraffin section. We compared six established methods for this purpose in five points; (1) reproducibility, (2) staining property and recognition, (3) specificity, (4) complexity in preparation and staining procedures and (5) cost. The most reliable specificity was considered to be obtained from immunoperoxidase. Other staining methods, in addition, gave equal positivities for HBs antigens; however, lipofuscin, bile pigments, and necrotic or necrobiotic cells were stained similarly and might become a source of false positivity. The differentiation of such false positive materials from real positive HBs antigens was not difficult for experienced pathologists. In view of easy recognition, stability of dye solution and cost, Victoria blue stain appears to be the best in the laboratory where the liver biopsy is done frequently. Although quick staining would be obtained by Orcein stain of Senba and Itakura's modification, it should be noted that Orcein solution can be utilized two days after the original preparation, and is stable for only two weeks. Therefore, this staining method is not suitable in laboratories with moderate number of liver biopsy materials. Based on the present study, Victoria blue-nuclear fast red stain is now in use in our department as a routine procedure.

REFERENCES

- 1) Hadziyannis, S., Gerber, M. A., Vissoulis, C. and Popper, H. : Cytoplasmic hepatitis B antigen in 'ground-glass' hepatocytes of carriers. *Arch. Pathol.* **96** : 327-330, 1973
- 2) Gerber, M. A., Hadziyannis, S., Vernase, S. and Vissoulis, C. : Incidence and nature of cytoplasmic hepatitis B antigen in hepatocytes. *Lab. Invest.* **32** : 251-256, 1975
- 3) Isumi, S. and Watanabe, K. : Fundamentals of immunoperoxidase method. *Med. Technol.* **23** : 539-552, 1979 (Jpn)
- 4) Mori, S. et al. : Immunoperoxidase of pathological tissue section. *Mod. Med. Lab.* **8** : 147-151, 1980 (Jpn)
- 5) Kawase, A. : Immunohistochemical diagnoses of functioning tumors. *Med. Technol.* **24** : 874-879, 1980 (Jpn)
- 6) Hayase, S. : Proof of immunoglobulin in lymph node. *Med. Technol.* **9** : 43-49, 1981 (Jpn)
- 7) Clausen, R. P. and Thomsen, P. : Demonstration of hepatitis B-surface antigen in liver biopsies. *Acta. Pathol. Microbiol. Scand. Sect. A* **86** : 383-388, 1978
- 8) Burns, J. : Immunoperoxidase localization of hepatitis B antigen (HB) in formalin-paraffin processed liver tissue. *Histochemistry* **44** : 133-135, 1975
- 9) Shikata, T. et al. : Study for staining of Australian antigen I. *Acta Hepatol. Jpn.* **14** : 425-431, 1973 (Jpn)
- 10) Shikata, T. et al. : Staining methods for HBs antigen in paraffin section. *Med. Technol.* **19** : 590-596, 1975 (Jpn)
- 11) Senba, M. and Itakura, H. : Improved method of HBs antigen staining by Orcein. *Acta Hepatol. Jpn.* **20** : 623, 1979 (Jpn)
- 12) Tanaka, K. and Mori, W. : Observation of tissue HBs antigen by Victoria blue-nuclear fast red stain. *Acta Hepatol. Jpn.* **20** : 306, 1979 (Jpn)
- 13) Suwa, K., Tanaka, K. and Mori, W. : Proof of HBs antigens in tissue section by Victoria blue stain. *Med. Technol.* **24** : 248-250, 1980 (Jpn)
- 14) Sano, Y. : Method of histological study. Nanzando, 1976, pp. 216, 276 (Jpn)
- 15) Kaneoka, A. : Comparative study of stainings for HBs antigen in liver biopsy section and laboratory data. *Jap. J. Med. Technol.* **9** : 58-61, 1979 (Jpn)
- 16) Shikata, T. et al. : Staining methods of Australian antigen in paraffin sections. *Jap. J. Exp. Med.* **44** : 25-36, 1974 (Jpn)