

Neuropathology of partial PGC-1 α deficiency recapitulates features of mitochondrial encephalopathies but not of neurodegenerative diseases

Levente Szalardy^a, Denes Zadori^a, Imola Plangar^a, Laszlo Vecsei^{a,b}, Patrick Weydt^c, Albert C. Ludolph^c, Peter Klivenyi^a, Gabor G. Kovacs^{d,*}

^a Department of Neurology, University of Szeged, Szeged, Hungary

^b Neuroscience Research Group in the Hungarian Academy of Science and University of Science, Szeged, Hungary

^c Department of Neurology, Ulm University, Ulm, Germany

^d Institute of Neurology, Medical University of Vienna, Vienna, Austria

Word count title: 15

Word count abstract: 244

Word count text: 4423

Number of figures: 3

Number of references: 61

Number of supplementary files: 1

Running head: Neuropathology of mice lacking full-length PGC-1 α protein

***Corresponding author:**

Gabor G. Kovacs, MD, PhD

✉ Institute of Neurology, AKH 4J, Währinger Gürtel 18-20, A-1097 Vienna, Austria

☎ Phone: +43-1-40400-5504; Fax +43-1-40400-5511;

Email: gabor.kovacs@meduniwien.ac.at

Abstract

Background: Deficient peroxisome proliferator activator receptor- γ coactivator-1 α (PGC-1 α) function is one component of mitochondrial dysfunction in neurodegenerative diseases. Current molecular classification of such diseases is based on the predominant protein accumulating as intra- or extracellular aggregates. Experimental evidence suggests that mitochondrial dysfunction and impaired protein processing are closely interrelated. *In vitro* findings further indicate that PGC-1 α dysfunction may contribute to protein misfolding in neurodegeneration.

Objective: To systematically evaluate the neuropathological alterations of mice lacking the expression of the full-length PGC-1 α protein (FL-PGC-1 α) but expressing an N-truncated fragment.

Methods: To assess the pattern of neurodegeneration-related proteins, we performed immunostaining for Tau, p-Tau, α -synuclein, amyloid- β , amyloid precursor protein, prion protein, FUS, TDP-43 and ubiquitin. Using Hematoxylin and Eosin, Klüver-Barrera and Bielschowsky silver stainings and anti-GFAP immunohistochemistry, we performed an anatomical mapping to provide a lesion profile.

Results: The immunohistochemical pattern of neurodegeneration-related proteins did not differ between FL-PGC-1 α knockout and wild-type animals, and there was a complete lack of protein deposits or ubiquitin-positive inclusions. The analysis of neuropathological alterations revealed wide-spread vacuolation predominating in the cerebral white matter, caudate-putamen, thalamus and brainstem, and reactive astrogliosis in the brainstem and cerebellar nuclei. This morphological phenotype was thus reminiscent of human mitochondrial encephalopathies, especially the Kearns-Sayre syndrome.

Conclusion: We conclude that the lack of FL-PGC-1 α *per se* is insufficient to recapitulate major features of neurodegenerative diseases, but evokes a pathology seen in mitochondrial encephalopathies, which makes PGC-1 α -deficient mice a valuable model for this yet incurable group of diseases.

Keywords: peroxisome proliferator activator receptor gamma coactivator-1alpha; mitochondrial dysfunction; misfolded protein; neurodegeneration; neuropathology; mitochondrial encephalopathy; Kearns-Sayre syndrome

Introduction

Mitochondria are membrane-bound organelles in the cytoplasm supposedly originating from the endosymbiosis of an ancient aerobic prokaryote with a eukaryotic cell. They provide environment for several essential biochemical processes, including the synthesis of adenosine triphosphate (ATP), and have a pivotal role in adaptive thermogenesis, intracellular Ca^{2+} homeostasis, cell-cycle regulation, development, aging and cell death. Mitochondrial dysfunction, accompanied by subsequent cellular energy imbalance and an overproduction of reactive oxygen species (ROS), has been strongly implicated in the pathogenesis of several neurological disorders, including the neurodegenerative diseases (NDDs) [1] and the primarily childhood-onset mitochondrial encephalopathies [2].

NDDs, such as Huntington's disease (HD), Alzheimer's disease (AD), Parkinson's disease (PD) and amyotrophic lateral sclerosis (ALS), are characterized by progressive loss of neurons in particular regions of the central nervous system (CNS), which is accompanied by the dysfunctional degradation and subsequent aggregation of misfolded proteins such as hyperphosphorylated tau (pTau), amyloid- β ($\text{A}\beta$), α -synuclein, prion protein (PrP), trans-activation response (TAR) DNA-binding protein (TDP-43) and fused in sarcoma protein (FUS). Accordingly, current molecular classification of NDDs is based on the predominant protein accumulating as intra- or extracellular aggregates [3]. The defects of both relevant degradation pathways – ubiquitin-proteasome system and autophagy – have been associated with NDDs [4], and emerging evidence based on neurotoxin-induced models of neurodegeneration suggests that mitochondrial dysfunction and impaired protein processing are closely interrelated [5-11].

The nuclear-encoded metabolic master regulator peroxisome proliferator activator receptor- γ (PPAR γ) coactivator-1 α (PGC-1 α) has a key integratory role in the transcriptional control of cellular energy metabolism, oxidative stress defense, mitochondrial function and biogenesis [12]. PGC-1 α directly interacts with various transcriptional regulatory factors such as PPARs, estrogen-related receptors (ERRs), forkhead box O (FOXO) 1, Yin-Yang 1, myocyte-specific enhancer factor 2C (MEF2C) and, most importantly, nuclear respiratory factor (NRF) 1 and 2. This robust activation of nuclear transcriptional factors on the one hand leads to the increased expression of several nuclear-encoded mitochondrial respiratory complex subunits and a number of mitochondrial factors responsible for mitochondrial DNA (mtDNA) replication, transcription and translation, and also for mitochondrial protein import

and assembly. On the other hand, PGC-1 α activation promotes the transformation of glycolytic metabolism towards fatty acid oxidation and gluconeogenesis; furthermore, it triggers adaptive thermogenesis via the induction of uncoupling protein 1 (UCP1) [13].

The contribution of PGC-1 α deficiency to neurodegenerative processes is supported by numerous experimental data [14]. Complementary to these, deficient PGC-1 α axis has been reported in HD [15], PD [16] and AD [17] patients. Additionally to impaired mitochondrial biogenesis, PGC-1 α -deficient neurons exhibit a markedly increased sensitivity against mitochondrial oxidative stress, as PGC-1 α is required for the recruitment of general antioxidant responses [18]. In line with the data linking mitochondrial dysfunction to impaired protein processing, recent *in vitro* studies demonstrated that PGC-1 α deficiency may contribute to α -synuclein accumulation [19] and the formation of toxic A β [17].

PGC-1 α has recently been demonstrated to undergo an alternative 3' splicing between exons 6 and 7 producing an in-frame stop codon at amino acid 268, which results in a shorter but functionally active splice variant of PGC-1 α called N-truncated PGC-1 α (NT-PGC-1 α) [20]. Moreover, both splice variants have been shown to have 3-3 distinct isoforms [21], the exact roles of which, however, have not yet been fully elucidated. In the past years, two independently developed whole-body knockout murine strains of PGC-1 α have been characterized. Surprisingly, however, despite the well-established contribution of PGC-1 α in mitochondrial functions, these knockouts are viable and fertile [22, 23], suggesting the presence of functional compensatory pathways. The first strain generated by Lin et al. represents a complete knockout of PGC-1 α [23], displaying no residual expression of any fragments of the protein (PGC-1 α $-/-$). The parallel developed knockout strain described by Leone et al. [22] lacks the expression of the full-length protein (FL-PGC-1 α $-/-$) but readily expresses a slightly shorter form of NT-PGC-1 α (amino acids 1-254) denoted as NT-PGC-1 α ²⁵⁴, which has very recently been shown to be functionally identical with the complete NT splice variant [21]. Notably, both PGC-1 α knockout strains were reported to display spongiform brain vacuolation predominantly in the caudate-putamen, which first led to the conclusion that PGC-1 α deficiency may model neurodegeneration. However, a number of interesting differences could be observed between the two strains, which include the intact thermoregulation, unimpaired hepatic gluconeogenesis and the adult onset obesity seen in FL-PGC-1 α $-/-$ mice. While the presence of functional NT-PGC-1 α ²⁵⁴ may explain the observed metabolic and thermoregulatory differences between the two knockout strains, the apparent similarity in the gross neuropathological phenotype and the progressive myopathy observed in

FL-PGC-1 α *-/-* mice [22] indicate that the lack of FL-PGC-1 α *per se* results in an irreplaceable loss of some aspects of mitochondrial function.

Based on the concordant data linking mitochondrial dysfunction and PGC-1 α deficiency to the dysregulation of protein processing and handling, in our present study, we performed a systematic neuropathological characterization of adult mice lacking the expression of FL-PGC-1 α , with special focus on the immunohistochemical pattern of neurodegeneration-related proteins.

In addition to the complete lack of pathological protein aggregation, the comprehensive mapping of lesion profiles, comprising spongiform vacuolated lesions and astrogliosis, showed that FL-PGC-1 α *-/-* mice evoke a tissue pathology seen in human mitochondrial encephalopathies, but do not associate with the pathology seen in adult-onset neurodegenerative diseases like HD, PD or AD.

Materials and methods

Animals

FL-PGC-1 α *-/-* mice developed on C57Bl/6J background were generated in Kelly Lab (Sanford-Burnham Institute for Medical Research at Lake Nona, Orlando, FL, USA). The genetic modification of the animals was carried out as previously described by Leone *et al.* [22]. Briefly, the insertion of a neomycin-based gene targeting construct resulted in a 3' homologous recombination and the duplication of exon 3 between exons 5 and 6 of the murine PGC-1 α gene, which created a coding region frameshift and a subsequent premature termination at amino acid 255.

15 FL-PGC-1 α *-/-* (8 male, 7 female) and 16 (8 male, 8 female) age-matched wild-type C57Bl/6J mice were involved in this study. The animals were housed in cages (maximum 4 per cages) in standard conditions with 12-12h light-dark cycle and *ad libitum* access to standard pellet food and water. The experiments were performed in accordance with the European Communities Council Directive (86/609/EEC) and were approved by the local animal care committee. The animals were sacrificed at 30 weeks of age. Brains were removed on ice and halved at the midline immediately following decapitation. Half brains were fixed in 4% paraformaldehyde overnight and kept in 10% glycerol in 4°C until embedding in paraffin.

Neuropathology and immunohistochemistry

4- μ m-thick sagittal sections of paraffin-embedded brain halves were evaluated. We performed the stainings at two levels, one in the level containing the septal nuclei, the medial thalamus and the retroflex fascicle, and one in the level of the caudate-putamen, containing also the substantia nigra. In addition to Hematoxylin and Eosin, Klüver-Barrera (Luxol and Fast red), and Bielschowsky silver stainings, the following monoclonal antibodies (crossreacting with mouse) were used for immunohistochemistry: anti-pTau AT8 (pS202/pT205, 1:200, Pierce Biotechnology, Rockford, IL, USA), anti- α -synuclein (1:10.000, clone 4D6, Signet, Dedham, MA, USA), anti-A β (1:50, clone 6F/3D, Dako, Glostrup, Denmark), anti-amyloid precursor protein (APP) (1:500, Millipore, Billerica, MA, USA) and anti-PrP (6H4, 1:1000, Prionics, Schlieren, Switzerland; epitope 144-152). Furthermore, the following polyclonal antibodies were used: anti-ubiquitin (1:1000, Dako, Glostrup, Denmark), anti-gial fibrillary acidic protein (GFAP) (1:3000, Dako, Glostrup, Denmark) anti-TDP-43 (1:100, ProteinTech Group, Chicago, IL, USA), anti-tau (1:100, Dako; cross-reacts with the tau-equivalent protein in mouse) and anti-FUS (1:1000, Sigma-Aldrich, St. Louis, MO, USA) antibodies. The DAKO EnVision detection kit, peroxidase/DAB, rabbit/mouse (Dako, Glostrup, Denmark) was used for visualization of antibody reactions. When applying mouse antibodies, we used the M.O.M. kit (Vector Laboratories, Burlingame, CA, USA) to prevent the aspecific background staining of endogenous mouse immunoglobulins. As positive controls for the immunostaining, we used tissue sections from human AD (pTau and A β), PD (α -synuclein) and frontotemporal lobar degeneration (FTLD) with TDP-43 or FUS inclusions (TDP-43 and FUS) as well as tissue sections from scrapie-infected mice (PrP, RML strain, Hamilton, MT, USA).

Neuropathological alterations (vacuolation and astrogliosis) were semiquantitatively evaluated in several anatomical regions (table 1). Respecting the fact that vacuole-like alterations may also develop due to histological preparatory processes, vacuoles were scored 0–4 as follows (fig. 1a): 0) No vacuoles or scattered vacuole-like alterations but not more than 1 per visual field at 40x magnification; 1) Scattered vacuole-like alterations but not more than 3 per visual field at 40x magnification; 2) Mildly vacuolated lesion(s) with less than 10 vacuoles per visual field at 40x magnification; 3) Moderately vacuolated lesion(s) with less than 20 vacuoles per visual field at 40x magnification; 4) Severely vacuolated lesion(s) with more than 20 vacuoles per visual field at 40x magnification. Astrogliosis were scored 0-3 as follows (fig. 1b): 0) No astrocytes or scattered resting astrocytes; 1) Cloudy positivity with

no signs of reactivation; 2) Moderate astrogliosis with multiple reactive astrocytes in a patchy distribution; 3) Severe astrogliosis with abundant reactive astrocytes in a confluent pattern.

Statistical analysis

The statistical evaluation of the data was carried out by SPSS Statistics 17.0 software[®]. The cross-tabulation analyses of the discrete variables were performed using Fisher's exact test. In structures large enough to be present in both the paramedian and the lateral sections, we performed a statistical analysis for the estimation of difference within the FL-PGC-1 α -/- animals. A value of $p < 0.05$ was regarded as significant. Structures with statistically significant medio-lateral difference were dealt separately; otherwise, pooled data were used for the comparative analysis of FL-PGC-1 α -/- and wild-type brain structures.

Results

Immunostaining for neurodegeneration-related proteins

Immunostaining for PrP revealed moderate staining of the neuropil, and for α -synuclein we observed immunopositivity in presynaptic structures. Anti-APP and anti-phospho-independent tau antibodies showed cytoplasmic immunoreactivity, while for TDP-43, FUS, and ubiquitin nuclear staining pattern was observed. All of these were the same in wild-type and PGC-1 α -deficient animals. Moreover, there was a complete lack of tangle-like structures, pretangles, glial or astrocytic tau pathology, extracellular plaques (A β or PrP) and TDP-43, FUS, or ubiquitin-immunopositive inclusion bodies (nuclear or cytoplasmic) in all animals and brain regions (fig. 2). The staining intensity was finely and evenly distributed throughout all animals, slices and anatomical regions, indicating the adequate penetration of the fixative in all brains examined.

Lesion profile

Neuropathological changes in the brains of FL-PGC-1 α -/- mice consisted of vacuolation, predominantly in the white matter, and reactive astrogliosis.

Spongiform alterations were present throughout the brain in PGC-1 α -deficient mice. The caudate-putamen was the most severely affected grey matter structure (fig. 3a), followed by the antero-lateral nuclei of the thalamus (reticular and ventral posterolateral area), but consistent mild to moderate alterations could be observed in the pontomedullary brainstem, the tegmental part of the midbrain, the nucleus accumbens, the globus pallidus, the medial

thalamus, the mammillary body, the substantia nigra, the cerebellar nuclei, as well as in the olfactory, insular, motor, sensory, postsubicular and also throughout the paramedian cortices (table 1). However, vacuolation was lacking in the cerebellar cortex, the tectal midbrain and the septal nuclei (not shown). Vacuoles within the cerebral cortex generally predominated in the deep cortical layers; furthermore, analysis of cerebral cortices in the lateral sagittal sections revealed a preference towards the posterior (visual and sensory) versus the anterior (motor, insular and piriform) cortices (Fisher's exact value = 19.184; $p < 0.001$). Spongiform change in the pontomedullary brainstem was more severe in the paramedian than in the lateral sections (Fisher's exact value = 9.282; $p = 0.018$). Notably, the hippocampal grey matter (*i.e.* cornu Ammonis (CA) 1-3 and the dentate gyrus) was relatively preserved, with consistent vacuolation mainly in the white matter bundles of the lacunosum molecular layer of the CA1, as revealed by the Klüver-Barrera staining of the lateral sections (supplementary fig. 1a). Similarly, the Klüver-Barrera staining of the caudate-putamen revealed that, besides being present in the striatal neuropil, the vacuoles within the caudate-putamen were the most abundant in the streaming fibers of the anterior internal capsule (pencil fibers) (supplementary fig. 1b).

In the white matter structures, robust vacuolation was observed in the internal capsule (fig. 3a) and the retroflex fascicle, mild to moderate alterations were noted in the cerebellar white matter, the fimbria hippocampi, the stria terminalis, the anterior commissure and the olfactory tract, while the optic tract remained consistently unaffected. Vacuolation of the myelin, which was arranged in chains in the severely affected white matter regions, was not associated with the damage of axons (fig. 3b). Indeed, there was a lack of APP-immunoreactive (not shown) or argyrophilic axonal swellings (fig. 3b), excluding morphological evidence of a disturbance in axonal transport in association with neuronal damage.

Prominent reactive gliosis was present in the brainstem and within the cerebellar nuclei of FL-PGC-1 α $-/-$ mice. This was the most striking in the paramedian sections of the pontomedullary brainstem (fig. 3c), while moderate astrogliosis was noted in the midbrain, the cerebellar nuclei and the lateral pontomedullary brainstem (supplementary fig. 1c). The median predominance of the involvement of the pontomedullary brainstem was statistically significant (Fisher's exact value = 10.758; $p = 0.004$). No other regions of the brain displayed any signs of astrocytic reactivation. Moreover, we did not observe pathological degree of vascular proliferation in any examined region (data not shown).

Discussion

The involvement of dysfunctional PGC-1 α axis in NDDs has already been demonstrated. The PGC-1 α -dependent thermoregulatory defect in transgenic HD mice and the decreased expression of PGC1-1 α and its target genes in human brain and transgenic mice were the first to suggest contribution in the pathogenesis of HD [24, 25]. Conversely, PGC-1 α overexpression in transgenic HD models displayed neuroprotective effects [24, 25]. Subsequently, a dysfunctional PGC-1 α axis was reported in the skeletal muscle of transgenic mice and HD patients [15], and PGC-1 α gene polymorphisms were associated with the age at onset [26, 27]. In HD, mutant huntingtin protein downregulates PGC-1 α both through a direct interaction with its promoter [24], and through an indirect effect, mediated by an increased extrasynaptic NMDA receptor activity and subsequent deregulation of cyclic AMP response element-binding protein (CREB) signaling [28]. According to a recent finding, the expression of NT-PGC-1 α itself is robustly and consistently altered in human and transgenic HD brains, human HD myoblasts and transgenic striatal cells [29].

Evidence suggests the pathogenic involvement of PGC-1 α in PD as well. Indeed, several PGC-1 α -responsive genes were found underexpressed in PD patients [16], and polymorphisms were also reported to be associated with the age at onset and the risk of developing PD [30]. Moreover, PGC-1 α -deficient mice exhibit an increased sensitivity against 1-methyl-4-phenyl-1,2,3,6-tetrahydropyridine (MPTP) neurotoxicity [18], whereas the overexpression of PGC-1 α protects dopaminergic neurons against rotenone and α -synuclein toxicity *in vitro* [16], and against parkin-deficiency *in vivo* [31]. Ebrahim *et al.* further demonstrated that PGC-1 α deficiency promotes the aggregation of α -synuclein *in vitro* [19].

With regard to AD, Qin *et al.* reported the inverse correlation of hippocampal PGC-1 α protein content with the severity of cognitive decline, neuritic plaque pathology and hippocampal A β_{x-42} burden in AD patients [17]. This group also provided *in vitro* evidence that PGC-1 α deficiency might contribute to the accumulation of AD-type A β in the brain via decreasing the non-amyloidogenic α -secretase activity.

The knockout strain used in our study lacks the expression FL-PGC-1 α , but expresses a slightly shorter though functionally identical form of a NT-PGC-1 α [21]. Indeed, both NT-PGC-1 α and NT-PGC-1 α ²⁵⁴ can readily coactivate PPAR γ and EER α and upregulate UCP1 [21], which clearly underlies the intact thermoregulation and UCP1 levels in FL-PGC-1 α *-/-* mice [21, 22], and may explain the metabolic differences between PGC-1 α *-/-* and FL-PGC-1 α *-/-* strains. However, NT isoforms lack the central and C-terminal domains responsible for

the activation of NRF1, NRF2, MEF2C and FOXO1. The published alterations in mitochondria-related protein expression in FL-PGC-1 α $-/-$ mice (*i.e.* decreased expression of cytochrome *c*, respiratory complex subunits and mitochondrial transcription factor A (TFAM) [22]) are in line with the roles of NRFs in mitochondrial function, and correspond to the observation that NT-PGC-1 α is unable to induce cytochrome *c* expression in PGC-1 α $-/-$ cells [21].

Based on the evidences suggesting that mitochondrial dysfunction and impaired protein processing are interrelated, together with the *in vitro* findings associating PGC-1 α deficiency with protein accumulation [17, 19], we hypothesized that the ablation of FL-PGC-1 α could evoke the accumulation of neurodegeneration-related proteins *in vivo*. This concept seemed feasible since disturbances in protein processing systems and formation of aggregates have already been demonstrated in rodents without a transgenic background for neurodegeneration-associated proteins (*i.e.* neurotoxin models [9-11], aged animals [32]). However, our systematic immunohistochemical analysis revealed no protein depositions; indeed, there was a complete lack of tangle-like structures, extracellular plaques and ubiquitin-immunopositive inclusion bodies throughout the brains, and the pattern of immunoreactivity was similar in FL-PGC-1 α $-/-$ and wild-type animals (fig. 2). These results indicate that despite its widely established contribution in NDDs, the absence of FL-PGC-1 α *per se* has no major influence on protein processing in adult mice. This suggests a more complex scenario for the interaction of mitochondrial dysfunction and protein aggregation in NDDs, and is consistent with the finding that PGC-1 α deficiency is not associated with a gross disturbance of autophagy within the CNS [33]. However, we cannot exclude the supplementary effect of NT-PGC1 α ²⁵⁴ in this context, which question could be answered by studying the PGC-1 α $-/-$ mice in a similar immunohistochemical paradigm.

Mitochondrial malfunction is the primary etiological factor in a group of sporadic or inherited CNS diseases, collectively termed mitochondrial encephalopathies. The underlying genetic alterations can affect either the mtDNA or nDNA. Although the distribution of the neuropathological alterations is characteristic to a particular syndrome, mitochondrial encephalopathies show various degrees of spongiform vacuolation (in particular regions with preserved neurons giving the characteristic appearance of “pseudonecrosis”), reactive astrogliosis and, less generally, pathological capillary proliferation (table 2).

The continuous attempts to create animal models for such diseases have been facing difficulties. Indeed, most of the developed genetic modifications result in embryonic or early

postnatal lethality (*e.g.* knockouts of CREB [34], ERR γ [35], NRF1 [36], NRF2 [37], TFAM [38], mtDNA polymerase γ 1 (POLG1) [39], optic atrophy 1 (OPA1) [40] and synthesis of cytochrome *c* oxidase 2 (SCO2) [41]), whereas a great proportion of viable strains, surprisingly, exhibit no neuropathology (*e.g.* knockouts of adenine nucleotide translocator 1 (ANT1) [42], PPAR γ [43], ERR α [44] and SURF1 [45]; Twinkle mutant ‘Deletor’ mice [46] and Δ mtDNA Mito-Mice [47]). To our knowledge, murine knockouts of apoptosis inducing factor (AIF) [48, 49], superoxide dismutase 2 (SOD2) [50], thymidine phosphorylase and uridine phosphorylase (TP/UP) [51] and NADH dehydrogenase [ubiquinone] iron-sulfur protein 4 (NDUFS4) [52] are the only ones that display a neuropathology resembling that of human mitochondrial encephalopathies (table 2).

In the present study, we characterized the lesion profile of 30-week old FL-PGC-1 α *-/-* mice, which age has not been previously characterized neurohistologically in PGC-1 α -deficient mice. The neuropathological findings consisted of widespread spongiform vacuolation and circumscribed astrogliosis, whereas vascular proliferation was absent. The most striking spongiform alterations were observed in the long white matter bundles of the internal capsule and the retroflex fascicle. The most severely affected grey matter regions included the thalamus and the caudate-putamen; however, myelin staining revealed the massive involvement of the pencil fibers streaming across the caudate-putamen, indicating that the abundant vacuolation in this region is at least in part attributable to myelin degeneration. The whole forebrain was free of gliosis, which contrasted with the robust and confluent astrogliotic reaction in the central pontomedullary brainstem, and the patchy reactions in the midbrain and the cerebellar nuclei. Collectively, this pattern is highly reminiscent of human mitochondrial spongiform encephalopathies, particularly of KSS and, in some aspects, LS (table 2). This impression was further supported by the ovoid shape and unidirectional longitudinal axes of the vacuoles in the white matter, the deep occipito-parietal preference of the cortical vacuoles, the median predominance of brainstem involvement, along with the preservation of axons in the vacuolated fibers as revealed by the lack of APP-immunopositive and argyrophilic axonal swellings. The sparing of axons contrasts the concept proposed by Lin *et al.* during the characterization of the PGC-1 α *-/-* strain, suggesting that the spongiform lesions in the caudate-putamen might arise from axonal degeneration [23]. This concept was partially confirmed by a later work of this group, demonstrating that neuron-specific knockouts of PGC-1 α also exhibit striatal and cortical vacuolation; however, with apparently less severity than the whole-body knockouts [33]. Our observations allow us to presume that spongy vacuolation in the FL-PGC-1 α *-/-* model may primarily share the

etiology of the status spongiosus seen in mitochondrial encephalopathies, in which myelin vacuoles are proposed to be attributable to mitochondrial dysfunction in oligodendrocytes, whereas grey matter vacuoles are presumed to develop due to the failure of ATP-dependent ion transporters in astrocytic membranes [53].

In their comprehensive study characterizing the PGC-1 α *-/-* strain, Lin *et al.* reported the presence of GFAP-immunopositive astrocytes in the vicinity of the vacuoles within the caudate-putamen, which has frequently been interpreted as a direct indicative of striatal neurodegeneration, turning the attention to the contribution of PGC-1 α to NDDs, especially to HD. It must be noted, however, that no reports have yet provided direct evidence of neuronal loss in PGC-1 α -deficient mice. In the strain examined in this study, the region of the caudate-putamen indeed displayed some slight GFAP positivity, suggestive of resident astroglia in the striatal white matter. However, the pattern of immunoreactivity and the appearance of astrocytes did not differ between FL-PGC-1 α *-/-* and wild-type animals. This pattern contrasts the massive reactive (*i.e.* hypertrophic and hyperplastic) astrogliosis in the brainstem and cerebellar nuclei of PGC-1 α -deficient mice used in our study.

Our finding that the neuroanatomical pattern of the lesions in this model overlaps with multiple human mitochondrial encephalopathies is not that surprising, considering that FL-PGC-1 α contributes to the proper functioning of several downstream proteins which practically cover all levels of mitochondrial functioning that have been associated with mitochondrial diseases [2]. More surprisingly, PGC-1 α -deficient mice are not only free of embryonic lethality, but they have normal longevity and acceptable reproduction [22, 23], suggesting the existence of potent complementary pathways, probably within the PGC family itself. It is possible that the presence of intact PGC-1 β and PGC-1-related coactivator (PRC) is sufficient to maintain an acceptable level of mitochondrial function, as both possess functional domains capable of interacting with nuclear hormone receptors and NRFs [54, 55]. This may at least in part explain the apparent discrepancy between the suggested roles of PGC-1 α in mitochondrial physiology and the observed viable phenotypes of the knockouts. Indeed, the directly upstream CREB, and a number of downstream factors (ERR γ , NRF1, NRF2, TFAM and POLG1) were found indispensable for embryonic or early postnatal development. On the other hand, the murine knockouts of the directly coactivated PPAR γ and the PGC-1 α -dependent ANT1 are viable, but display no neuropathological alterations. The most closely reminiscent brain pathology of that observed in this study was reported in the murine knockout of SOD2 (also downstream of PGC-1 α), indicating that oxidative damage may play an important role in the development of the spongiform leukoencephalopathy.

Although the lifespan of the SOD2 null model can be somewhat increased by antioxidant protection, these animals die within the first 3–4 weeks [50]. We suggest that PGC-1 α -deficient mice with their normal lifespan and measurable neurological symptoms may represent a useful animal model to investigate the therapeutic potential of candidates in halting the progression of mitochondrial diseases. Our findings also suggest that polymorphisms in the PGC-1 α gene might be valuable targets of investigation in mitochondrial diseases with unidentified genetic origin, and correspond to the notion that the activation of PGC-1 α axis may be of therapeutic benefit in mitochondrial diseases [56, 57].

We conclude that mitochondrial dysfunction due to the lack of FL-PGC-1 α *per se* is unable to recapitulate major features of NDDs with regard to impaired protein processing and the anatomical pattern of reactive astrogliosis in adult mice. Specifying the nature and distribution of the neuropathological alterations in FL-PGC-1 α *-/-* mice, we propose that those are reminiscent of human mitochondrial encephalopathies, which makes PGC-1 α -deficient mice an appropriate and viable animal model for this, yet incurable, group of diseases.

Acknowledgements

We are grateful for the excellent technical work of Ms. Irene Leisser. This work was supported by OTKA (K 75628) and TÁMOP-4.2.1/B-09-1/KONV-2010-0005 – Creating the Centre of Excellence at the University of Szeged.

Conflicts of interest

The authors report no conflicts of interest.

References

- 1 Beal MF: Mitochondria take center stage in aging and neurodegeneration. *Ann Neurol* 2005;58:495-505.
- 2 Finsterer J, Harbo HF, Baets J, Van Broeckhoven C, Di Donato S, Fontaine B, De Jonghe P, Lossos A, Lynch T, Mariotti C, Schols L, Spinazzola A, Szolnoki Z, Tabrizi SJ, Tallaksen CM, Zeviani M, Burgunder JM, Gasser T: EFNS guidelines on the molecular diagnosis of mitochondrial disorders. *Eur J Neurol* 2009;16:1255-1264.
- 3 Kovacs GG, Botond G, Budka H: Protein coding of neurodegenerative dementias: the neuropathological basis of biomarker diagnostics. *Acta Neuropathol* 2010;119:389-408.
- 4 Rubinsztein DC: The roles of intracellular protein-degradation pathways in neurodegeneration. *Nature* 2006;443:780-786.
- 5 Cappelletti G, Surrey T, Maci R: The parkinsonism producing neurotoxin MPP+ affects microtubule dynamics by acting as a destabilising factor. *FEBS Lett* 2005;579:4781-4786.
- 6 Ren Y, Liu W, Jiang H, Jiang Q, Feng J: Selective vulnerability of dopaminergic neurons to microtubule depolymerization. *J Biol Chem* 2005;280:34105-34112.
- 7 Hoglinger GU, Carrard G, Michel PP, Medja F, Lombes A, Ruberg M, Friguet B, Hirsch EC: Dysfunction of mitochondrial complex I and the proteasome: interactions between two biochemical deficits in a cellular model of Parkinson's disease. *J Neurochem* 2003;86:1297-1307.
- 8 Kowall NW, Hantraye P, Brouillet E, Beal MF, McKee AC, Ferrante RJ: MPTP induces alpha-synuclein aggregation in the substantia nigra of baboons. *Neuroreport* 2000;11:211-213.
- 9 Gibrat C, Saint-Pierre M, Bousquet M, Levesque D, Rouillard C, Cicchetti F: Differences between subacute and chronic MPTP mice models: investigation of dopaminergic neuronal degeneration and alpha-synuclein inclusions. *J Neurochem* 2009;109:1469-1482.
- 10 Betarbet R, Sherer TB, MacKenzie G, Garcia-Osuna M, Panov AV, Greenamyre JT: Chronic systemic pesticide exposure reproduces features of Parkinson's disease. *Nat Neurosci* 2000;3:1301-1306.
- 11 Sherer TB, Kim JH, Betarbet R, Greenamyre JT: Subcutaneous rotenone exposure causes highly selective dopaminergic degeneration and alpha-synuclein aggregation. *Exp Neurol* 2003;179:9-16.
- 12 Liang H, Ward WF: PGC-1alpha: a key regulator of energy metabolism. *Adv Physiol Educ* 2006;30:145-151.
- 13 Scarpulla RC: Transcriptional paradigms in mammalian mitochondrial biogenesis and function. *Physiol Rev* 2008;88:611-638.
- 14 Rona-Voros K, Weydt P: The role of PGC-1alpha in the pathogenesis of neurodegenerative disorders. *Curr Drug Targets* 2010;11:1262-1269.
- 15 Chaturvedi RK, Adihetty P, Shukla S, Hennessy T, Calingasan N, Yang L, Starkov A, Kiaei M, Cannella M, Sassone J, Ciammola A, Squitieri F, Beal MF: Impaired PGC-1alpha function in muscle in Huntington's disease. *Hum Mol Genet* 2009;18:3048-3065.
- 16 Zheng B, Liao Z, Locascio JJ, Lesniak KA, Roderick SS, Watt ML, Eklund AC, Zhang-James Y, Kim PD, Hauser MA, Grunblatt E, Moran LB, Mandel SA, Riederer P, Miller RM, Federoff HJ, Wullner U, Papapetropoulos S, Youdim MB, Cantuti-Castelvetri I, Young AB, Vance JM, Davis RL, Hedreen JC, Adler CH, Beach TG, Graeber MB, Middleton FA, Rochet JC, Scherzer CR: PGC-1alpha, a potential

- therapeutic target for early intervention in Parkinson's disease. *Sci Transl Med* 2010;2:52ra73.
- 17 Qin W, Haroutunian V, Katsel P, Cardozo CP, Ho L, Buxbaum JD, Pasinetti GM: PGC-1alpha expression decreases in the Alzheimer disease brain as a function of dementia. *Arch Neurol* 2009;66:352-361.
 - 18 St-Pierre J, Drori S, Uldry M, Silvaggi JM, Rhee J, Jager S, Handschin C, Zheng K, Lin J, Yang W, Simon DK, Bachoo R, Spiegelman BM: Suppression of reactive oxygen species and neurodegeneration by the PGC-1 transcriptional coactivators. *Cell* 2006;127:397-408.
 - 19 Ebrahim AS, Ko LW, Yen SH: Reduced expression of peroxisome-proliferator activated receptor gamma coactivator-1alpha enhances alpha-synuclein oligomerization and down regulates AKT/GSK3beta signaling pathway in human neuronal cells that inducibly express alpha-synuclein. *Neurosci Lett* 2010;473:120-125.
 - 20 Zhang Y, Huypens P, Adamson AW, Chang JS, Henagan TM, Boudreau A, Lenard NR, Burk D, Klein J, Perwitz N, Shin J, Fasshauer M, Kralli A, Gettys TW: Alternative mRNA splicing produces a novel biologically active short isoform of PGC-1alpha. *J Biol Chem* 2009;284:32813-32826.
 - 21 Chang JS, Fernand V, Zhang Y, Shin J, Jun HJ, Joshi Y, Gettys TW: NT-PGC-1alpha Protein Is Sufficient to Link beta3-Adrenergic Receptor Activation to Transcriptional and Physiological Components of Adaptive Thermogenesis. *J Biol Chem* 2012;287:9100-9111.
 - 22 Leone TC, Lehman JJ, Finck BN, Schaeffer PJ, Wende AR, Boudina S, Courtois M, Wozniak DF, Sambandam N, Bernal-Mizrachi C, Chen Z, Holloszy JO, Medeiros DM, Schmidt RE, Saffitz JE, Abel ED, Semenkovich CF, Kelly DP: PGC-1alpha deficiency causes multi-system energy metabolic derangements: muscle dysfunction, abnormal weight control and hepatic steatosis. *PLoS Biol* 2005;3:e101.
 - 23 Lin J, Wu PH, Tarr PT, Lindenberg KS, St-Pierre J, Zhang CY, Mootha VK, Jager S, Vianna CR, Reznick RM, Cui L, Manieri M, Donovan MX, Wu Z, Cooper MP, Fan MC, Rohas LM, Zavacki AM, Cinti S, Shulman GI, Lowell BB, Krainc D, Spiegelman BM: Defects in adaptive energy metabolism with CNS-linked hyperactivity in PGC-1alpha null mice. *Cell* 2004;119:121-135.
 - 24 Cui L, Jeong H, Borovecki F, Parkhurst CN, Tanese N, Krainc D: Transcriptional repression of PGC-1alpha by mutant huntingtin leads to mitochondrial dysfunction and neurodegeneration. *Cell* 2006;127:59-69.
 - 25 Weydt P, Pineda VV, Torrence AE, Libby RT, Satterfield TF, Lazarowski ER, Gilbert ML, Morton GJ, Bammler TK, Strand AD, Cui L, Beyer RP, Easley CN, Smith AC, Krainc D, Luquet S, Sweet IR, Schwartz MW, La Spada AR: Thermoregulatory and metabolic defects in Huntington's disease transgenic mice implicate PGC-1alpha in Huntington's disease neurodegeneration. *Cell Metab* 2006;4:349-362.
 - 26 Weydt P, Soyal SM, Gellera C, Didonato S, Weidinger C, Oberkofler H, Landwehrmeyer GB, Patsch W: The gene coding for PGC-1alpha modifies age at onset in Huntington's Disease. *Mol Neurodegener* 2009;4:3.
 - 27 Taherzadeh-Fard E, Saft C, Andrich J, Wiczorek S, Arning L: PGC-1alpha as modifier of onset age in Huntington disease. *Mol Neurodegener* 2009;4:10.
 - 28 Okamoto S, Pouladi MA, Talantova M, Yao D, Xia P, Ehrnhoefer DE, Zaidi R, Clemente A, Kaul M, Graham RK, Zhang D, Vincent Chen HS, Tong G, Hayden MR, Lipton SA: Balance between synaptic versus extrasynaptic NMDA receptor activity influences inclusions and neurotoxicity of mutant huntingtin. *Nat Med* 2009;15:1407-1413.

- 29 Johri A, Starkov AA, Chandra A, Hennessey T, Sharma A, Orobello S, Squitieri F, Yang L, Beal MF: Truncated peroxisome proliferator-activated receptor-gamma coactivator 1alpha splice variant is severely altered in Huntington's disease. *Neurodegener Dis* 2011;8:496-503.
- 30 Clark J, Reddy S, Zheng K, Betensky RA, Simon DK: Association of PGC-1alpha polymorphisms with age of onset and risk of Parkinson's disease. *BMC Med Genet* 2011;12:69.
- 31 Shin JH, Ko HS, Kang H, Lee Y, Lee YI, Pletinkova O, Troconso JC, Dawson VL, Dawson TM: PARIS (ZNF746) repression of PGC-1alpha contributes to neurodegeneration in Parkinson's disease. *Cell* 2011;144:689-702.
- 32 Soontornniyomkij V, Risbrough VB, Young JW, Soontornniyomkij B, Jeste DV, Achim CL: Increased hippocampal accumulation of autophagosomes predicts short-term recognition memory impairment in aged mice. *Age (Dordr)* 2012;34:305-316.
- 33 Ma D, Li S, Lucas EK, Cowell RM, Lin JD: Neuronal inactivation of peroxisome proliferator-activated receptor gamma coactivator 1alpha (PGC-1alpha) protects mice from diet-induced obesity and leads to degenerative lesions. *J Biol Chem* 2010;285:39087-39095.
- 34 Rudolph D, Tafuri A, Gass P, Hammerling GJ, Arnold B, Schutz G: Impaired fetal T cell development and perinatal lethality in mice lacking the cAMP response element binding protein. *Proc Natl Acad Sci U S A* 1998;95:4481-4486.
- 35 Alaynick WA, Kondo RP, Xie W, He W, Dufour CR, Downes M, Jonker JW, Giles W, Naviaux RK, Giguere V, Evans RM: ERRgamma directs and maintains the transition to oxidative metabolism in the postnatal heart. *Cell Metab* 2007;6:13-24.
- 36 Huo L, Scarpulla RC: Mitochondrial DNA instability and peri-implantation lethality associated with targeted disruption of nuclear respiratory factor 1 in mice. *Mol Cell Biol* 2001;21:644-654.
- 37 Ristevski S, O'Leary DA, Thornell AP, Owen MJ, Kola I, Hertzog PJ: The ETS transcription factor GABPalpha is essential for early embryogenesis. *Mol Cell Biol* 2004;24:5844-5849.
- 38 Larsson NG, Wang J, Wilhelmsson H, Oldfors A, Rustin P, Lewandoski M, Barsh GS, Clayton DA: Mitochondrial transcription factor A is necessary for mtDNA maintenance and embryogenesis in mice. *Nat Genet* 1998;18:231-236.
- 39 Hance N, Ekstrand MI, Trifunovic A: Mitochondrial DNA polymerase gamma is essential for mammalian embryogenesis. *Hum Mol Genet* 2005;14:1775-1783.
- 40 Davies VJ, Hollins AJ, Piechota MJ, Yip W, Davies JR, White KE, Nicols PP, Boulton ME, Votruba M: Opa1 deficiency in a mouse model of autosomal dominant optic atrophy impairs mitochondrial morphology, optic nerve structure and visual function. *Hum Mol Genet* 2007;16:1307-1318.
- 41 Yang H, Brosel S, Acin-Perez R, Slavkovich V, Nishino I, Khan R, Goldberg IJ, Graziano J, Manfredi G, Schon EA: Analysis of mouse models of cytochrome c oxidase deficiency owing to mutations in Sco2. *Hum Mol Genet* 2010;19:170-180.
- 42 Lee J, Schriener SE, Wallace DC: Adenine nucleotide translocator 1 deficiency increases resistance of mouse brain and neurons to excitotoxic insults. *Biochim Biophys Acta* 2009;1787:364-370.
- 43 Zhao X, Strong R, Zhang J, Sun G, Tsien JZ, Cui Z, Grotta JC, Aronowski J: Neuronal PPARgamma deficiency increases susceptibility to brain damage after cerebral ischemia. *J Neurosci* 2009;29:6186-6195.
- 44 Luo J, Sladek R, Carrier J, Bader JA, Richard D, Giguere V: Reduced fat mass in mice lacking orphan nuclear receptor estrogen-related receptor alpha. *Mol Cell Biol* 2003;23:7947-7956.

- 45 Dell'agnello C, Leo S, Agostino A, Szabadkai G, Tiveron C, Zulian A, Prella A, Roubertoux P, Rizzuto R, Zeviani M: Increased longevity and refractoriness to Ca(2+)-dependent neurodegeneration in Surf1 knockout mice. *Hum Mol Genet* 2007;16:431-444.
- 46 Tyynismaa H, Mjosund KP, Wanrooij S, Lappalainen I, Ylikallio E, Jalanko A, Spelbrink JN, Paetau A, Suomalainen A: Mutant mitochondrial helicase Twinkle causes multiple mtDNA deletions and a late-onset mitochondrial disease in mice. *Proc Natl Acad Sci U S A* 2005;102:17687-17692.
- 47 Tanaka D, Nakada K, Takao K, Ogasawara E, Kasahara A, Sato A, Yonekawa H, Miyakawa T, Hayashi J: Normal mitochondrial respiratory function is essential for spatial remote memory in mice. *Mol Brain* 2008;1:21.
- 48 El Ghouzzi V, Csaba Z, Olivier P, Lelouvier B, Schwendimann L, Dournaud P, Verney C, Rustin P, Gressens P: Apoptosis-inducing factor deficiency induces early mitochondrial degeneration in brain followed by progressive multifocal neuropathology. *J Neuropathol Exp Neurol* 2007;66:838-847.
- 49 Bouaita A, Augustin S, Lechauve C, Cwerman-Thibault H, Benit P, Simonutti M, Paques M, Rustin P, Sahel JA, Corral-Debrinski M: Downregulation of apoptosis-inducing factor in Harlequin mice induces progressive and severe optic atrophy which is durably prevented by AAV2-AIF1 gene therapy. *Brain* 2011;135:35-52.
- 50 Melov S, Schneider JA, Day BJ, Hinerfeld D, Coskun P, Mirra SS, Crapo JD, Wallace DC: A novel neurological phenotype in mice lacking mitochondrial manganese superoxide dismutase. *Nat Genet* 1998;18:159-163.
- 51 Lopez LC, Akman HO, Garcia-Cazorla A, Dorado B, Marti R, Nishino I, Tadesse S, Pizzorno G, Shungu D, Bonilla E, Tanji K, Hirano M: Unbalanced deoxynucleotide pools cause mitochondrial DNA instability in thymidine phosphorylase-deficient mice. *Hum Mol Genet* 2009;18:714-722.
- 52 Quintana A, Kruse SE, Kapur RP, Sanz E, Palmiter RD: Complex I deficiency due to loss of Ndufs4 in the brain results in progressive encephalopathy resembling Leigh syndrome. *Proc Natl Acad Sci U S A* 2010;107:10996-11001.
- 53 Oldfors A, Fyhr IM, Holme E, Larsson NG, Tulinius M: Neuropathology in Kearns-Sayre syndrome. *Acta Neuropathol* 1990;80:541-546.
- 54 Lin J, Puigserver P, Donovan J, Tarr P, Spiegelman BM: Peroxisome proliferator-activated receptor gamma coactivator 1beta (PGC-1beta), a novel PGC-1-related transcription coactivator associated with host cell factor. *J Biol Chem* 2002;277:1645-1648.
- 55 Andersson U, Scarpulla RC: Pgc-1-related coactivator, a novel, serum-inducible coactivator of nuclear respiratory factor 1-dependent transcription in mammalian cells. *Mol Cell Biol* 2001;21:3738-3749.
- 56 Srivastava S, Diaz F, Iommarini L, Aure K, Lombes A, Moraes CT: PGC-1alpha/beta induced expression partially compensates for respiratory chain defects in cells from patients with mitochondrial disorders. *Hum Mol Genet* 2009;18:1805-1812.
- 57 Wenz T: PGC-1alpha activation as a therapeutic approach in mitochondrial disease. *IUBMB Life* 2009;61:1051-1062.
- 58 Brown GK, Squier MV: Neuropathology and pathogenesis of mitochondrial diseases. *J Inherit Metab Dis* 1996;19:553-572.
- 59 Tanji K, Kunimatsu T, Vu TH, Bonilla E: Neuropathological features of mitochondrial disorders. *Semin Cell Dev Biol* 2001;12:429-439.
- 60 Betts J, Lightowers RN, Turnbull DM: Neuropathological aspects of mitochondrial DNA disease. *Neurochem Res* 2004;29:505-511.

- 61 Filosto M, Tomelleri G, Tonin P, Scarpelli M, Vattei G, Rizzuto N, Padovani A, Simonati A: Neuropathology of mitochondrial diseases. *Biosci Rep* 2007;27:23-30.

Table 1. Lesion profile in the brains of FL-PGC-1 α -/- mice.

Comprehensive mapping of lesion profile in FL-PGC-1 α -/- animals, demonstrating the typical degree of involvement of an anatomical region in the spongiform vacuolation and reactive astrogliosis. The differences between FL-PGC-1 α -/- and wild-type animals are represented by the means and the corresponding *p* values in the respective anatomical regions.

Typical degree of vacuolation	Region	Mean	<i>p</i> -value
Mild	cerebellar white matter	1.833	< 0.001
	pontomedullary brainstem ^l *	1.923	0.005
	substantia nigra	1.375	0.004
	hippocampus ^m	1.133	0.006
	hippocampus ^l	1.933	< 0.001
	fimbria hippocampi	1.182	0.007
Moderate	cerebellar nuclei *	2.150	< 0.001
	pontomedullary brainstem ^m **	2.933	< 0.001
	midbrain *	2.571	< 0.001
	nucleus accumbens	2.600	< 0.001
	globus pallidus	2.692	< 0.001
	mammillary body	2.143	< 0.001
	cerebral cortex	2.305	< 0.001
	thalamus ^m	2.067	< 0.001
	anterior commissure	2.533	< 0.001
	stria terminalis	2.786	< 0.001
olfactory tract	2.071	< 0.001	
Severe	caudate-putamen	4.000	< 0.001
	thalamus ^l	3.533	< 0.001
	internal capsule	3.615	< 0.001
	retroflex fascicle	4.000	< 0.001

^l lateral section

^m paramedian section

* accompanied by moderate astrogliotic reaction

** accompanied by severe astrogliotic reaction.

Table 2. Comparative summary of the typical neuropathological findings and their distribution in human mitochondrial spongiform encephalopathies and their most reminiscent murine models.

Abbreviations: AIF, apoptosis inducing factor; FL-PGC-1 α $-/-$, knockout for the full-length peroxisome proliferator activator receptor gamma coactivator-1alpha protein; KSS, Kearns-Sayre syndrome; LHON, Leber's hereditary optic neuropathy; LS, Leigh syndrome; MELAS, mitochondrial encephalomyopathy, lactic acidosis and stroke-like episodes; MERRF, myoclonic epilepsy with ragged-red fibers; NDUSF4, NADH dehydrogenase [ubiquinone] iron-sulfur protein 4; SOD2, superoxide dismutase 2; TP/UP, thymidine phosphorylase and uridine phosphorylase; WM, white matter; +, present; -, absent.

Disease	Vacuolation	Anatomical predominance of vacuolation	Astrogliosis	Anatomical predominance of astrogliosis	Characteristic vascular proliferation	References
Human disorders						
<i>KSS</i>	+	cerebral WM thalamus basal ganglia brainstem cerebellum	+	brainstem cerebellum	-	
<i>LS</i>	+	thalamus basal ganglia brainstem cerebellar nuclei	+	thalamus basal ganglia brainstem cerebellar nuclei	+	
<i>MELAS</i>	+	cerebrum cerebellum	+	cerebrum thalamus basal ganglia brainstem cerebellum	+	[58-61]
<i>MERRF</i>	+	cerebrum brainstem	+	basal ganglia brainstem cerebellar cortex cerebellar nuclei	-	
<i>LHON</i>	+	optic nerve	+	optic nerve retinal ganglia	-	
Experimental models						
<i>FL-PGC-1α</i> <i>-/- mice</i>	+	cerebrum thalamus basal ganglia brainstem cerebellar nuclei	+	brainstem cerebellar nuclei	-	
<i>Ndufs4</i> <i>-/- mice</i>	+	brainstem cerebellar nuclei	+	brainstem cerebellar nuclei	+	[52]
<i>TP/UP double</i> <i>-/- mice</i>	+	cerebral WM thalamus basal ganglia cerebellar WM cerebellar nuclei	No data available		-	[51]
<i>SOD-2</i> <i>-/- mice</i>	+	cerebral cortex brainstem	+	cerebral cortex brainstem	-	[50]
<i>AIF</i> <i>-/- (Harlequin)</i> <i>mice</i>	-		+	thalamus basal ganglia cerebellar nuclei retinal ganglia optic tract	+	[48, 49]

Fig. 1. Representative images corresponding to the semiquantitative scores used to evaluate vacuolation (a) and astrogliosis (b).

Bar in a represents 20 μm .

Abbreviations: H&E, Hematoxylin and Eosin; GFAP, glial fibrillary acidic protein.

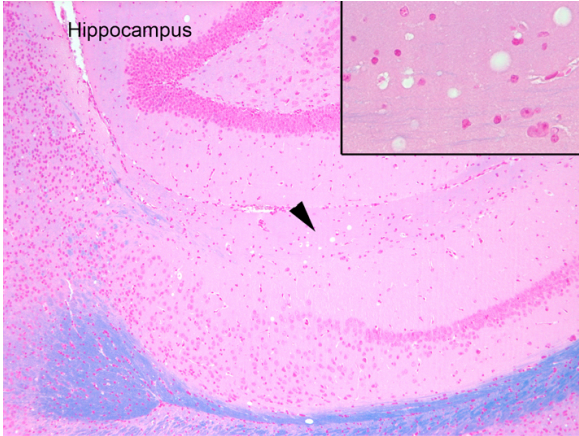


Fig.1A. Klüver-Barrera staining (original magnification x100) showing vacuolation in the stratum lacunosum (arrowhead points to the area enlarged in the inset; x400).

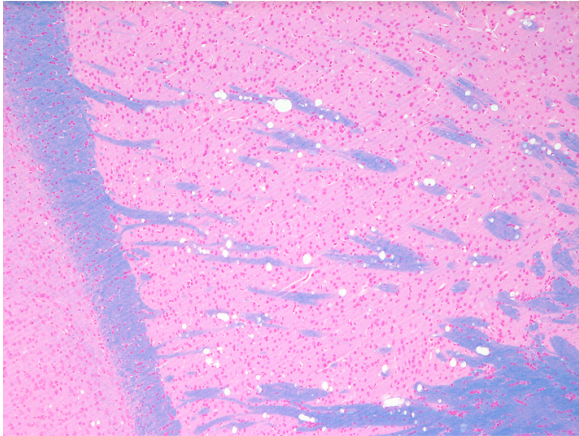


Fig.1B. Vacuolation in the pencil fibers in the striatum (original magnification x100).

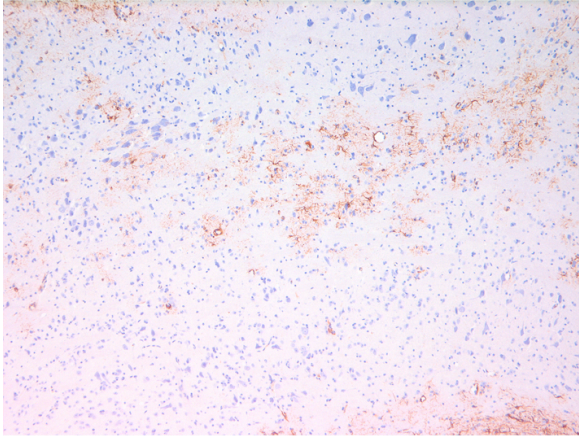


Fig.1C. Moderate gliosis in the lateral section of the pontomedullary brainstem (original magnification x100).

Fig. 2. The absence of FL-PGC-1 α expression is not associated with the accumulation of neurodegeneration-related proteins in adult mice.

Immunostaining for prion protein (PrP), α -synuclein (a-Syn), amyloid precursor protein (APP), amyloid-beta (A-beta), Tau, phosphorylated Tau (pTau), TDP-43, FUS, and ubiquitin (Ubi) in various anatomical regions in wild-type (WT) and FL-PGC-1 α $-/-$ (PGC-1 α) animals. The representative images demonstrate lack of pathological protein aggregation and inclusion body formation throughout the brain of mature FL-PGC-1 α $-/-$ mice.

Bar represents 50 μ m for the images of PrP, a-Syn, A-beta, and ubiquitin; 20 μ m for APP; and 7.5 μ m for Tau, pTau, TDP-43, and FUS.

Fig. 3. Lesion profile in the brains of FL-PGC-1 α $-/-$ mice is reminiscent of human mitochondrial encephalopathies.

(a) Hematoxylin and Eosin (H&E) staining in different anatomical regions in wild-type (WT) and FL-PGC-1 α $-/-$ (PGC-1 α) animals, demonstrating prominent vacuolation in the caudate-putamen and the internal capsule in PGC-1 α -deficient animals. (b) Vacuolation in the myelin (as shown by Klüver-Barrera staining on the left) exhibits chain-like appearance (as exemplified by the lower image of the retroflex fascicle) and is associated with relatively preserved axons, pushed towards the edge of the vacuoles (as shown by Bielschowsky silver staining on the right). (c) Immunostaining for glial fibrillary acidic protein (GFAP) in different anatomical regions in wild-type (WT) and FL-PGC-1 α $-/-$ animals, showing reactive astrogliosis in the brainstem regions. Bar in A represents 75 μ m for the images of the caudate-putamen and internal capsule in a and c; 125 μ m for the brainstem in c; and 10 and 5 μ m for b upper and lower panel, respectively.