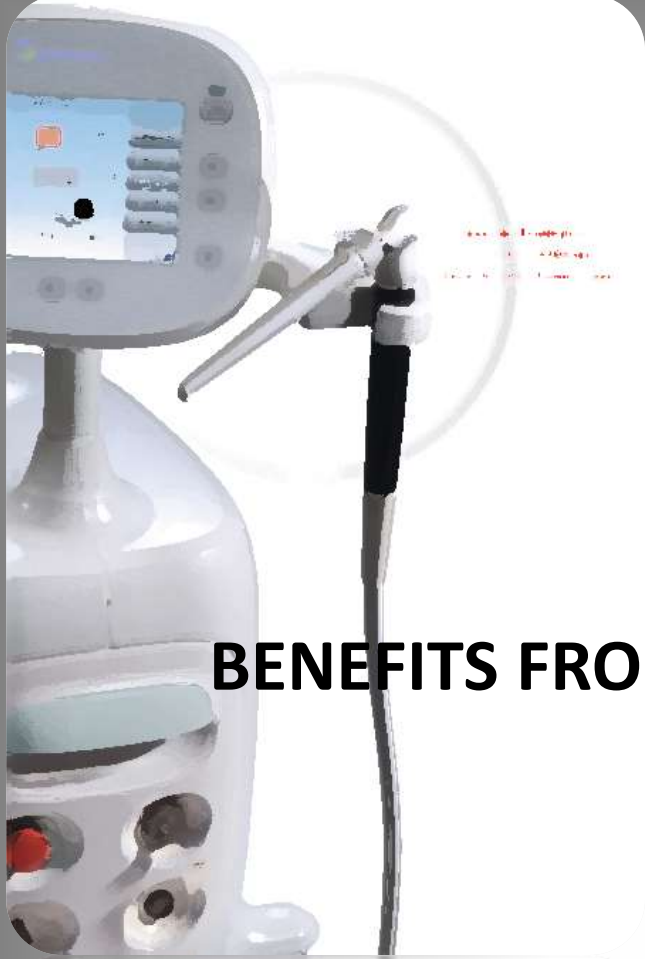




BENEFITS FROM Er:YAG LASER THERAPY IN DAILY DENTAL PRACTICE

Ana Minovska, Daniela Cvetanovska Stojcheva,
Ana Bundalevska
ETERNA dent, Skopje
Plovdiv, 2015





Modification of tooth neck dentin with a diode laser for desensitisation

case report
Laser assisted crown lengthening in the anterior maxilla

industry report
The TwinLight® approach to periimplantitis



2013 International Symposium for Advanced Biomaterials and Tissue Engineering

Date December 27th (Fri) ~ 28th (Sat), 2013 **Venue** School of Dentistry, Chonnam National University - Gwangju Rimoda Plaza Hotel
11 | R&D Foundation for Advanced Biomaterials, KJ-IP | Gwangju Technopark





Er:YAG LASER – THE FUTURE OF DENTISTRY

- Working with light energy in dentistry is still our choice. In future it will be a must – the patients demand rises.
- Dental laser applicable in so many dental procedures is a new level of GP dentistry;
 - Are we “better” general practitioners???
 - Do the cases look differently done by the Er-YAG LiteTouch™???

To know how to work with the Er:YAG laser is important to get informed about:

1. Physics of laser light
2. Laser – tissue interaction – THE MOVEMENT WITH OUR HAND!
3. Laser device
4. Clinical application of Er:YAG laser in dentistry
5. Clinical cases



POSSIBLE BENEFITS FROM Er:YAG LASER

- **Wider indication field for a GENERAL PRACTITIONER**
- Better success predictability
- Better overall time management etc.

We have chosen the following indications coming into the daily practice:

1. **Fractured teeth**, (*Ellis class VIII fractured crown en masse and it`s replacement*)
2. **Patients with “gummy smile”**,
3. **Patients with moderate chronic periodontitis**,
4. **Patients with aggressive periodontitis**,
5. **Localized traumatic occlusion associated attachment loss**

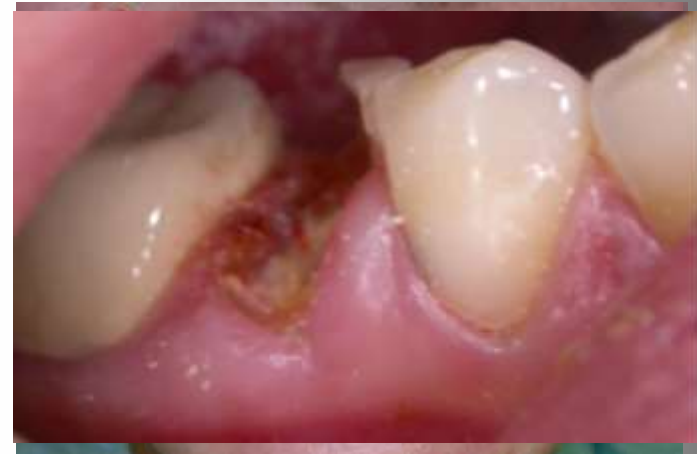

POSSIBLE BENEFITS FROM Er:YAG LASER

1. *Prosthetic reconstructions on fractured teeth, (Ellis class VIII crown en masse and it`s replacement)*
2. *Patients with “gummy smile”,*
3. *Patients with moderate chronic periodontitis,*
4. *Patients with advanced/aggressive periodontitis,*
5. *Localized traumatic occlusion associated attachment loss*

THERAPEUTIC OPTIONS:

1. Extraction + implant **vs.** crown lengthening + crown
2. Prosthetics **vs.** gummy smile correction + prosthetics
3. Conventional **vs.** Er:YAG laser treatment
4. Extraction **vs.** conventional vs. Er:YAG laser treatment
5. Grafting **vs.** Er:YAG laser treatment

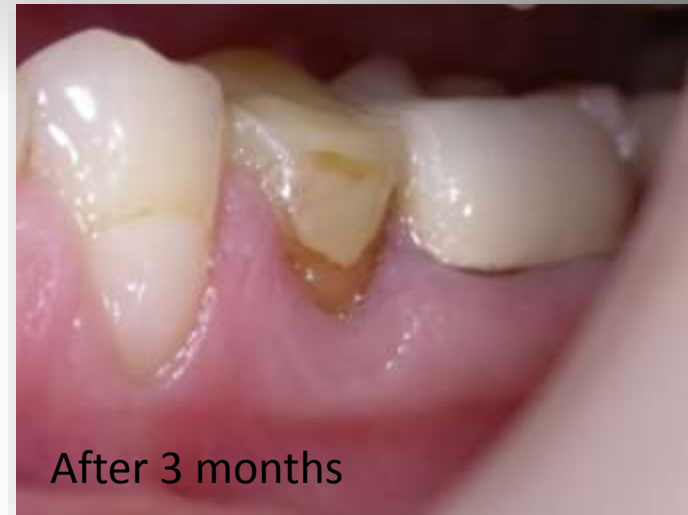

Prosthetic reconstructions on fractured teeth

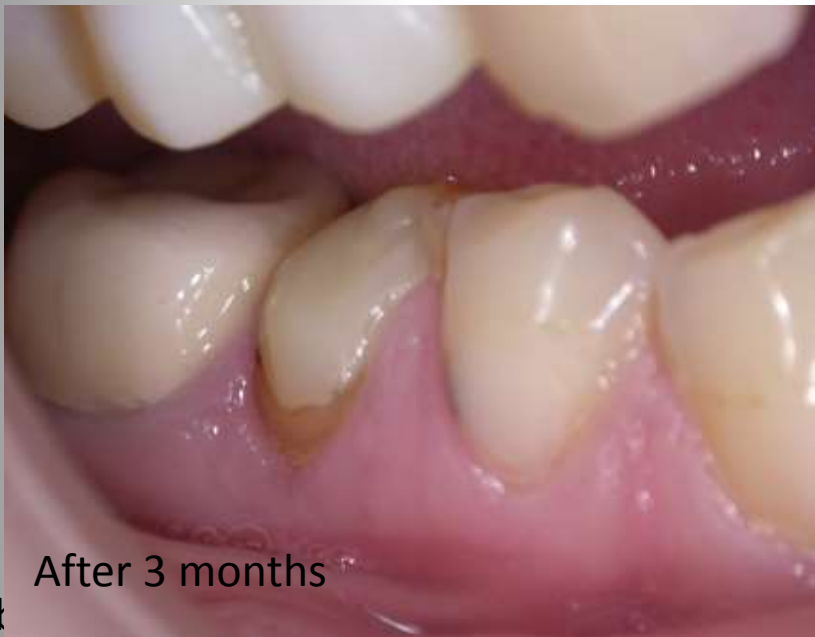Ellis class VIII (crown en masse)



- Possible therapy: restore vs. extract
 - Endodontics+post+core+crown if feasible – if not has poor prognosis that leads to extraction and implant or bridge ? **Predictability ?**
- Therapy of choice:
 - Crown-lengthening makes better prognosis (ferulle effect and better feasibility)



After 3 months

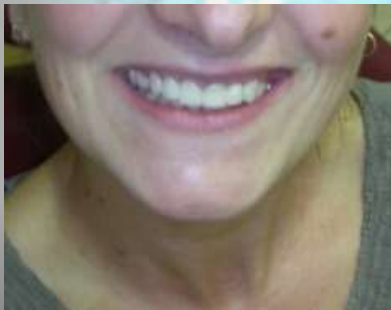
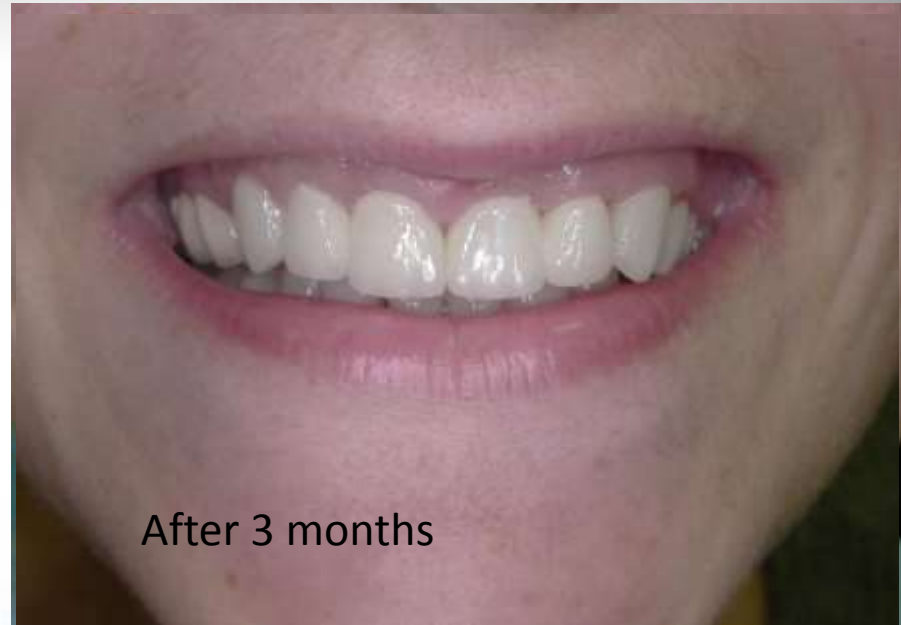
After 3 months

Er:YAG settings: ST 0,2mm tip, contact mode, 200mJ/20Hz; ST 1,3 tip, non-contact mode, 100mJ/20Hz
HT 0,8mm tip, non-contact mode, 100-200mJ/20Hz

Patients with “Gummy Smile” and need for prosthetic reconstruction

- **Possible therapy:**
 - restore without “gummy smile” correction
 - restore without “gummy smile” correction surgically/vs laser
- **Therapy of choice:**
 - Crown-lengthening with Er:YAG laser and prosthetics



Protocol For Crown Lengthening In The Front Region In Patients With Chronic Periodontitis

The procedure is in steps, after FINISHED INITIAL, BASIC AND CORRECTIVE THERAPY:

1. Step

1. Photography;
2. X-Ray
3. Professional cleaning supra- and subgingivally concretions and debris removal;
4. Impressions
5. Sulcus – Periodontal Pocket Depth measurements on 6 points

2. Step

1. Studio models, analysis of models with the *Chu aesthetical perio gauges**, and X-Ray for classification of the crown-lengthening type, planning of the crown-lengthening procedure and wax ups

3. Step

1. **LiteTouch crown-lengthening****
2. Photo

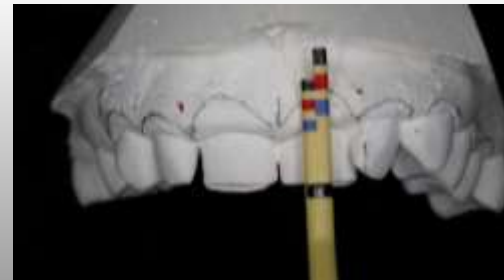
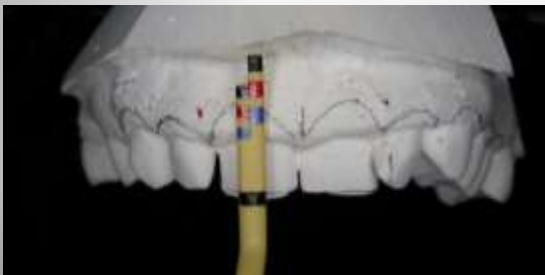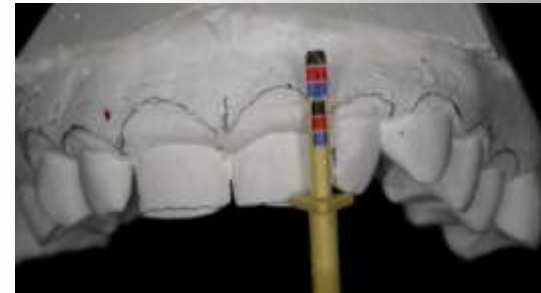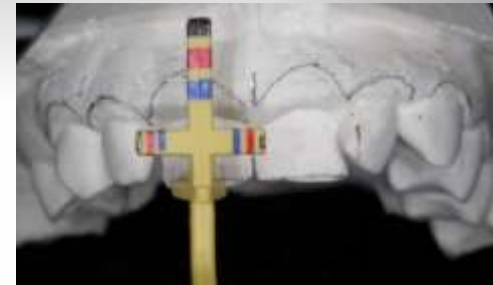4. Step

1. Prosthetic reconstruction
 1. Immediately after (Type 1)
 2. After **3-4** Weeks in (Type 2 and 3)

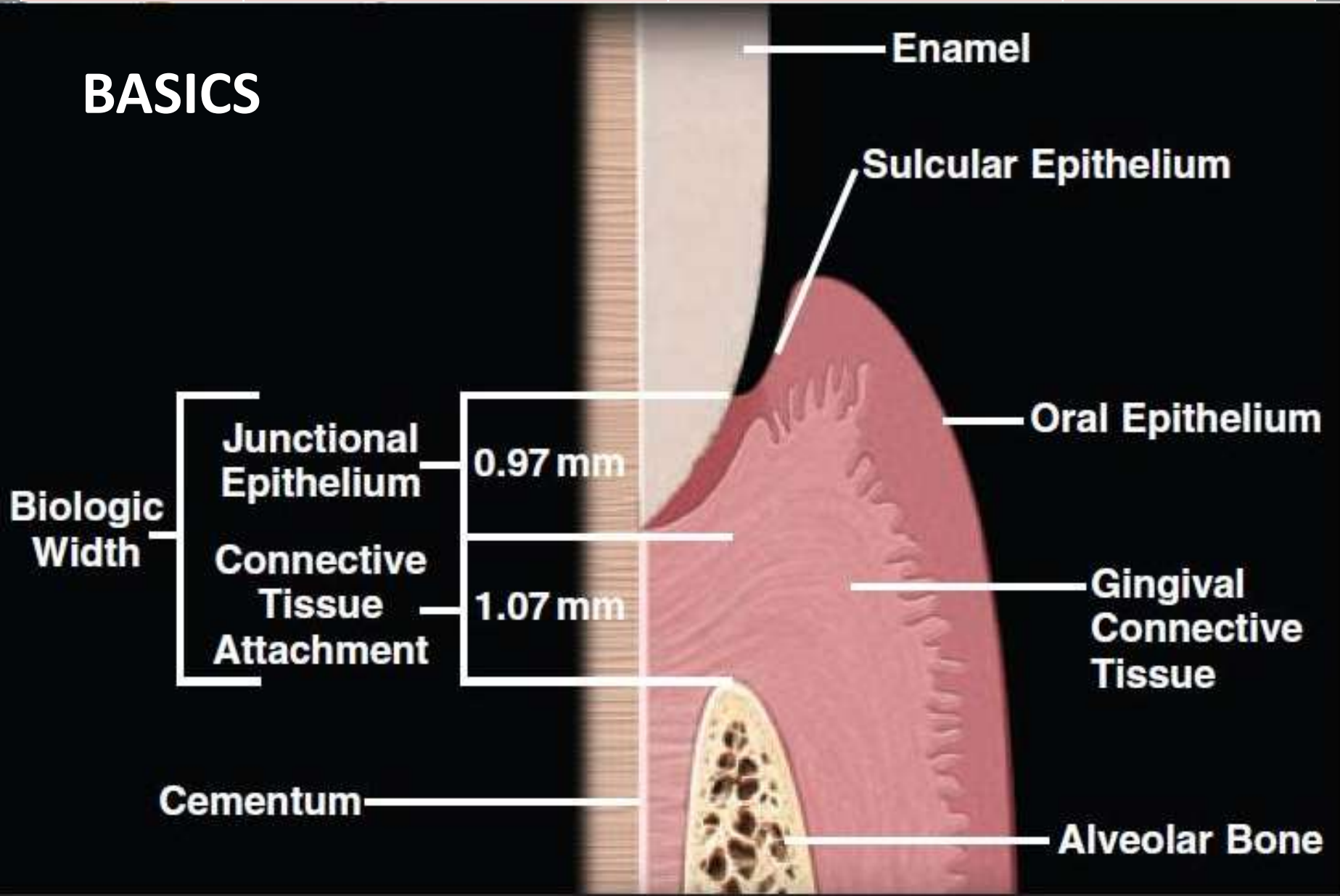
Protocol For Crown Lengthening In The Front Region In Patients With Chronic Periodontitis

DEFINITION OF THE FUTURE:

1. Incisors edge in corono-apical aspect
 2. Teeth proportion
 3. Gingival zenith point
 4. Gingival margin marking
 5. Limbus alveolaris
1. Gingival and osseous interdental papilla – the rule of D. Tarnow



BASICS



Protocol for crown lengthening in the front region in patients with chronic periodontitis



1. LiteTouch crown-lengthening

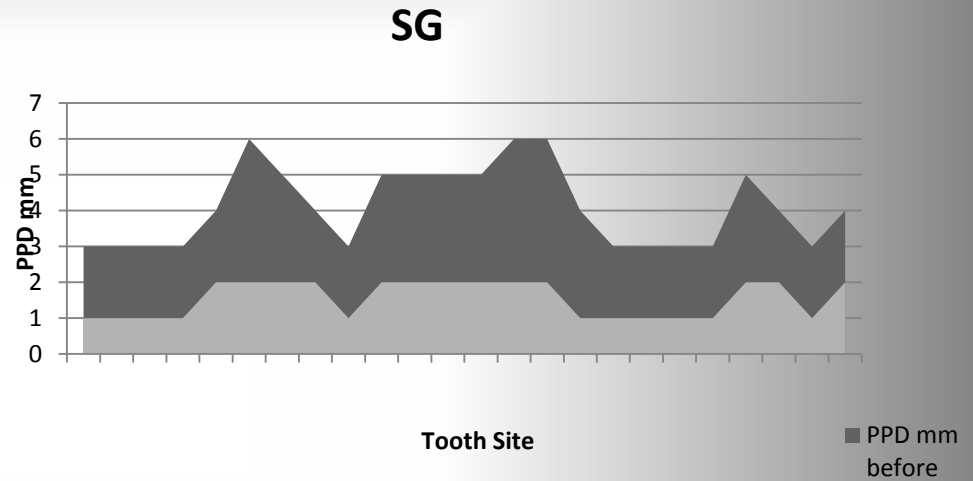
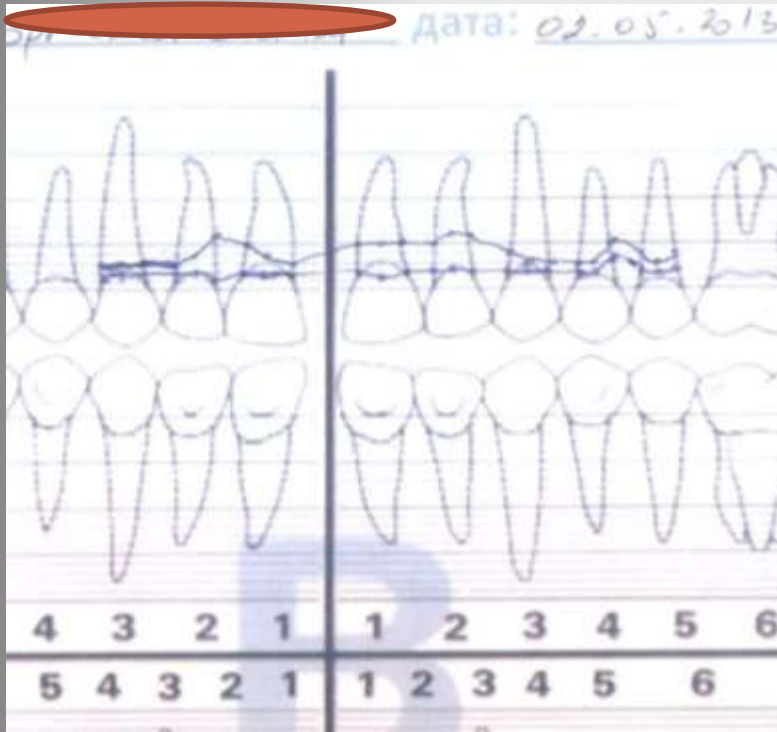
1. Without flap in patients with PPD max<4mm if Type 1 and 2
2. With open flap in patients with PPD max<6mm if Type 2 and 3
3. With open flap in patients with PPD max over 6 mm

STEPS:

- Definition of the incisors edge in corono-apical aspect
- Marking of the future gingiva line – the red-white esthetics line
- Incision : 0,2 mm or 0,4 mm tip; ST mode; contact; 200mJ/20Hz
- Rising a flap and periodontal debridement of the necrotic cement CH tip, HT; contact; 100mJ/15Hz
- Granulation tissue ablation 1,3 mm tip; ST mode, non-contact; 400mJ/17Hz
- Soft tissue pocket wall 0,6 mm tip; ST mode; slight contact; 50m. and going at and over the edge of the flap – cell racing phenomena
- Bone recontouring 1,3mm tip; HT; non-contact; 300-200 mJ/20-25Hz
- Sutura

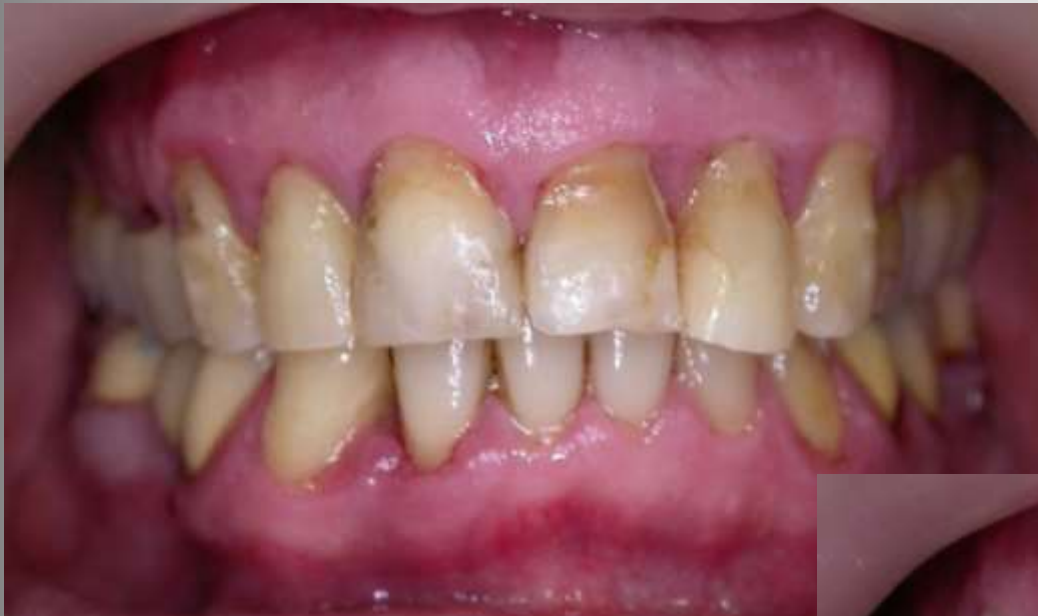

38 Years old, female, non-smoker
 Moderate Periodontitis + Gummy Smile
 Type 3 of Crown-Lengthening



	PPDmax mm	BOP
Before	6	3
After 2 years	3	1

Patients with chronic periodontitis

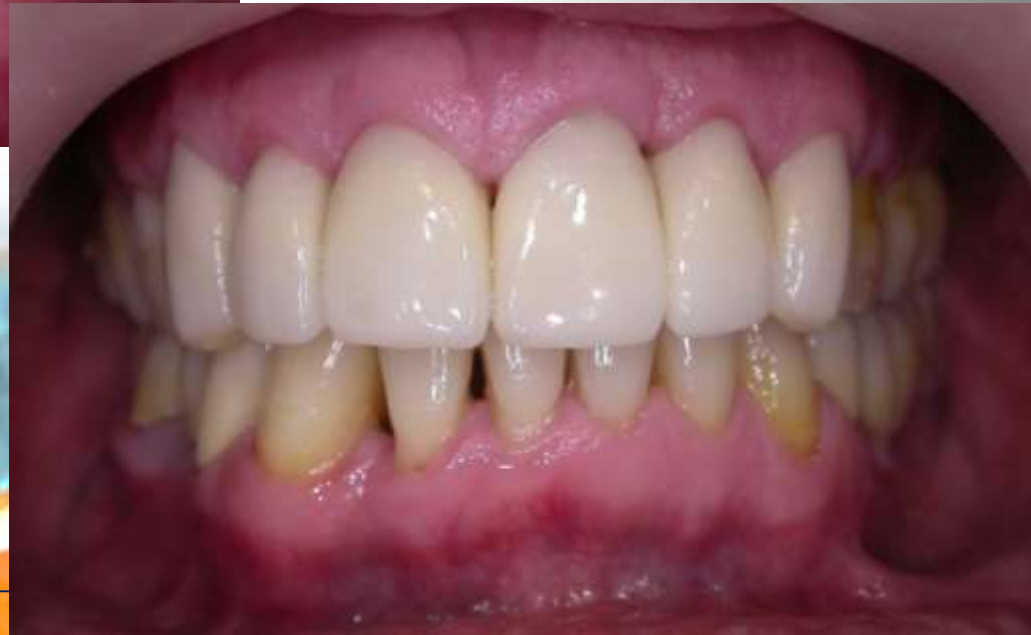

Er:YAG settings: ST 0,6mm tip,
contact mode, 50mJ/30Hz;
HT chisel tip, non-contact mode,
100mJ/15Hz

Beginning



After 4 years



Topic 2. ER:YAG LASER ADVENTAGES FOR PATIENTS WITH CHRONIC PERIODONTITIS

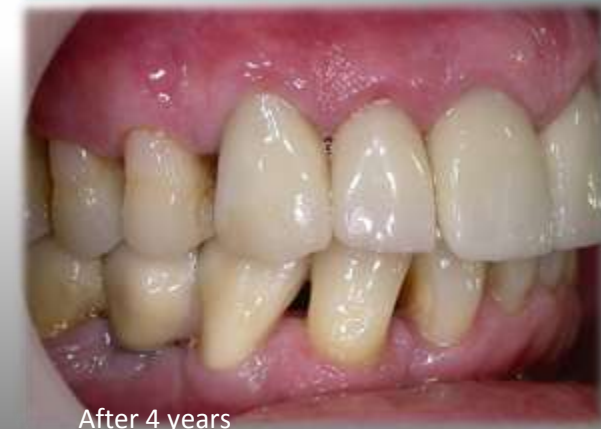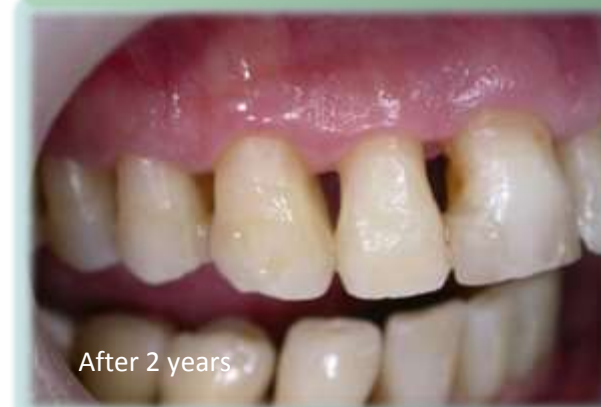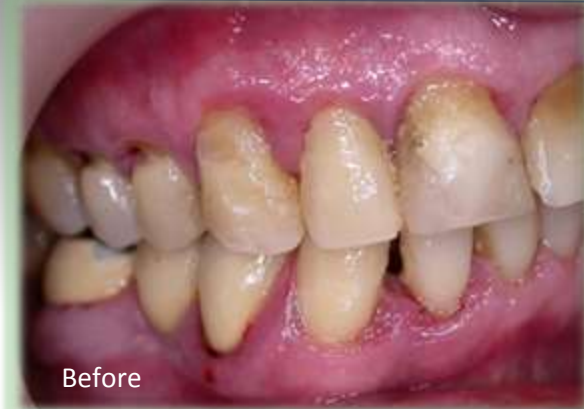Er:YAG function in periodontology

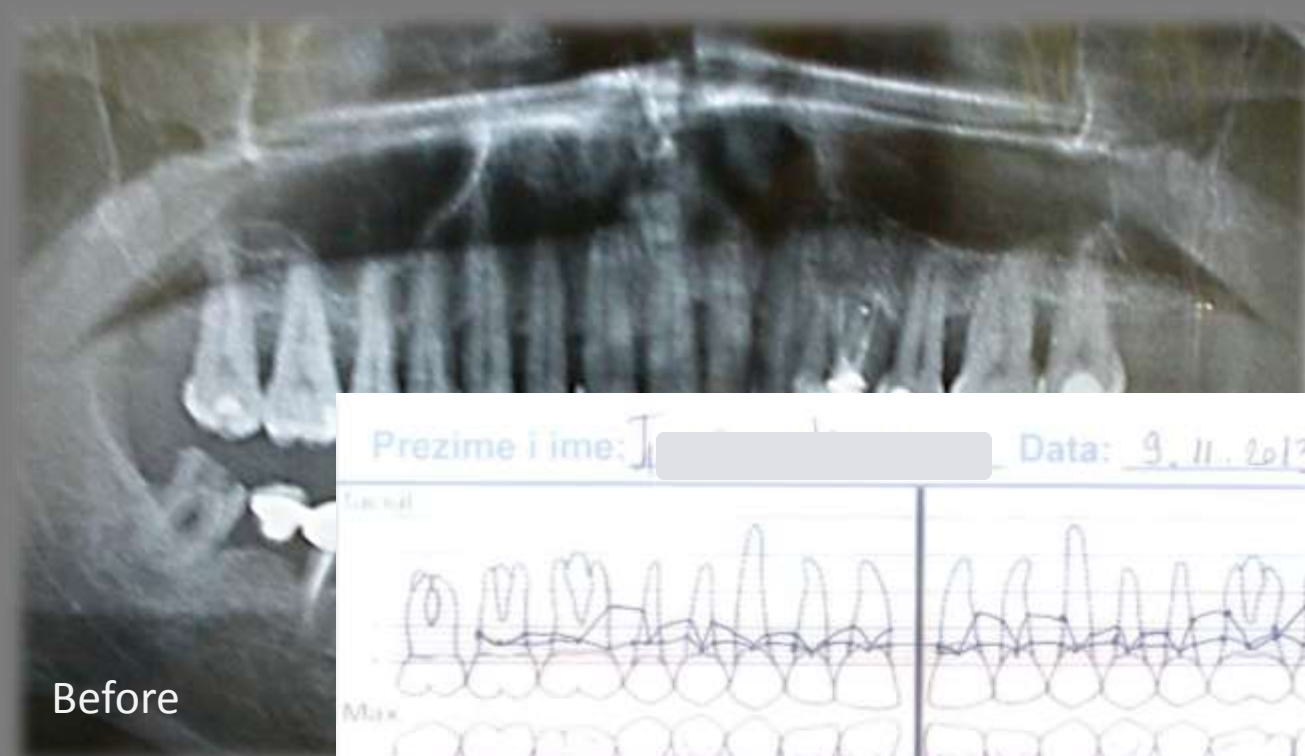
- Ablates the soft and hard tissue
- Decontaminates - Detoxifies
- Disinfects
- Eventually low level irradiation stimulation
- Better wound healing



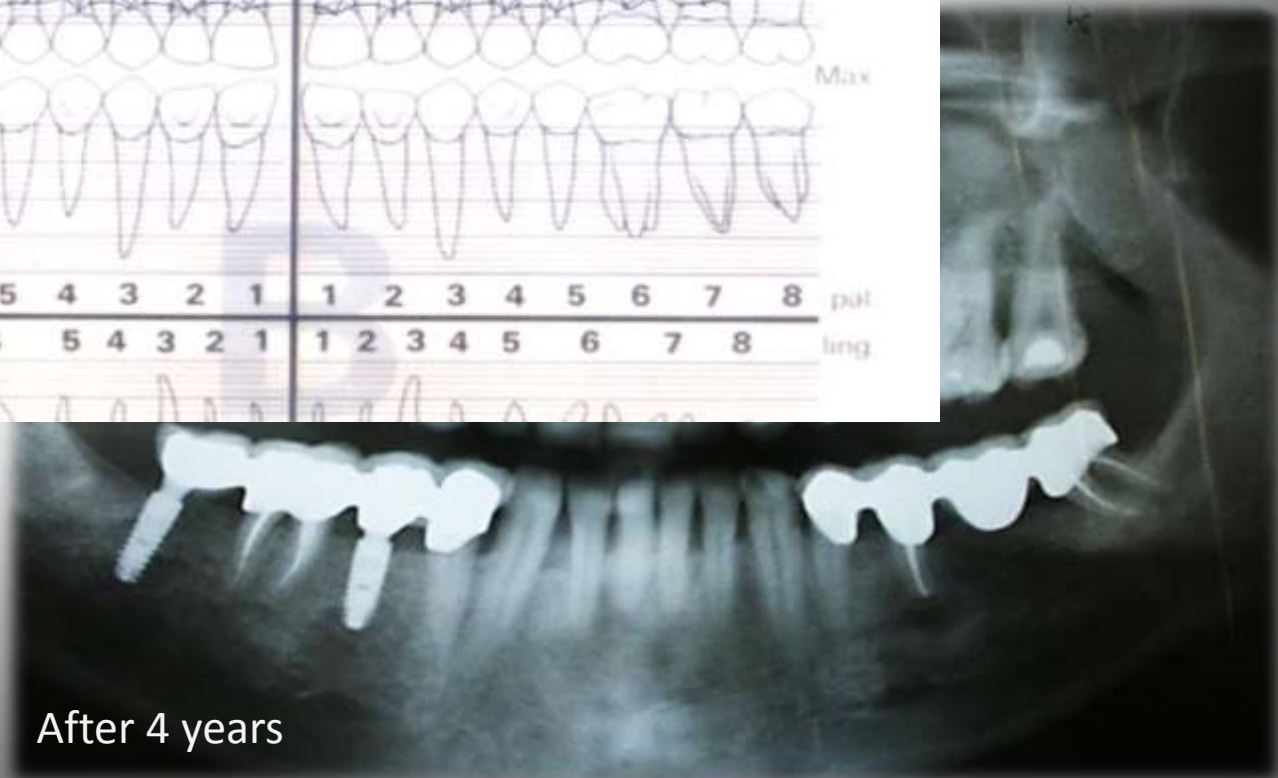
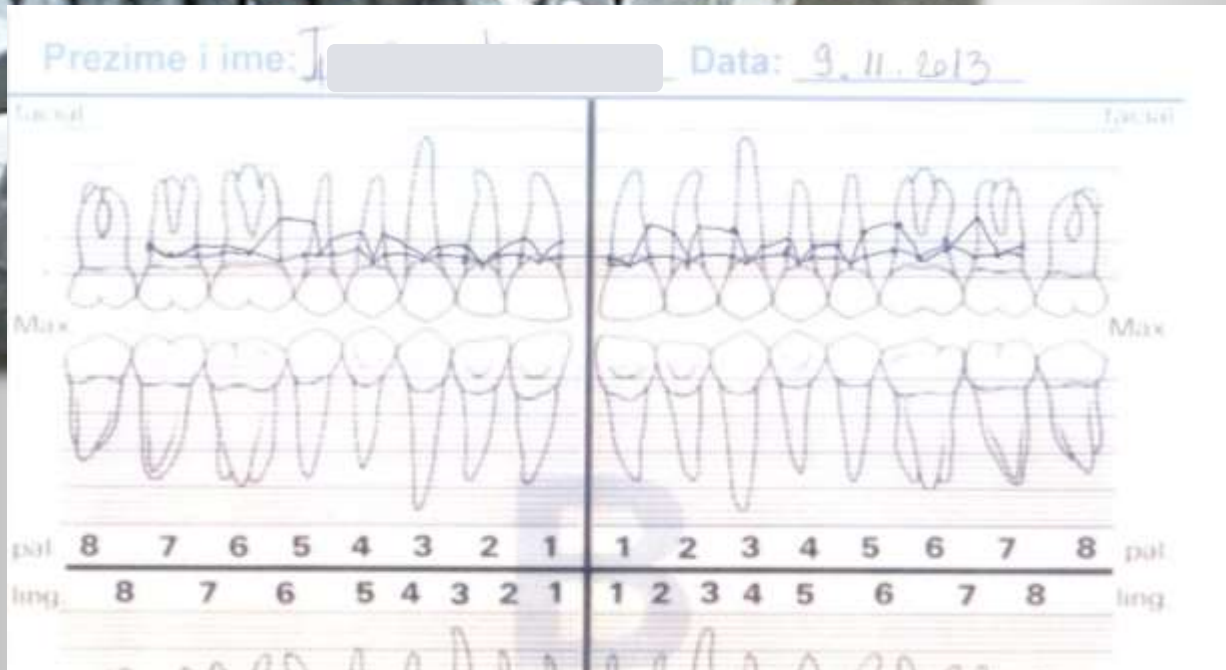
WHY ER:YAG LASER IS ADVENTAGEOUS FOR PATIENTS WITH CHRONIC PERIODONTITIS

- Faster wound healing then conventional SRP methods
- Pocket reduce & Less recessions then conventionally
- Long prognostic results





Before

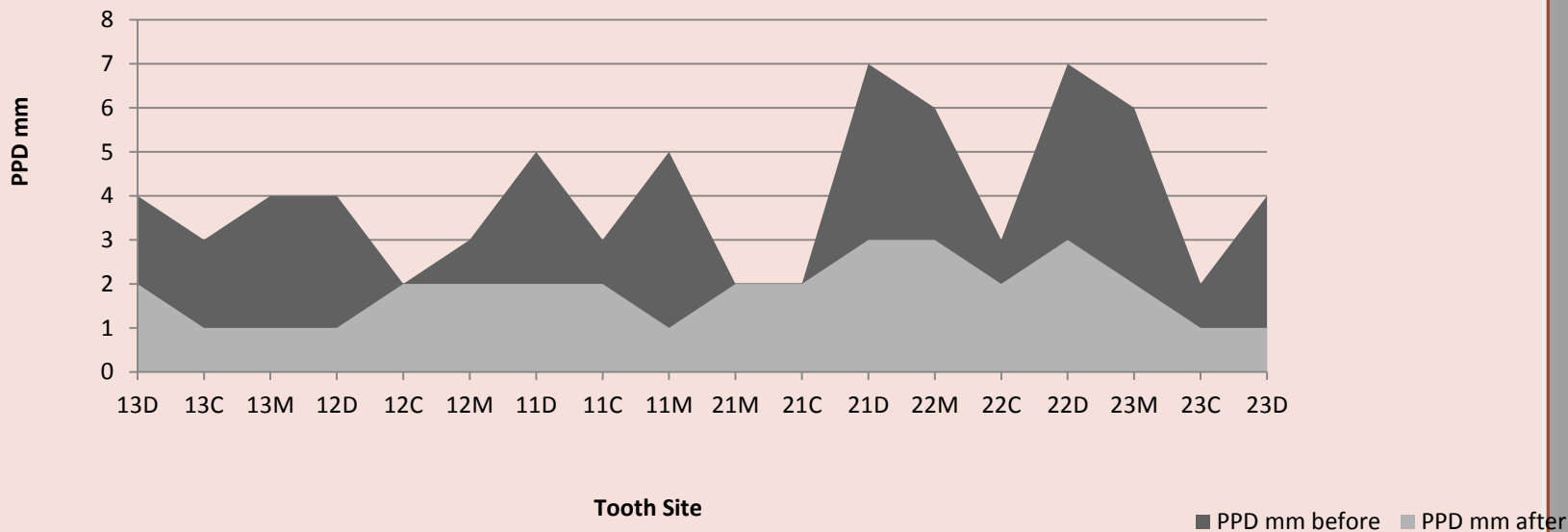


After 4 years

Er:YAG laser assisted Perio Protocol



55 years old male, non-smoker



	PPDmax mm	BOP
Before	7	4
After 4 years	3	1

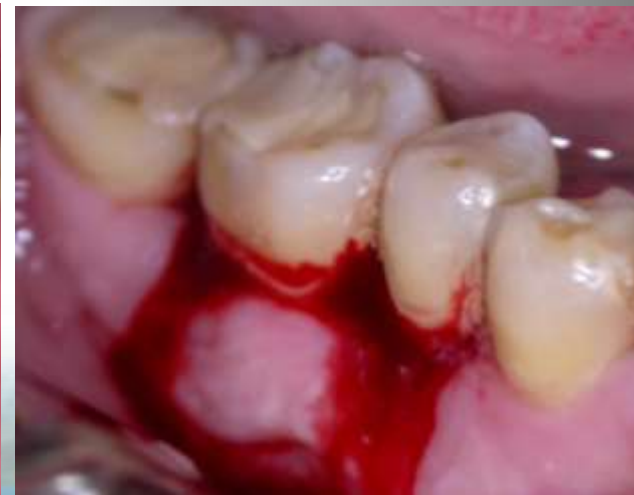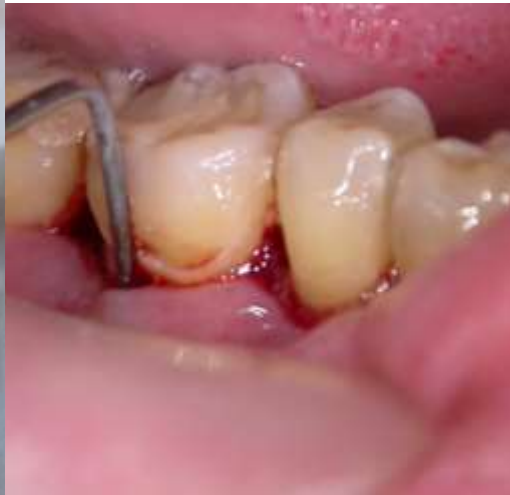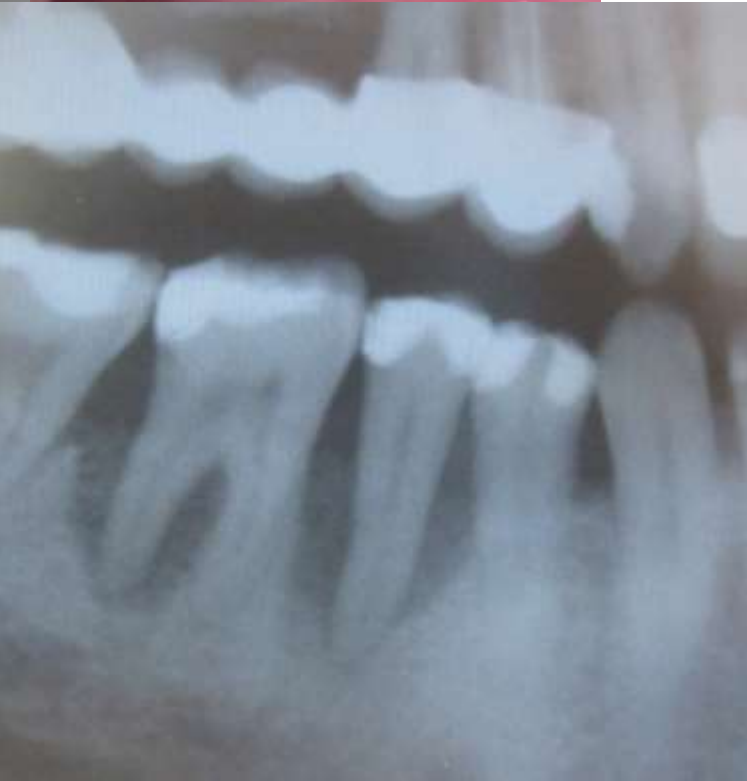Patients with advanced localized periodontitis

– possible therapy:



EXTRACTION + ?

*LANAP+TISSUE GUIDED REGENERATIVE THERAPY +
PROSTHETICS*



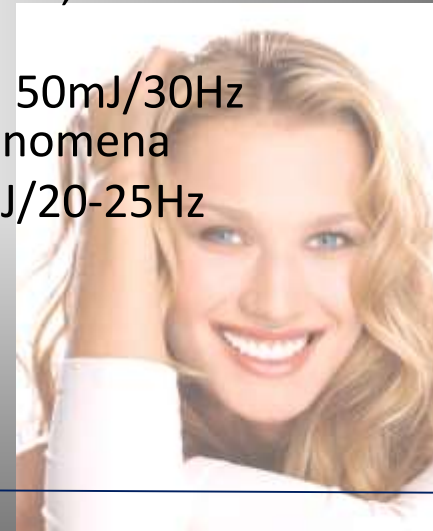WHAT CAN THE PATIENT EXPECT

- Aggressive localized periodontitis: essential therapeutic considerations for the clinician are to control the infection, arrest disease progression, correct anatomic defects, replace missing teeth, and ultimately help the patient maintain periodontal health with frequent periodontal maintenance care.

Therapeutic modalities: conventional, surgical resective, regenerative, antimicrobial.

OUR PROTOCOLE

- Rising a flap and periodontal debridement of the necrotic cement CH tip, HT; contact; 100mJ/15Hz
- Granulation tissue ablation 1,3 mm tip; ST mode, non-contact; 400mJ/17Hz
- Soft tissue pocket wall 0,6 mm tip; ST mode; slight contact; 50mJ/30Hz and going at and over the edge of the flap – cell racing phenomena
- Bone recontouring 1,3mm tip; HT; non-contact; 300-200 mJ/20-25Hz
- BioOss, Geistlich, Swiss + suture

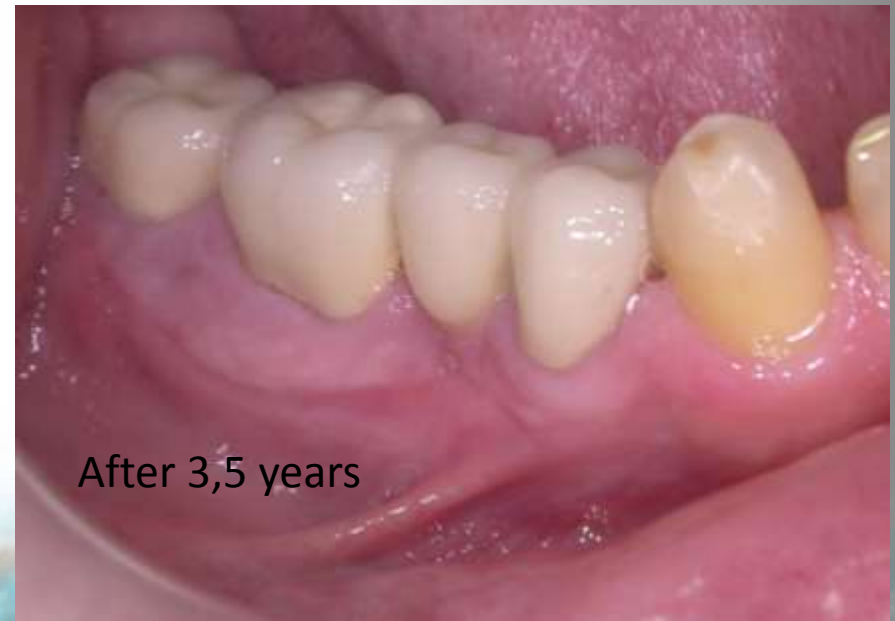
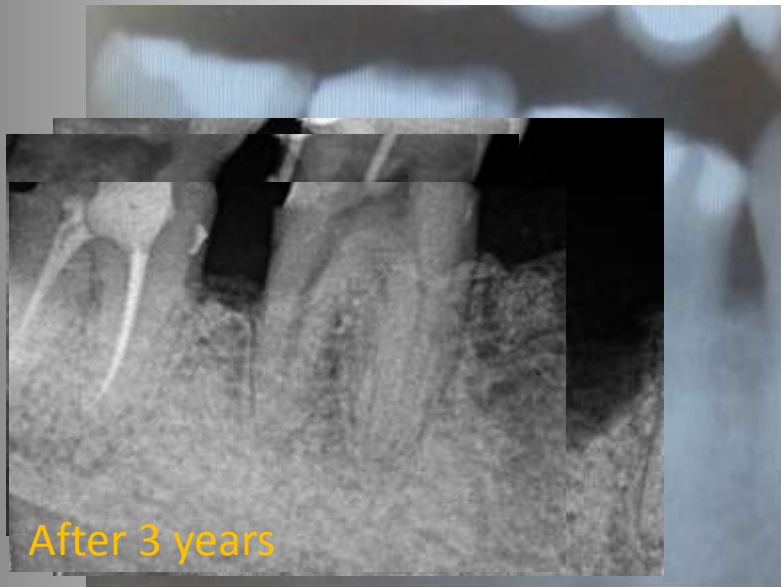
Patients with advanced localized periodontitis

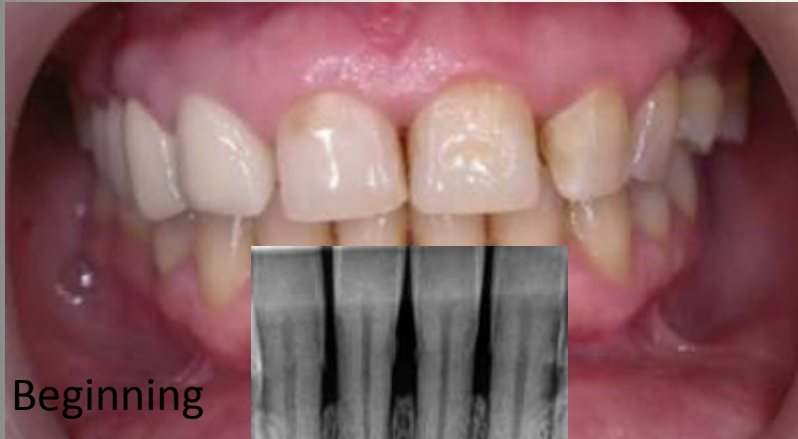– possible therapy:



ER:YAG LASER DEBRIDMENT+TISSUE GUIDED REGENERATIVE THERAPY + PROSTHETICS

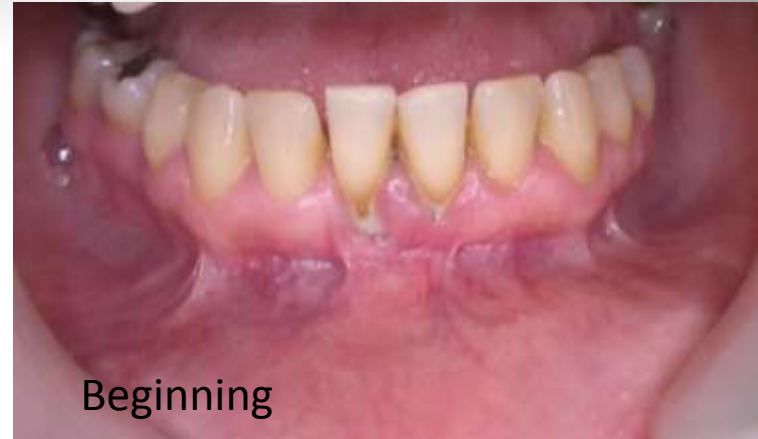

Localized traumatic occlusion associated attachment loss



Beginning

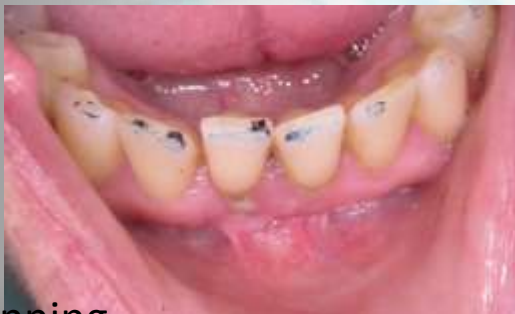Miller class 3



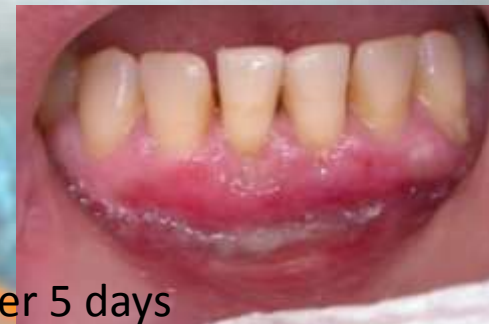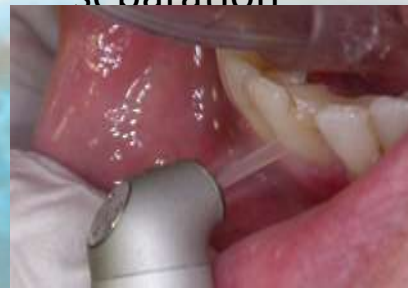Beginning

Therapy protocole:

- Initial therapy+balancing occlusion
- Er:YAG subgingival debridment+periostal separation



Beginning

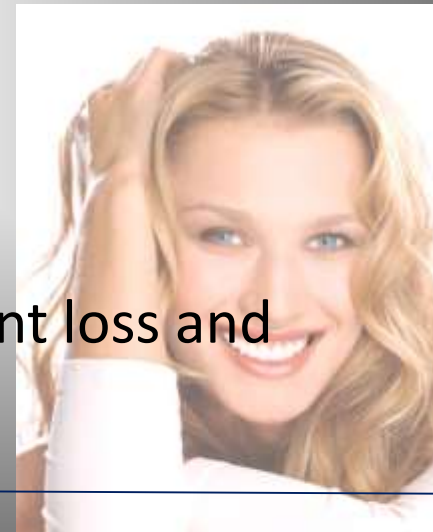


After 5 days

Better overall time management



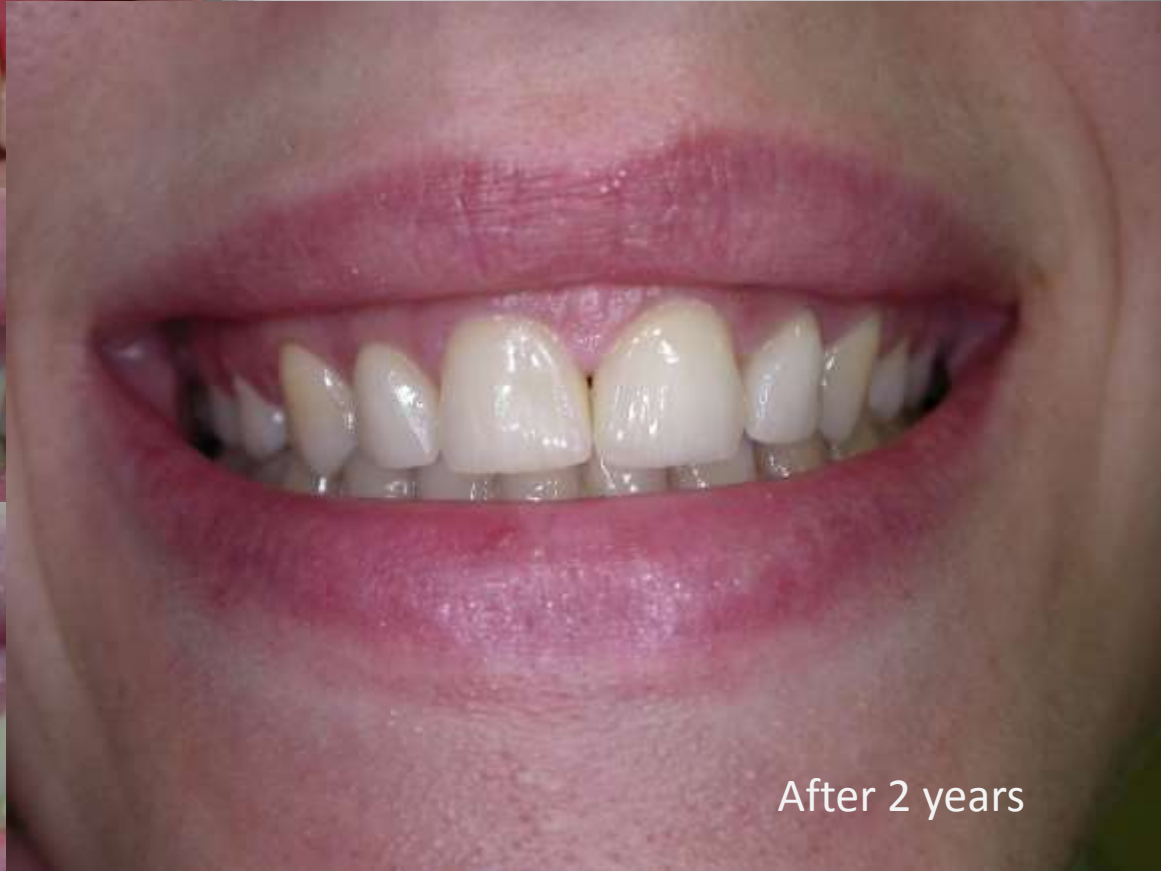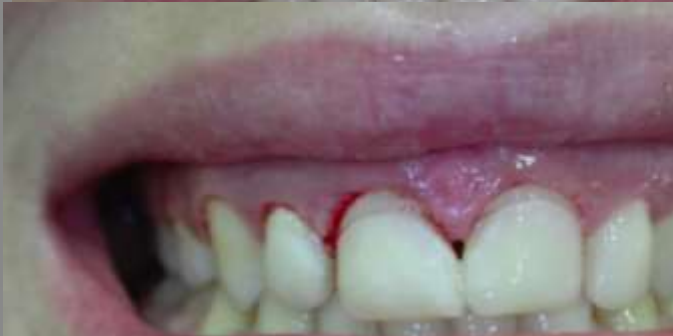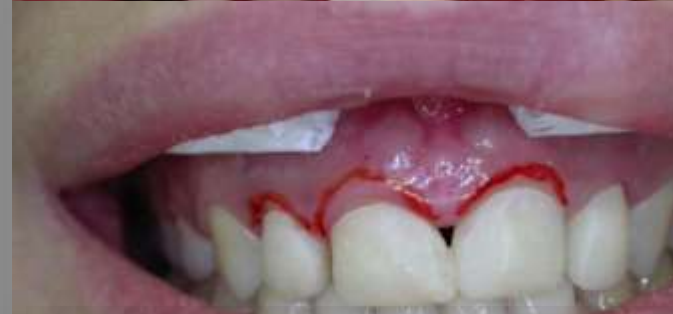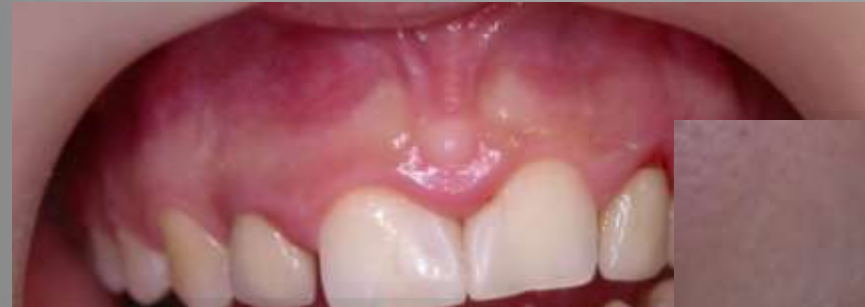- In order to compare the Er:YAG laser vs. conventional protocols in aspect of improving the time management in the daily dental work, we have compared
 - over all time needed for completing the whole treatment plan
 - predictability and
 - patient`s comfort for the following indications:
- prosthetic reconstructions on fractured teeth,
- patients with “gummy smile”,
- patients with moderate chronic periodontitis,
- patients with aggressive periodontitis,
- localized traumatic occlusion associated attachment loss and
- second stage of implant procedures.




Er:YAG Treated

	Number of teeth	Number of patients	Over all time	Predictability	Patient`s comfort
Crown lengthening for prosthetic reconstructions on fractured teeth*	23	10	35 days/vs 3 months	better	Patients prefer the Er:YAG laser than the bur or blade
Er:YAG surgical correction of "Gummy Smile"	30	5	35 days/vs 3 months	better	
Moderate chronic periodontitis	96	5	/	better	
Aggressive periodontitis	26	5	shorter	better	
Localized traumatic occlusion associated attachment loss	21	7	Shorter time for recession recovery	better	
Second stage of implant procedures	30	8	6 days/vs 10 days	better	

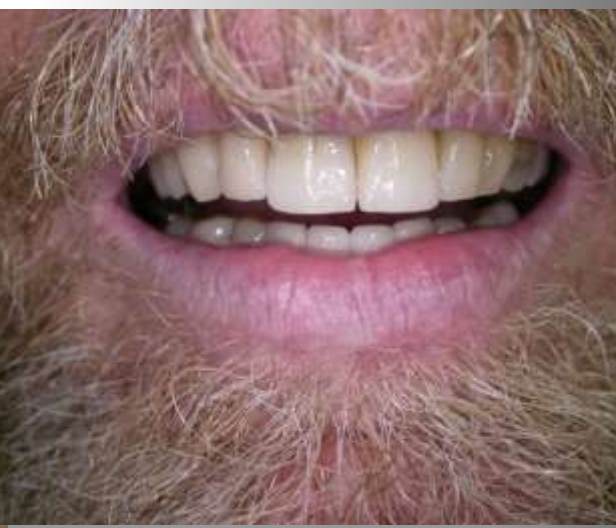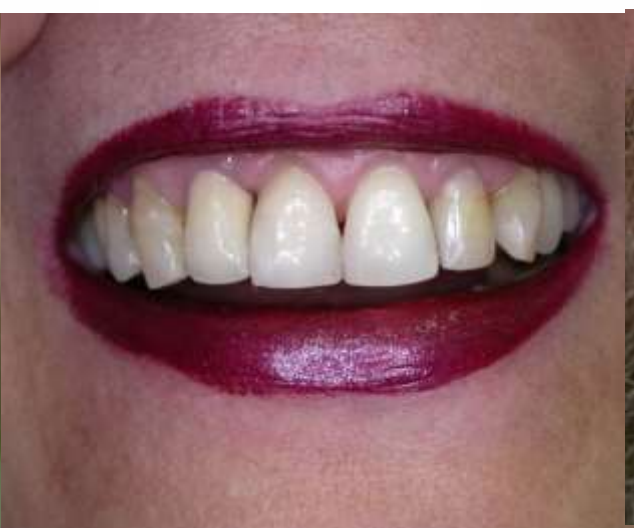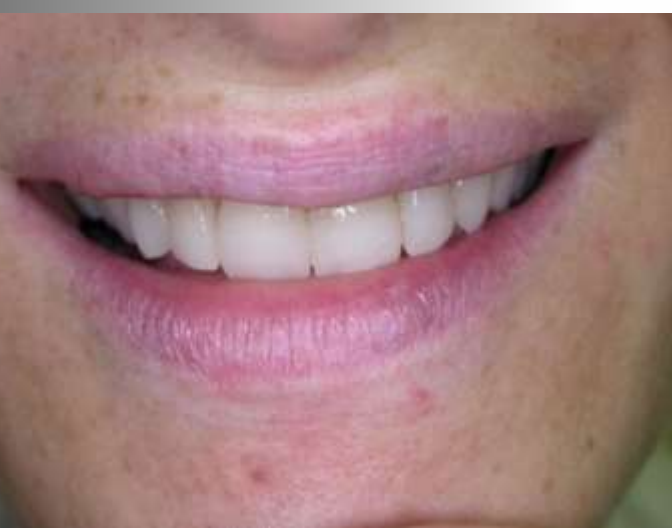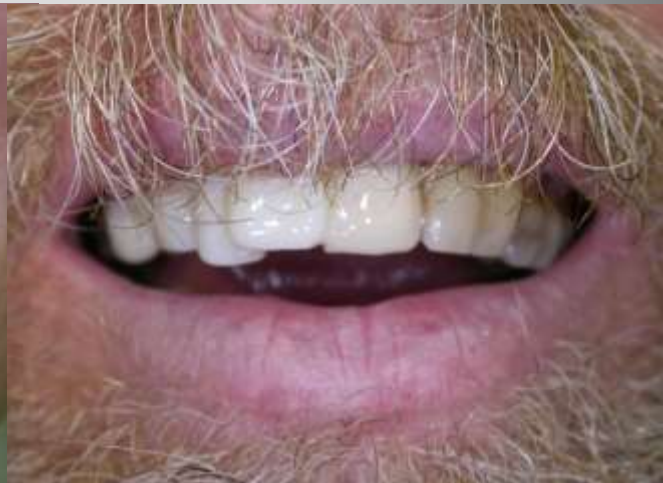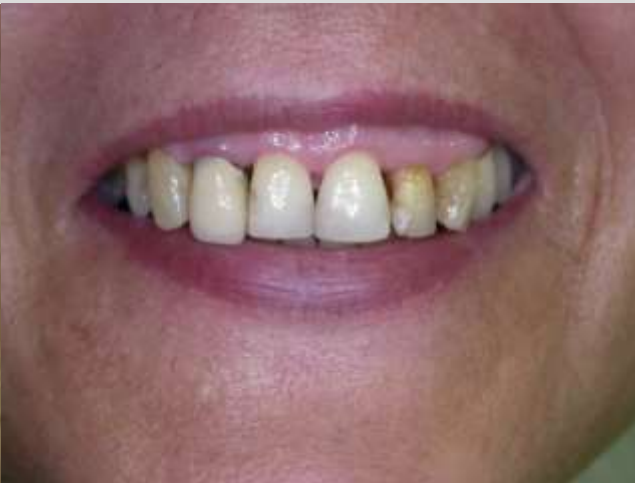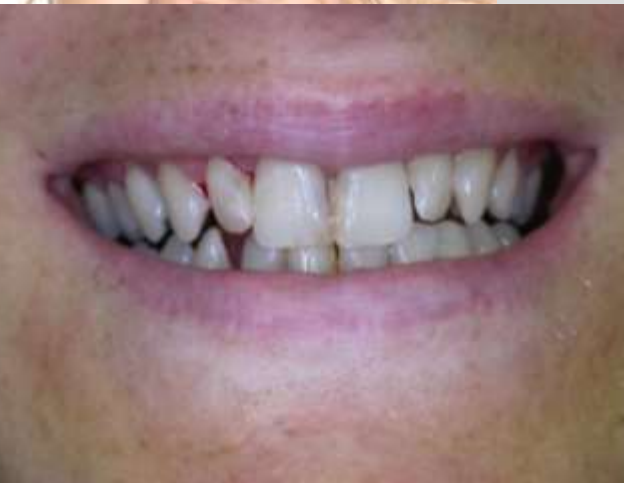Type 1 Er:YAG LiteTouch™ laser assisted CL



After 2 years



WHY Er:YAG LASER ?



POSSIBLE BENEFITS FROM Er:YAG LASER

- Er:YAG laser got very popular among dental practitioners because of its unique abilities for
 - Soft and hard tissue ablation,
 - Bactericidal effect and
 - Improved wound healing.
- The "all tissue" laser is applicable in many dental procedures, but interesting is: in which aspect is it improving general dentistry?
 - Wider indication field
 - Better success predictability
 - Better overall time management etc.
- **GP ROUTNE COMPETENCES**



Skopje City Park

