

Global Retinoblastoma Presentation and Analysis by National Income Level

Global Retinoblastoma Study Group

[+ Supplemental content](#)

IMPORTANCE Early diagnosis of retinoblastoma, the most common intraocular cancer, can save both a child's life and vision. However, anecdotal evidence suggests that many children across the world are diagnosed late. To our knowledge, the clinical presentation of retinoblastoma has never been assessed on a global scale.

OBJECTIVES To report the retinoblastoma stage at diagnosis in patients across the world during a single year, to investigate associations between clinical variables and national income level, and to investigate risk factors for advanced disease at diagnosis.

DESIGN, SETTING, AND PARTICIPANTS A total of 278 retinoblastoma treatment centers were recruited from June 2017 through December 2018 to participate in a cross-sectional analysis of treatment-naïve patients with retinoblastoma who were diagnosed in 2017.

MAIN OUTCOMES AND MEASURES Age at presentation, proportion of familial history of retinoblastoma, and tumor stage and metastasis.

RESULTS The cohort included 4351 new patients from 153 countries; the median age at diagnosis was 30.5 (interquartile range, 18.3-45.9) months, and 1976 patients (45.4%) were female. Most patients (n = 3685 [84.7%]) were from low- and middle-income countries (LMICs). Globally, the most common indication for referral was leukocoria (n = 2638 [62.8%]), followed by strabismus (n = 429 [10.2%]) and proptosis (n = 309 [7.4%]). Patients from high-income countries (HICs) were diagnosed at a median age of 14.1 months, with 656 of 666 (98.5%) patients having intraocular retinoblastoma and 2 (0.3%) having metastasis. Patients from low-income countries were diagnosed at a median age of 30.5 months, with 256 of 521 (49.1%) having extraocular retinoblastoma and 94 of 498 (18.9%) having metastasis. Lower national income level was associated with older presentation age, higher proportion of locally advanced disease and distant metastasis, and smaller proportion of familial history of retinoblastoma. Advanced disease at diagnosis was more common in LMICs even after adjusting for age (odds ratio for low-income countries vs upper-middle-income countries and HICs, 17.92 [95% CI, 12.94-24.80], and for lower-middle-income countries vs upper-middle-income countries and HICs, 5.74 [95% CI, 4.30-7.68]).

CONCLUSIONS AND RELEVANCE This study is estimated to have included more than half of all new retinoblastoma cases worldwide in 2017. Children from LMICs, where the main global retinoblastoma burden lies, presented at an older age with more advanced disease and demonstrated a smaller proportion of familial history of retinoblastoma, likely because many do not reach a childbearing age. Given that retinoblastoma is curable, these data are concerning and mandate intervention at national and international levels. Further studies are needed to investigate factors, other than age at presentation, that may be associated with advanced disease in LMICs.

Group Information: The members of the Global Retinoblastoma Study Group appear at the end of this article.

Corresponding Author: Ido Didi Fabian, MD, London School of Hygiene & Tropical Medicine, Keppel Street, London WC1E 7HT, United Kingdom (didi@didifabian.com).

JAMA Oncol. 2020;6(5):685-695. doi:[10.1001/jamaoncol.2019.6716](https://doi.org/10.1001/jamaoncol.2019.6716)
Published online February 27, 2020.

Retinoblastoma, the most common eye cancer of childhood, is fatal if left untreated. Prognosis of patients with retinoblastoma in high-income countries (HICs) has improved over the past 50 years, now reaching a near 100% disease-free survival rate.¹⁻³ This is attributed to several factors, including (1) creation of specialized referral centers, (2) decoding of the genetic basis of the disease, (3) formation of screening programs, and (4) the introduction of chemotherapy.⁴ In HICs, retinoblastoma is a curable disease, and attention has now shifted to eye salvage^{5,6} and improvement of quality of life.⁷ In low- and middle-income countries (LMICs), where more than 80% of global retinoblastoma cases arise, the prognosis is poor, and it is assumed that this is because of delayed diagnosis and treatment.⁸⁻¹⁰ Publications from LMICs are scarce, and many countries do not report their retinoblastoma data.¹¹ The stage of retinoblastoma at the time of diagnosis in low-income, middle-income, and high-income countries has not been surveyed globally. This information is important for policy and health care planning at national and international levels.

The objectives of this study are to (1) report the stage at diagnosis in a large global sample of patients with retinoblastoma, (2) examine associations between clinical variables at presentation and national-income level, and (3) investigate risk factors for advanced disease at diagnosis.

Methods

This study originated from a consortium of retinoblastoma treatment centers in 8 countries on 3 continents.¹² From June 2017 through December 2018, all known retinoblastoma treatment centers across the world were contacted by means of personal communications, presentations at scientific conferences, and linking to professional societies in the fields of ophthalmology and oncology to form a global network. All centers involved in the diagnosis and treatment of patients with retinoblastoma, at least by means of enucleation, were eligible to participate.

Study Design

This study adheres to the Strengthening the Reporting of Observational Studies in Epidemiology (STROBE) reporting guidelines.¹³ It was a 1-year cross-sectional analysis that included all treatment-naïve patients with retinoblastoma who presented to participating centers from January 1, 2017, to December 31, 2017, and who were treated or offered treatment for retinoblastoma. A predesigned form was used for data collection (eTable 1 in the [Supplement](#)). The data collected included country of residence, sex, first ocular symptom as noted by parents, age at first indication of symptom, age and ocular indication at presentation to the retinoblastoma treatment center, laterality, familial history of retinoblastoma, staging according to the *American Joint Committee on Cancer Staging Manual, Eighth Edition*¹⁴ and the International Retinoblastoma Staging System,¹⁵ and primary treatment. Data on country of residence, sex, and laterality were minimum criteria for patient enrollment. The staging classifications were simplified to include only the major subcategories (eTable 2 in the [Supplement](#)). For the primary tumor site (cT), the

Key Points

Question Is the income level of a country of residence associated with the clinical stage of presentation of patients with retinoblastoma?

Findings In this cross-sectional analysis that included 4351 patients with newly diagnosed retinoblastoma, approximately half of all new retinoblastoma cases worldwide in 2017, 49.1% of patients from low-income countries had extraocular tumor at time of diagnosis compared with 1.5% of patients from high-income countries.

Meaning The clinical stage of presentation of retinoblastoma, which has a major influence on survival, significantly differs among patients from low-income and high-income countries, which may warrant intervention on national and international levels.

eye with the more advanced disease was used for analysis. Completed forms were electronically uploaded onto a secure server, after which a data quality assurance process was performed (eMethods in the [Supplement](#)).

The study was approved by the institutional review board at the London School of Hygiene & Tropical Medicine, which granted a waiver of patient informed consent. Participating centers applied for and received ethics clearance in their countries according to local institutional guidelines.

Statistical Analysis

All analyses were performed using R software, version 3.5.2 (R Foundation for Statistical Computing), and IBM SPSS Statistics, version 25.0 (IBM Corp). The crude birth rate, country population size, and country classification by national income level were obtained from the 2017 World Population Prospects.¹⁶ The predicted number of new patients with retinoblastoma per country was calculated as follows: [country population × crude birth rate/1000/17 000], and predicted number per national income level was the sum result of all countries at the same level.

Unless otherwise indicated, summary statistics are presented as median and interquartile range (25%-75%). The *t* test was used to compare means of normally distributed continuous variables, Fisher exact and Pearson χ^2 tests were used to compare categorical variables, Spearman rank correlation test was used for nonnormal continuous and ordinal variables, and the Cochran-Armitage test^{17,18} was used to test for trend in the proportions of patients with a given parameter across the income levels. Binomial logistic regression was used to model the effect of income level (upper-middle-income level and high-income level combined), presentation age (grouped by tertiles), familial retinoblastoma history, sex, and bilaterality, on the likelihood of children having advanced disease (cT4) at presentation. An α level of .05 and 2-tailed *P* values were used to determine statistical significance.

Results

The study sample included 4351 treatment-naïve patients with retinoblastoma residing in 153 countries (**Figure**). The data

analyzed by national income level are shown in **Table 1**. Country-level and continent-level data are shown at <http://globalretinoblastoma.org> (password: Ret2017).

Geographic and Socioeconomic Characteristics

More than half (2276 [52.3%]) of the patients were from Asia, 1024 (23.5%) were from Africa, 522 (12.0%) were from Europe, 512 (11.8%) were from the Americas, and 17 (0.4%) were from Oceania. Of all patients, 533 (12.3%) came from low-income countries (LICs), 1940 (44.6%) from lower-middle, 1212 (27.9%) from upper-middle, and 666 (15.3%) from HICs.

Completeness of Data

For 4116 (94.6%) of the study patients, data were reported on each study parameter, except for age at first ocular symptom of retinoblastoma (2175 [50.0%]; not included in the analysis). Analysis by national income level showed that reporting was nearly complete ($\geq 98.5\%$) for patients from high-income and upper-middle-income countries, and more than 94.1% and 89.1% for patients from lower-middle-income countries and LICs, respectively.

Symptoms Leading to Referral

The most common first symptom of disease was leukocoria ($n = 2638$ [62.8%]), followed by strabismus ($n = 429$ [10.2%]), with a further 162 (3.9%) patients having a combination of leukocoria and strabismus (eTable 3 in the **Supplement**). Proptosis was reported in 309 (7.4%) patients. At least 1 symptom of advanced disease (ie, proptosis, swollen eyelids, red eye) was reported in 487 (11.7%) patients. A higher income level was associated with a lower proportion of patients with symptoms of advanced disease (z score = 10.9, $dim = 4$; $P < .001$; additional analysis is provided in eTable 4 in the **Supplement**).

Symptoms at Time of Diagnosis at Retinoblastoma Centers

Of all patients, 2998 (70.4%) presented with either leukocoria, strabismus, or a combination of these symptoms (eTable 3 in the **Supplement**). In LICs, combinations of proptosis, red eye, orbital cellulitis, and extraocular retinoblastoma (ie, advanced disease) were present in 248 (46.7%) patients. Analysis of patients who had only leukocoria and/or strabismus (ie, early disease) as the symptoms noticed by the parents, but who presented to retinoblastoma treatment centers with symptoms of advanced disease, showed a significantly larger proportion coming from LICs (z score = 18.4, $dim = 4$; $P < .001$; additional analysis is provided in eTable 4 in the **Supplement**).

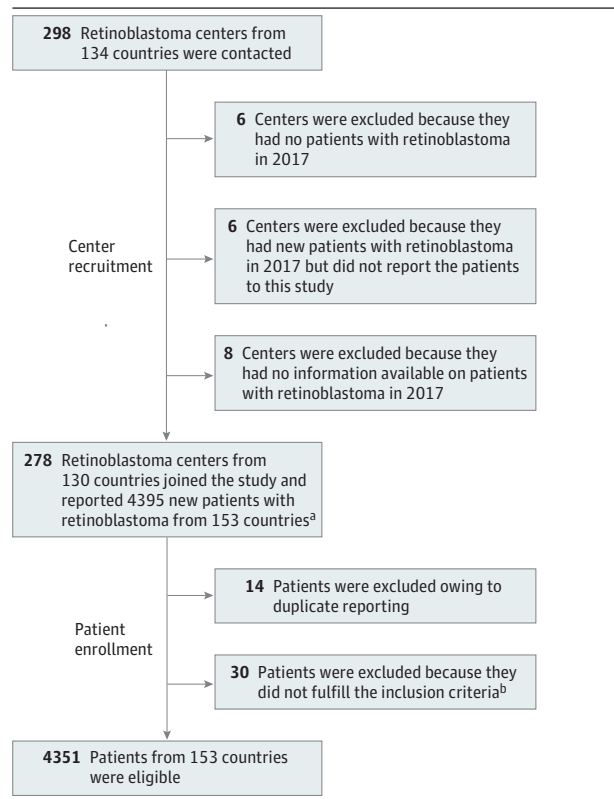
Age at Diagnosis

The overall median age at diagnosis was 23.5 months (interquartile range [IQR], 11.2-36.5 months; Table 1). The median age at diagnosis of patients from LICs was 30.5 months (IQR, 18.3-45.9 months) compared with 14.0 months (IQR, 6.2-26.6 months) for patients from HICs. There was a significant association between presentation age and national income level, with children in LMICs presenting at an older age (eTable 5 in the **Supplement**).

Tumor Staging

Globally, the most common cTNM stages were cT3 ($n = 1933$ of 4114 [47.0%]), NO ($n = 3303$ of 4281 [77.2%]), and

Figure. Cohort Recruitment Flowchart



^a Patients from 23 countries with no retinoblastoma centers were treated outside of their country of residence.

^b Inclusion criteria included reporting of country of residence, sex, and laterality. Patients for whom 1 or more of these parameters were not available were not included in the analytic sample.

MO ($n = 3964$ of 4275 [92.7%]) (Table 1). Extraocular retinoblastoma at time of diagnosis was reported in 926 of 4302 (21.5%) patients (256 [49.1%] in LICs vs 10 [1.5%] in HICs). Distant metastases were reported in 94 (18.9%), 157 (8.3%), 58 (4.8%), and 2 (0.3%) patients from low, lower-middle, upper-middle, and high income-level countries, respectively (z score = 11.9, $dim = 4$; $P < .001$). Higher economic grouping was associated with higher proportions of intraocular and earlier stage disease at diagnosis (Table 1).

Risk Factors for Advanced Disease at Time of Diagnosis

Sex ($\chi^2_1 = 1.016$; $P = .31$), bilaterality ($\chi^2_1 = 0.830$; $P = .36$) and familial history of retinoblastoma ($\chi^2_1 = 2.269$; $P = .13$) were found to be nonsignificant factors for the prediction of cT4 category (extraocular retinoblastoma) and hence were removed from the model. On logistic regression, low-income level and older presentation age were found to be independent and significant predictive factors for advanced disease (Table 2).

Familial History and Bilateral Retinoblastoma

Familial history of retinoblastoma was reported in 199 of 4215 (4.7%) patients (15 [3.1%], 75 [4.0%], 54 [4.5%], and 55 [8.4%] patients from low, lower-middle, upper-middle, and high

Table 1. Clinical Characteristics at Presentation of 4351 New Patients With Retinoblastoma Diagnosed in 2017

Parameter	National Income Level, No. (% within the national income level) [% within the evaluated parameter]				Total, No. (%)	Significance	P Value
	Low	Lower-Middle	Upper-Middle	High			
Age at diagnosis, median (IQR), mo							
Total sample	30.5 (18.3-45.9)	24.4 (12.2-37.3)	20.7 (10.1-33.8)	14.0 (6.2-26.6)	23.5 (11.2-36.5)		
Unilateral	35.0 (22.2-48.0)	29.1 (18.1-42.9)	25.5 (12.9-37.6)	19.7 (9.0-32.4)	27.1 (15.0-41.0)	p: -0.22	<.001 ^a
Bilateral	22.9 (11.8-32.8)	14.4 (8.0-25.8)	11.4 (6.0-21.0)	8.1 (3.7-15.8)	12.3 (6.1-24.3)		
Reported cases, No. (%)	524/533 (98.3)	1909/1940 (98.4)	1192/1212 (98.3)	664/666 (99.7)	4289/4351 (98.6)		
Laterality at diagnosis^b							
Unilateral	408 (76.5) [13.6]	1325 (68.3) [44.0]	847 (69.9) [28.1]	430 (64.6) [14.3]	3010/4351 (69.2)	NA	<.001 ^c
Bilateral	125 (23.5) [9.3]	615 (31.7) [45.9]	365 (30.1) [27.2]	236 (35.4) [17.6]	1341/4351 (30.8)		
Familial history of retinoblastoma							
No	467 (96.9) [11.6]	1805 (96.0) [44.9]	1141 (95.5) [28.4]	603 (91.6) [15.0]	4016/4215 (95.3)	z score: -4.3, dim: 4	<.001 ^d
Yes	15 (3.1) [7.5]	75 (4.0) [37.7]	54 (4.5) [27.1]	55 (8.4) [27.6]	199/4215 (4.7)		
Total, No. (%)	482/533 (90.4)	1880/1940 (96.9)	1195/1212 (98.6)	658/666 (98.8)	4215/4351 (96.9)		
Primary tumor							
cT1	5 (1.0) [1.8]	96 (5.1) [35.3]	67 (6.1) [24.6]	104 (15.9) [38.2]	272/4114 (6.7)	z score: 22.3, dim: 4	<.001 ^e
cT2	62 (12.6) [4.9]	406 (21.7) [31.8]	482 (44.1) [37.8]	326 (49.7) [25.5]	1276/4114 (31.0)		
cT3	209 (42.6) [10.8]	1013 (54.1) [52.4]	488 (44.6) [25.2]	223 (34.0) [11.5]	1933/4114 (47.0)		
cT4	215 (43.8) [34.0]	359 (19.2) [56.7]	56 (5.1) [8.8]	3 (0.4) [0.4]	633/4114 (15.4)		
Total, No. (%)	491/533 (92.1)	1874/1940 (96.6)	1093/1212 (90.2)	656/666 (98.5)	4114/4351 (94.6)		
Regional lymph node							
NX	105 (20.7) [12.6]	350 (18.4) [42.1]	267 (22.2) [32.1]	109 (16.4) [13.1]	831/4281 (19.4)	z score: 8.3, dim: 4	<.001 ^f
N0	360 (71.0) [10.9]	1475 (77.3) [44.7]	912 (75.9) [27.6]	556 (83.6) [16.8]	3303/4281 (77.2)		
N1	42 (8.3) [28.6]	82 (4.3) [55.8]	23 (1.9) [15.6]	0	147/4281 (3.4)		
Total, No. (%)	507/533 (95.1)	1907/1940 (98.3)	1202/1212 (99.2)	665/666 (99.8)	4281/4352 (98.4)		
Distant metastasis							
M0	404 (81.1) [10.2]	1749 (91.8) [44.1]	1147 (95.2) [28.9]	664 (99.7) [16.8]	3964/4275 (92.7)	z score: 11.9, dim: 4	<.001 ^g
cM1	65 (13.1) [30.4]	110 (5.8) [51.4]	39 (3.2) [18.2]	0	214/4275 (5.0)		
pM1	29 (5.8) [29.9]	47 (2.5) [48.5]	19 (1.6) [19.6]	2 (0.3) [2.1]	97/4275 (2.3)		
Total, No. (%)	498/533 (93.1)	1906/1940 (98.2)	1205/1212 (99.4)	666/666 (100)	4275/4351 (98.3)		
Hereditary trait							
HX	360 (72.7) [14.2]	1211 (63.8) [47.9]	736 (61.6) [29.1]	221 (33.4) [8.7]	2528/4250 (59.5)	NA	NA
H0	0	44 (2.3) [17.3]	59 (4.9) [23.2]	151 (22.8) [59.4]	254/4250 (6.0)		
H1	135 (27.3) [9.2]	643 (33.9) [43.8]	400 (33.5) [27.2]	290 (43.8) [19.8]	1468/4250 (34.5)		
Total, No. (%)	495/533 (92.9)	1898/1940 (97.8)	1195/1212 (98.6)	662/666 (99.4)	4250/4351 (97.7)		
Extraocular retinoblastoma							
No	265 (50.9) [7.8]	1393 (73.0) [41.3]	1062 (88.0) [31.5]	656 (98.5) [19.4]	3376/4302 (78.5)	z score: 21.8, dim: 4	<.001 ^h
Yes	256 (49.1) [27.6]	515 (27.0) [55.6]	145 (12.0) [15.7]	10 (1.5) [1.1]	926/4302 (21.5)		
Total, No. (%)	521/533 (97.7)	1908/1940 (98.4)	1207/1212 (99.6)	666/666 (100)	4302/4351 (98.9)		
International Retinoblastoma Staging System							
Stage 0	44 (8.7) [3.0]	459 (24.2) [31.3]	585 (48.8) [39.9]	378 (56.8) [25.8]	1466/4264 (34.4)	NA	NA
Stage I	170 (33.8) [1.0]	816 (43.0) [47.9]	444 (37.0) [26.1]	272 (40.8) [16.0]	1702/4264 (39.9)		
Stage II	58 (11.5) [27.2]	111 (5.9) [52.1]	40 (3.3) [18.8]	4 (0.6) [1.9]	213/4264 (5.0)		
Stage III	101 (20.1) [26.1]	242 (12.8) [62.5]	41 (3.4) [10.6]	3 (0.5) [0.7]	387/4264 (9.1)		
Stage IV	94 (18.7) [29.9]	157 (8.3) [50.0]	60 (5.0) [19.1]	3 (0.5) [1.0]	314/4264 (7.4)		
NA	36 (7.2) [19.8]	111 (5.9) [61.0]	29 (2.4) [15.9]	6 (0.9) [3.3]	182/4264 (4.3)		
Total, No. (%)	503/533 (94.4)	1896/1940 (97.7)	1199/1212 (98.9)	666/666 (100)	4264/4351 (98.0)		

Abbreviations: IQR, interquartile range; NA, not applicable.

^a Spearman rank correlation.

^b Inclusion criteria: 100% reporting.

^c Fisher exact test for proportion of bilateral cases.

^d Cochran-Armitage test for proportion of familial history of retinoblastoma.

^e Cochran-Armitage test for proportion of cT3 or greater.

^f Cochran-Armitage test for proportion of cases with lymph node involvement.

^g Cochran-Armitage test for proportion of cases with distant metastasis.

^h Cochran-Armitage test for proportion of cases with extraocular disease.

Table 2. Logistic Regression Analysis: Predictors of Advanced Disease at Presentation^{a,b}

Variable	B (SE)	Corrected P Value	Odds Ratio (95% CI)
Income level			
Low vs (upper-middle + high)	2.886 (0.166)	<.001	17.92 (12.94-24.80)
Low-middle vs (upper-middle + high)	1.748 (0.148)	<.001	5.74 (4.30-7.68)
Age at diagnosis			
14.27-31.20 mo	1.343 (0.167)	<.001	3.83 (2.76-5.31)
>31.20 mo	2.026 (0.160)	<.001	7.58 (5.54-10.38)
Constant	-4.602 (0.190)	<.001	0.01

^a The logistic regression model was statistically significant ($\chi^2_4 = 727.27$; $P < .001$). The model explained 28.5% (Nagelkerke R^2) of the variance and correctly classified 85.1% of cases. Area under the curve was 0.813.

^b Advanced disease is defined as cT4.

income-level countries, respectively). Bilateral disease at time of diagnosis was seen in 1341 of 4351 (30.8%) patients (125 [23.5%], 615 [31.7%], 365 [30.1%], and 236 [35.4%] patients from low, lower-middle, upper-middle, and high income-level countries, respectively) (Table 1). Significantly more familial (z score = -4.3, $dim = 4$; $P < .001$) and, independently, more bilateral cases were seen in HICs compared with LICs.

Diagnostic Facilities and Treatment Modalities

The available diagnostic and treatment modalities are shown in eTable 6 in the Supplement. The majority of patients (4201 [96.6%]) were diagnosed in a center that contained resources for computed tomography and/or magnetic resonance imaging. A histopathology service was available for 4236 (97.4%) participants, and intravenous chemotherapy for 4263 (98.0%).

Global Magnitude of Retinoblastoma and Representativeness of the Study

Given that the mean age at the time of diagnosis was approximately 2 years old, the 2015 birth rate data were used for calculation of the number of new retinoblastoma cases.¹⁶ According to these data, the predicted annual number of new retinoblastoma cases worldwide ranged from 7752 to 8914. Using an average incidence figure of 1 of 17 000 live births, capture rates were 88.2%, 56.5%, 48.7%, and 39.9% of expected cases from high, upper-middle, lower-middle, and low-income countries, respectively. No data were received from 65 countries and principalities, mainly with small populations; the estimated number of missing cases from these countries was 46.

Discussion

Findings of this study show a large disparity in the presentation patterns of retinoblastoma between HICs and LMICs. A total of 666 children were from HICs, 99% of whom had at the time of diagnosis a tumor confined to the eye and thus a favorable prognosis. In comparison, of the 3685 patients from LMICs, 25% were diagnosed with tumor spread beyond the globe, for which the prognosis is much worse.^{19,20} It is likely that the real gap in the pattern of retinoblastoma presentation is even wider owing to unreported patients in LICs who never arrived at a retinoblastoma treatment center and for whom death from metastatic disease is inevitable.

Late cancer diagnosis, also in the pediatric population, is a major issue in LMICs.²¹⁻²⁵ This study confirms this finding

for retinoblastoma, which, if detected early, can be cured. These findings are consistent with a recent study of global disease burden that found that cancer among 0- to 4-year-olds accounts for 37% of the global disease-adjusted life year; this proportional burden is greater in LMICs.²⁶

The factors causing delay in retinoblastoma diagnosis and treatment in LMICs are beyond the scope of this study. However, the findings here suggest that late recognition of signs of retinoblastoma, as well as delay in reaching a dedicated retinoblastoma treatment center once ocular symptoms have been detected, likely play a role, and both factors are associated with national income level. These findings indicate clinically significant progression of signs between parental detection and presentation to a specialist center in LMICs. Earlier recognition of leukocoria or strabismus and urgent referral for diagnosis is very important if children are to receive treatment before extraocular spread occurs.

A familial history of retinoblastoma followed the same pattern, with relatively fewer cases in lower-income countries. A possible explanation could be underreporting or inadequate medical record keeping in resource-limited settings. However, a more plausible explanation would be that children with familial history of disease are diagnosed and treated early in HICs so that they survive to childbearing age, whereas this may not be the case in LMICs.

Nearly all essential diagnostic and therapeutic modalities were available in most participating treatment centers. Enucleation surgery, which was available in all treatment centers, can save lives, and intravenous chemotherapy, which was available for 98.0% of the patients in this study, can save lives and also result in globe salvage if patients are diagnosed and treated in time.^{27,28}

The results of this study point to an urgent need to improve retinoblastoma detection and access to treatment in LMICs. Several initiatives are addressing this challenge by implementing twinning programs that link centers from higher-resource and lower-resource countries.^{12,29-32} However, there is a pressing need for coordinated action on a global level. In a rare yet curable cancer such as retinoblastoma, with approximately 8000 new patients annually worldwide, such an action is feasible to make retinoblastoma a zero-death cancer.³³ The World Health Organization Global Initiative for Childhood Cancer aims to raise survival for key childhood cancers, including retinoblastoma, to 60% by the year 2030 by helping health systems in LMICs integrate childhood cancer into their national strategies and improve their capacity to diagnose and deliver curative treatment.³⁴ In this context, accu-

rate retinoblastoma-specific data are essential. The results of this study serve as a report of the current retinoblastoma presentation status, against which future interventions can be measured, and demonstrate the need for a strong global partnership to improve outcomes for patients with retinoblastoma everywhere.

Results of the present study showed that older age at presentation and, independently, national income level were associated with advanced disease, which suggests that other factors besides age may be important in disease progression. It has been suggested that infection by the human papillomavirus, which is more prevalent in LMICs, is associated with the development of nonhereditary retinoblastoma, and it is possible that this could be associated with more aggressive disease behavior.³⁵ Another possible explanation relates to the genetic landscape of retinoblastoma and especially to cases with no *RBI* mutation but a high level of amplification of the oncogene *MYCN*.³⁶ These cases are unilateral, develop at an early age, and show aggressive features. They were found only in 1.4% of unilateral retinoblastoma cases, all from cohorts in HICs,³⁶ but have not been evaluated in patients from LICs. Notably, in the present study, there were substantially more unilateral cases in LICs as compared with other income levels, in keeping with the above-mentioned hypotheses. However, these speculations, warrant further studies.

Limitations

This study has several limitations. First, it included a convenience sample and therefore had an inherent potential bias. Nevertheless, to our knowledge, it is the largest and most geographically comprehensive study in the field of retinoblastoma, and we believe its findings can be generalized. Second,

data collection was mostly retrospective, with the exception of treatment centers that were recruited early in 2017. However, the simplicity of the study design and quality assurance process enabled the collection of almost complete data, also from LMICs. Third, the socioeconomic status of individual families was not included as a variable, and the national income level was used as a surrogate, an approach that assumes that all families from the same country are of the same socioeconomic level.

Conclusions

The findings of this cross-sectional global analysis of retinoblastoma at the time of diagnosis revealed important differences in presentation among patients from different countries, depending on their national income level. Patients with retinoblastoma from HICs present with early disease and are, therefore, likely to survive. In contrast, patients from lower-income settings present with late disease, many with extraocular extension and some already with metastasis, and their prognosis is poorer. A familial history of retinoblastoma is relatively uncommon in lower-income countries, likely owing to death related to late-disease presentation before childbearing years. A surprise finding of this study is that more advanced disease at presentation in lower-income countries is not entirely explained by older age. Further research is warranted to investigate what factors other than age play a role in disease progression in low-income settings. Prompt action at national and international levels is warranted to improve health education about retinoblastoma, as well as access to early diagnosis and treatment in retinoblastoma treatment centers in LMICs.

ARTICLE INFORMATION

Accepted for Publication: November 13, 2019.

Open Access: This is an open access article distributed under the terms of the [CC-BY License](https://creativecommons.org/licenses/by/4.0/).
© 2020 Global Retinoblastoma Study Group.
JAMA Oncology.

Published Online: February 27, 2020.
doi:10.1001/jamaoncol.2019.6716

The Global Retinoblastoma Study Group Authors:

The following investigators take authorship responsibility for the study results: Ido Didi Fabian, MD; Elhassan Abdallah, MD; Shehu U. Abdullahi, MD; Rula A. Abdulqader, MD; Sahadatou Adamou Boubacar, MD; Dupe S. Ademola-Popoola, FMCOPh, FWACS; Adedayo Adio, FWACS; Armin R. Afshar, MD; Priyanka Aggarwal, MD; Ada E. Aghaji, MSc, FMCOPh; Alia Ahmad, MRCPC; Marliyanti N. R. Akib, MD; Lamis Al Harby, MD; Mouroug H. Al Ani, MD; Aygun Alakbarova, MD; Silvia Alarcón Portabella, MD; Safaa A. F. Al-Badri, MD; Ana Patricia A. Alcasbas, MD; Saad A. Al-Dahmash, MD; Amanda Alejos, MD; Ernesto Alemany-Rubio, MD; Amadou I. Alfa Bio, MD; Yvania Alfonso Carreras, MD; Christiane Al-Haddad, MD; Hamoud H. Y. Al-Hussaini, MD, MSc; Amany M. Ali, MD; Donjeta B. Alia, MD; Mazin F. Al-Jadiry, MD; Usama Al-Jumaly, MD; Hind M. Alkatan, MD; Charlotta All-Eriksson, MD, PhD; Ali A. R. M. Al-Mafrachi, FIBMS; Argentina A. Almeida, MD; Khalifa M. Alsawidi, MD; Athar A. S. M. Al-Shaheen,

MD; Entissar H. Al-Shammary, MD; Primawita O. Amiruddin, MD; Romanzo Antonino, MD; Nicholas J. Astbury, FRCS, FRCOPhth; Hatice T. Atalay, MD; La-onsing Atchaneeyasakul, MD; Rose Atsiaya, OCO; Taweewat Attaseth, MD; Than H. Aung, MRCSEd; Silvia Ayala; Baglan Baizakova, MD; Julia Balaguer, MD, PhD; Ruhengiz Balayeva, PhD; Walentyna Balwierz, MD; Honorio Barranco, MD, PhD; Covadonga Bascaran, MD, MSc; Maja Beck Popovic, MD; Raquel Benavides, MD; Sarra Benmiloud, MD; Nissrine Bennani Guebessi, MD, PhD; Rokia C. Berete, MD, PhD; Jesse L. Berry, MD; Anirban Bhaduri, MS; Sunil Bhat, MD; Shelley J. Biddulph, FCOph; Eva M. Biewald, MD; Nadia Bobrova, MD; Marianna Boehme; H.C. Boldt, MD; Maria Teresa B. C. Bonanomi, MD, PhD; Norbert Bornfeld, MD; Gabrielle C. Bouda, MD; Hédi Bouguila, MD, PhD; Amaria Boumedane, MD; Rachel C. Brennan, MD; Bénédicte G. Brichard, MD, PhD; Jassada Buaboonnam, MD; Patricia Calderón-Sotelo, MD; Doris A. Calle Jara, MD; Jayne E. Camuglia, FRANZCO; Miriam R. Cano, MD, MSc; Michael Capra, FRCPI; Nathalie Cassoux, MD, PhD; Guilherme Castela, MD; Luis Castillo, MD; Jaume Català-Mora, MD, PhD; Guillermo L. Chantada, MD, PhD; Shabana Chaudhry, MD; Sonal S. Chaugule, MD; Argudit Chauhan, BA; Bhavna Chawla, MD; Violeta S. Chernodrinska, MD, PhD; Faraja S. Chiwanga, MSc; Tsengelmaa Chuluunbat, MD, PhD; Krzysztof Cieslik, MD; Ruelly L. Cockcroft, MB, ChB, MMedPaed; Codruta Comsa, MD; Zelia M. Correa, MD, PhD; Maria G. Correa Llano, MD; Timothy W. Corson, PhD; Kristin

E. Cowan-Lyn, MD, MBBS; Monika Csóka, MD, PhD; Xuehao Cui, MS; Isac V. Da Gama, MD; Wantanee Dangboon, MD; Anirban Das, MD; Sima Das, MS; Jacquelyn M. Davanzo, BSN, BSPH; Alan Davidson, MBChB, MPhil; Patrick De Potter, MD, PhD; Karina Q. Delgado, MD, PhD; Hakan Demirci, MD; Laurence Desjardins; Rosdali Y. Diaz Coronado, MD; Helen Dimaras, PhD; Andrew J. Doggshun, MPhil; Craig Donaldson, MD, FRANZCO; Carla R. Donato Macedo, MD; Monica D. Dragomir, MD, PhD; Yi Du, MD; Magritha Du Bruyn, MD; Kemala S. Edison, MD; I. Wayan Eka Sutyanawan, MD; Asmaa El Kettani, MD; Amal M. Elbahi, MD; James E. Elder, MBBS; Dina Elgalaly, BPh; Alaa M. Elhaddad, MD, PhD; Moawia M. Ali Elhassan, MD; Mahmoud M. Elzembely, MD; Vera A. Essuman, FWACS; Ted Grimbert A. Evina, MD; Zehra Fadoo, MBBS; Adriana C. Fandiño, MD; Mohammad Faranoush, MD; Oluyemi Fasina, FWACS; Delia D. P. G. Fernández, MSc; Ana Fernández-Teijeiro, MD, PhD; Allen Foster, FRCOPhth; Shahar Frenkel, MD, PhD; Ligia D. Fu, MD; Soad L. Fuentes-Alabi, MD, MPH; Brenda L. Gallie, MD; Moira Gandiwa, MD; Juan L. Garcia, MSc; David García Aldana, MD; Pascale Y. Gassant, MD; Jennifer A. Geel, MBChB, MMed; Fariba Ghassemi, MD; Ana V. Girón, MD; Zelalem Gizachew, MD; Marco A. Goenz, MD; Aaron S. Gold, OD; Maya Goldberg-Lavid, MD; Glen A. Gole, MD, FRANZCO; Nir Gomel, MD; Efrén Gonzalez, MD; Graciela Gonzalez Perez, MD; Liudmira González-Rodríguez, MD; Henry N. Garcia Pacheco, MD; Jaime Graells, MD; Liz Green, MBA; Pernille A. Gregersen, MD;

Nathalia D. A. K. Grigorovski, MD; Koffi M. Guedenon, MD; D. Sanjeeva Gunasekera, MD; Ahmet K. Gündüz, MD; Himika Gupta, MD; Sanjiv Gupta, MS; Theodora Hadjistilianou, MD; Patrick Hamel, MD; Syed A. Hamid, FCPS; Norhafizah Hamzah, MSc; Eric D. Hansen, MD; J. William Harbour, MD; M. Elizabeth Hartnett, MD; Murat Hasanreisoglu, MD; Sadiq Hassan, MD, FWACS; Shadab Hassan, FRCS, FCPS; Stanislava Hederova, MD; Jose Hernandez, MD; Lorelay Marie Carcamo Hernandez, MD; Laila Hessissen, MD; Diriba F. Hordofa, MD; Laura C. Huang, MD; G. B. Hubbard, MD; Marlies Hummlen, MD; Kristina Husakova, MD; Allawi N. Hussein Al-Janabi, MD; Russo Ida, MD; Vesna R. Ilic, MD; Vivekaraj Jairaj, DNB; Irfan Jeeva, FRCOphth; Helen Jenkinson, MD, PhD; Xunda Ji, MD; Dong Hyun Jo, MD, PhD; Kenneth P. Johnson, MD; William J. Johnson, MD; Michael M. Jones, MD, PhD, FRANZCO; Theophile B. Amani Kibesha, MD, PhD; Rolande L. Kabore, MD; Swathi Kaliki, MD; Abubakar Kalinaki, MD; Mehmet Kantar, MD; Ling-Yuh Kao, MD; Tamar Kardava, PhD; Rejin Kebudi, MD; Tomas Kepak, MD; Naama Keren-Froim, BMedSc; Zohora J. Khan, MD; Hussain A. Khaqan, MD; Phara Khauv, MD; Wajih J. Kheir, MD; Vikas Khetan, FRCS; Alireza Khodabande, MD; Zaza Khotenashvili, MD; Jonathan W. Kim, MD; Jeong Hun Kim, MD, PhD; Hayyam Kiratli, MD; Tero T. Kivelä, MD; Artur Klett, MD, PhD; Jess Elio Kosh Komba Palet, MD; Dalia Krivaitiene, MD, PhD; Mariana Kruger, MMedPaed, PhD; Kittisak Kulvichit, MD; Mayasari W. Kuntorini, MD; Alice Kyara, BA; Eva S. Lachmann, MD; Carol P. S. Lam, FCOphth; Geoffrey C. Lam, FRANZCO; Scott A. Larson, MD; Slobodanka Latinović, MD, PhD; Kelly D. Laurenti, MD; Bao Han A. Le, MD; Karin Lecuona, MD; Amy A. Leverant, MD; Cairui Li, MD; Ben Limbu, MD; Quah Boon Long, FRCS(Ed), MMedOphth; Juan P. López, MD; Robert M. Lukamba, MD; Livia Lumbroso, MD; Sandra Luna-Fineman, MD; Delfitri Lutfi, MD; Lesia Lysytsia, MD; George N. Magrath, MD; Amita Mahajan, MD; Abdul Rahim Majeed, MPPA; Erika Maka, MD; Mayuri Makan, MD; Emil K. Makimbetov, MD; Chatonda Manda, MMedOphth; Nieves Martín Begue, MD, PhD; Lauren Mason, MBA; John O. Mason III, MD; Ibrahim O. Matende, MD, MMedOphth; Miguel Materin, MD; Clarissa C. D. S. Mattosinho, MD; Marcelo Matua, BAPh; Ismail Mayet, MD; Freddy B. Mbumba, MD, MMedPaed; John D. McKenzie, MD; Aurora Medina-Sanson, MD, PhD; Azim Mehrvar, MD; Aemero A. Mengesha, MD; Vikas Menon, MD; Gary John V. D. Mercado, MD; Marilyn B. Mets, MD; Edoardo Midená, MD, PhD; Divyansh K. C. Mishra, DNB; Furahini G. Mndeme, MD; Ahmed A. Mohamedani, FRCPath; Mona T. Mohammad, MD, FRCS; Annette C. Moll, MD, PhD; Margarita M. Montero, MD; Rosa A. Morales, MD; Claude Moreira, MD, PhD; Prithvi Mruthyunjaya, MD, MHS; Mchikirwa S. Msina, MMedOphth; Gerald Msukwa, MMedOphth; Sangeeta S. Mudaliar, DNBPediatric; Kangwa I. Muma, MMedOphth, FCOphth; Francis L. Munier, MD; Gabriela Murgoi, MD; Timothy G. Murray, MD, MBA; Kareem O. Musa, FWACS, FMCOPhth, FICO; Asma Mushtaq, MD; Hamzah Mustak, MD; Okwen M. Muyen, MD; Gita Naidu, MMedPaed, PhD; Akshay Gopinathan Nair, MD; Larisa Naumenko, MD, PhD; Paule Aida Ndoye Roth, MD, PhD; Yetty M. Nancy, MD; Vladimir Neroev, MD, PhD; Hang Ngo, MD; Rosa M. Nieves, MD; Marina Nikitovic, MD, PhD; Elizabeth D. Nkanga, FMCOPh; Henry Nkumbe, MD; Murtuza Nuruddin, FRCS; Mutale Nyaywa, MD, MMedOphth, FCOphth; Ghislaine Obono-Obiang, MD; Ngozi C. Oguego, MB, BS, FWASC, FAEH; Andrzej Olechowski, MD; Scott C.

N. Oliver, MD; Peter Osei-Bonsu, MD, FWACS; Diego Ossandon, MD; Manuel A. Paez-Escamilla, MD; Halimah Pagarra, MD, PhD; Sally L. Painter, FRCOphth; Vivian Paintsil, FWACP; Luisa Paiva, MD; Bikramjit P. Pal, FCF, FICO; Mahesh Shanmugam Palanivelu, FRCS(Ed); Ruzanna Pappayan, MD; Raffaele Parrozzani, MD, PhD; Manoj Parulekar, MS, FRCOphth; Claudia R. Pascual Morales, MD; Katherine E. Paton, MD, FRCS; Katarzyna Pawinska-Wasikowska, MD, PhD; Jacob Pe'er, MD; Armando Peña, MD; Sanja Perić, MD, PhD; Chau T. M. Pham, MD; Remezo Philbert, MD; David A. Plager, MD; Pavel Pochop, MD, PhD; Rodrigo A. Polania, MD; Vladimir G. Polyakov, MD; Manca T. Pompe, MD, PhD; Jonathan J. Pons, MD; Daphna Prat, MD; Vireak Prom, MD; Ignatius Purwanto, BS; Ali O. Qadir, MD; Seema Qayyum, FCPS; Jiang Qian, MD; Ardizal Rahman, MD; Salman Rahman, MD; Jamalia Rahmat, MD; Purnima Rajkarnikar, MD; Rajesh Ramanjulu, MD; Aparna Ramasubramanian, MD; Marco A. Ramirez-Ortiz, MD, MPH; Léa Raobela, MD; Riffat Rashid, MS; M. Ashwin Reddy, FRCOphth; Ehud Reich, MD; Lorna A. Renner, FRCPC; David Reynders, MD; Dahiru Ribadu, FMCOPh; Mussagy M. Riheia, MD; Petra Ritter-Soviniz, MD; Duangnate Rojanaporn, MD; Livia Romero, MD; Soma R. Roy, DCO; Raya H. Saab, MD; Svetlana Saakyan, MD, PhD; Ahmed H. Sahban, MD; Mandeep S. Sagoo, FRCS(Ed); Azza M. A. Said, MD; Rohit Saiju, MD; Beatriz Salas, MD; Sonsoles San Román Pacheco, MD; Gissela L. Sánchez, MD; Phayvanh Sayalith, MD; Trish A. Scanlan, MRCPI, MSc; Amy C. Scheffler, MD; Judy Schoeman, MSc; Ahmad Sedaghat, MD; Stefan Seregard, MD, PhD; Rachna Seth, DNB MNAMS; Ankoor S. Shah, MD, PhD; Shawkat A. Shakoork, MS; Manoj K. Sharma, MD; Sadik T. Sherief, MD; Nandan G. Shetye, MS; Carol L. Shields, MD; Sorath Noorani Siddiqui, MD; Sidi Sidi Cheikh, MD, PhD; Sónia Silva, MD; Arun D. Singh, MD; Niharika Singh, MS; Usha Singh, MS; Penny Singha, MD; Rita S. Sitorus, MD, PhD; Alison H. Skalet, MD, PhD; Hendrian D. Soebagjo, MD, PhD; Tetyana Sorochynska, MD, PhD; Grace Ssali, MD; Andrew W. Stacey, MD; Sandra E. Staffieri, PhD; Erin D. Stahl, MD; Christina Stathopoulos, MD; Branka Stir Kranjc, MD, PhD; David K. Stones, MBChB, FCPaed; Caron Strahlendorf, MD; Maria Estela Coleoni Suarez, MD; Sadiya Sultana, FCPS; Xiantao Sun, MD; Meryl Sundy, MD; Rosanne Superstein, MD; Eddy Supriyadi, MD, PhD; Supawan Surukrattanasakul, MD; Shigenobu Suzuki, MD, PhD; Karel Svojcik, MD, PhD; Fatoumata Sylla, MD; Gevorg Tamamyan, MD, PhD; Deborah Tan, MBBS; Alketa Tandili, MD, PhD; Fanny F. Tarrillo Leiva, MD; Maryam Tashvighi, MD; Bekim Tateshi, MD, PhD; Edi S. Tehuteru, MD; Luiz F. Teixeira, MD; Kok Hoi Teh, MD; Tuyisabe Theophile, MSc; Helen Toledano, MBChB; Doan L. Trang, MD; Fousseyni Traoré, MD; Sumalin Trichaiyaporn, MD; Samuray Tuncer, MD; Harba Tyau-Tyau, MD; Ali B. Umar, MD, FMCPath; Emel Unal, MD; Ogul E. Uner, BA; Steen F. Urbak, MD, PhD; Tatiana L. Ushakova, MD; Rustam H. Usmanov, MD; Sandra Valeina, MD; Milo van Hoefen Wijsard, MD; Adisai Varadisai, MD; Liliana Vasquez, MD; Leon O. Vaughan, FRCS(Ed); Nevyana V. Veleva-Krasteva, MD, PhD; Nishant Verma, MD; Andi A. Victor, MD, PhD; Maris Viksnins, MD; Edwin G. Villacis Chafra, MD; Viktoria Vishnevskia-Dai, MD; Tushar Vora, MD; Antonio E. Wachtel, MD; Werner Wackernagel, MD; Keith Waddell, DM, FRCP, FRCOphth; Patricia D. Wade, MBBS; Amina H. Wali, MD, FMCOPh; Yi-Zhuo Wang, MD; Avery Weiss, MD; Matthew W. Wilson, MD; Amelia D. C. Wime, MD; Atchareeya Wiwatwongwana, MD; Damrong Wiwatwongwana, MD; Charlotte Wolley Dod, MD; Phanthipha

Wongwai, MD, PhD; Daoman Xiang, MD, PhD; Yishuang Xiao, MSc; Jason C. Yam, FRCSEd; Huasheng Yang, MD; Jenny M. Yanga, MD; Muhammad A. Yaqub, MD, FCPS, FRCS(Ed); Vera A. Yarovaya, MD; Andrey A. Yarovoy, MD, PhD; Huijing Ye, MD; Yacoub A. Yousef, MD; Putu Yuliawati, MD; Arturo M. Zapata López, MD; Ekhtelbenina Zein, MD; Chengyue Zhang, MD; Yi Zhang, MD, PhD; Junyuan Zhao, MD; Xiaoyu Zheng, MD; Katsiaryna Zhilyaeva, MD; Nida Zia, MBBS, MCPS; Othman A. O. Ziko, MD, PhD; Marcia Zondervan, MBA; Richard Bowman, FRCOphth.

Affiliations of The Global Retinoblastoma Study Group Authors: International Centre for Eye Health, London School of Hygiene & Tropical Medicine, London, United Kingdom (Fabian, Astbury, Bascaran, Foster, Zondervan, Bowman); The Goldschleger Eye Institute, Sheba Medical Center, Tel Hashomer, Tel Aviv University, Tel Aviv, Israel (Fabian, Prat, Vishnevskia-Dai); Ophthalmology Department of Rabat, Mohammed V University, Rabat, Morocco (Abdallah); Aminu Kano Teaching Hospital, Bayero University, Kano, Nigeria (Abdullahi, Sadiq Hassan, Umar); Basra Children's Specialty Hospital, Basra, Iraq (Abdulqader, Al-Shaheen); National Hospital of Niamey, Niamey, Niger (Adamou Boubacar); University of Ilorin Teaching Hospital, University of Ilorin, Ilorin, Nigeria (Ademola-Popoola); Department of Ophthalmology, University of Port Harcourt Teaching Hospital, Port Harcourt, Nigeria (Adio); University of California, San Francisco (Afshar, S. Rahman); Department of Pediatrics, Banaras Hindu University, Varanasi, India (Aggarwal); Department of Ophthalmology, College of Medicine, University of Nigeria, Enugu, Nigeria (Aghaji, Oguego); The Children's Hospital and the Institute of Child Health, Lahore, Pakistan (Ahmad, Mushtaq, Qayyum); RS Dr Wahidin Sudirohusodo, Makassar, Indonesia (Akib, Pagarra); The Royal London Hospital, Barts Health NHS Trust, and Moorfields Eye Hospital NHS Foundation Trust, London, United Kingdom (Al Harby, Reddy); Hawler Medical University, Erbil, Iraq (AI Ani); Zarifa Aliyeva National Center of Ophthalmology, Baku, Azerbaijan (Alakbarova, Balayeva); Department of Pediatric Ophthalmology, Hospital Vall d'Hebron, Barcelona, Spain (Portabella, Martín Begue, Wolley Dod); Pediatric Oncology Unit, Children Welfare Teaching Hospital, College of Medicine, University of Baghdad, Baghdad, Iraq (Al-Badri, Al-Jadiry, Sabhan); Philippine General Hospital, University of the Philippines, Manila, Philippines (Alcasabas, Mercado); College of Medicine, King Saud University, Riyadh, Saudi Arabia (Al-Dahmash, Alkatan); Unidad Nacional de Oncología Pediátrica, Guatemala City, Guatemala (Alejos, Girón); Instituto Cubano de Oftalmología Ramón Pando Ferrer, Marianao, Havana, Cuba (Alemany-Rubio, González-Rodríguez); University of Parakou, Parakou, Benin (Alfa Bio); St Damien Pediatric Hospital, Port-au-Prince, Haiti (Alfonso Carreras, Gassant); Department of Ophthalmology, American University of Beirut Medical Center, Beirut, Lebanon (Al-Haddad); Pediatric Oncology Department, National Oncology Center, Sana'a, Yemen (Al-Hussaini); Pediatric Oncology Department, South Egypt Cancer Institute, Assiut University, Assiut, Egypt (Ali, Elzembely); University Hospital Center Mother Theresa, Tirana, Albania (Alia, Tandili); Imam Hussein Cancer Center, Karbala, Iraq (Al-Jumaly); St Erik Eye Hospital, Stockholm, Sweden (Ali-Eriksson, Seregard); Ibn Al Haitham Teaching Eye Hospital, Baghdad, Iraq (Al-Mafrachi); Beira Central Hospital, Beira, Mozambique (Almeida); Tripoli Eye

Hospital, University of Tripoli, Tripoli, Libya (Alsawidi, Elbahi); Oncology Unit, Child's Central Teaching Hospital, Baghdad, Iraq (Al-Shammari); National Eye Center, Cicendo Eye Hospital, Bandung, Indonesia (Amiruddin, Kuntorini); Bambino Gesù IRCCS Children's Hospital, Rome, Italy (Antonino, Ida); Department of Ophthalmology, School of Medicine, Gazi University, Ankara, Turkey (Atalay, Hasanreisoglu); Siriraj Hospital, Mahidol University, Bangkok, Thailand (Atchaneeyasakul, Buaboonnam); Lighthouse For Christ Eye Centre, Mombasa, Kenya (Atsiaya, Matende); Department of Ophthalmology, Faculty of Medicine, Ramathibodi Hospital, Mahidol University, Bangkok, Thailand (Attaseth, Rojanaporn); Yangon Eye Hospital, University of Medicine 1, Yangon, Myanmar (Aung); Retina Consultants of Houston, Houston, Texas (Ayala, Scheffler); Scientific Center of Pediatrics and Pediatric Surgery, Almaty, Kazakhstan (Baizakova); Pediatric Oncology Unit, Hospital Universitario y Politécnico La Fe, Valencia, Spain (Balaguer, Barranco); Institute of Pediatrics, Jagiellonian University Medical College, Children's University Hospital of Krakow, Krakow, Poland (Balwierz, Pawinska-Wasikowska); Pediatric Hematology-Oncology Unit, Lausanne University Hospital, Lausanne, Switzerland (Beck Popovic); Hospital Nacional de Niños Dr Carlos Sáenz Herrera, San Jose, Costa Rica (Benavides); Department of Pediatric Oncology, University Hassan II Fès, Fez, Morocco (Benmiloud); Center Hospitalier et Universitaire Ibn Rochd, Casablanca, Morocco (Bennani Guebessi, El Kettani); Ophthalmologic Department of the Teaching Hospital of Treichville, Abidjan, Côte d'Ivoire (Berete); Children's Hospital Los Angeles, Keck School of Medicine, University of Southern California, Los Angeles (Berry, J. W. Kim); The Calcutta Medical Research Institute, Kolkata, India (Bhaduri); Department of Pediatric Hematology and Oncology, Narayana Health City, Bangalore, India (Bhat); University of the Witwatersrand, Johannesburg, South Africa (Biddulph, Mayet, Naidu); Department of Ophthalmology, Essen University Hospital, University Duisburg-Essen, Essen, Germany (Biewald, Boehme, Bornfeld); The Filatov Institute of Eye Diseases and Tissue Therapy, Odessa, Ukraine (Bobrova, Sorochynska); Department of Ophthalmology and Visual Sciences, University of Iowa, Iowa City (Boldt, Larson); Hospital das Clínicas da FMUSP, São Paulo, Brazil (Bonanomi); Centre Hospitalier Universitaire Yalgado Ouédraogo de Ouagadougou, Ouagadougou, Burkina Faso (Bouda, Kabore); Institut Hédi Rais d'Ophthalmologie, Faculté de Médecine, Université Tunis El Manar, Tunis, Tunisia (Bougaila); Etablissement Hospitalière Spécialise Emir Abdelkader CEA Service d'Oncologie Pédiatrique, Oran, Algeria (Boumedane); Solid Tumor Division, Department of Oncology, St. Jude Children's Research Hospital, Memphis, Tennessee (Brennan); Cliniques Universitaires Saint-Luc, Brussel, Belgium (Brichard, De Potter); Hospital Infantil Manuel de Jesús Rivera, Managua, Nicaragua (Calderón-Sotelo, Morales); Hospital del Niño Dr. Francisco De Icaza Bustamante, Guayaquil, Ecuador (Calle Jara, Villacís Chafila); Department of Ophthalmology, Queensland Children's Hospital, Brisbane, Queensland, Australia (Camuglia, Gole); Salud Ocular, Ministerio de Salud Publica, Asuncion, Paraguay (Cano); Our Lady's Children's Hospital, Dublin, Ireland (Capra); Institut Curie, Université de Paris Medicine Paris V Descartes, Paris, France (Cassoux); Centro Hospital Universitário de Coimbra, University of Coimbra, Coimbra, Portugal (Castela, Silva); Hospital Pereira Rossell, Montevideo, Uruguay (Castillo); Hospital Sant Joan de Déu,

Barcelona, Spain (Català-Mora, Chantada, Correa Llano); Hospital Garrahan, Buenos Aires, Argentina (Chantada, Fandiño); National Scientific and Technical Research Council, CONICET, Buenos Aires, Argentina (Chantada); Paediatric Ophthalmology Department, Mayo Hospital and College of Allied Visual Sciences, King Edward Medical University, Lahore, Pakistan (Chaudhry); Department of Ophthalmic Plastic Surgery, Orbit and Ocular Oncology, PBMA's H. V. Desai Eye Hospital, Pune, Maharashtra, India (Chaugule); University of Louisville, Louisville, Kentucky (Chauhan, Ramasubramanian); Ocular Oncology Service, Dr Rajendra Prasad Centre for Ophthalmic Sciences, All India Institute of Medical Sciences, New Delhi, India (Chawla); Eye Clinic, Department of Ophthalmology, University Hospital Alexandrovska, Medical University, Sofia, Sofia, Bulgaria (Chernodirska, Veleva-Krasteva); Muhimbili National Hospital, Dar es Salaam, Tanzania (Chiwanga, Kyara, Scalan); National Center for Maternal and Children Health of Mongolia, Ulaanbaatar, Mongolia (Chuluunbat); Department of Ophthalmology, The Children's Memorial Health Institute, Warsaw, Poland (Cieslik, Olechowski); Starship Children's Health, Auckland, New Zealand (Cockcroft); Institute of Oncology, Prof. Dr Al. Trestioreanu, Bucharest, Romania (Comsa, Dragomir, Murgoi); Wilmer Eye Institute, Johns Hopkins Medicine, Baltimore, Maryland, and University of Cincinnati College of Medicine, Cincinnati, Ohio (Correa); Indiana University Medical Center, Indianapolis (Corson, Plager); Bustamante Hospital for Children, Kingston, Jamaica (Cowan-Lyn, Vaughan); Semmelweis University, Budapest, Hungary (Csóka, Maki); Department of Ophthalmology, Xinhua Hospital, Shanghai Jiao Tong University School of Medicine, Shanghai, China (Cui, Ji); Quelimane Central Hospital, Quelimane, Mozambique (Da Gama); Department of Ophthalmology, Songklanagarind Hospital, Prince of Songkla University, Songkla, Thailand (Dangboon, Singha); Department of Pediatric Hematology-Oncology, Tata Medical Center, Kolkata, India (A. Das); Ocular Oncology Services, Dr Shroff's Charity Eye Hospital, New Delhi, India (S. Das); Cole Eye Institute, Cleveland Clinic, Cleveland, Ohio (Davanzo, A. D. Singh); Red Cross War Memorial Children's Hospital and the University of Cape Town, Cape Town, South Africa (Davidson); National Children's Hospital, Panama City, Panama (Delgado, L. M. C. Hernandez); Department of Ophthalmology, Kellogg Eye Center, University of Michigan, Ann Arbor (Demirci); Institut Curie, Paris, France (Desjardins, Lumbroso); Instituto Nacional de Enfermedades Neoplásicas, Lima, Perú (Diaz Coronado, Wachtel, Zapata López); The Hospital for Sick Children, Toronto, Ontario, Canada (Dimaras, Gallie); Department of Paediatrics, University of Otago, Christchurch, Children's Haematology and Oncology Center, Christchurch Hospital, Christchurch, New Zealand (Dodgshun); The Children's Hospital at Westmead, Sydney, New South Wales, Australia (Donaldson, Jones); Pediatric Oncology Institute, Federal University of São Paulo, São Paulo, Brazil (Donato Macedo, Teixeira); Department of Ophthalmology, The First Affiliated Hospital of Guangxi Medical University, Nanning, China (Du); University of KwaZulu-Natal, Durban, South Africa (Du Bruyn); Ophthalmology Department, Dr M. Djamil General Hospital, Faculty of Medicine, Andalas University, West Sumatra, Indonesia (Edison, A. Rahman); Department of Ophthalmology, Faculty of Medicine, Udayana University, Sanglah Eye

Hospital, Bali, Indonesia (Eka Sutyawan, Yuliawati); Department of Ophthalmology, Royal Children's Hospital, Parkville, Victoria, Australia (Elder, McKenzie, Staffieri); Department of Paediatrics, Melbourne Medical School, University of Melbourne, Parkville, Victoria, Australia (Elder); Children's Cancer Hospital Egypt 57357, Cairo, Egypt (Elgalaly, Elhaddad); Department of Oncology, National Cancer Institute, University of Gezira, Wadi Madani, Sudan (Elhassan); Ophthalmology Unit, Department of Surgery, School of Medicine and Dentistry, University of Ghana, Accra, Ghana (Essuman); Magrabi ICO Cameroon Eye Institute, Yaounde, Cameroon (Egina, Nkumbe); Aga Khan University, Karachi, Pakistan (Fadoo, Jeeva); Pediatric Growth and Development Research Center, Institute of Endocrinology and Metabolism, Iran University of Medical Sciences, Rasool Akram Hospital, Tehran, Iran (Faranoush); Department of Ophthalmology, University College Hospital, University of Ibadan, Ibadan, Nigeria (Fasina); Mi Clinic, Ciudad del Este, Paraguay (Fernández); Hospital Universitario Virgen Macarena, Sevilla, Spain (Fernández-Teijeiro); Hadassah Medical Center, Hebrew University of Jerusalem, Jerusalem, Israel (Frenkel, Pe'er); Hospital Escuela, Tegucigalpa, Honduras (Fu, Peña); Pediatric Oncology Department, Benjamin Bloom National Children's Hospital, San Salvador, El Salvador (Fuentes-Alabi, Goenz); Lions Sight First Eye Hospital, Queen Elizabeth Central Hospital, Blantyre, Malawi (Gandiwa, Manda, Msukwa); Clínica Anglo American, Lima, Perú (García); Servicio Andaluz de Salud, Sevilla, Spain (García Aldana); Charlotte Maxeke Johannesburg Academic Hospital, Johannesburg, South Africa (Geel); Retina and Vitreous Service, Farabi Eye Hospital, Tehran University of Medical Sciences, Tehran, Iran (Ghassemi, Khodabande); Department of Ophthalmology, School of Medicine, Addis Ababa University, Addis Ababa, Ethiopia (Gizachew, Sherief); Murray Ocular Oncology and Retina, Miami, Florida (Gold, Murray); Sackler Faculty of Medicine, Tel Aviv University, Tel Aviv, Israel (Goldberg-Lavid, Keren-Froim); Department of Ophthalmology, Sourasky Medical Center Tel Aviv, School of Medicine, Sackler Faculty of Medicine, Tel Aviv University, Tel Aviv, Israel (Gomel); Department of Ophthalmology, Boston Children's Hospital and Harvard Medical School, Boston, Massachusetts (Gonzalez, Shah); Hospital Civil de Guadalajara, Guadalajara, Mexico (Gonzalez Perez); Pediatric Oncology Unit, Instituto Regional de Enfermedades Neoplásicas del Sur, Arequipa, Perú (García Pacheco); Unidad de Oncología Ocular Hospital Oncológico Luis Razzetti, Caracas, Venezuela (Graells, Romero); IAM NOOR Eye Care Programme, Afghanistan (Green, Majeed); Department of Clinical Genetics and Center for Rare Disorders, Aarhus University Hospital, Aarhus, Denmark (Gregersen); National Cancer Institute, Rio de Janeiro, Brazil (Grigorovski, Mattosinho); Département de Pédiatrie, CHU Sylvanus Olympio, Université de Lomé, Lomé, Togo (Guedenon); National Cancer Institute, Maharagama, Sri Lanka (Gunasekera); Department of Ophthalmology, Ankara University School of Medicine, Ankara, Turkey (Gündüz); Bai Jerbai Wadia Hospital for Children, Mumbai, India (H. Gupta, Mudaliar); King George's Medical University, Lucknow, India (S. Gupta, Verma); Retinoblastoma Referral Center, University of Siena, Siena, Italy (Hadjjistilianou); Centre Hospitalier Universitaire Sainte-Justine, University of Montreal, Montréal, Quebec, Canada (Hamel, Superstein); The Indus Hospital, Karachi, Pakistan (Hamid, Zia); Hospital

Kuala Lumpur, Kuala Lumpur, Malaysia (Hamzah, Rahmat, Teh); John A. Moran Eye Center, University of Utah, Salt Lake City (Hansen, Hartnett); Bascom Palmer Eye Institute, University of Miami Miller School of Medicine, Miami, Florida (Harbour, Paez-Escamilla); Department of Pediatric Ophthalmology and Strabismus, Al Shifa Trust Eye Hospital, Rawalpindi, Pakistan (Shadab Hassan, Siddiqui); University Children's Hospital, Bratislava, Slovakia (Hederova, Husakova); Hospital Nacional Guillermo Almenara Irgoyen, Lima, Perú (J. Hernandez, Pascual Morales); Pediatric Hematology and Oncology Center, Mohammed V University, Rabat, Morocco (Hessissen); Department of Pediatrics and Child Health, Jimma University Medical Center, Jimma, Ethiopia (Hordofa); Byers Eye Institute, Stanford University, Stanford, California (Huang, Mruthyunjaya); Emory Eye Center, Atlanta, Georgia (Hubbard, Uner); Department of Ophthalmology, Oslo University Hospital, Oslo, Norway (Hummlen); Oncology Unit, Child's Central Teaching Hospital, Baghdad, Iraq (Hussein Al-Janabi); Institute for Oncology and Radiology of Serbia, Belgrade, Serbia (Ilic, Nikitovic); Pacific International Hospital, Port Moresby, Papua New Guinea (Jairaj); Eye Department, Birmingham Children's Hospital, Birmingham Women's and Children's NHS Foundation Trust, Birmingham, United Kingdom (Jenkinson, Painter, Parulekar); Fight Against Angiogenesis-Related Blindness Laboratory, Biomedical Research Institute, Seoul National University Hospital, Seoul, Republic of Korea (Jo); Clínica Oftalmológica Pasteur, Santiago, Chile (K. P. Johnson); Storm Eye Institute, Medical University of South Carolina, Charleston (W. J. Johnson, Magrath); Bukavu Eye Clinic, Bukavu Official University, Bukavu, Democratic Republic of the Congo (Kabasha); Operation Eyesight Universal Institute for Eye Cancer, L V Prasad Eye Institute, Hyderabad, India (Kaliki); Department of Ophthalmology, Makerere University College of Health Sciences Kampala, Uganda (Kalinaki); Division of Pediatric Oncology, School of Medicine, Ege University, Izmir, Turkey (Kantar); Chang Gung Memorial Hospital, Taipei, Taiwan (Kao); Ophthalmology Department, Central Children's Hospital of Georgia, Tbilisi, Georgia (Kardava, Khotenashvili); Division of Pediatric Hematology-Oncology, Department of Pediatrics, Cerrahpaşa Faculty of Medicine and Oncology Institute, Istanbul University, Istanbul, Turkey (Kebudi); St. Anne's University Hospital Brno, Masaryk University, and International Clinical Research Center/St Anna University Hospital, Brno, Czech Republic (Kepak); Dhaka Medical College Hospital, Dhaka, Bangladesh (Khan); Department of Ophthalmology, Postgraduate Medical Institute, Ameer-Ud-Din Medical College, Lahore General Hospital, Lahore, Pakistan (Khaqan); Angkor Hospital for Children, Krong Siem Reap, Cambodia (Khauv); Duke Eye Center, Duke University Hospital, Durham, North Carolina (Kheir, Materin); Sankara Nethralaya, Chennai, India (Khetan, Prom, N. Singh); Department of Ophthalmology, Seoul National University Hospital, Seoul, Republic of Korea (J. H. Kim); Ocular Oncology Service, Department of Ophthalmology, Hacettepe University School of Medicine, Ankara, Turkey (Kiratli); Ocular Oncology Service, Department of Ophthalmology, Helsinki University Hospital, University of Helsinki, Helsinki, Finland (Kivelä); East Tallinn Central Hospital, Tallinn, Estonia (Klett); Oncologue Pédiatre Responsable d'Unité de Bangui, Bangui, Central African Republic (Komba

Palet); Children's Ophthalmology Department, Children's Hospital of Vilnius, University Hospital Santaros Clinic, Vilnius, Lithuania (Krivaiteiene); Department of Paediatrics and Child Health, Faculty of Medicine and Health Sciences, Stellenbosch University, Stellenbosch, South Africa (Kruger); Vitreo-Retina Research Unit, Department of Ophthalmology, Chulalongkorn University, Bangkok, Thailand (Kulvichit, Varadisa); University Medical Center Hamburg-Eppendorf, Hamburg, Germany (Lachmann); Hong Kong Eye Hospital, Chinese University of Hong Kong, Hong Kong SAR, China (C. P. S. Lam, Yam); Perth Children's Hospital, University of Western Australia, Perth, Western Australia, Australia (G. C. Lam); Clinical Center of Vojvodina, University Eye Clinic, Eye Research Foundation Vidar-Latinović, Novi Sad, Serbia (Latinović); Division of Ophthalmology, Feinberg School of Medicine, Northwestern University, and Ann & Robert H. Lurie Children's Hospital of Chicago, Chicago, Illinois (Laurenti, Mets); John A. Burns School of Medicine, University of Hawaii, Honolulu, and University of Southern California Roski Eye Institute, Los Angeles (Le); Division of Ophthalmology, Faculty of Health Sciences, University of Cape Town, Cape Town, South Africa (Lecuona, Mustak); Phoenix Children's Hospital, Phoenix, Arizona (Leverant); Affiliated Hospital of Dali University, Dali City, China (Li); Tilganga Institute of Ophthalmology, Kathmandu, Nepal (Limbu, Rajkarnikar, Saiju); Singapore National Eye Center, Singapore, Singapore (Long, Tan); Ophthalmology Department, Faculty of Medicine, Universidad de Chile, Santiago, Chile (López); University Clinics of Lubumbashi, University of Lubumbashi, Lubumbashi, Democratic Republic of Congo (Lukamba); Pediatric Hematology/Oncology/Stem Cell Transplantation, Center for Global Health, Children's Hospital Colorado, University of Colorado, Aurora (Luna-Fineman); Department of Ophthalmology, Dr Soetomo General Hospital, Airlangga University, Surabaya, Indonesia (Lutfi, Soebagjo); Okhmatdyt National Children's Hospital, Kiev, Ukraine (Lysytsia); Pediatric Hematology-Oncology Unit, Apollo Center for Advanced Pediatrics, Indraprastha Apollo Hospital, New Delhi, India (Mahajan); Sekuru Kaguvi Eye Unit, Parienyatwa Group of Hospitals, Harare, Zimbabwe (Makan); National Center of Oncology and Hematology, Bishkek, Kyrgyzstan (Makimbetov); University of Alabama at Birmingham, Birmingham (L. Mason, J. O. Mason III); Ruharo Eye Centre, Ruharo Mission Hospital, Mbarara, Uganda (Matua, Waddell); Scottish Livingstone Hospital, Molepolole, Botswana (Mbumba); Department of Ocular Oncology, Royal Victorian Eye and Ear Hospital, East Melbourne, Victoria, Australia (McKenzie); Department of Oncology, Hospital Infantil de México Federico Gómez, Mexico City, Mexico (Medina-Sanson); MAHAK Hematology Oncology Research Center, Mahak Hospital, Tehran, Iran (Mehrvan, Tashvighi); Department of Ophthalmology, Jimma University, Jimma, Ethiopia (Mengesha); Centre for Sight, New Delhi, India (Menon); Department of Ophthalmology, University of Padova, Padova, Italy (Midena, Parrozzani); Sankara Eye Hospital, Bangalore, India (Mishra, Palanivelu, Ramanjulu); Kilimanjaro Christian Medical Centre, Moshi, Tanzania (Mndeme, Msina); Department of Pathology, Faculty of Medicine, University of Gezira, Wad Medani, Sudan (Mohamedani); King Hussein Cancer Center, Amman, Jordan (Mohammad, Yousef); Department of Ophthalmology, Amsterdam UMC, Amsterdam, the Netherlands (Moll, van Hoefen Wijsard); Hospital

Infantil Dr Robert Reid Cabral, Santo Domingo, Dominican Republic (Montero, Nieves); Service d'Oncologie Pédiatrique de l'Hôpital Aristide le Dantec, Dakar, Senegal (Moreira); Ministry of Health, Lusaka, Zambia (Muma); Jules-Gonin Eye Hospital, Fondation Asile des Aveugles, University of Lausanne, Lausanne, Switzerland (Munier, Stathopoulos); Department of Ophthalmology, Lagos University Teaching Hospital, College of Medicine of the University of Lagos, Lagos, Nigeria (Musa); Abii Specialists Hospital, Bamenda, Cameroon (Muyen); Aditya Jyot Eye Hospital, Mumbai, India (Nair); Lokmanya Tilak Municipal General Hospital and Medical College, Mumbai, India (Nair); N.N. Alexandrov National Cancer Centre of Belarus, Minsk, Belarus (Naumenko, Zhilyaeva); Cheikh Anta Diop University, Le Dantec Hospital, Dakar, Senegal (Ndoye Roth); Child Health Department, Faculty of Medicine, Diponegoro University, Semarang, Indonesia (Nency); Moscow Helmholtz Research Institute of Eye Diseases, Moscow, Russia (Neroev, Saakyan); Ho Chi Minh Eye Hospital, Ho Chi Minh, Vietnam (Ngo); Department of Ophthalmology, Calabar Children's Eye Center, University of Calabar Teaching Hospital, Calabar Nigeria (Nkanga); Chittagong Eye Infirmary and Training Complex, Chittagong, Bangladesh (Nuruddin, Roy); Arthur Davison Children's Hospital, Ndola, Zambia (Nyaywa); CHU Angondien Cancerologie, Libreville, Gabon (Obono-Obiang); Sue Anschutz-Rodgers Eye Center, University of Colorado School of Medicine, Aurora (Oliver); Komfo Anokye Teaching Hospital, Kumasi, Ghana (Osei-Bonsu, Paintsil); Clínica Alemana de Santiago, Universidad del Desarrollo, Santiago, Chile (Ossandon); National Ophthalmological Institute of Angola, Luanda, Angola (Paiva, Wime); H M Diwan Eye Foundation, and Tata Medical Center, Kolkata, India (Pal); Department of Oncology, Yerevan State Medical University, and Pediatric Cancer and Blood Disorders Center of Armenia, Hematology Center after R. H. Yeolyan, Yerevan, Armenia (Papyan, Tamamyanyan); University of British Columbia, Vancouver, British Columbia, Canada (Paton); University Hospital Center Zagreb, Zagreb, Croatia (Perić); Vietnam National Institute of Ophthalmology, Ha Noi, Vietnam (Pham, Trang); Centre Hospitalier Universitaire de Kamenge, Bujumbura, Burundi (Philbert); Department of Ophthalmology for Children and Adults, Second Faculty of Medicine, Charles University, and Motol University Hospital, Prague, Czech Republic (Pochop); Fundacion Clinica Valle del Lili, Cali, Colombia (Polania); Head and Neck Tumors Department, SRI of Pediatric Oncology and Hematology, N.N. Blokhin Russian Cancer Research Center, Moscow, Russia (Polyakov, Ushakova); Russian Medical Academy of Postgraduate Education, Moscow, Russia (Polyakov, Ushakova); University Eye Hospital Ljubljana, University Medical Center Ljubljana, Ljubljana, Slovenia (Pompe, Stirn Kranjc); Good Shepherd Hospital, Siteki, Swaziland (Pons); Sardjito Hospital, Faculty of Medicine, Universitas Gadjah Mada, Yogyakarta, Indonesia (Purwanto, Supriyadi); Hiwa Cancer Hospital, Sulaymaniyah, Iraq (Qadir); Department of Ophthalmology, Eye and Ear, Nose, and Throat Hospital of Fudan University, Shanghai, China (Qian); Department of Ophthalmology, Hospital Infantil de Mexico Federico Gómez, Mexico City, Mexico (Ramirez-Ortiz); Centre Hospitalier Universitaire Joseph Ravoahangy Andrianavalona, Antananarivo, Madagascar (Raobela); Department of Oculoplasty and Ocular Oncology, Ispahani Islamiya Eye Institute and Hospital, Dhaka, Bangladesh (Rashid, Sultana); Department of

Ophthalmology, Davidoff Center for Oncology, Rabin Medical Center, Sackler School of Medicine, Tel Aviv University, Israel (Reich); School of Medicine and Dentistry, Korle-Bu Teaching Hospital, University of Ghana, Accra, Ghana (Renner); University of Pretoria, Pretoria, South Africa (Reynders, Schoeman); Federal Medical Center, Yola, Nigeria (Ribadu); Nampula Central Hospital, Nampula, Mozambique (Rihea); Division of Pediatric Hematology and Oncology, Department of Pediatrics and Adolescent Medicine, Medical University of Graz, Graz, Austria (Ritter-Sovinz); Children's Cancer Institute, American University of Beirut Medical Center, Beirut, Lebanon (Saab); NIH Biomedical Research Centre for Ophthalmology, Moorfields Eye Hospital, and UCL Institute of Ophthalmology and London Retinoblastoma Service, Royal London Hospital, London, United Kingdom (Sagoo); Department of Ophthalmology, Faculty of Medicine, Ain Shams University, Cairo, Egypt (Said, Ziko); Hospital Dr Manuel Ascencio Villarreal, Cochabamba, Bolivia (Salas); Pediatric Hemato-Oncology, Hospital Universitario Infantil La Paz, Madrid, Spain (San Román Pacheco); Hospital Solca Quito, Quito, Ecuador (Sánchez); Mahosot Hospital, Vientiane, Laos (Sayalith); Department of Ophthalmology, Rasool Akram Hospital, Tehran, Iran (Sedaghat); Department of Pediatrics, All India Institute of Medical Sciences, New Delhi, India (Seth); National Institute of Ophthalmology, Dhaka, Bangladesh (Shakoor); East Timor Eye Program, Dili, Timor-Leste (Sharma); Tata Memorial Hospital, Mumbai, India (Shetye, Vora); Ocular Oncology Service, Wills Eye Hospital, Thomas Jefferson University, Philadelphia, Pennsylvania (Shields); Ophthalmology Department, Nouakchott Medical University, Nouakchott, Mauritania (Sidi Cheikh); Department of Ophthalmology, Postgraduate Institute of Medical Education and Research, Chandigarh, India (U. Singh); Department of Ophthalmology, Faculty of Medicine, Universitas Indonesia, and Dr Cipto Mangunkusumo National General Hospital, Jakarta, Indonesia (Sitorus, Victor); Casey Eye Institute, Oregon Health & Science University, Portland (Skalet, Sundy); Mulago National Referral Hospital, Kampala, Uganda (Ssali); Department of Ophthalmology, University of Washington, Seattle (Stacey, Weiss); Centre for Eye Research Australia, University of Melbourne, East Melbourne, Victoria, Australia (Staffieri); Children's Mercy Hospital, Kansas City, Missouri (Stahl); Department of Paediatrics and Child Health, University of the Free State, Bloemfontein, South Africa (Stones); BC Children's Hospital, Vancouver, British Columbia, Canada (Strahlendorf); Pediatra Hemato-Oncologia, Instituto Oncologico del Oriente Boliviano, Santa Cruz de la Sierra, Bolivia (Suarez); Henan Children's Hospital, Affiliated Children's Hospital of Zhengzhou University, Zhengzhou, China (Sun); Queen Sirikit National Institute of Child Health, Bangkok, Thailand (Surukrattanasakul, Trichaiyaporn); Department of Ophthalmic Oncology, National Cancer Center Hospital, Tokyo, Japan (Suzuki); Department of Pediatric Hematology and Oncology, Second Faculty of Medicine, Charles University, Motol University Hospital, Prague, Czech Republic (Svojgr); Africa Institute of Tropical Ophthalmology, Bamako, Mali (Sylla); Hospital Nacional Edgardo Rebagliati Martins, Lima, Perú (Tarrillo Leiva, Vasquez); University Eye Clinic, Skopje, Macedonia (Tateshi); National Cancer Center, Dharmas Cancer Hospital, Jakarta, Indonesia (Tehuteru); Ophthalmology Department, Federal University of São Paulo, São Paulo, Brazil (Teixeira); Kabgayi Eye Unit, Gitarama,

Rwanda (Theophile); Department of Pediatric Hematology-Oncology, Schneider Children's Medical Center, Sackler School of Medicine, Tel Aviv University, Tel Aviv, Israel (Toledano); Pediatric Oncology Service, Gabriel Toure Hospital, Bamako, Mali (Traoré); Department of Ophthalmology, Faculty of Medicine, Ocular Oncology Service, Istanbul University, Istanbul, Turkey (Tuncer); Université Adam Barka, Abeche, Chad (Tyau-Tyau); Division of Pediatric Hematology-Oncology, Department of Pediatrics, Ankara University, Ankara, Turkey (Unal); Department of Ophthalmology, Aarhus University Hospital, Aarhus, Denmark (Urbak); National Cancer Center of Uzbekistan, Tashkent, Uzbekistan (Usmanov); Children's Clinical University Hospital, Riga, Latvia (Valeina, Viksnins); Department of Ophthalmology, Medical University of Graz, Graz, Austria (Wackernagel); Jos University Teaching Hospital, Jos, Nigeria (Wade); National Eye Center Kaduna, Kaduna, Nigeria (Wali); Department of Paediatrics, Beijing Tongren Hospital, Capital Medical University, Beijing, China (Wang, Y. Zhang); Department of Surgery, St Jude Children's Research Hospital, Memphis, Tennessee (Wilson); Department of Ophthalmology, Chiang Mai University, Chiang Mai, Thailand (A. Wiwatwongwana, D. Wiwatwongwana); Department of Ophthalmology, Faculty of Medicine, Khon Kaen University, Khon Kaen, Thailand (Wongwai); Department of Pediatric Ophthalmology, Guangzhou Children's Hospital and Guangzhou Women and Children's Medical Center, Guangzhou Medical University, Guangzhou, China (Xiang); Kunming Children's Hospital, Kunming, China (Xiao); State Key Laboratory of Ophthalmology, Zhongshan Ophthalmic Center, Sun Yat-sen University, Guangzhou, China (Yang, Ye); Service d'Ophthalmologie, Cliniques Universitaires de Kinshasa, Université de Kinshasa, Kinshasa, Democratic Republic of Congo (Yanga); Armed Forces Institute of Ophthalmology, Rawalpindi, Pakistan (Yaqub); S.Fyodorov Eye Microsurgery Federal State Institution, Moscow, Russia (Yarovaya, Yarovoy); Assistante Hospitalo Universitaire, Faculté de Médecine de Nouakchott Medecin Oncopédiatre, Center National d'Oncologie, Nouakchott, Mauritania (Zein); Department of Ophthalmology, Beijing Children's Hospital, Capital Medical University, Beijing, China (C. Zhang, Zhao); Department of Ophthalmology, Children's Hospital, Zhejiang University School of Medicine, Hangzhou, China (Zheng); Ophthalmology Department, Great Ormond Street Hospital, London, United Kingdom (Bowman).

Author Contributions: Dr Fabian had full access to all of the data in the study and takes responsibility for the integrity of the data and the accuracy of the data analysis. All coauthors approved the final version for publication.

Study concept and design: Fabian, Foster, Bowman.
Acquisition, analysis, or interpretation of data: All authors.

Drafting of the manuscript: Fabian, Bascaran, Chantada, Dimaras, Foster, Khetan, Kivela, Reddy, Sagoo, Stacey, Zondervan, Bowman.

Critical revision of the manuscript for important intellectual content: All authors.

Statistical analysis: Stacey.

Conflict of Interest Disclosures: Dr Berry reports receiving grants from National Cancer Institute (K08CA232344), Wright Foundation, Knights Templar Eye Foundation, American Cancer Society, Hyundai Hope on Wheels, and Childhood Eye Cancer Trust, as well as nonfinancial support from Institute for Families, The Larry and Celia Moh

Foundation, and Research to Prevent Blindness. Dr Correa reports receiving personal fees from Castle Biosciences and Immunocore. Dr Diaz Coronado reports receiving support from Merck Sharp & Dohme. Dr Demirci reports receiving support Castle Biosciences and Immunocore. Dr Foster reports receiving grants from the Queen Elizabeth Diamond Jubilee Trust. Dr Gold reports receiving personal fees from Regeneron. Dr Harbour reports receiving royalties and other support from Castle Biosciences. Dr Hartnett reports receiving grants from the National Eye Institute; having a patent issued and a patent pending related to her work in eye care; receiving honoraria from Wolters Kluwer as editor in chief of the textbook *Pediatric Retina Disease, Second Edition*; receiving honoraria for academic lectures at the University of Alabama at Birmingham, Michigan State University, University of Florida, University of Iowa, Ohio State University, Indiana University, Cole Eye Institute, Scheie Eye Institute, Massachusetts Eye and Ear, and University of Colorado; and receiving paid trips to consult for the National Eye Institute's National Advisory Eye Council and for grant review for the Knights Templar Eye Foundation. Dr Kivela reports receiving personal fees from Santen. Dr Materin reports receiving personal fees from IDEAYA Biosciences and Castle Biosciences. Dr Nair reports receiving personal fees from HelpMeSee and Carl Zeiss Meditec. Dr Oliver reports receiving grants from Roche. Dr Skalet reports receiving support as a consultant from Castle Biosciences and Immunocore. Dr Soebagjo reports rights to 2 licensed patents. Dr Stahl reports receiving personal fees from Avedo and nonfinancial support from Sydnexis.

Funding/Support: This work was supported by the Queen Elizabeth Diamond Jubilee Trust.

Role of the Funder/Sponsor: The funder had no role in the design and conduct of the study; collection, management, analysis, and interpretation of the data; preparation, review, or approval of the manuscript; and decision to submit the manuscript for publication. The funder assisted in institutional review board application fees for selected retinoblastoma centers from low-income countries.

Additional Contributions: We thank the following contributors for assisting in the creation of the global network: Malakhova Alina, Yuriy Serov, and Olga Yugay from N. N. Blokhin National Medical Research Center of Oncology in Moscow, Russia; Syuzanna Tadevosyan from Helmholtz Moscow Research Institute of Eye Diseases in Moscow, Russia; George Ramappa from LV Prasad Eye Institute in Hyderabad, India; Friska Mardianti from Cicendo Eye Hospital in Bandung, Jawa Barat, Indonesia; Daniel Getaneh and Bethelhem Sileshi from Menelik II Hospital in Addis Ababa, Ethiopia; Mostafizur Rahman and Mastura Khatun from Ispahani Islamiya Eye Institute and Hospital in Dhaka, Bangladesh; Alenka Lavric Groznik from University Eye Clinic, Ljubljana in Ljubljana, Slovenia; Layal Bayram from Children's Cancer Center of Lebanon in Beirut, Lebanon; Narjes Mehrvar from MAHAK Children Hospital in Tehran, Iran; Chinsisi Myirenda, Catherine Lunduka, and George Chagaluka from Lions Sight First Eye Hospital, Queen Elizabeth Central Hospital in Blantyre, Malawi; Suganeswari Ganesan and Pukhraj Rishi from Sankara Nethralaya in Chennai, India; Dyna Pixtún Borrayo from Unidad Nacional de Oncología Pediátrica in Guatemala City,

Guatemala; Wayne Nicholls and Timothy Hassall from Queensland Children's Hospital in South Brisbane, Queensland, Australia; Suradej Hongeng, Rangsim Aroonroch, and Sirintara Singhara Na Ayudhaya from Ramathibodi Hospital in Bangkok, Thailand; Nutsuchar Wangtiramuay and Sirin Lueangaram from Queen Sirikit National Institute of Child Health in Bangkok, Thailand; Lalita Sathitsamitphong from Maharaj Nakorn Chiang Mai Hospital in Chiang Mai, Thailand; Supaporn Tengtrisorn from Songklanagarind Hospital in Songkhla, Thailand; Patcharee Komvilaisak from Srinagarind Hospital in Khon Kaen, Thailand; Hamid Razi from Farabi Eye Hospital in Tehran, Iran; Christopher Tinley and Nicola Freeman from Red Cross War Memorial Children's Hospital in Cape Town, South Africa; Irmela Marie Erdmann from Christian Blind Mission in West Africa; James Muecke from Sight For All in Adelaide, South Australia, Australia; John Onyango from Mbarara Regional Referral Hospital in Mbarara, Uganda; Michael Belkin from Tel-Aviv University in Tel Aviv, Israel; Ibrahim Qaddoumi from St. Jude Children's Research Hospital in Memphis, Tennessee; Timothy Garrington from Children's Hospital Colorado in Aurora, Colorado; Alon Skaat and Michael Kinori from Goldschleger Eye Institute in Tel HaShomer, Israel; and the New Zealand Child Cancer Registry. We also thank Abdoulaye Barnabas from Université Adam Barka in Abèchè, Chad, who treated children with retinoblastoma in Chad and collected data for the study but died in September 2019. They were not compensated for their contributions.

Additional Information: All authors comply with International Committee of Medical Journal Editors criteria for authorship. Second to before last coauthors are listed in alphabetical order.

REFERENCES

- MacCarthy A, Birch JM, Draper GJ, et al. Retinoblastoma: treatment and survival in Great Britain 1963 to 2002. *Br J Ophthalmol*. 2009;93(1):38-39. doi:10.1136/bjo.2008.139626
- Munier FL, Mosimann P, Puccinelli F, et al. First-line intra-arterial versus intravenous chemotherapy in unilateral sporadic group D retinoblastoma: evidence of better visual outcomes, ocular survival and shorter time to success with intra-arterial delivery from retrospective review of 20 years of treatment. *Br J Ophthalmol*. 2017;101(8):1086-1093. doi:10.1136/bjophthalmol-2016-309298
- Fernandes AG, Pollock BD, Rabito FA. Retinoblastoma in the United States: a 40-year incidence and survival analysis. *J Pediatr Ophthalmol Strabismus*. 2018;55(3):182-188. doi:10.3928/01913913-20171116-03
- Fabian ID, Onadim Z, Karaa E, et al. The management of retinoblastoma. *Oncogene*. 2018;37(12):1551-1560. doi:10.1038/s41388-017-0050-x
- Yamane T, Kaneko A, Mohri M. The technique of ophthalmic arterial infusion therapy for patients with intraocular retinoblastoma. *Int J Clin Oncol*. 2004;9(2):69-73. doi:10.1007/s10147-004-0392-6
- Munier FL, Gaillard M-C, Balmer A, et al. Intravitreal chemotherapy for vitreous disease in retinoblastoma revisited: from prohibition to conditional indications. *Br J Ophthalmol*. 2012;96(8):1078-1083. doi:10.1136/bjophthalmol-2011-301450
- Fabian ID, Naeem Z, Stacey AW, et al. Long-term visual acuity, strabismus, and nystagmus outcomes following multimodality treatment in group D retinoblastoma eyes. *Am J Ophthalmol*. 2017;179:137-144. doi:10.1016/j.ajo.2017.05.003
- Chantada G, Fandiño A, Manzitti J, Urrutia L, Schwartzman E. Late diagnosis of retinoblastoma in a developing country. *Arch Dis Child*. 1999;80(2):171-174. doi:10.1136/adc.80.2.171
- Chawla B, Hasan F, Azad R, et al. Clinical presentation and survival of retinoblastoma in Indian children. *Br J Ophthalmol*. 2016;100(2):172-178. doi:10.1136/bjophthalmol-2015-306672
- Nyamori JM, Kimani K, Njuguna MW, Dimaras H. Retinoblastoma referral pattern in Kenya. *Middle East Afr J Ophthalmol*. 2014;21(4):321-327. doi:10.4103/0974-9233.142270
- Canturk S, Qaddoumi I, Khetan V, et al. Survival of retinoblastoma in less-developed countries: impact of socioeconomic and health-related indicators. *Br J Ophthalmol*. 2010;94(11):1432-1436. doi:10.1136/bjo.2009.168062
- Bowman R. Retinoblastoma: a curable, rare and deadly blinding disease. *Community Eye Health*. 2018;31(101):1-4.
- Vandenbroucke JP, von Elm E, Altman DG, et al; STROBE Initiative. Strengthening the Reporting of Observational Studies in Epidemiology (STROBE): explanation and elaboration. *Int J Surg*. 2014;12(12):1500-1524. doi:10.1016/j.ijsu.2014.07.014
- Mallipatna AC, Gallie BL, Chévez-Barrios P, et al. Retinoblastoma. In: Amin MB, Edge SB, Greene FL, et al, eds. *AJCC Cancer Staging Manual*. 8th ed. New York, NY: Springer; 2017. doi:10.1007/978-3-319-40618-3_68
- Chantada G, Doz F, Antoneli CBG, et al. A proposal for an international retinoblastoma staging system. *Pediatr Blood Cancer*. 2006;47(6):801-805. doi:10.1002/pbc.20606
- United Nations, Department of Economic and Social Affairs. World Population Prospects: the 2017 Revision. Volume I: Comprehensive Tables. https://population.un.org/wpp/Publications/Files/WPP2017_Volume-I_Comprehensive-Tables.pdf. Published 2017. Accessed January 18, 2020.
- Cochran WG. Some methods for strengthening the common χ^2 tests. *Biometrics*. 1954;10(4):417-451. doi:10.2307/3001616
- Armitage P. Tests for linear trends in proportions and frequencies. *Biometrics*. 1955;11(3):375-386. doi:10.2307/3001775
- Leal-Leal CA, Rivera-Luna R, Flores-Rojas M, Juárez-Echenique JC, Ordaz JC, Amador-Zarco J. Survival in extra-orbital metastatic retinoblastoma: treatment results. *Clin Transl Oncol*. 2006;8(1):39-44. doi:10.1007/s12094-006-0093-x
- Kaliki S, Patel A, Iram S, Palkonda VAR. Clinical presentation and outcomes of stage III or stage IV retinoblastoma in 80 Asian Indian patients. *J Pediatr Ophthalmol Strabismus*. 2017;54(3):177-184. doi:10.3928/01913913-20161019-01
- Kruger M, Hendricks M, Davidson A, et al. Childhood cancer in Africa. *Pediatr Blood Cancer*. 2014;61(4):587-592. doi:10.1002/pbc.24845
- Israels T, Ribeiro RC, Molyneux EM. Strategies to improve care for children with cancer in Sub-Saharan Africa. *Eur J Cancer*. 2010;46(11):1960-1966. doi:10.1016/j.ejca.2010.03.027
- Jedy-Agba E, McCormack V, Adebamowo C, Dos-Santos-Silva I. Stage at diagnosis of breast cancer in sub-Saharan Africa: a systematic review and meta-analysis. *Lancet Glob Health*. 2016;4(12):e923-e935. doi:10.1016/S2214-109X(16)30259-5
- Ladep NG, Lesi OA, Mark P, et al. Problem of hepatocellular carcinoma in West Africa. *World J Hepatol*. 2014;6(11):783-792. doi:10.4254/wjh.v6.i11.783
- Harford JB. Barriers to overcome for effective cancer control in Africa. *Lancet Oncol*. 2015;16(8):e385-e393. doi:10.1016/S1470-2045(15)00160-6
- Force LM, Abdollahpour I, Advani SM, et al; GBD 2017 Childhood Cancer Collaborators. The global burden of childhood and adolescent cancer in 2017: an analysis of the Global Burden of Disease Study 2017. *Lancet Oncol*. 2019;20(9):1211-1225. doi:10.1016/S1470-2045(19)30339-0
- Fabian ID, Stacey AW, Johnson KP, et al. Primary intravenous chemotherapy for group D retinoblastoma: a 13-year retrospective analysis. *Br J Ophthalmol*. 2017;101(1):82-88. doi:10.1136/bjophthalmol-2016-309710
- Shields CL, Mashayekhi A, Au AK, et al. The International Classification of Retinoblastoma predicts chemoreduction success. *Ophthalmology*. 2006;113(12):2276-2280. doi:10.1016/j.ophtha.2006.06.018
- Traoré F, Sylla F, Togo B, et al. Treatment of retinoblastoma in Sub-Saharan Africa: experience of the paediatric oncology unit at Gabriel Toure Teaching Hospital and the Institute of African Tropical Ophthalmology, Bamako, Mali. *Pediatr Blood Cancer*. 2018;65(8):e27101. doi:10.1002/pbc.27101
- Hill JA, Kimani K, White A, et al; Daisy's Eye Cancer Fund & The Kenyan National Retinoblastoma Strategy Group. Achieving optimal cancer outcomes in East Africa through multidisciplinary partnership: a case study of the Kenyan National Retinoblastoma Strategy group. *Global Health*. 2016;12(1):23. doi:10.1186/s12992-016-0160-1
- Wilimas JA, Wilson MW, Haik BG, et al. Development of retinoblastoma programs in Central America. *Pediatr Blood Cancer*. 2009;53(1):42-46. doi:10.1002/pbc.21984
- Qaddoumi I, Nawaiseh I, Mehyar M, et al. Team management, twinning, and telemedicine in retinoblastoma: a 3-tier approach implemented in the first eye salvage program in Jordan. *Pediatr Blood Cancer*. 2008;51(2):241-244. doi:10.1002/pbc.21489
- Dimaras H, Corson TW, Cobrinik D, et al. Retinoblastoma. *Nat Rev Dis Primers*. 2015;1:15021. doi:10.1038/nrdp.2015.21
- World Health Organization. Global Initiative for Childhood Cancer. <https://www.who.int/cancer/childhood-cancer/en/>. Published 2018. Accessed October 26, 2019.
- Shetty OA, Naresh KN, Banavali SD, et al. Evidence for the presence of high risk human papillomavirus in retinoblastoma tissue from nonfamilial retinoblastoma in developing countries. *Pediatr Blood Cancer*. 2012;58(2):185-190. doi:10.1002/pbc.23346
- Rushlow DE, Mol BM, Kennett JY, et al. Characterisation of retinoblastomas without RB1 mutations: genomic, gene expression, and clinical studies. *Lancet Oncol*. 2013;14(4):327-334. doi:10.1016/S1470-2045(13)70045-7