

Contents lists available at ScienceDirect

Journal of Global Antimicrobial Resistance

journal homepage: www.elsevier.com/locate/jgar

Short communication

Continues renal replacement therapy (CRRT) with disposable hemoperfusion cartridge: A promising option for severe COVID-19



Farzaneh Dastan^{a,b}, Ali Saffaei^c, Seyed Mehdi Mortazavi^b, Hamidreza Jamaati^b, Nadia Adnani^d, Sasan Samiee Roudi^e, Arda Kiani^f, Atefeh Abedini^b, Seyed MohammadReza Hashemian^{b,*}

^a Department of Clinical Pharmacy, School of Pharmacy, Shahid Beheshti University of Medical Sciences, Tehran, Iran

^b Chronic Respiratory Diseases Research Center (CRDRC), National Research Institute of Tuberculosis and Lung Diseases (NRITLD), Shahid Beheshti University of Medical Sciences, Tehran, Iran

^c Student Research Committee, Department of Clinical Pharmacy, School of Pharmacy, Shahid Beheshti University of Medical Sciences, Tehran, Iran

^d Nephrology Research Center, Department of Nephrology, School of Medicine, Alborz University of Medical Sciences, Karaj, Iran

^e Infectious Research Center, Department of Infectious Disease, School of Medicine, Iran University of Medical Sciences, Tehran, Iran

^f Tracheal Diseases Research Center, National Research Institute of Tuberculosis and Lung Diseases (NRITLD), Shahid Beheshti University of Medical Sciences, Tehran, Iran

ARTICLE INFO

Article history:

Received 1 April 2020

Received in revised form 9 April 2020

Accepted 16 April 2020

Available online 27 April 2020

Keywords:

COVID-19

Continues renal replacement therapy

Hemoperfusion

Acute respiratory distress syndrome

ABSTRACT

Cytokine release syndrome is prevalent in severe cases of COVID-19. In this syndrome, an uncontrolled response of immune system occurs. Extracorporeal blood purification has been proven to effectively remove the released inflammatory cytokines. Here, we reported a successful case to represent our experience of extracorporeal blood purification in a patient with severe COVID-19.

© 2020 The Authors. Published by Elsevier Ltd on behalf of International Society for Antimicrobial Chemotherapy. This is an open access article under the CC BY-NC-ND license (<http://creativecommons.org/licenses/by-nc-nd/4.0/>).

A 54-year old man presented to the emergency department of Erfan Niyayesh Hospital, Tehran, Iran, with complains of high-grade fever, cough, and dyspnea for five days. At admission time, he had fever up to 38 °C. Peripheral oxygen saturation was 90% with a face mask. No abnormality was seen in laboratory results except positive C-reactive protein, lymphopenia with 570 cells/ μ L, and severe respiratory acidosis. The chest X-ray imaging revealed bilateral infiltration in both upper and lower lobes (Fig. 1a). The patient had no underlying diseases and history of medicine usage. Reverse transcription-polymerase chain reaction (RT-PCR) sample for COVID-19 was reported positive and according to RT-PCR test and clinical symptoms, the diagnosis of COVID-19 was made for the patient. The therapeutic regimen included Hydroxychloroquine at a dose of 200 mg P.O. BID and lopinavir/ritonavir at a dose of 200/50 mg P.O. BID initiated for the patient. After four days, the clinical condition of the patient was deteriorated and he was subjected to intubation for invasive mechanical ventilation. The peripheral oxygen saturation decreased

to 82%. The chest X-ray imaging showed the progressive infiltration (Fig. 1b) and the patient was categorized as a critically COVID-19 case with remarkable acute respiratory distress syndrome (ARDS). The plasma level of interleukin-1 (IL-1), IL-6, IL-8, and tumor necrosis factor alpha were measured at this time. The results showed high levels of inflammatory cytokines. The urine output also decreased to 200 mL during the last 12 h and creatinine increased to 1.5 mg/dL. At this time, it is decided to start continuous renal replacement therapy (CRRT, Prismaflex, Baxter, IL, USA) with disposable hemoperfusion cartridge (HA 380 cartridge, Jafron Biomedical Co., China) due to cytokine release storm and hypoxemia. A Shaldon catheter was inserted and CRRT was done for three sessions. The CRRT modality was continuous veno-venous hemofiltration (CVVH). The replacement fluid volume was removed by 35 mL/kg/h and the pump circulated blood by 250 mL/min. Priming of hemoperfusion was done with saline, and the cartridge was primed in a vertical position with the arterial side facing downward. A bolus dose of 2500 IU of heparin was administered into the arterial line, the cartridge was kept inlet side down, and blood flow through the cartridge was begun. Totally, 6000 IU was needed through the procedure. CRRT was started with a high ultrafiltration rate (200 mL/h). Each cartridge was replaced with a new cartridge after 6 h.

* Corresponding author.

E-mail address: iran.criticalcare@yahoo.com (S.M. Hashemian).

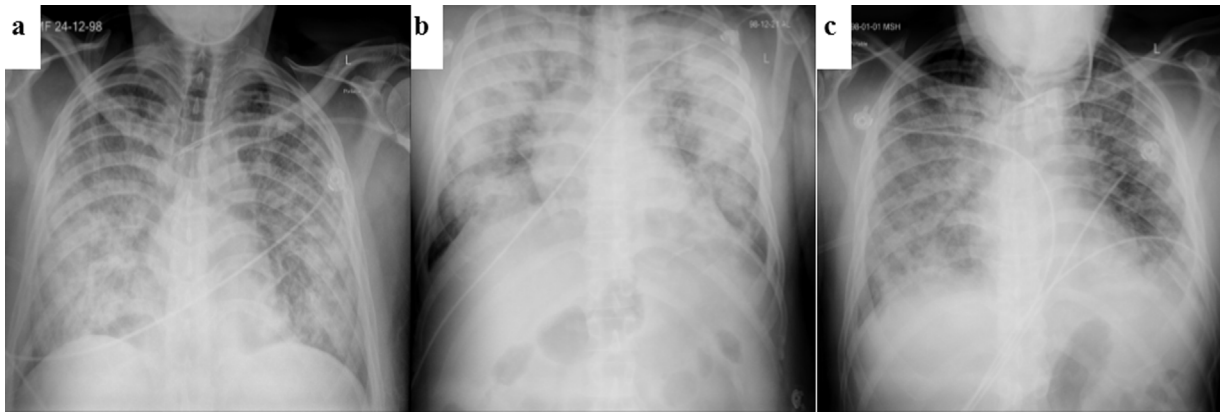


Fig. 1. The chest X-ray of the patient during hospitalization (a; admission time, b; before hemoperfusion, c; after hemoperfusion).

The fluid removal rate was decreased to 50 mL/h after 8 h and then to zero mL/h during the last 8 h in the first 24 h. The second and the third sessions of CRRT were conducted by 0 mL/h fluid removal. A 24-h rest between sessions, was considered to avoid the probable coagulopathy and electrolyte abnormality. After three sessions of CRRT plus hemoperfusion, the clinical condition of the patient was improved with the peripheral oxygen saturation of 95%. The creatinine also decreased to 1.1 mg/dL after the end of CRRT and urine output reached to 70 mL/h. No laboratory abnormality was seen during the CRRT. The chest X-ray revealed recovery of both lungs following the completion of 3 sessions of hemoperfusion (Fig. 1c). Also, the inflammatory cytokines were measured 48 h following the last session of hemoperfusion and showed a remarkable decrease. IL-1, and IL-6 were decreased from 523.3 pg/mL to 38.25 pg/mL, and 226.35 pg/mL to 210.18 pg/mL, respectively. The measurements also showed the decrease in IL-8 from 886.5 pg/mL to 482.4 pg/mL. Tumor necrosis factor alpha level decreased from 49.5 pg/mL to 47.3 pg/mL at the end of 3 sessions of hemoperfusion. The patient was finally transferred to the ward with an acceptable clinical condition.

The “cytokine cascade” in patients with new coronavirus (COVID-19) is a leading cause of death in critically ill patients [1]. A variety of blood purification technology treatment methods such as CRRT plus hemoperfusion seem to be effective in certain cases. Cytokine release storm is the probable phenomenon in severe COVID-19 cases [2]. Extracorporeal organ support can not only support vital organ functions such as the heart, lungs, kidneys, and liver but also avoid organ damage by removing excess inflammatory mediators [3]. Extracorporeal blood purification technology has been proven to effectively eliminate inflammatory cytokines such as CRP, IL-1, IL-6, etc. [4]. Here, we reported a successful case to represent our experience of extracorporeal blood purification in a patient with confirmed COVID-19. In this case, IL-6 was high and Tocilizumab, as an IL-6 antagonist, was another potential agent.

However, Tocilizumab therapy may be associated with adverse effects and the access to Tocilizumab is limited in Iran. Also, tocilizumab is effective only on IL-6 regarding its mechanism. Hemoperfusion can have impact on more than one cytokine and may be more effective. This case responded to hemoperfusion and CRRT without remarkable complication. Hence, hemoperfusion with a disposable cartridge may be a promising option to decrease the inflammatory cytokines in COVID-19 induced ARDS. However, it is necessary to conduct clinical trials to find the efficacy and safety of this strategy.

Funding

None

Written informed consent

Obtained.

Conflict of interest

None.

References

- [1] Channappanavar R, Perlman S. Pathogenic human coronavirus infections: causes and consequences of cytokine storm and immunopathology. *Seminars in immunopathology*. Springer; 2017. p. 529–39.
- [2] Zhou Y, Fu B, Zheng X, Wang D, Zhao C, Qi Y, et al. Pathogenic T cells and inflammatory monocytes incite inflammatory storm in severe COVID-19 patients. *Natl Sci Rev* 2020.
- [3] MacLaren G, Fisher D, Brodie D. Preparing for the most critically ill patients with COVID-19: the potential role of extracorporeal membrane oxygenation. *JAMA* 2020.
- [4] Venkataraman R, Subramanian S, Kellum JA. Clinical review: extracorporeal blood purification in severe sepsis. *Crit Care* 2003;7:139.