

CASE REPORT

Eraser Rhinolith: A Case Report

Hesam Jahandideh¹, Farideh Hosseinzadeh²

¹ Department of Otolaryngology-Head and Neck Surgery, Firoozgar Hospital, Iran University of Medical Sciences, Tehran, Iran

² ENT and Head and Neck Research Center, The Five Senses Institute, Iran University of Medical Sciences, Tehran, Iran

Received: 12 Aug. 2018; Accepted: 14 Nov. 2018

Abstract- Nasal foreign bodies are usually received in otolaryngology practice. Although more frequently seen in pediatric patients, also they can affect adults, specifically those with mental retardation or any psychiatric problems. We presented an unusual case of the nasal foreign body, an eraser rhinolith in a 17-year-old boy with mild mental retardation presented with long-lasting nasal obstruction but no chronic infection or epistaxis. Computed tomography revealed a peripherally calcified sub-mucosal round mass in the left nasal cavity. After surgery, a round shape foreign body that looked like an eraser piece was removed from the nasal cavity. Rhinolith can present just with nasal obstruction. With properly diagnosed and appropriate surgery, all rhinoliths can be removed and complication of extraction can be minimized.

© 2019 Tehran University of Medical Sciences. All rights reserved.

Acta Med Iran 2019;57(2):141-142.

Keywords: Foreign bodies; Nasal obstruction; Nasal cavity; Child

Introduction

Rhinolith is a mineralized mass in the nasal cavity, and when is complete or partial, incrustation of an intranasal body is created (1). Most of the times rhinoliths organize around the nucleus of a small exogenous foreign body, clot or inspissated secretion by gradually deposition of calcium and magnesium salts (2). The common exogenous substances are buttons, beads, fruit seeds, pebbles, sand, cotton or paper, and endogenous materials are cited as a blood clot, epithelial debris, teeth, dried pus, or nasal secretions and osseous fragment (1). Although nasal foreign bodies are reported in patients of all ages, they have been more frequently realized in children. In this report, we presented a case of a rhinolith in the floor of the nasal cavity.

Case Report

A 17-year-old boy with mild mental retardation presented to us with left-sided nasal obstruction since 5 years ago. He did not have any complaint of rhinorrhea and showed no symptoms of epistaxis, headache, and purulent nasal discharge. The patient himself was not aware of any foreign mass. Anterior rhinoscopy revealed severe C-form septal deviation with convexity to right side plus a mass with normal appearing mucosal surface in the floor of the left nasal cavity. Computed tomography

revealed a peripherally calcified sub-mucosal round mass in the left nasal cavity (Figure 1-A). Septoplasty in conjunction with an elevation of nasal floor mucosal flap was done, and a round shape foreign body that looked like an eraser piece was removed (Figure 1-B)

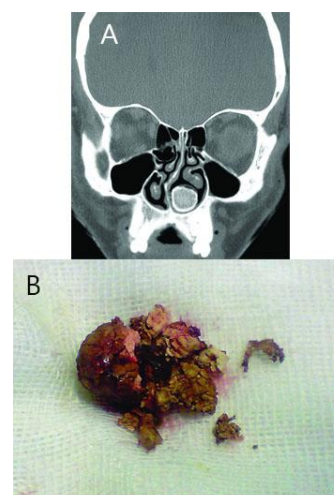


Figure 1. (A) Coronal computed tomography shows the rhinolith in the floor of the left nasal cavity in conjunction with septal deviation and inferior turbinate upward displacement. (B) The large foreign body that looks like an eraser piece

Discussion

Rhinolith, a mineralized mass in the nasal cavity, is the result of complete or partial incrustation of an

Corresponding Author: F. Hosseinzadeh

ENT and Head and Neck Research Center, The Five Senses Institute, Iran University of Medical Sciences, Tehran, Iran
Tel: +98 917 3781386, Fax: +98 21 66525329, E-mail address: Hosseinzadeh.farideh@gmail.com

Eraser rhinolith

intranasal body (1). There is a large difference of manifestation of rhinoliths according to their origin and location. Rhinoliths usually form around the nucleus of a small exogenous foreign body, inspissated secretion, clot or by slow deposition of calcium and magnesium salts (2). Beads, pebbles, fruit seeds, sand, buttons, cotton or paper, are commonly mentioned as exogenous kernels, and blood clot, epithelial debris, teeth, dried pus, or nasal secretions and osseous fragments are cited as endogenous ones (1). X-ray diffraction, Micro-probe electron microscopy, and infrared spectroscopy are techniques can be mentioned in the detection of rhinoliths mineralogical components. The main matter of them is minerals (>90%), such as calcium phosphate, magnesium phosphate, calcium carbonate, and others. The organic materials derive from lacrimal fluid and nasal secretions. Most of the patients with rhinolith could not remember the entrance of a foreign body. Materials enter to the nose through the nostrils, by vomiting and coughing. In maxillary and frontal sinuses, rhinoliths have been reported (3,4). Most of the times rhinoliths in maxillary sinus and frontal sinus are asymptomatic and diagnosed accidentally, but sometimes patients have complaints of symptoms (5). In the latter situation, most of the patients complain of foul-smelling, unilateral nasal discharge and nasal obstruction (2). The most common site of rhinoliths in the nasal cavity is the nasal floor (6). long-standing rhinoliths bound to different complications like the destruction of the mucosa, septal perforation, and perforations of the palate and oro-nasal fistulas, recurrent otitis media and recurrent dacryocystitis are reported (7,8). Bony destruction was observed at the nasal septum as well. Treatment consists of surgical removal of the rhinolith, usually through nostrils (2). Often, the mass is removed in a piecemeal fashion. Moreover, lithotripsy has been used disintegrate a large stone and reduce it in size to facilitate removal (5). The rhinolith in our patient presented with long-lasting nasal obstruction. Coronal computed tomography showed the rhinolith in the floor of the left nasal cavity in conjunction with septal

deviation and inferior turbinate upward displacement. In this patient, septoplasty was done, and nasal floor flap was elevated, and all of the foreign body was removed successfully. The large foreign body which looked like an eraser piece was seen. Cauterization and nasal packing may be necessary due to the bleeding and granulation tissue after removal of rhinoliths. Appropriate antibiotics should be prescribed for control of infection that is determined by culture sensitivity. Fortunately, during the follow-up, no complication occurred in our patient. Septal deviation or chronic sinusitis can be corrected by surgery if needed.

References

1. Pinto LS, Campagnoli EB, de Souza Azevedo R, Lopes MA, Jorge J. Rhinoliths causing palatal perforation: case report and literature review. *Oral Surg Oral Med Oral Pathol Oral Radiol Endod* 2007;104:e42-6.
2. Munoz A, Pedrosa I, Villafruela M. "Eraseroma" as a cause of rhinolith: CT and MRI in a child. *Neuroradiology* 1997;39:824-6.
3. Grant DG, Hussain A, Burgel R. Frontal sinolith. *J Laryngol Otol* 1998;112:570-2.
4. Fahim Ahmed Shah, Sunil George, Nair Reghunandan. A Case Presentation of a Large Rhinolith. *Oman Med J* 2010;25:230-1.
5. Orhan K, Kocyigit D, Kisnisci R, Paksoy CS. Rhinolithiasis: an uncommon entity of the nasal cavity. *Oral Surg Oral Med Oral Pathol Oral Radiol Endod* 2006;101:e28-32.
6. Vandervliet EJ, Vanhoenacker FM, Van Haesendonck J, Parizel PM. Rhinolith of the nasal septum. *JBR-BTR* 2010;93:164-5.
7. Gill RS, Lal M. Perforation of the hard palate by a rhinolith and its repair. *J Laryngol Otol* 1977;91:85-9.
8. Flood TR. Rhinolith: an unusual cause of palatal perforation. *Br J Oral Maxillofac Surg* 1988;26:486-90.