



## Graduate Medical Education Research Journal

---

Volume 2 | Issue 1

Article 60


---

September 2020

### Virchow's Triad in Action

Adam Karevoll et al.

Follow this and additional works at: <https://digitalcommons.unmc.edu/gmerj>

 Part of the [Higher Education Commons](#), and the [Medicine and Health Sciences Commons](#)

---

#### Recommended Citation

Karevoll, A. Virchow's Triad in Action. Graduate Medical Education Research Journal. 2020 Sep 29; 2(1). <https://digitalcommons.unmc.edu/gmerj/vol2/iss1/60>

This Conference Proceeding is brought to you for free and open access by DigitalCommons@UNMC. It has been accepted for inclusion in Graduate Medical Education Research Journal by an authorized editor of DigitalCommons@UNMC. For more information, please contact [digitalcommons@unmc.edu](mailto:digitalcommons@unmc.edu).

---

## Virchow's Triad in Action

Creative Commons License



This work is licensed under a [Creative Commons Attribution-Noncommercial-No Derivative Works 4.0 License](https://creativecommons.org/licenses/by-nc-nd/4.0/).



anticoagulation. CT angiography confirmed the clot and revealed extensive compression of the proximal left common iliac vein by the right common iliac artery suggestive of May-Thurner syndrome. Intravenous heparin anticoagulation was initiated and apixaban held, but there was suspicion for development of heparin induced thrombocytopenia so he was transitioned to argatroban for anticoagulation.

**Methods:** Physical Exam, Doppler Ultrasound, CT Angiography

**Conclusion:** To manage May-Thurner syndrome he underwent manual thrombectomy with endovascular stent placement. The following night he developed worsening pain and swelling in his left leg consistent with compartment syndrome. He underwent four compartment fasciotomy and was restarted on argatroban. Repeat Doppler ultrasound revealed recurrence of extensive left lower extremity DVT. Given multiple recurrent DVTs despite adequate anticoagulation, dedicated peripheral blood

smear was obtained and revealed atypical myeloblasts concerning for acute myeloid leukemia. Following confirmatory bone marrow biopsy, he was started on induction chemotherapy. He remained in hospital receiving ongoing chemotherapy after residual disease was detected on bone marrow biopsy following initial chemotherapy cycles. ■

<https://doi.org/10.32873/unmc.dc.gmerj.2.1.059>

## Vanishing Bile Duct Syndrome: A Paraneoplastic Phenomenon Secondary to Occult Hodgkin's lymphoma

Lauren M. Keim<sup>1</sup>, Ian Cormier<sup>1</sup>

<sup>1</sup>University of Nebraska Medical Center, Department of Internal Medicine

**Mentor:** Marco Olivera-Martinez

**Program:** Internal Medicine

**Type:** Case Report

**Background:** A 27-year-old female with no medical history presented with one month of progressively worsening jaundice and a 30-pound weight loss. She was found to have conjugated hyperbilirubinemia with an acute cholestatic hepatitis. Ultrasound of the liver was unremarkable and magnetic resonance cholangiopancreatography revealed normal appearing intrahepatic and extrahepatic bile ducts without mechanical obstruction. An extensive workup for autoimmune and infectious etiologies of hepatitis was unremarkable. A liver biopsy was significant for features of cholestasis and ductopenia suggestive of vanishing bile duct syndrome (VBDS). A computed tomography scan of the chest revealed a large complex anterior mediastinal mass with extensive lymphadenopathy (Figure 1). A core needle

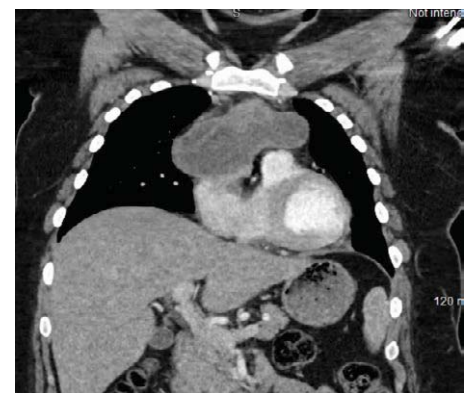
biopsy of the right supraclavicular lymph node was obtained, and pathology was consistent with Hodgkin's lymphoma. She was initiated on induction therapy with improvement in her liver enzymes.

**Methods:** Ultrasound, CT scan

**Conclusion:** VBDS refers to a group of disorders with variable etiologies that cause a progressive destruction of intrahepatic bile ducts with resulting cholestatic liver injury. The diagnosis is made pathologically and requires a paucity of interlobular bile ducts, defined as less than 50% of portal areas with a bile duct on biopsy. Etiologies include infections, ischemia, autoimmune conditions, drug reactions, and malignancy. Treatment depends on the underlying cause and includes withdrawal of offending medications, immunosuppression, ursodeoxycholic acid, and treatment of malignancy in patients with paraneoplastic VBDS. Those with irreversible hepatic failure should be considered for

liver transplantation. Prognosis is variable as some progress to cirrhosis and others have regeneration of biliary epithelium with recovery of hepatic function. ■

<https://doi.org/10.32873/unmc.dc.gmerj.2.1.061>



**Figure 1.** Computed tomography scan of the chest demonstrating large anterior mediastinal mass.

## Acute Colonic Ischemia Secondary to Oral Contraceptive Use

Lauren M. Keim<sup>1</sup>, Ian Cormier<sup>1</sup>, Brett Henderson<sup>2</sup>, Mark Mailliard<sup>2</sup>

<sup>1</sup>University of Nebraska Medical Center, Department of Internal Medicine

<sup>2</sup>University of Nebraska Medical Center, Department of Internal Medicine, Division of Gastroenterology

**Mentor:** Mark Mailliard

**Program:** Internal Medicine

**Type:** Case Report

**Background:** A 39-year-old female presented with sudden onset of abdominal pain and hematochezia. Her medical history was significant for obesity and hypertension. The abdomen was tender to palpation in the left lower quadrant without rigidity. Workup was significant for leukocytosis and elevated inflammatory markers. Her stool was negative for gastrointestinal pathogens, including

*Clostridium difficile*. A colonoscopy was performed and revealed a diffusely edematous, ulcerated and violaceous segment of the sigmoid colon concerning for severe ischemic injury (Figure 1). Biopsies of the mucosa were obtained, and pathology confirmed ischemic colitis. Review of medications was significant for an oral contraceptive which was discontinued due to suspicion for drug induced colonic ischemia. The patient's hematochezia and abdominal pain resolved with conservative treatment.

**Methods:** Physical Exam, Colonoscopy

**Conclusion:** When young adults present with hematochezia, infectious colitis, inflammatory bowel disease, and hemorrhoids are commonly considered. However, intestinal ischemia is an important differential diagnosis. Ischemic colitis is the most common form of intestinal ischemia, generally encountered in patients greater than 50 years old as a result of nonocclusive hypoperfusion. Rarely, ischemic colitis may result from drug exposure. Mesenteric thrombotic events linked to contraceptive medications have been described in the literature and are thought to be secondary to a hypercoagulable