



Graduate Medical Education Research Journal

Volume 2 | Issue 1

Article 10

September 2020

Laryngeal Histoplasmosis in patients with Crohn's Disease undergoing treatment with HUMIRA (adalimumab): A Case Series

Jenna Berg

University of Nebraska Medical Center

Jonathan Blecha

University of Nebraska Medical Center

Chris Bingcang

University of Nebraska Medical Center

Justin Oltman

University of Nebraska Medical Center

Jayme Dowdall

University of Nebraska Medical Center

See next page for additional authors

Follow this and additional works at: <https://digitalcommons.unmc.edu/gmerj>



Part of the [Digestive System Diseases Commons](#), [Gastroenterology Commons](#), [Higher Education Commons](#), and the [Otolaryngology Commons](#)

Recommended Citation

Berg, J., Blecha, J., Bingcang, C., Oltman, J., Dowdall, J., , Lele, S. M. Laryngeal Histoplasmosis in patients with Crohn's Disease undergoing treatment with HUMIRA (adalimumab): A Case Series. Graduate Medical Education Research Journal. 2020 Sep 29; 2(1).
<https://digitalcommons.unmc.edu/gmerj/vol2/iss1/10>

This Case Report is brought to you for free and open access by DigitalCommons@UNMC. It has been accepted for inclusion in Graduate Medical Education Research Journal by an authorized editor of DigitalCommons@UNMC. For more information, please contact digitalcommons@unmc.edu.

Laryngeal Histoplasmosis in patients with Crohn's Disease undergoing treatment with HUMIRA (adalimumab): A Case Series

Abstract

The FDA has advocated for increasing awareness of histoplasmosis for patients undergoing TNF blockers as delay in diagnosis can lead to a poor outcome.¹ Laryngeal histoplasmosis is a rare entity that should be part of the differential diagnosis in patients receiving immune suppression for Crohn's disease. Patients with laryngeal histoplasmosis often report hoarseness, mucosal ulcerations, dysphagia, and odynophagia. We present a series of two cases of laryngeal histoplasmosis in patients with Crohn's. These cases illustrate the high index of suspicion required to make the diagnosis of laryngeal histoplasmosis, especially in the Midwestern United States. Diagnosis is made quickly and cost-effectively with proper staining. Delayed diagnosis may lead to dissemination, increased morbidity, and mortality.

Creative Commons License



This work is licensed under a [Creative Commons Attribution-NonCommercial-No Derivative Works 4.0 License](https://creativecommons.org/licenses/by-nc-nd/4.0/).

Authors

Jenna Berg, Jonathan Blecha, Chris Bingcang, Justin Oltman, Jayme Dowdall, and Subodh M. Lele

Laryngeal Histoplasmosis in Patients With Crohn's Disease Undergoing Treatment With HUMIRA (adalimumab): A Case Series

Jenna Berg¹, Jonathan Blecha¹, Chris Bingcang¹, Justin Oltman¹, Jayme Dowdall¹, Subodh M. Lele²

¹ University of Nebraska Medical Center, Department of Otolaryngology – Head and Neck Surgery

² University of Nebraska Medical Center, Department of Pathology and Microbiology

Introduction

Involvement of the larynx in Crohn's disease is rarely described, but may be associated with symptoms such as dysphonia, dysphagia and globus sensation, correlating to examination findings including ulceration, granuloma formation, laryngeal edema, and vocal fold hypomobility.^{1,2} With biologics like Humira (adalimumab) leading to improved management of Crohn's disease, side effects of immune suppression should be considered in the differential diagnosis for patients with symptoms in the upper aerodigestive tract. The FDA has advocated for increasing awareness of histoplasmosis for patients undergoing treatment with TNF blockers as delay in diagnosis can lead to a poor outcomes.³

Histoplasmosis, a granulomatous disease caused by the intracellular organism *Histoplasma capsulatum*, is the most commonly diagnosed endemic mycosis in the United States, and is most prevalent in the Ohio and Mississippi River Valleys.^{3,4} Laryngeal histoplasmosis rarely presents as an isolated primary lesion and is more often associated with disseminated histoplasmosis. Due to its low prevalence, laryngeal histoplasmosis is often not included in the differential diagnosis of many clinicians. In the absence of other symptoms, such as laryngeal lesions associated with histoplasmosis, it may easily be confused with laryngeal Crohn's, carcinoma or tuberculosis.^{4,5} We report two cases of laryngeal histoplasmosis in patients with Crohn's disease receiving adalimumab therapy and discuss the clinical presentation, diagnosis, and management of this disease. Consent was obtained for usage of patient photographs.

Case

Two individual patients presented to our clinic for evaluation of new onset voice changes with associated odynophagia and dysphagia. Upon evaluation, it was noted that both patients were on immunosuppression medication including Humira (adalimumab) for Crohn's disease and both were non-smokers.

The endoscopic evaluation revealed laryngeal lesions suspicious for malignancy with diffuse laryngeal disease with ulceration and thickening of the supraglottic larynx (Figure 1A). Biopsy of both patients was performed to rule out laryngeal malignancy. One patient was diagnosed after Gomori Methenamine Silver Stain showed the presence of intracellular organisms consistent with histoplasmosis (Figure 2). The second patient's diagnosis was delayed until bowel resection pathology showed disseminated histoplasmosis. The laryngeal slides were re-reviewed in light of the bowel resection and were indeed positive for fungal elements that were not diagnosed on the original pathology slides. Both patients were seen by Infectious Disease specialists and received antifungal therapy in addition to discontinuation of Humira, ultimately leading to resolution of their symptoms. Follow up endoscopic examination after two months of therapy showed marked improvement of laryngeal lesions (Figure 1B), and complete resolution by six months for the first patient and three months for the second.

Discussion

Laryngeal histoplasmosis is a relatively rare presentation of this mycosis and can

widely vary in its presentation. Typically, histoplasmosis is inhaled from spores within the soil, first causing pulmonary infection, and can subsequently spread hematologically to other organ systems. Although the involvement of the larynx is usually associated with disseminated disease, there have been cases reported in the literature of primary laryngeal histoplasmosis.⁶

The majority of infected patients are immunocompetent and asymptomatic or may present with a mild, flu-like illness which resolves without treatment. Immunocompromised patients, however, have an increased risk of disseminated disease, which can progress to fatality if left untreated.⁷ Of note, both patients in this series were receiving adalimumab for immunosuppressive therapy at the time of diagnosis.

In patients taking TNF blockers, histoplasmosis is the most common invasive fungal infection, and is a more common cause of serious infections than tuberculosis.³ TNF- α has been identified as an integral cytokine for developing protective immunity against *Histoplasma capsulatum*, and inhibiting this cytokine can lead to macrophage dysfunction.⁸ Infections in patients with TNF blockade tend

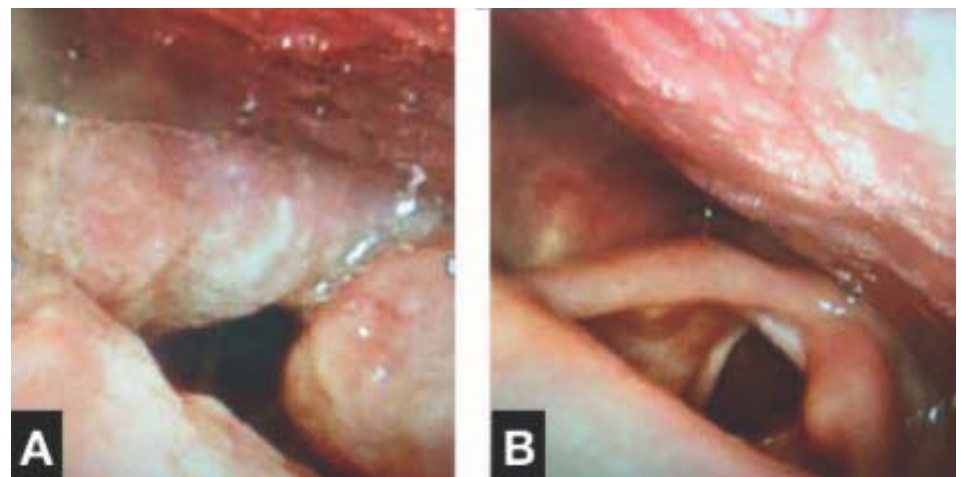


Figure 1. Larynx as seen during flexible laryngoscopy.

A: Pre-antifungal therapy. Moderately edematous and erythematous supraglottic larynx with irregular mucosal surface and yellow discoloration.

B: Post-antifungal therapy. Mild residual inflammation of left arytenoid.

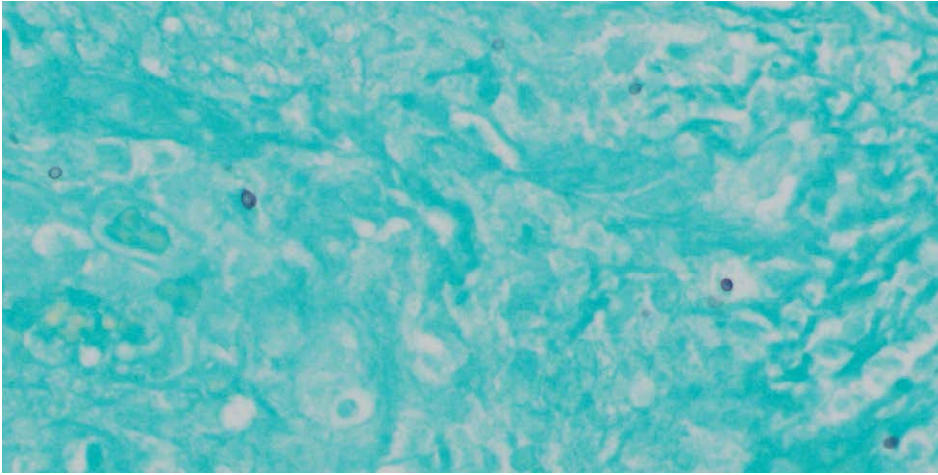


Figure 2. Gomori Methamine Stain 400x showing fungal-like yeast forms.

to present with pneumonia or other pulmonary symptoms and/or signs of progressive disseminated histoplasmosis, but may also present with symptoms including skin necrosis,³ or bowel perforation and laryngeal lesions as seen in our patients.

Sonkhya et al. reported that the most common primary laryngeal lesions were located on the false cords and aryepiglottic folds, with an endophytic pattern of growth. However, an exophytic pattern of growth has also been reported, as have locations involving the laryngeal surface of the epiglottis, the vocal cords, cricoid region, and supraglottic region.⁶

The diagnosis of laryngeal histoplasmosis is challenging secondary to the varied physical presentation of the lesions, and their similarity to malignancy. While suspicion must be high in an immunocompromised patient, the key to diagnosis is histopathologic identification. It is imperative to biopsy the lesions and communicate your suspicions to the examining pathology, as Grocott and Gomori silver staining can distinguish the yeast forms.

Therapy for histoplasmosis varies according to the immune status of the patient, as well as the extent and severity of the disease. Intravenous Amphotericin B for 7-10 days

followed by oral Itraconazole for 9-12 months is the treatment of choice for disseminated disease with pulmonary involvement.⁹ It is not currently recommended to routinely screen for histoplasma antigen or to treat patients taking TNF blockers prophylactically with anti-fungal therapy.³

Conclusion

Laryngeal histoplasmosis is an unusual presentation of this dimorphic fungus, one that can easily be mistaken for malignancy or inflammatory etiologies. It is important to have a high index of suspicion of this disease, especially in immunocompromised patients and in endemic areas, so that appropriate testing is performed. Indeed, upper aerodigestive tract findings may be present in patients with Crohn's disease undergoing surveillance endoscopy who are on treatment with Humira (adalimumab). Delay may lead to further dissemination of the disease, resulting in increased morbidity and mortality. It is especially important to consider this diagnosis if the patient is immunocompromised and pathologic examination has ruled out malignancy. ■

<https://doi.org/10.32873/unmc.dc.gmerj.2.1.009>

References

- Loos E, Lemkens P, Vander Poorten V, et al. Laryngeal Manifestations of Inflammatory Bowel Disease. *Journal of Voice*. 33.2 (2019): 1-6.
- Yang J, Maronian N, Reyes V, et al. Laryngeal and other otolaryngologic manifestations of Crohn's disease. *Journal of Voice*. 16.2 (2002): 278-282.
- Hage Chadi A, Bowyer S, Tarvin SE, et al. Recognition, diagnosis, and treatment of histoplasmosis complicating tumor necrosis factor blocker therapy. *Clinical Infectious Diseases*. 50.1 (2010): 85-92.
- Mave V, Mushatt D. A case of laryngeal histoplasmosis mimicking carcinoma with a review of the literature. *J La State Med Soc*. 2008;160(3):160-163.
- Pochini Sobrinho F, Della Negra M, Queiroz W, et al. Histoplasmosis of the larynx. *Braz J Med Biol Res*. 2007;73(6):857-861.
- Sonkhya N, Mehta R, Sonkhya D, et al. Primary Histoplasmosis of Larynx: A Case Series and Review of Literature. *Int J Otorhinolaryngol Head Neck Surg*. 2013;2(2):47-51
- Ansari HA, Saeed N, Khan N, et al. Laryngeal histoplasmosis. *BMJ Case Reports*. 2016. doi:10.1136/bcr-2016-216423
- Deepe GS Jr. Modulation of infection with *Histoplasma capsulatum* by inhibition of tumor necrosis factor- α activity. *Clin Infect Dis*. 2005. 41(Suppl 3): S204-7.
- Wheat LJ, Freifeld A, Kleiman M, et al. Clinical practice guidelines for the management of patients with histoplasmosis: 2007 update by the Infectious Diseases Society of America. *Clin Infect Dis*. 2007 Oct 1;45(7):807-25.