



## Graduate Medical Education Research Journal

Volume 2 | Issue 1


Article 68

September 2020

### Chemoembolization of Hepatocellular Carcinoma with Parasitic Blood Supply from the Inferior Phrenic Artery

Lei Yu et al.

Follow this and additional works at: <https://digitalcommons.unmc.edu/gmerj>

 Part of the [Higher Education Commons](#), and the [Medicine and Health Sciences Commons](#)

#### Recommended Citation

Yu, L. Chemoembolization of Hepatocellular Carcinoma with Parasitic Blood Supply from the Inferior Phrenic Artery. *Graduate Medical Education Research Journal*. 2020 Sep 29; 2(1).  
<https://digitalcommons.unmc.edu/gmerj/vol2/iss1/68>

This Conference Proceeding is brought to you for free and open access by DigitalCommons@UNMC. It has been accepted for inclusion in *Graduate Medical Education Research Journal* by an authorized editor of DigitalCommons@UNMC. For more information, please contact [digitalcommons@unmc.edu](mailto:digitalcommons@unmc.edu).

---

## Chemoembolization of Hepatocellular Carcinoma with Parasitic Blood Supply from the Inferior Phrenic Artery

Creative Commons License



This work is licensed under a [Creative Commons Attribution-Noncommercial-No Derivative Works 4.0 License](https://creativecommons.org/licenses/by-nc-nd/4.0/).

rates between the Lymph2Cx assay and the Hans and Choi algorithms were calculated.

**Results:** By the Lymph2Cx assay analysis, 36 cases (51%) were classified as GCB, 25 cases (36%) were classified as ABC and 9 cases (13%) were intermediate/unclassified. The Hans algorithm classified 37/70 cases (53%) as GCB and 33/70 cases (47%) as non-GCB. The Choi algorithm classified 14/36 cases (39%) as GCB and 22/36 cases (61%) as ABC. After excluding the 9 intermediate/unclassified cases by the Lymph2Cx assay,

61 cases classified by the Hans algorithm and 30 cases classified by the Choi algorithm were compared to the Lymph2Cx. Overall, 54 (89%) of cases classified by the Hans IHC algorithm and Lymph2Cx assay were concordant. 22 (77%) classified by the Choi algorithm and Lymph2Cx assay were concordant.

**Conclusion:** The Lymph2Cx assay is a useful tool to determine COO in DLBCL. ■

<https://doi.org/10.32873/unmc.dc.gmerj.2.1.064>

## **Nontuberculous Mycobacterium (NTM) Infection in Aquatic Workers With Purified Protein Derivative (PPD) and Gold QuantiFERON Tests**

Lavanya Ravipati<sup>1</sup>, Sarah A. Howard<sup>1</sup>

<sup>1</sup>University of Nebraska Medical Center, Clarkson Family Medicine

**Mentor:** Sarah A. Howard

**Program:** Clarkson Family Medicine

**Type:** Case Report

**Background:** Nontuberculous mycobacteria (NTM) infections are commonly caused by *Mycobacterium marinum* and *fortuitum* with *M. marinum* more likely to cause skin infections. Aquatic environments are a potential source of contact with *M. marinum* and *fortuitum*. Patients with NTM infections may present with positive tuberculin purified protein derivative (PPD) and/or gold QuantiFERON tests. However, PPD cannot differentiate between NTM infection and other tuberculous infections caused by different mycobacterial strains. We present an asymptomatic patient who presented for further evaluation of an off-site positive PPD and gold QuantiFERON Test.

**Methods:** Patient informed consent was obtained for this case report.

**Results:** A 31 year-old, healthy, female marine biologist employed in an aquatic environment presented to the clinic with a positive PPD and a positive gold QuantiFERON test. Her job exposes her to sea creatures that maybe infected with *Mycobacterium marinum* and *fortuitum*. She denied any history that was suggestive of tuberculous infection. A referral was made to specialist service for further evaluation at which time a repeat gold QuantiFERON test was performed and was noted to be positive. Following this work up, the patient, understanding her likelihood of having exposure to *M. Marinum* and *fortuitum*, preferred to follow a conservative treatment approach to monitor for any symptoms of active tuberculosis and seek follow up as needed.

**Conclusion:** Clinicians should not downplay the importance of aquatic occupations and hobbies in patients who exhibit positive PPD and gold QuantiFERON test. Healthcare providers should consider NTM infection in their differential diagnosis when examining patient populations exposed to aquarium water, saltwater, and freshwater environments. Preventative apparel like waterproof gloves can protect the exposed skin from infection. Clinicians can prevent NTM infections by increasing awareness and promoting prevention measures in at-risk populations, particularly since infection can be prevented with appropriate protective attire. ■

<https://doi.org/10.32873/unmc.dc.gmerj.2.1.074>

## **Chemoembolization of Hepatocellular Carcinoma With Parasitic Blood Supply From the Inferior Phrenic Artery**

Lei Yu<sup>1\*</sup>, Alex Hodson<sup>2\*</sup>, Timothy Donovan<sup>1</sup>, Christoph Vargo<sup>1</sup>

<sup>1</sup>University of Nebraska Medical Center, Department of Radiology

<sup>2</sup>University of Nebraska Medical Center, College of Medicine

\*These authors contributed equally to this work.

**Mentor:** Christopher Vargo

**Program:** Radiology

**Type:** Case Report

**Background:** Transarterial chemoembolization (TACE) is a commonly used embolotherapy for unresectable hepatocellular carcinoma (HCC). The hepatic artery is usually the vessel of choice, however, up to 30% of HCCs can develop an extrahepatic collateral (EHC) supply and failure to recognize EHC can lead to

treatment failure. The most common extra hepatic artery supplying HCC is the inferior phrenic artery (IPA), with right IPA and left IPA comprising up to 83% and 12% of all collaterals respectively. Certain imaging features can help predict the presence of IPA collaterals and should be considered at the time of treatment.

**Methods:** We reviewed one recurrent HCC after radioembolization and one residual HCC after chemoembolization to identify tumor characteristics associated with the formation of EHC, especially IPA collaterals. Procedural

considerations during IPA embolization and common complications are also reviewed.

**Results:** Several factors raise the suspicion for EHC development, including large size, location (segment VII), and prior arterial embolization. Avoiding non-target embolization is crucial in treatment planning as inferior phrenic artery supplies the diaphragm, and rarely, the pericardium and bowel. Prophylactic embolization to non-tumor feeding branches can limit non-target embolization.

**Conclusion:** Prompt recognition of extrahepatic collaterals of HCC plays a key role in increasing the efficacy of TACE. The most common collateral supply is from the inferior phrenic artery. Several imaging clues often suggest potential development of parasitic blood supply, and in such cases we recommend IPA angiography be preformed during TACE procedures. Prophylactic embolization of non-tumor feeding IPA branches is important in avoiding non-target embolization. ■

<https://doi.org/10.32873/unmc.dc.gmerj.2.1.087>

## Reference

- Cheng LF, Ma KF, Fan WC, Yung AW, Li TM, Wong CS. Hepatocellular carcinoma with extrahepatic collateral arterial supply. *J Med Imaging Radiat Oncol.* 2010;54(1):26-34.
- Miyayama S, Matsui O, Taki K, et al. Extrahepatic blood supply to hepatocellular carcinoma: angiographic demonstration and transcatheter arterial chemoembolization. *Cardiovasc Intervent Radiol.* 2006;29(1):39-48.
- Gwon DI, Ko GY, Yoon HK, et al. Inferior phrenic artery: anatomy, variations, pathologic conditions, and interventional management. *Radiographics.* 2007;27(3):687-705.
- Kim HC, Chung JW, Lee W, Jae HJ, Park JH. Recognizing extrahepatic collateral vessels that supply hepatocellular carcinoma to avoid complications of transcatheter arterial chemoembolization. *Radiographics.* 2005;25 Suppl 1:S25-39.
- Moustafa AS, Abdel aal AK, Ertel N, Saad N, Dubay D, Saddekni S. Chemoembolization of Hepatocellular Carcinoma with Extrahepatic Collateral Blood Supply: Anatomic and Technical Considerations. *Radiographics.* 2017;37(3):963-977.

## Performance of the Meso Scale Multiplex Platform in the Assessment of Serum Cytokines/Chemokines in Rheumatoid Arthritis

Peter M. Maloley<sup>1</sup>, Bryant R. England<sup>2,3</sup>, Harlan Sayles<sup>4</sup>, Geoffrey M. Thiele<sup>2,3</sup>, Michael J. Duryee<sup>2,3</sup>, Jeffrey Payne<sup>5</sup>, Ted R. Mikuls<sup>2,3</sup>

<sup>1</sup>University of Nebraska Medical Center, Department of Internal Medicine

<sup>2</sup>University of Nebraska Medical Center, Department of Internal Medicine, Division of Rheumatology

<sup>3</sup>Veteran Affairs Nebraska Western Iowa Health Care System

<sup>4</sup>University of Nebraska Medical Center, College of Public Health

<sup>5</sup>University of Nebraska Medical Center, College of Dentistry

**Mentor:** Ted Mikuls

**Program:** Internal Medicine

**Type:** Original Research

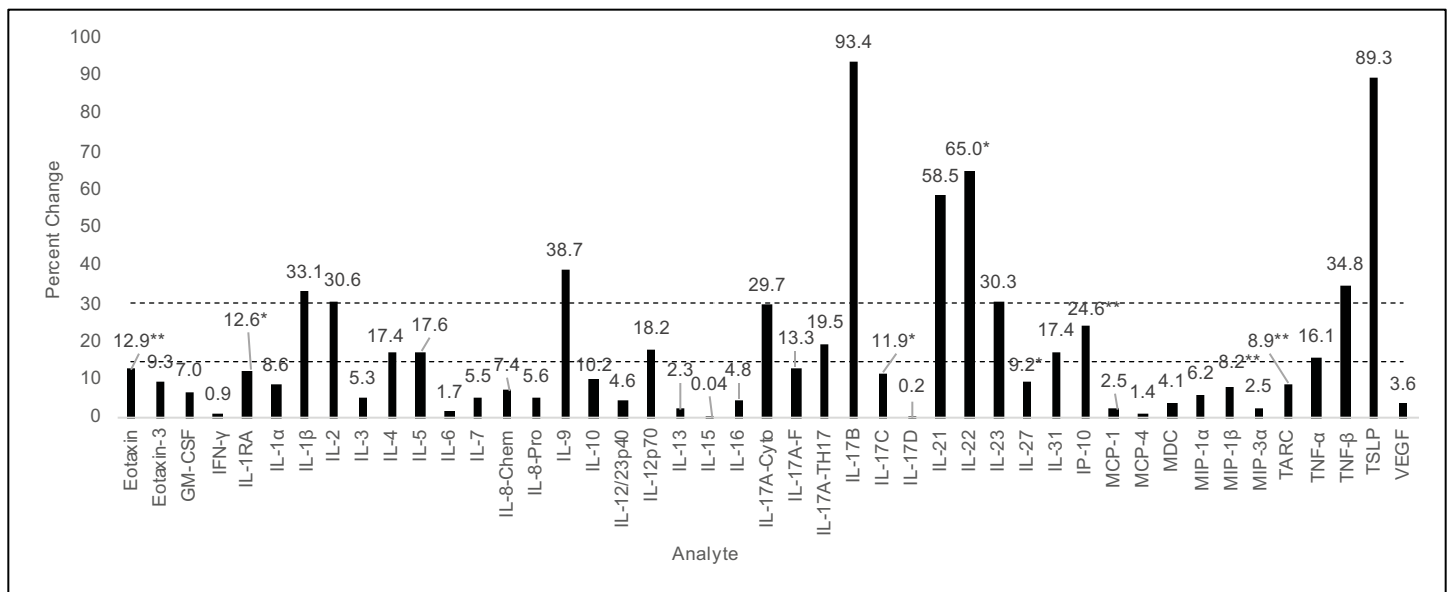
**Background:** Cytokines and chemokines (cytokines) are central to RA pathogenesis, a fact underscored by the emergence of multiplex immunoassays for quantifying cytokine values. Intrinsic factors to rheumatoid arthritis (RA), namely rheumatoid factor (RF), may interfere with assay outcomes by nonspecifically binding

detection analytes. Thus, we evaluated the performance of a commercially available multiplex platform and assessed the impact of RF depletion.

**Methods:** Forty-five cytokines were tested using the Meso Scale Discovery V-PLEX<sup>TM</sup> immunoassays and serum from 40 RA and 40 osteoarthritis (OA) patients. Select samples were depleted of RF using a commercial binder. Performance was assessed using intraclass correlation coefficients (CV), intraclass correlation coefficients (ICC), percent change

following RF depletion, and discriminative ability between RA and OA.

**Results:** Of the 44 cytokines analyzed in duplicate, 22 yielded CVs <10%; only 3 demonstrated CVs >30%. ICCs universally exceeded 0.85 with the exception of seven analytes. RF depletion altered cytokine values by <15% for 28 analytes with larger changes (>30%) seen for nine analytes. Of the 45 analytes tested, 24 differed based on measurement in plasma vs. serum. Analytes were frequently greater in RA vs. OA, but



**Figure 1.** Mean absolute percent change in analyte concentration following RF depletion.

\* Wilcoxon signed-rank test p-value < 0.05

\*\* Wilcoxon signed-rank test p-value < 0.01

Of the 45 analytes, 28 exhibited <15% change, eight showed intermediate changes (15-30%), and nine demonstrated >30% change. RED lines indicate cut off points.