



Role of vitamin C on hormonal and pathological changes in *Heteropneustes fossilis* (Bloch) due to exposure to sodium fluoride

Shiv Shankar Yadav^{1*} & Madhu Tripathi²

¹Institute of Biomedical Sciences Bundelkhand University Jhansi-284 128, Uttar Pradesh, India

²Department of Zoology, University of Lucknow, Lucknow-226 007, Uttar Pradesh, India

Received 22 May 2019; revised 22 August 2020

Fluoride is an essential trace element for humans and animals. Here, we explored the effects of sodium fluoride (NaF) on morphological, hormonal and histological changes in ovary of Asian stinging catfish *Heteropneustes fossilis* (Bloch) after exposure to 1/10th mg and 1/5th mg F/L of LC₅₀ of fluoride in water for 45 and 90 days. Activities of follicle stimulating hormone (FSH), luteinizing hormone (LH), testosterone (T) and estradiol (E) were measured using an enzyme-linked immunosorbent assay. Histological evaluation of the ovaries was conducted after staining with haematoxylin-eosin (HE). Reproductive hormones were significantly decreased after NaF-treated groups. Ovary was found to be adversely effected by exposure to NaF. Maturation of follicles was inhibited by exposure after observation of GSI and histology in ovary. These results suggest that female reproductive system is adversely affected by NaF. NaF may thus significantly reduce the fertility of female fish. This study encompasses alteration in hormonal assay to evaluate the role of vitamins C in the recovery of fluoride toxicity in fish. Vitamin C is a water-soluble ROS scavenger with high potency.

Keywords: Antioxidant, Asian stinging catfish, Gonadal hormone, Luteinizing hormone (LH), Reproductive toxicity, Serum FSH

Environmental pollution due to fluoride compounds is currently one of the most important problems due to its hazardous effect on ecosystems¹⁻³. Fluoride has been included as toxicant in the list of UNEP⁴. It is an electronegative element very reactive; belonging to halide group which is the 13th most abundant element of the earth's crust⁵. It enters the atmosphere mainly from anthropogenic sources i.e. manmade sources which include industrial discharges from the industries like fertilizers industries, paint industry, steel processing industry, glass, brick, ceramic industries etc. Natural sources like volcanic eruptions, rock dust or the marine environment make only a small contribution to fluoride contamination.

In higher concentration, fluoride can interfere with Glycogen, lipids, protein, enzymes and mineral metabolism^{6,7}. Reproduction is susceptible to disruption by fluoride that is sufficient to produce other manifestations of toxicity⁸. A number of animal studies indicate that adverse reproductive and developmental outcomes occur in individuals exposed

to relatively high concentration of fluoride⁹. The effect of fluoride on fertility has become an area of growing concern. Various studies show that fluoride causes adverse changes on both male and female fertility. Outcome of fluoride on reproductive status in relation to adverse effects and their amelioration are limited. It is also reported that in the epididymal secretory epithelium, impaired its metabolic and functional position, inhibited sperm maturation, motility and reduced fertility of sodium fluoride-treated animals (rats, mice, rabbits and guinea pigs)¹⁰⁻¹³. At the gonadal stage, steroid hormones are important and play essential roles in maintaining reproductive functions^{14,15}.

A number of antioxidants exist to balance the cellular production of ROS, maintaining the intracellular redox balance by preventing the cellular damage caused by ROS. Vitamin C is one of the most natural antioxidants in living system. It acts by inactivating damaged free radicals produced through normal cellular activity and diverse stressors, thus protects cell membranes and others intracellular component sensitive to oxidation^{16,17}. In this study, we have investigated the effects of sodium fluoride (NaF) exposure on morphological, hormonal and

*Correspondence:

Phone: 9918293184 (Mob.)

E-Mail: shivshankaryadav2008@gmail.com

histological changes in ovary in the Asian stinging catfish *Heteropneustes fossilis* (Bloch).

Materials and Methods

Experimental animals and chemicals

The fresh water cat fish *H. fossilis* (Mean weight 25.64 ± 0.16 g and length 16.89 ± 0.17 cm) were purchased from the local market in Lucknow and used for the chronic toxicity. They were acclimated to laboratory conditions for 25 days prior to the experiments. The specimens were given prophylactic treatment by bathing them twice in 0.05% KMnO_4 solution for 2 min to avoid any dermal infections. The NaF (AR grade) obtained from Qualigens Fine Chemicals Limited, Mumbai, India. Vitamin C was purchased from HiMedia.

Fishes were divided into five groups with 12 fish in each group. Control (without F added to the water) and Exposure (Low & High dose) was exposed to a concentration of fluoride 35 & 70 mg F ion/L (one-tenth & one-fifth of 96-h LC_{50} value). Pre-treatment (100 mg/L Vitamin C + low and high dose fluoride) and Post-treatment (low and high dose fluoride + 100 mg/L Vitamin C). At the end of the experiment, the fish were sacrificed. The ovary of both control and treated fish were dissected. The organs were washed in ice-cold physiological saline solution and stored at -80°C until analysis.

Biochemical estimation by serum

At the end of the each experimental duration, six fish were removed from the aquaria and used as replicates. Blood samples were taken from the caudal vein of each fish as described earlier¹⁸. This blood was collected in anticoagulant free centrifuge tubes. Serum was obtained by centrifugation of blood at 3500 rpm for 10 min. at 4°C . Serum samples were then stored at -80°C until analysis.

Hormonal Assay

FSH and LH activity was estimated by Marshall¹⁹ using Eliscan ELISA kit. Testosterone activity was estimated by using Labor Diagnostika Nord GmbH ELISA kit. Estrogen activity was estimated by Grant & Beastall²⁰ using ENZO Bio Life Sciences ELISA kit.

Histopathological examination of tissues

Samples of ovary washed with 0.9% saline, were taken for histopathological examinations. Samples were immediately fixed in 10% formalin, drained and embedded in paraffin. Sections was

made of the paraffin blocks and stained with haematoxylin-eosin (HE).

Statistical analysis

Results were expressed as mean and standard error (Mean \pm SE). Data was subjected to one way analysis of variance (ANOVA). The treatment groups were compared with a control group using Dunnett's test. All the statistics were carried out in Graph Pad In Stat Software Inc., v. 3.06, San Diageo, USA.

Results

Gonado somatic index (GSI)

After 45 & 90 days of fluoride exposure the GSI level was decreased significantly ($P < 0.001$, 27.99% and 39.80%) and ($P < 0.001$, 35.72% and 57.43%) in low dose as well as in high dose, respectively as compared with control.

The GSI level were increased significantly ($P < 0.01$, 35.03 and 50.21%) of low and high concentration of pre-treatment group, respectively. In post treatment group, it was increased significantly ($P < 0.01$, 35.98% and 37.57%) in both concentration group as compared with control (Fig. 1A).

Follicle stimulating hormone (FSH)

After 45 & 90 days fluoride exposure FSH activity was decreased significantly ($P < 0.01$, 22.01% and 38.61%) and ($P < 0.01$, 27% and 46.37%) in low and high dose group, respectively as compared with control.

In pre-treatment group of low and high concentration, FSH activity was increased significantly ($P < 0.01$, 23.69% and 7.06%), respectively. In post treatment group it was also increased significantly in low and high concentration ($P < 0.01$, 8.44% and 8.10%), respectively as compared with control (Fig. 1B).

Luteinizing hormone (LH)

After 45 & 90 days fluoride exposure the LH activity was decreased significantly ($P < 0.01$, 33.92% and 40.36%) and ($P < 0.01$, 61.78% and 50.64%) in low dose as well as in high dose, respectively as compared with control.

In pre-treatment group of low concentration the LH activity was increased significantly ($P < 0.01$, 15.04%) and at high concentration increased insignificantly ($P > 0.05$, 4.58%). In post treatment group it was increased significantly ($P < 0.01$, 22.75%) in low dose and at high dose ($P < 0.05$, 6.97%) as compared with control (Fig. 1C).

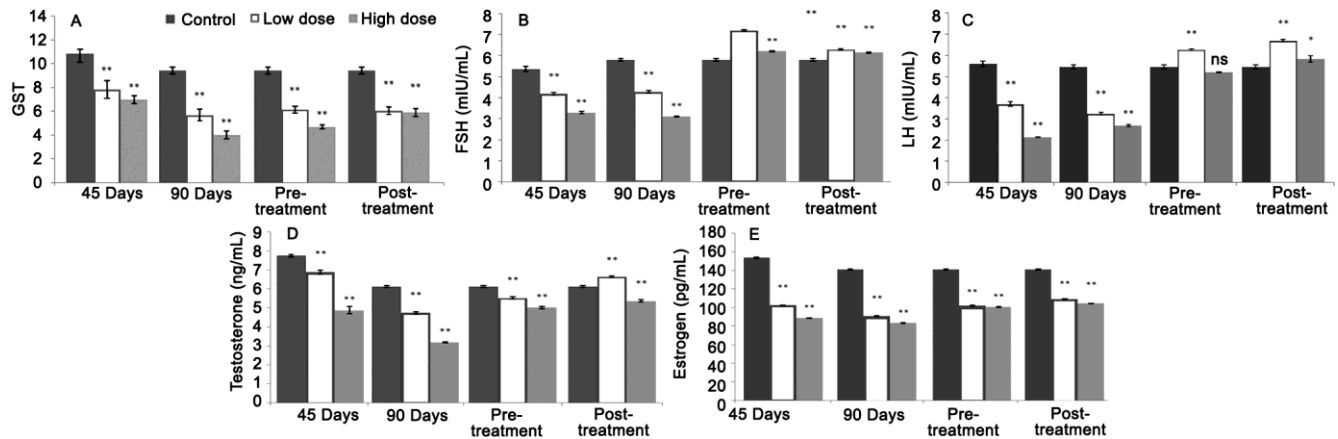


Fig. 1 — Effect of fluoride and vitamin C on (A) GSI level; (B) FSH activity; (C) LH activity; (D) Testosterone activity; and (E) Estrogen activity in *H. fossilis*. [Each bar expressed as mean \pm SE for (n=6) in each group. $P < 0.01$ **, $P > 0.05$ ns, $P < 0.05$ * as compared with Control. N, Nucleus; MO, Mature oocyte; AF, Atretic follicle; V, Vacuolisation; ROF, Rupture ovarian follicle; CMO, Crack of mature oocyte; NC, Necrosis; CYG, Clumping of yolk granules; AT, Atresia; DCA, Disrupted cortical alveolar stage; DO, Disrupted oocytes; and PS, Perinuclear stage].

Testosterone

After 45 & 90 days fluoride exposure, testosterone activity was decreased significantly ($P < 0.001$, 11.22%, and 37.03%) and ($P < 0.01$, 22.83% and 48.12%). in low and high concentration, respectively as compared with control.

In pre-treatment group of low and high concentration, it was increased significantly ($P < 0.05$, 10.12% and 18.17%), respectively. In post treatment group it was also increased significantly ($P < 0.01$, 8.15%) in low concentration and at high concentration ($P < 0.01$, 12.56%) as compared with control (Fig. 1D).

Estrogen

After 45 days fluoride exposure estrogens activity was decreased significantly ($P < 0.01$, 33.29% and 42.28%) in low and high concentration group respectively. At 90 days fluoride exposure it was also decrease significantly ($P < 0.05$, 35.55%) in low dose and at high dose ($P < 0.01$, 40.88%), respectively as compared with control.

In pre-treatment group of low and high concentration, estrogens activity was increased significantly ($P < 0.01$, 27.70% and 28.65%), respectively. In post treatment group it was also increased significantly ($P < 0.01$, 22.71% and 26.00%) in low and high dose respectively as compared with control (Fig. 1E).

Ovary

Histology of normal ovary reveals an outer layer thin peritoneum, a thick vascularised connective tissue and the close germinal epithelial layer

projecting into the part showed many oocytes in different stages of developmental with matured ova at some place.

Control group

After 45 and 90 days of experimentation, matured ova showed well formed rounded nuclei and the cytoplasm was full of yolk vesicles. All the oocytes and ova become visible well formed and in excellent condition. In the mature ova outer boundaries showed well formed outer most theca followed by zona granulosa and innermost zona radiata layer with deeply stained nuclei. The nucleus of mature ovum is large and rounded [Figs 2A(i) & B(ii)].

Experimental group

The ovary of *H. fossilis* exposed to different concentration of fluoride for 45 and 90 days showed several histological changes were observed. The sever changes were observed with increasing concentration of fluoride and duration of exposure.

Low concentration

After 45 & 90 days exposure, the ovary of lower concentration fluoride exposed group, it showed degenerative changes in the cytoplasm and nuclei of the ova in various stages of development. The degenerative changes appear to proceeds atresia of the ova. The production and growth of oocytes are retarded and the number of atretic follicles was enhanced. Ovarian follicle was found ruptured and vacuolization was seen in cytoplasm due to their liquification the cracks were also seen in mature oocytes. Degenerative changes in yolk nucleus were

more prominent. Cytoplasm and nucleus showed high affinity with stains. Heavy degenerative changes were observed in mature oocytes [Fig. 2A(ii) & B(ii)].

High concentration

After 45 & 90 days fluoride exposure, the nucleus showed pyknosis and karyolysis in different stages of oocytes in ovarian follicle. Various degenerative changes were seen in oocytes. Rupture of outer layer of ovarian follicles was observed. The ovarian wall becomes very thick. Production and growth of oocytes was retarded and the number of atretic follicle was increased. Vacuolization and degenerative

changes also appeared in nuclei and nucleolus. The theca and granulosa showed degenerative changes [Fig. 2A(iii) & B(iii)].

Pre- & Post treatment group

Pre-treatment of vitamin C showed restoration of histological changes in ovary after 90 days exposure with normalised degenerative changes were observed in mature oocytes. Theca and granulosa showed also normalise with degenerative changes (Fig. 3A & B).

After 90 days exposure post-treatment of vitamin C showed restoration of histological changes with proliferation and growth of oocytes was expanded and the number of atretic follicle was increased. Vacuolization and degenerative changes was normalised and also appeared in nuclei and nucleolus showed pyknosis (Fig. 3C & D).

Discussion

The gonado somatic index (GSI) is a good indicator of reproductive activity and is being used to determine the ovarian growth, stages of gonadal maturation and reproductive status²¹. In the present study decreased GSI have been observed after exposure to fluoride. Decreased GSI is known to indicate adverse effect on reproduction in animals²². It may be due to inhibited synthesis of various reproductive enzyme and hormones which are responsible for maturation and development of reproductive organs^{23,24}. Similar results have been reported in both *C. batrachus* and *H.fossilis* male and female GSI was found to be decreased in all groups maintained in different concentrations of sodium fluoride as compared to control group²⁵. Present study the role of vitamin C in pre and post treatment group GSI level was increased as compared to control. Similar result showed that after treatment of vitamin C improved the GSI²⁶.

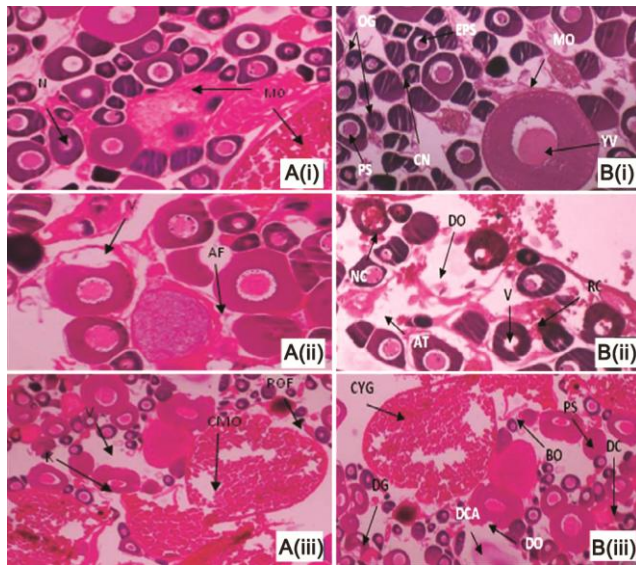


Fig. 2 — Photomicrograph of ovary of *H. fossilis* after 45 and 90 days exposure of fluoride. Fig. A(i) & B(i); control group showing normal structure of developing and mature oocytes with distinct nuclei. Fig. A(ii), B(ii) & C(i), C(ii); Low & high concentration exposed group showing marked cytoplasmic fragmentation, vacuolization and increase in atretic follicles, karyolysis and cracks in mature oocytes, degenerative changes in cytoplasm ruptured ovarian follicles, yolk liquefaction, vacuolization and nuclear degeneration respectively (arrow).

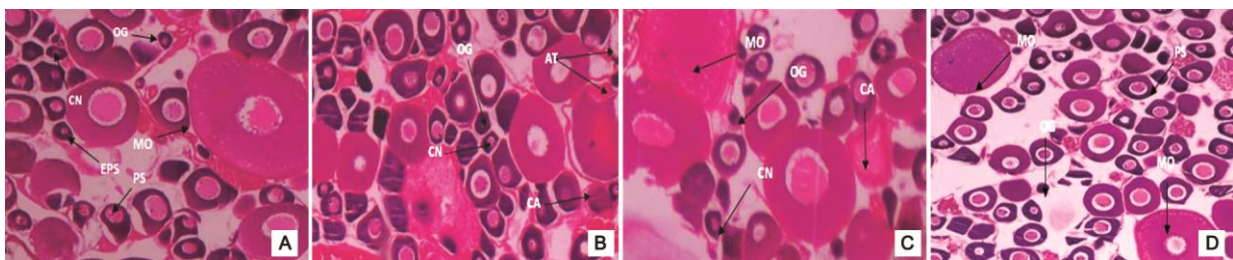


Fig. 3 — Pre-treatment and Post-treatment. Photomicrograph of ovary of *H. fossilis* was treated with vitamin C (100 mg/L) and exposed to low & high concentration (35 & 70 mg/L) of fluoride showing recovery of necrosis, vacuolization, gain of oocytes. Normalized vacuolization, karyolysis and loss of disorganization was observed after 90 days of exposure. (Arrow) (Fig. A, B). Photomicrograph of ovary of *H. fossilis* exposed to low and high concentration (35 & 70 mg/L) of fluoride and treated with vitamin C (100 mg/L) showing normalized atretic follicles, maturation of oocytes was normal vacuolization and degeneration of nuclear was normalized after 90 days of exposure. (Arrow) (Fig. C, D)

Hormones play an important role in physiological activities of animals. In females ovary is the target for FSH. Each month FSH initiates the development of several ovarian follicles, secretary cells that surround a developing oocyte. FSH also stimulate follicle cell to secrete estrogens. Gonadotropin releasing hormone (GnRH) from the hypothalamus stimulates FSH release. In females LH triggers ovulation the release of secondary oocyte (ovum) from ovary. LH stimulates formation of the corpus luteum in the ovary and the secretion of progesterone by the corpus luteum. Together FSH and LH also stimulate secretion of estrogens by ovarian cells. Secretion of LH like that of FSH is controlled by GnRH. Pituitary gonadotropins, FSH and LH play central roles in regulating gametogenesis and the production of gonadal hormones required for the development of sexual behaviour and secondary sex characters in all vertebrates. In present study the activity of FSH and LH hormone decreased significantly after exposure to different concentration of fluoride. It may be due to decrease in the biosynthesis. Similar observation have reported reduced fertility in the next generation and different doses of lead showed a dose-dependent decrease in testosterone and LH secretion as well as suppressed plasma estrogen activity during maturation in female's rat^{27,28}. Trojnar *et al.*²⁹ also reported decrease in testosterone and LH as well as estradiol activity in female *Prussian carp* after treatment of lead exposure. Alexandra *et al.*³⁰ have reported that Aluminium can inhibit synthesis of FSH and LH. Meiyang Li *et al.*³¹ also reported decreased activity of FSH and LH hormones after exposure to fluoride. Declined LH may reduce ovulation and lower FSH, resulting in abnormal development of ovarian follicles, such as follicular atresia, degeneration and bubble-shaped cavity. The decreased FSH and LH may decrease synthesis of aromatizing enzyme³² and inhibit reproductive function through disturbing the synthesis of oestrogen and progesterone³³.

Testosterone is a steroid hormone, responsible for the growth and development of male secondary sex organs and secondary characters. It stimulates spermatogenesis. In our study, there was a significant decrease in the activity of testosterone after fluoride exposure. It may be due to diminished responsiveness of leydig cells to LH and direct inhibition of testosterone synthesis in *H. fossilis* after fluoride exposure. Similarly Zhou *et al.*³⁴ reported that the activity of FSH, LH, testosterone and estrogen were

decreased after treatment with sodium fluoride in female rats. The adverse effect of fluoride on spermatogenesis may be because fluoride reduces the testosterone activity. In present study, it was found gonadal secretion of estrogens and testosterone was decreases in the sodium fluoride-treated groups. Previous study has confirmed that steroid hormones, such as estrogen and testosterone, play an important role in the growth and differentiation of reproductive organs and in the maintenance of reproductive functions³⁵. Estrogen can enhance the sensitivity of granulosa cells to FSH and LH, thereby increasing the biosynthesis of progesterone by granulosa cells³⁶. Estrogen modulates steroidogenesis, promotes granulosa cell proliferation and maintains follicular development^{37,38}. Similarly, Reddy *et al.*³⁹ who have reported that the decrease in circulatory testosterone levels could be due to diminished responsiveness of leydig cells to LH and direct inhibition of testosterone synthesis in rats exposed to fluoride during embryonic development and suckling periods. Earlier studies also show that exposure to fluoride induces adverse changes on both male and female reproduction. Decreased testosterone concentrations have been reported in skeletal fluorosis patients and in men drinking the water as the patients¹¹.

Estrogen is a group of steroid hormone. It is mainly secreted by follicular epithelial cells of membrana granulosa of graffian follicles. Secretion of estrogen is stimulated by LH from anterior lobe of pituitary gland. It includes estrodiol, estriol and estrone. Estrodiol is principle estrogens. It regulates the female reproductive cycle, oogenesis and stimulates growth and development of female secondary sex organs and secondary sexual characteristics. Hormones play central roles in the regulation of uterine environment. The principal hormones that specify uterine receptivity are ovarian steroids estrogen and progesterone⁴⁰. The present study indicates that the activity of serum estradiol declined in sodium fluoride treated groups. It may be due to sodium fluoride treatment inhibited estradiol synthesis and release. Similar results have also reported that sodium fluoride cause to damage reproductive function in female rats³⁶. Similarly, many workers have reported that cadmium and aluminium also exert toxic effects on ovarian steroids estrogen and progesterone synthesis and release in rats⁴¹. Mishra & Mohanty⁴², reported disruption of pituitary ovarian axis on the basis of immune characteristics of

pituitary gonadotrophs as well as alterations in serum level of 17β -estradiol. In addition, atrophy of the gonadotrophs and their less immunoreactivity indicating disruptions at pituitary which might further affect ovarian steroidogenesis as production of estradiol in teleosts is dependent on pituitary gonadotropins FSH^{43,44}.

In our study pre and post treatment group of fluoride exposure the level of FSH, LH, testosterone and estrogen increased as compared to control. It may be due to vitamin C scavenges of free radical and ROS. Similar observations have reported vitamin C and vitamin E treatment on lead intoxicated animals significant increase in reproductive hormones⁴⁵. Vitamin C treatment showed a higher ameliorative effect on testosterone, FSH levels and sperm motility and morphology as compared to vitamin E treatment.

Present study indicates that sodium fluoride inhibits the secretion of FSH and LH from the pituitary gland, thus weakening the promotional activity of FSH and LH on ovarian granular cells. Decrease of testosterone and estrogens secretion is consistent with weakened FSH and LH promotional activity. In our study, after fluoride exposure ovary showed several degenerative changes including hyperplasia of germinal epithelium reduction in the ovarian weight, retarded growth of the pre-vitellogenic oocytes, and rupture of follicular epithelium, cytoplasmic clumping fragmentation and karyolysis of ova. These findings suggest that the cellular changes in the ovary might be a reflection of the disturbance in the hormonal imbalance. Similar observations have been reported by several workers^{46,47}. Similar results have been reported by Hitesh⁴⁸ who found changes in gonadal tissue of *Poecilia reticulata* after chronic exposure to fluoride. Sodium fluoride treated ovary of fish showed significant increase in atretia, increase frequency of premature oocyte, an increase the interfollicular spaces. Interfollicular tissue was degenerated and vacuolization was observed within follicle. The epithelium of ovum was ruptured and there was increase folding of epithelium. Fragmentation and karyolysis was seen with decreased ovarian activity. Similarly, Sharma *et al.*⁴⁹ reported that long term exposure of cadmium chloride in *H. fossilis* resulted in marked degenerative changes in the ovary. These changes included prominent interfollicular spaces, appearance of atretic follicles, degenerative change in nucleus and ovarian follicles. Similar

results reported that the changes in gonads are mostly duration and dose dependent. It was observed that fluoride treatment cause vacuolization of oocyte, inhibition of yolk synthesis, emptying of follicle and damaged oocyte. Vitamin C increase reproduction performances such as ovarian growth in common carp. In fishes it has been establishments that vitamin C is an important role in reproduction^{50,51}.

Conclusion

In present study concluded that after exposure of *H. fossilis* with different doses of fluoride. GSI were found to be decreased significantly where as it was increased insignificantly after treatment of vitamin C as compared with control. Vitamin C significantly increased the GSI value. FSH, LH, testosterone and estrogen level were found to be decreased significantly after different concentration of fluoride. In this regard, the observation of inhibitory action of fluoride on these hormones suppressing gonadal development of fish has significance. In pre- and post-treatment of vitamin C, it was increased significantly. Histological alterations were found in the ovary after fluoride exposure, which were corrected to some extent by the treatment with vitamin C.

Acknowledgement

The authors are thankful to the Head, Department of Zoology University of Lucknow, for providing the necessary facilities and suggestions.

Conflict of interest

There are no conflict of interest.

References

- 1 World Health Organization (WHO), Environmental Health Criteria: 227 Fluoride IPS, Geneva Switzerland, (2002) 2012.
- 2 ATSDR Toxicological profile for fluorides, hydrogen fluoride, and fluorine; US Department of Health and Human Services, Public Health Service Agency for Toxic Substances and Disease Registry; Atlanta, GA. <http://www.atsdr.cdc.gov/ToxProfiles/tp.asp?id0212&tid038>. Accessed March, (2003) 2012.
- 3 Divan AM, Oliva MA & Ferreira FA, Dispersal fluoride accumulation in eight plant species. *Ecological Indicators*, 8 (2008) 454.
- 4 Sharma PD, Environmental pollution in Ecology and Environment, 7th edition *Rastogi Publication Meerut*, India. (2002) 417.
- 5 Nowak B, Sicilio L, Kizior C, Tedder G, Zimmerman N & Bobo N, Advocating for oral health through fluoridation. *NASN Sch Nurse*, 34 (2019) 288.
- 6 Bajpai S, Tripathi N, Tewari S & Tripathi M, Retardation of growth after fluoride exposure in Catfish, *Heteropneustis*

- fossilis* (Bloch). Bioresources for Rural Livelihood. Narendra Publishing House, 1 (2010)167.
- 7 Yadav SS, Kumar R, Khare P & Tripathi M, Oxidative stress biomarkers in the freshwater fish, *Heteropneustes fossilis* (Bloch) exposed to sodium fluoride: Antioxidant Defense and role of ascorbic acid. *Toxicol Int*, 22 (2015) 71.
 - 8 Spittlea B & Meiersb P, Fluoride poisoning: is fluoride in your drinking water—and from other sources making you sick. Review of fluoride poisoning: Is Fluoride in your Drinking Water. *Fluoride*, 40 (2007) 250.
 - 9 Dhar V & Bhatnagar M, Physiology and toxicity of fluoride. Official Publication of Indian Society for Dental Research. *Indian J Dental Res*, 20 (2009) 350.
 - 10 Narayana MV & Chinoy NJ, Effect of fluoride on rat testicular steroidogenesis. *Fluoride*, 27(1994) 7.
 - 11 Susheela AK & Jethanandani P, Circulating testosterone levels in skeletal fluorosis patients. *J Toxicol Clin Toxicol*, 34(1996)183.
 - 12 Ortiz-Perez D, Rodriguez-Martinez M, Martinez F, Borja-Aburto VH, Castelo J, Grimaldo JI, Cruz EDL, Carizales L, & Barriga FD, Fluoride induced disruption of reproductive hormones in men. *Environ Res*, 93 (2003) 20.
 - 13 Wang J, Zhang Y, Zhang H, Zhang K, Zhang Z & Li J, Toxic effects of fluoride on reproductive ability in male rats: sperm motility, oxidative stress, cell cycle, and testicular apoptosis. *Fluoride*, 42 (2009) 174.
 - 14 Kime DE, A strategy for assessing the effects of xenobiotics on fish reproduction. *Sci Tot Environ*, 225 (1999) 3.
 - 15 Rurangwa E, Roelants I, Huyskens G, Ebrahimi M, Kime DE & Ollevier F, The minimum acceptable spermatozoa to egg ratio for artificial insemination and the effects of heavy metal pollutants on sperm motility and fertilization ability. In the African catfish (*Clarias gariepinus*, Burchell 1822). *J Fish Biol*, 53 (1998) 402.
 - 16 Halver JE, Vitamin requirement study techniques. *J Appl Ichthyol*, 11 (1995)215.
 - 17 Eman A, Gawad AE, Omnia M & Hamid A, Effect of vitamin C dietary supplementation in reducing the alterations induced by fenitrothion in *Oreochromis niloticus*. *Fish Physiol Biochem*, 1 (2013) 10.
 - 18 Congleton JL & LaVoie WJ, Comparison of blood chemistry values for samples collected from juvenile Chinook salmon by three methods. *J Aquat Anim Health*, 13 (2001)168.
 - 19 Marshall JC, Clinics in endocrinology and metabolism. Investigative procedures. *Clin Endocrinol Metab*, 4 (1975) 545.
 - 20 Grant JK & Beastall GH, *Clinical Biochemistry of Steroid Hormones: Methods and Applications*, (Elsevier, Amsterdam), 1983.
 - 21 Hojo RES, Santos GB & Bazzoli N, Reproductive biology of Moenkhausia intermeida (Eigenmann) (Pisces, Characiformes) in Itumbiara Reservoir, Goias, Brazil. *Revista Brasileira de Zoologia*, 21 (2004) 519.
 - 22 Chinoy NJ, Effect of fluoride on physiology of animals and human beings: a review. *J Environ Toxicol*, 1 (1991) 17.
 - 23 Freni SC, Exposure to high fluoride concentrations in drinking water is associated with decreased birth rates. *J Toxicol Environ Health*, 42(1994) 109.
 - 24 Chinoy NJ & Sharma AK, Amelioration of fluoride toxicity by vitamin E and D in reproductive function of male mice. *Fluoride*, 31 (1998) 203.
 - 25 Agniwanshi S, Shedpure M & Jain N, Effect of sodium fluoride on body weight gain and gonadosomatic index in freshwater catfishes. *J Ind Poll Cont*, 30 (2014) 339.
 - 26 Javadi MM & Jafari VA, Effect of dietary supplementation of vitamin C on the reproductive performance of female live bearing ornamental fish. *J Anim Vet Adv*, 10 (2011) 2074.
 - 27 Dearth RK, Hiney JK, Srivastava V, Burdick SB, Bratton GR & Dees WL, Effects of lead (Pb) exposure during gestation and lactation on female pubertal development in the rat. *Reprod Toxicol*, 16 (2002) 343.
 - 28 Ronis MJ, Gandy J & Badger T, Endocrine mechanisms underlying reproductive toxicity in the developing rat chronically exposed to dietary lead. *J Toxicol Environ Health*, 54 (1998) 77.
 - 29 Trojnar EL, Kozak ED, Szczerbik P, Socha M & Popek W, Effect of long-term dietary lead exposure on some maturation and reproductive parameters of a female Prussian carp (*Carassius gibelio B.*). *Environ Sci Pollut Res*, 21 (2014) 2465.
 - 30 Alexandra T, Eugenia D & Muselin F, The consequences of chronic aluminum sulphate intake on exposure and morphological integrity biomarkers (aluminum level and weight of sexual organs) in female rats. *Lucrari Științifice Medicina Veterinara*, 41 (2008) 981.
 - 31 Meiyang Li, Jinling C, Yangfei Z, Panhong W, Xuehual Li, Forouzan K, Yongli H & Jundong W, Fluoride impairs ovary development by affecting oogenesis and inducing oxidative stress and apoptosis in female zebra fish (*Danio rerio*). *Chemosphere*, 256 (2020) 127105.
 - 32 Wang C, Hsueh AJ & Erickson GF, The role of cyclic AMP in the induction of estrogen and progesterin synthesis in cultured granulosa cells. *Mol Cell Endocrinol*, 25 (1982) 73.
 - 33 Wang N, Yue S, Zhu YZ, Zhao HN, Shao B, Sun H, Hu C & Li Y, Effects of subchronic aluminum exposure on the reproductive function in female rats. *Biol Trace Elem Res*, 145 (2012) 382.
 - 34 Zhou Y, Zhang H, He J, Chen X, Ding Y, Wang Y & Liu X, Effects of sodium fluoride on reproductive function in female rats. *Food and Chem Toxicol*, 56 (2013) 297.
 - 35 Da Silva Faria T, De Bittencourt Brasil F, Sampaio FJB & Da Fonte Ramos C, Effects of maternal undernutrition during lactation on Estrogen and Androgen receptor expressions in rat ovary at puberty. *Nutrition*, 26 (2010) 993.
 - 36 Welsh TH, Zhuang LZ & Hsueh AJ, Estrogen augmentation of gonadotropin-stimulated progesterin biosynthesis in cultured rat granulosa cells. *Endocrinology*, 112 (1983) 1916.
 - 37 Robker RL & Richards JS, Hormone-induced proliferation and differentiation of granulosa cells: a coordinated balance of the cell cycle regulators cyclin D2 and p27Kip1. *Mol Endocrinol*, 12 (1998) 924.
 - 38 Drummond AE & Findlay JK, The role of estrogen in folliculogenesis. *Mol Cell Endocrinol*, 151 (1999) 57.
 - 39 Reddy PS, Puspalatha T & Reddy PS, Suppression of male reproduction in rats after exposure to sodium fluoride during early stages of development. *Natur Wissen Schäften*, 94 (2007) 607.
 - 40 Wang H & Dey SK, Roadmap to embryo implantation: clues from mouse models. *Nat Rev Gen*, 7 (2006) 185.
 - 41 Zhang W, Pang F, Huang Y, Yan P & Lin W, Cadmium exerts toxic effects on ovarian steroid hormone release in rats. *Toxicol Lett*, 182 (2008) 18.

- 42 Mishra AK & Mohanty B, Effect of Sublethal Hexavalent Chromium Exposure on the Pituitary-Ovarian Axis of a Teleost, *Channa punctatus* (Bloch). *Environ Toxicol*, 27 (2012) 415.
- 43 Specker JL, Sullivan CV, Davey KG, Peter RE & Tobe SS, Vitellogenesis in fishes status and perspectives in comparative endocrinology. (National Research Council, Ottawa), 1994, 304.
- 44 Okuzawa K, Puberty in teleosts. *Fish Physiol Biochem*, 26 (2002) 31.
- 45 Ayinde OC, Ogunnowo S & Ogedegbe RA, Influence of Vitamin C and Vitamin E on testicular zinc content and testicular toxicity in lead exposed albino rats. *Pharm Toxicol*, 13 (2012) 17.
- 46 Dutta HM, Nath A, Adhikari S, Roy PK, Singh NK & Munshi JSD, Sublethal Malathion induced changes in the ovary of an air-breathing fish, *Heteropneustes fossilis*: a histological study. *Hydrobiologia*, 294 (1994) 215.
- 47 Chatterjee S, Dutta AB & Ghosh R, The influence of technical grade carbofuran (CF) on the egg maturational processes of catfish, *Heteropneustes fossilis* (Bloch). *Arch Environ Contam Toxicol*, 32 (1997) 426.
- 48 Hitesh US, Histoarchetuctural changes in gonadal tissue of *Poecilia reticulata* Peters on chronic exposure to sodium fluoride. *Bionano Front*, 4 (2011) 237.
- 49 Sharma S, Manhor S, Qureshi TA, Kaur P & Dar BA, Histological studies on the cadmium chloride exposed air-breathing fish, *Heteropneustes fossilis* (Bloch) with special reference to ovaries. *Int J Environ Sci*, 2 (2011) 423.
- 50 Emata AC, Borlongan IG & Damaso JP, Dietary vitamin C and E supplementation and reproduction of milkfish *Chanos forsskal*. *Aquacult Res*, 31 (2000) 557.
- 51 Dobrowaski K & Ciereszko A, Ascorbic acid and reproduction in fish: endocrine regulation and gamete quality. *Aquacult Res*, 32 (2001) 623.