

Effects of Rutin on Lipid Profile in Hypercholesterolaemic Rats

Amir Ziaee^{1,2}, Farzaneh Zamansoltani^{2,3}, Marjan Nassiri-Asl^{2,4} and Esmail Abbasi⁴

¹Department of Endocrinology, Qazvin University of Medical Sciences, Qazvin, Iran, ²Qazvin Metabolic Disease Research Centre, Qazvin University of Medical Sciences, Qazvin, Iran, ³Department of Anatomy, Qazvin University of Medical Sciences, Qazvin, Iran,

⁴Department of Pharmacology, Qazvin University of Medical Sciences, Qazvin, Iran

(Received July 30, 2008; Accepted October 10, 2008)

Abstract: Rutin (3, 3', 4', 5, 7-pentahydroxyflavone-3-rhamnoglucoside) is a flavonoid of the flavonol type. Rutin is found in many plants and is also an important dietary constituent of food and plant-based beverages. Rutin has several pharmacological properties including antioxidant and cardioprotective activities. Also, it was identified that rutin is the major low-density lipoprotein (LDL) antioxidant compound of mulberry in an *in vitro* study. The effects of rutin were tested by using it as a supplement in a high-cholesterol diet. Male rats were fed a high-cholesterol diet (1 ml/100 g) for 4 weeks with rutin (10 or 100 mg/kg) or rutin 100 mg/kg and lovastatin supplementation to study the hypocholesterolaemic effects of rutin on plasma lipid levels, hepatic enzyme activity, and liver tissue. Feeding the animals a high-cholesterol diet resulted in marked hypercholesterolaemia and increased the serum level of LDL cholesterol (LDL-C). Rutin (at 100 mg/kg) alone or in combination with lovastatin significantly reduced the levels of total cholesterol, and LDL-C and also markedly decreased liver enzymes and weight in animals with a high-cholesterol diet. Our findings show that 100 mg/kg of rutin alone or with lovastatin supplementation lowered liver weight and enzymes as well as plasma total cholesterol and LDL. The hepatic histopathological results reflect the correlation of rutin and lovastatin combination with both liver weight and the levels of plasma total cholesterol and LDL-C. These results indicate that rutin in combination with lovastatin has increased anti-hypercholesterolaemic effects in an animal model.

Cardiovascular disease is now the most common cause of death worldwide. Lipid levels are a metabolic risk factor for cardiovascular disease and abnormalities in plasma lipoprotein classes, and derangements in lipid metabolism rank among the most firmly-established and best-understood risks factors for atherosclerosis [1]. Plasma cholesterol levels are regulated by the absorption of dietary cholesterol, excretion of cholesterol via faecal sterols or bile acids, cholesterol biosynthesis, and removal of cholesterol from circulation. Numerous previous studies have reported on the beneficial effects of hepatic 3-hydroxy-3-methylglutaryl-CoA (HMG-CoA) reductase and acyl-CoA: cholesterol acyltransferase inhibitors of hypercholesterolaemia and atherosclerosis [2,3]. Low-density lipoprotein cholesterol (LDL-C) transports cholesterol from liver to tissues, whereas high-density lipoprotein cholesterol (HDL-C) facilitates the translocation of cholesterol from the peripheral tissues to the liver for catabolism. Therefore, HDL-C has a useful effect in reducing tissue cholesterol and an elevated ratio of HDL-C in serum is suggested together with a decreased level of LDL-C to reduce the risk of cardiovascular diseases [4].

In recent decades, it has been shown that a high-cholesterol level and a high ratio of saturated and monounsaturated to polyunsaturated fatty acids in the blood predisposes patients to vascular diseases, whereas a high dietary intake of vegetables and fruits has the opposite effect [5,6]. Similarly, it was reported that the intake of flavonoids inversely

correlates with the plasma total cholesterol and LDL-C concentrations in human beings [7]. Flavonoids are dietary phenolic compounds that are widely distributed in nature and are ubiquitous in plants, fruits, seeds and vegetables. They possess anti-inflammatory, antiviral, antioxidant, hepatoprotective, antithrombotic, anticarcinogenic, and other biological effects [6].

Rutin (3, 3', 4', 5, 7-pentahydroxyflavone-3-rhamnoglucoside, fig. 1) is a flavonoid of the flavonol type. Rutin is found in many typical plants such as buckwheat and apples. It is also an important dietary constituent of other foods and plant-based beverages [8]. It was reported that rutin has several pharmacological properties including antioxidant, anticarcinogenic, cytoprotective, antiplatelet, antithrombotic, vasoprotective and cardioprotective activities [9–14]. Moreover, rutin was found to be a neuroprotective agent and can

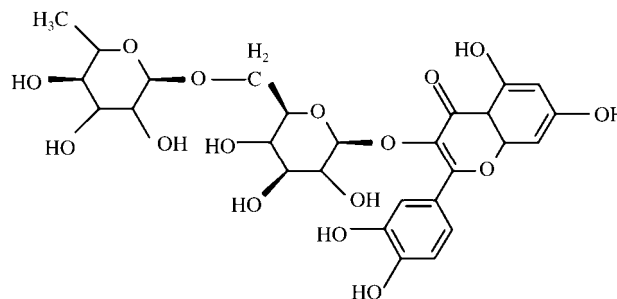


Fig. 1. Chemical structure of rutin.

ameliorate ischaemic reperfusion injury in the heart, brain, and skeletal muscle [15–19]. Rutin was identified to be the major LDL antioxidant compound of mulberry in an *in vitro* study [20].

Therefore, in this study we examined the hypocholesterolaemic effects of chronic administration of rutin in rats. It was predicted that rutin would show hypocholesterolaemic effects on the lipid profile and liver tissue because of its properties.

Material and Methods

Animals. Male Wistar rats (250–300 g) were obtained from the Razi Institute (Karaj, Iran) and housed in groups of four per cage under standard laboratory conditions. They were kept at constant room temperature ($21 \pm 2^\circ$) under a normal 12 hr light : 12 hr dark regime with free access to food and water. All animal experiments were carried out in accordance with the European Communities Council directive of 24 November 1986 (86/609/EEC) in such a way as to minimize their suffering.

Chemicals. Rutin and cholic acid were purchased from Sigma and Merck. The other drugs used in this study were lovastatin (Tehran Chemie Pharmaceutical Co, Iran), propylthiouracil (Iran Hormone, Tehran, Iran), ketamine (Rotexmedica, GmbH, Germany), and xylazine (Loughrea Co, Galway, Ireland).

Rat model of hypercholesterolaemia. In rats, hypercholesterolaemia was induced by gavage by daily administration of 1 ml/100 g body weight of a cocktail containing in 1 l peanut oil: 100 g cholesterol, 30 g propylthiouracil and 100 g cholic acid over a period of 28 days. The test compounds were administered simultaneously with the cocktail [21].

The rats were divided into six groups of 10 animals in each group. Group I received peanut oil orally (1 ml/100 g). Group II received cocktail only as described above. Group III received cocktail and lovastatin (10 mg/kg). Group IV received cocktail and rutin (10 mg/kg); Group V received cocktail and rutin (100 mg/kg); Group VI received cocktail and lovastatin (10 mg/kg) and rutin (100 mg/kg).

Laboratory testing. The lipid profile was analysed using commercially available kits for HDL-C, LDL-C, total cholesterol, and triglycerides (Pars Azmoon, Iran) and expressed in mg/dl. Serum total T_4 was determined by electrochemiluminescence immunoassay (ECLIA, Roche, Germany) and expressed in nmol/l. Plasma alanine aminotransferase (ALT) and aspartate aminotransferase (AST) were analysed using biochemical analysis kits (Pars Azmoon, Iran) and expressed in IU/l.

Twenty-four hours after the last gavages, the rats were anaesthetized with an injection of ketamine (60 mg/kg intraperitoneally) and xylazine (6 mg/kg intraperitoneally). Blood samples were taken from the left ventricle of the heart and collected into the test tubes to obtain serum. Samples were subsequently centrifuged for 10 min. (4000 \times g). Serum was separated and used for the assessment of total cholesterol, LDH-C, LDL-C, triglycerides, AST and ALT.

Liver histopathological assessment. The livers were removed, weighed and then cut into small pieces. Liver sections were fixed in 10% formalin, dehydrated in gradual ethanol (50–100%), cleared in xylene, and embedded in paraffin. Sections (4–5 μ m thick) were prepared and stained with haematoxylin and eosin dye for histopathological examination and observed under a microscope at a magnification 100 \times [22].

Statistics. The data were expressed as mean values \pm S.E.M and tested with ANOVA followed by the multiple comparison test of Tukey–Kramer. Results with $P < 0.05$ were considered significant.

Results

Laboratory testing

Feeding rats a high cholesterol diet in group II for 28 days resulted in hypercholesterolaemia, as evidenced by high serum total cholesterol and LDL-C, which were more than the vehicle animals (table 1). Total cholesterol in groups IV, V and VI was reduced by 21.1%, 17.6% and 18.4%, respectively, compared to group II. The total cholesterol in group III decreased by 14.7% compared to group II.

LDL-C levels in groups IV and V decreased by 48.4% and 47.5%, respectively, compared to group II. However, LDL-C in groups III and VI was reduced by 59.4% and 55.2%, respectively, compared to group II. The differences between all groups were not as significant as regards HDL-C and triglyceride levels. Furthermore, serum total T_4 of all groups was significantly reduced compared to group I.

The measured plasma AST and ALT activities in rats that consumed the rutin-supplemented high cholesterol diet and lovastatin are shown in figs 2 and 3. The difference between the plasma AST and ALT activities in group II and I was significant ($P < 0.001$). Plasma AST in groups IV and V was reduced compared to group II by 30.4% and 41.5%, respectively. The difference between groups V and I was not significant. However, the difference between groups IV and

Table 1.

Effects of rutin and lovastatin supplementation on the serum lipid profile in hypercholesterolaemic rats.

Parameter	Group I	Group II	Group III	Group IV	Group V	Group VI
TC (mg/dl)	143 \pm 4	374 \pm 2*	319 \pm 1.5 [†]	295 \pm 16.4 [‡]	308 \pm 12 [‡]	305 \pm 2 [‡]
TG (mg/dl)	80 \pm 6	111 \pm 14	102 \pm 3	86 \pm 18	95 \pm 15	97 \pm 8
LDL-C (mg/dl)	76 \pm 3	281 \pm 2*	114 \pm 2 [‡]	145 \pm 7 [‡]	147 \pm 8 [‡]	126 \pm 5 [‡]
HDL-C (mg/dl)	49 \pm 3	42 \pm 1	38 \pm 5	49 \pm 1	35 \pm 3	37 \pm 3
T_4 (nmol/l)	62 \pm 2.3	12.6 \pm 0.3*	12*	10.5 \pm 0.1*	10.2 \pm 0.3*	8.7 \pm 0.5*

Group I: Vehicle; Group II: Cocktail; Group III: Cocktail + lovastatin (10 mg/kg); Group IV: Cocktail + rutin (10 mg/kg); Group V: Cocktail + rutin (100 mg/kg); Group VI: Cocktail + lovastatin (10 mg/kg) + rutin (100 mg/kg).

Values are the mean \pm S.E.M. for 10 rats. * $P < 0.001$ compared to group I; [†] $P < 0.01$, [‡] $P < 0.001$ compared to group II, Tukey–Kramer Test. TC, total cholesterol; TG, triglycerides.

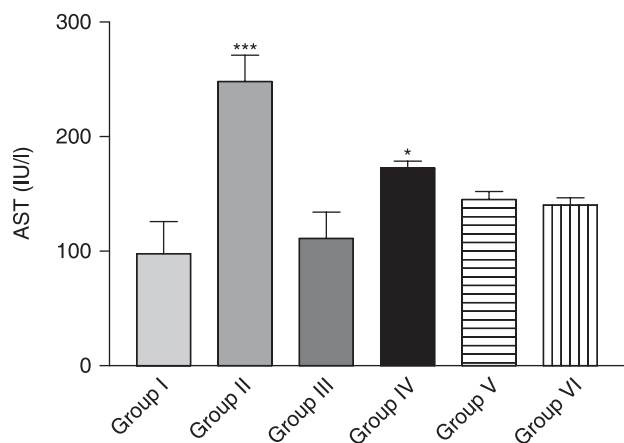


Fig. 2. Effect of rutin on plasma AST levels in hypercholesterolaemic rats. Group I: Vehicle; Group II: Cocktail; Group III: Cocktail + lovastatin (10 mg/kg); Group IV: Cocktail + rutin (10 mg/kg); Group V: Cocktail + rutin (100 mg/kg); Group VI: Cocktail + lovastatin (10 mg/kg) + rutin (100 mg/kg). Values are the mean \pm S.E.M. for 10 rats. * $P < 0.05$, *** $P < 0.001$ compared to group I, Tukey–Kramer test.

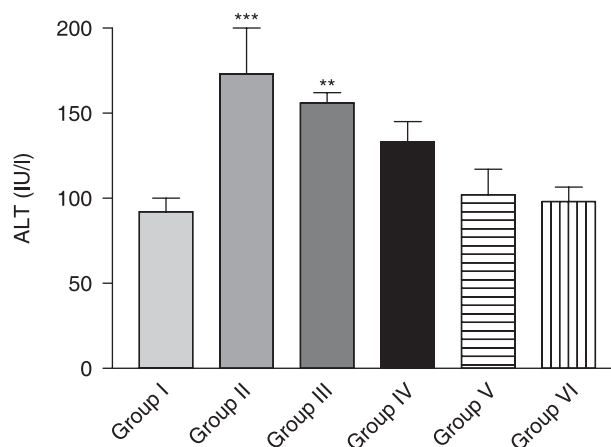


Fig. 3. The effect of rutin on plasma ALT levels in hypercholesterolaemic rats. Group I: Vehicle; Group II: Cocktail; Group III: Cocktail + lovastatin (10 mg/kg); Group IV: Cocktail + rutin (10 mg/kg); Group V: Cocktail + rutin (100 mg/kg); Group VI: Cocktail + lovastatin (10 mg/kg) + rutin (100 mg/kg). Values are the mean \pm S.E.M. for 10 rats. ** $P < 0.01$, *** $P < 0.001$ compared to group I, Tukey–Kramer test.

I was significant ($P < 0.05$) (fig. 2). Moreover, groups IV and V had a decreased plasma ALT compared to group II by 23.1% and 41%, respectively (fig. 3).

Plasma AST in group III was reduced by 55.2% compared to group II. The difference between groups III and I was not significant (fig. 2). Plasma ALT was reduced in group III by 9.8% compared to group II. Moreover, the differences between groups III and I were significant ($P < 0.01$) (fig. 3).

Plasma AST in group VI was reduced by 43.5% compared to group II. The difference between groups VI and I was not significant (fig. 2). Also, plasma ALT was reduced in group VI by 43.3% compared to group II and the difference between groups VI and I was not significant (fig. 3).

Effect on liver weight : body weight ratio.

The ratio of liver weight : total body weight was significantly higher in group II than in group I ($P < 0.01$) (table 2). Moreover, liver weight : body weight ratio was not different between groups V and VI in comparison with group I.

Histological results.

In group I, a normal lobular pattern, hepatic cells with well-preserved cytoplasm, a prominent nucleus, and a

well-visualized central vein were observed (fig. 4A). In group II, microvesicular fatty changes, small-droplet fat in hepatocytes with centrally located nuclei, mononuclear inflammatory infiltration, and venous congestion were observed (fig. 4B). In group III, small-droplet fat in hepatocytes of zone III and mononuclear inflammatory infiltration was observed (fig. 4C). In group IV, steatosis in zone III and mononuclear inflammatory infiltration was observed (fig. 4D). In group V, no steatosis or inflammation was found. However, venous congestion was occasionally observed (fig. 4E). In group IV, the appearance of the cells was similar to the control group. Steatosis and inflammation were not found (fig. 4F).

Discussion

Rats are generally considered to be resistant to naturally-occurring and experimentally-induced atherosclerosis [23]. High doses of dietary cholesterol combined with bile acids and experimentally induced hypothyroidism have been demonstrated to lead to the development of atherosclerotic lesions in rats [24]. Therefore, in the current study hypercholesterolaemia was induced in rats, evident from the total cholesterol level in plasma after feeding the animals a

Table 2.

Effect of rutin and lovastatin supplementation on liver weight : body weight (LW : BW) ratio in hypercholesterolaemic rats.

Mean	Group I	Group II	Group III	Group IV	Group V	Group VI
LW : BW (mg/g)	40.3 \pm 0.7	61.4 \pm 3**	60.4 \pm 3**	65.4 \pm 3*	52.2 \pm 4	55.3 \pm 1.6

Group I: Vehicle; Group II: Cocktail; Group III: Cocktail + lovastatin (10 mg/kg); Group IV: Cocktail + rutin (10 mg/kg); Group V: Cocktail + rutin (100 mg/kg); Group VI: Cocktail + lovastatin (10 mg/kg) + rutin (100 mg/kg).

Values are the mean \pm S.E.M. for 10 rats. * $P < 0.05$, ** $P < 0.01$ compared to group I, Tukey–Kramer test.

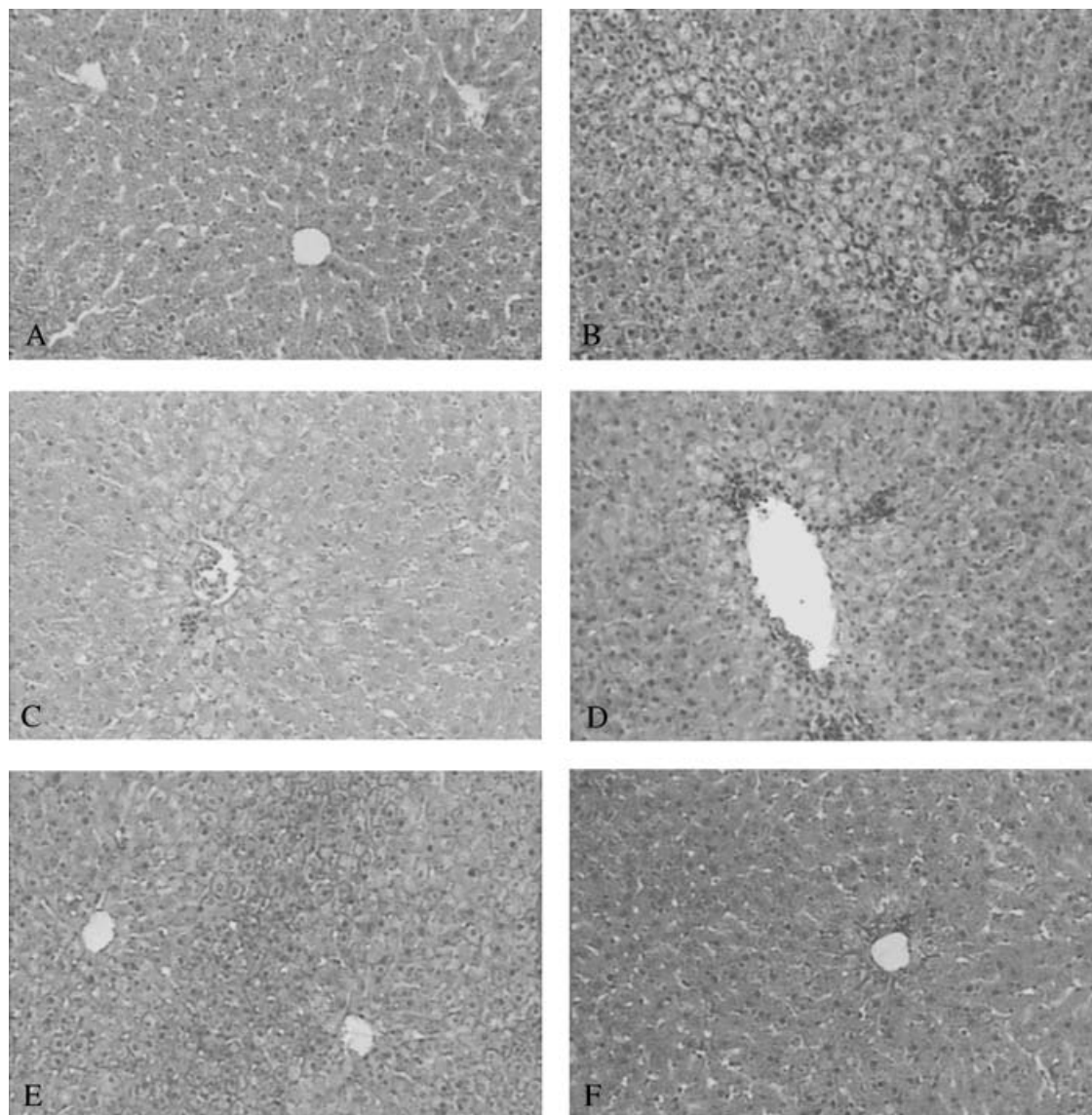


Fig. 4. Haematoxylin and eosin stained section of the rat liver in the group I (Vehicle) (A), II (Cocktail) (B), III (Lovastatin 10 mg/kg) (C), IV (Cocktail + rutin 10 mg/kg) (D), V (Cocktail + rutin 100 mg/kg) (E), VI (Cocktail + rutin 100 mg/kg + lovastatin 10 mg/kg) (F). Magnification 100 \times .

high-cholesterol diet. Serum total T_4 of all groups was significantly reduced compared to group I, which showed that all study groups had hypothyroidism (except the vehicle group). After the model was established, the possible hypercholesterolaemic effects of chronic administration of rutin alone or with lovastatin were examined in rats. In this context, the serum lipid profile, liver enzymes, and tissue were investigated.

According to the results, the effects of different doses of rutin (10 and 100 mg/kg) and lovastatin with rutin (100 mg/kg) on reducing plasma total cholesterol were greater than lovastatin alone. The effects of rutin groups and lovastatin and lovastatin with 100 mg/kg rutin on reducing LDL were statistically equal. However, it seems that the effects of lovastatin alone and lovastatin with 100 mg/kg rutin were greater than administration of rutin alone.

A hypercholesterolaemic diet caused an increase in oxidative stress in the liver, resulted in an increase in AST and ALT levels, and induced fatty liver [25,20]. Therefore, in the present study, ALT and AST, apart from cholesterol, were also evaluated to reveal the protective effects of rutin on hepatic enzymes. As a result, it seems that supplementing a high-cholesterol diet with 100 mg/kg rutin or lovastatin and 100 mg/kg rutin could lower AST and ALT activities more than 10 mg/kg rutin or lovastatin alone. As the liver weight : body weight ratio indicates, it is possible that animals that received rutin 100 mg/kg alone or with lovastatin with their hypercholesterolaemic diets have less fat accumulation in the liver.

In other studies, the influence of the flavonoids on the endogenous regulation of cholesterol biosynthesis has been

discussed and antiatherosclerotic effects of flavonoids have been explained in several studies [6,27,28].

On the other hand, quercetin, one of the metabolites of rutin, lowered the plasma lipid and hepatic cholesterol levels in high-cholesterol-fed rats. Quercetin also decreased HMG-CoA reductase activity. It was suggested that supplementation of quercetin dihydrate and gallate promotes an increase in faecal sterols, which in turn leads to a decreased absorption of dietary cholesterol as well as lowered plasma and hepatic cholesterol [29,30]. Thus, it is possible that rutin, by converting to its active metabolite, decreased HMG-CoA reductase activity and decreased absorption of dietary cholesterol.

Moreover, both rutin and quercetin have an antioxidant effect, and rutin showed clear synergism with quercetin in an *in vitro* study [31]. It has also been reported that quercetin and rutin could suppress lipid peroxidation in biological membrane systems such as mitochondria, erythrocytes, and others [32,33]. Thus, the other possibility for the hepatoprotective effects of rutin may be related to antioxidant activity to prevent liver injury. However, further studies are needed to clarify the exact mechanism.

Another possible explanation for the decreased liver damage and lower liver enzymes for the 100 mg/kg rutin alone group or the group with rutin and lovastatin along with a high-cholesterol diet in animals depends on the anti-inflammatory effects of both drugs. Anti-inflammatory effects of rutin were found in several studies [34,35]. Furthermore, it is suggested that rutin has effective anti-inflammatory effects in the chronic model of inflammation [36].

Statins also have an anti-inflammatory effect that is independent of changes in the cholesterol level [37,38]. Furthermore, the neuroprotective effects of statins against a variety of CNS diseases have been studied [39,40].

In conclusion, our findings indicate that 100 mg/kg rutin alone or with lovastatin supplementation lowered liver weight as well as plasma total cholesterol and LDL. The hepatic histopathological results reflect a correlation of rutin and lovastatin combination with both liver weight and the levels of plasma total cholesterol and LDL-C. However, histopathological results show that liver injury in rats given 100 mg/kg rutin with lovastatin was less than in rats given 100 mg/kg rutin alone. Our data clearly indicate that the antihypercholesterolaemic effects of rutin in an animal model increased in combination therapy with lovastatin. It seems that several mechanisms may contribute to the hypercholesterolaemic effects of rutin.

Acknowledgements

This work was supported by a grant from QMDRC, Qazvin, Iran. The authors are grateful for this financial support.

References

- 1 Loscalzo J, Libby P, Braunwald E. Disorder of cardiovascular disorders. In: Fauci AS, Braunwald E, Kasper DL, Hauser SL, Longo DL, Jameson JL *et al.* (eds). *Harrison's Principles of Internal Medicine*. Mc Graw Hill Companies Inc, New York, 2008;1375, 1378, 1505.
- 2 Byington RP, Jukema JW, Salonen JT, Pitt B, Bruschke AV, Hoen H *et al.* Reduction in cardiovascular events during pravastatin therapy. Pooled analysis of clinical events of the pravastatin atherosclerosis intervention program. *Circulation* 1995;**92**:2419–25.
- 3 Delsing DJ, Offerman EH, van Duyvenvoorde W, van der Boom H, de Wit EC, Gijbels MJ *et al.* Acyl-CoA: cholesterol acyltransferase inhibitor avasimibe reduces atherosclerosis in addition to its cholesterol-lowering effect in ApoE*3-Leiden mice. *Circulation* 2001;**103**:1778–86.
- 4 Nofer JR, Kehrel B, Fobker M, Levkau B, Assmann G, von Eckardstein A. HDL and arteriosclerosis: beyond reverse cholesterol transport. *Atherosclerosis* 2002;**161**:1–16.
- 5 Bok SH, Lee SH, Park YB, Bae KH, Son KH, Jeong TS *et al.* Plasma and hepatic cholesterol and hepatic activities of 3-hydroxy-3-methyl-glutaryl-CoA reductase and acyl CoA: cholesterol transferase are lower in rats fed citrus peel extract or a mixture of citrus bioflavonoids. *J Nutr* 1999;**129**:1182–5.
- 6 Havsteen BH. The biochemistry and medical significance of the flavonoids. *Pharmacol Ther* 2002;**96**:67–202.
- 7 Arai Y, Watanabe S, Kimira M, Shimoi K, Mochizuki R, Kinai N. Dietary intakes of flavonols, flavones and isoflavones by Japanese women and the inverse correlation between quercetin intake and plasma LDL cholesterol concentration. *J Nutr* 2000;**130**:2243–50.
- 8 Kuntic V, Pejic N, Ivkovic B, Vujic Z, Ilic K, Micic S *et al.* Isocratic RP-HPLC method for rutin determination in solid oral dosage forms. *J Pharm Biomed Anal* 2007;**43**:718–21.
- 9 Schwedhelm E, Maas R, Troost R, Boger RH. Clinical pharmacokinetics of antioxidants and their impact on systemic oxidative stress. *Clin Pharmacokinet* 2003;**42**:437–59.
- 10 Sheu JR, Hsiao G, Chou PH, Shen MY, Chou DS. Mechanisms involved in the antiplatelet activity of rutin, a glycoside of the flavonol quercetin, in human platelets. *J Agric Food Chem* 2004;**52**:4414–18.
- 11 Janbaz KH, Saeed SA, Gilani AH. Protective effect of rutin on paracetamol- and CCl₄-induced hepatotoxicity in rodents. *Fitoterapia* 2002;**73**:557–63.
- 12 La Casa C, Villegas I, Alarcon de la Lastra C, Motilva V, Martin Calero MJ. Evidence for protective and antioxidant properties of rutin, a natural flavone, against ethanol induced gastric lesions. *J Ethnopharmacol* 2000;**71**:45–53.
- 13 Mellou F, Loutrari H, Stamatis H, Roussos C, Kolisis FN. Enzymatic esterification of flavonoids with unsaturated fatty acids: effect of the novel esters on vascular endothelial growth factor release from K562 cells. *Process Biochem* 2006;**41**:2029–34.
- 14 Trumbeckaite S, Bernatoniene J, Majiene D, Jakstas V, Savickas A, Toleikis A. The effect of flavonoids on rat heart mitochondrial function. *Biomed Pharmacother* 2006;**60**:245–8.
- 15 Nassiri-Asl M, Shariati-Rad S, Zamansoltani F. Anticonvulsive effects of intracerebroventricular administration of rutin in rats. *Prog Neuro-Psychopharmacol Biol Psychiatry* 2008;**32**:989–93.
- 16 Lebeau J, Nevriere R, Cotelle N. Beneficial effects of different flavonoids on functional recovery after ischemia and reperfusion in isolated rat heart. *Bioorg Med Chem Lett* 2001;**11**:23–7.
- 17 De Celle T, Heeringa P, Strzelecka AE, Bast A, Smits JF, Janssen BJ. Sustained protective effects of 7-mono-hydroxyethyl-rutoside in an *in vivo* model of cardiac ischemia-reperfusion. *Eur J Pharmacol* 2004;**494**:205–12.
- 18 Gupta R, Singh M, Sharma A. Neuroprotective effect of antioxidants on ischaemia and reperfusion-induced cerebral injury. *Pharmacol Res* 2003;**48**:209–15.
- 19 Neumayer C, Fugl A, Nanobashvili J, Blumer R, Punz A, Gruber H *et al.* Combined enzymatic and antioxidative treatment reduces ischemia-reperfusion injury in rabbit skeletal muscle. *J Surg Res* 2006;**133**:150–8.

- 20 Katsube T, Imawaka N, Kawano Y, Yamazaki Y, Shiwaku K, Yamane Y. Antioxidant flavonol glycosides in mulberry (*Morus alba* L.) leaves isolated based on LDL antioxidant activity. *Food Chem* 2006;**97**:25–31.
- 21 Vogel HG, Vogel WH. *Drug Discovery and Evaluation, Pharmacological Assay*. Springer, Berlin, 1997;1096.
- 22 Jeon SM, Park YB, Choi MS. Antihypercholesterolemic property of naringin alters plasma and tissue lipids, cholesterol-regulating enzymes, fecal sterol and tissue morphology in rabbits. *Clin Nut* 2004;**23**:1025–34.
- 23 Moghadasian MH. Experimental atherosclerosis: a historical overview. *Life Sci* 2002;**70**:855–65.
- 24 Burstein PJ, Draznin B, Johnson CJ, Schalch DS. The effect of hypothyroidism on growth, serum growth hormone, the growth hormone-dependent somatomedin, insulin-like growth factor, and its carrier protein in rats. *Endocrinology* 1997;**104**:1107–11.
- 25 Choe S, Kim H, Jeong T, Bok S, Park Y. Naringin has an anti-atherogenic effect with the inhibition of intercellular adhesion molecule-in hypercholesterolaemic rabbits. *Cardiovasc Pharmacol* 2001;**38**:947–55.
- 26 Kanhal MA, Ahmad F, Othman AA, Arif Z, Orf S, Murshed KS. Effects of pure and oxidized cholesterol-rich diet on some biochemical parameters in rats. *Int J Food Nutr* 2002;**53**:381–8.
- 27 Borradaile NM, Carroll KK, Kurowska EM. Regulation of HepG2 cell apolipoprotein B metabolism by the citrus flavanones hesperetin and naringenin. *Lipids* 1999;**34**:591–8.
- 28 Attaway JA, Buslig BS. Antithrombogenic and antiatherogenic effects of citrus flavonoids. *Contributions of Ralph C. Robbins. Adv Exp Med Biol* 1998;**439**:165–73.
- 29 Cervantes-Laurean D, Schramm DD, Jacobson EL, Halaweish I, Bruckner GG, Boissonneault GA. Inhibition of advanced glycation end product formation on collagen by rutin and its metabolites. *J Nut Biochem* 2006;**17**:531–40.
- 30 Bok SH, Park SY, Park YB, Lee MK, Jeon SM, Seong TS *et al*. Quercetin dihydrate and gallate supplements lower plasma and hepatic lipids and change activities of hepatic antioxidant enzymes in high cholesterol-fed rats. *Int J Vitam Nutr Res* 2002;**72**:161–9.
- 31 Becker EM, Ntouma G, Skibsted LH. Synergism and antagonism between quercetin and other chain-breaking antioxidants in lipid systems of increasing structural organization. *Food Chem* 2007;**103**:1288–96.
- 32 Middleton E Jr, Kandaswami C, Theoharides TC. The effects of plant flavonoids on mammalian cells: implications for inflammation, heart disease, and cancer. *Pharmacol Rev* 2000;**52**:673–751.
- 33 Lopez-Revuelta A, Sanchez-Gallego JA, Hernandez-Hernandez A, Sanchez-Yague J, Llanillo M. Membrane cholesterol contents influence the protective effects of quercetin and rutin in erythrocytes damaged by oxidative stress. *Chem Biol Interact* 2006;**161**:79–91.
- 34 Kim H, Kong H, Choi B, Yang Y, Kim Y, Lim MJ *et al*. Metabolic and pharmacological properties of rutin, a dietary quercetin glycoside, for treatment of inflammatory bowel disease. *Pharma Res* 2005;**22**:1499–509.
- 35 Kwon KH, Murakami A, Tanaka T, Ohigashi H. Dietary rutin, but not its aglycone quercetin, ameliorates dextran sulfate sodium-induced experimental colitis in mice: attenuation of proinflammatory gene expression. *Biochem Pharmacol* 2005;**69**:395–406.
- 36 Rotelli AE, Guardia T, Juárez AO, de la Rocha NE, Pelzer LE. Comparative study of flavonoids in experimental models of inflammation. *Pharmacol Res* 2003;**48**:601–606.
- 37 Farmer JA. Aggressive lipid therapy in the statin era. *Prog Cardiovas Dis* 1998;**41**:71–94.
- 38 Iseri S, Ercan F, Gedik N, Yuksel M, Alican I. Simvastatin attenuates cisplatin-induced kidney and liver damage in rats. *Toxicology* 2007;**230**:256–64.
- 39 Asahi M, Huang Z, Thomas S, Yoshimura S, Sumii T, Mori T *et al*. Protective effects of statins involving both eNOS and tPA in focal cerebral ischemia. *J Cereb Blood Flow Metab* 2005;**25**:722–9.
- 40 Stanislaus R, Pahan K, Singh AK, Singh I. Amelioration of experimental allergic encephalomyelitis in Lewis rats by lovastatin. *Neurosci Lett* 1999;**269**:71–4.