

Human papillomaviruses and DNA ploidy in anal condylomata acuminata

S. Rihet¹, P. Bellaich², M. Lorenzato¹, D. Bouttens¹, P. Bernard², P. Birembaut¹ and C. Clavel¹

¹Cell Biology Unit, Laboratoire Pol Bouin, Reims, France and ²Department of Dermatology, C.H.U. de Reims, France

Summary. Previous studies have emphasized the usefulness of DNA ploidy measurement and Human Papillomavirus (HPV) detection as prognostic markers in low grade cervical lesions. We addressed the eventual relationship between HPV type, DNA profile, and p53 tumor suppressor protein expression in anal condylomata acuminata to eventually determine parameters which may be considered as predictive risk factors for the development of cancer. DNA ploidy was assessed by image cytometry after Feulgen staining of contiguous serial sections of 45 anal condylomata acuminata without atypia containing HPV detected by in situ hybridization and Polymerase Chain Reaction (PCR). p53 expression was detected by immunohistochemistry. DNA aneuploidy was found in 53.3% of these lesions, 48.9% containing non oncogenic HPV types 6 and/or 11 and 4.4% harbouring HPV types 11 and 18. The DNA diploid lesions were all associated with non oncogenic HPV types 6 and/or 11 and one case also contained HPV type 33. There was no significant correlation between the detection of DNA aneuploidy and the presence of immunodetected p53. DNA aneuploidy was not related to the presence of oncogenic HPV in anal condylomata acuminata. The DNA aneuploid profile frequently observed, especially in lesions associated with non oncogenic HPV types, is not yet well explained and cannot be considered as a prognostic factor. In contrast, a more intensive clinical follow-up should be proposed in patients with oncogenic HPV associated to DNA aneuploidy.

Key words: Human papillomavirus, Anal condylomata acuminata, DNA ploidy

Introduction

Genital warts (condylomata acuminata) are sexually transmitted lesions of the ano-genital tract. Histologically they are characterized by papillary

excrescences lined by hyperkeratotic squamous epithelium usually exhibiting variable degrees of koilocytotic changes. Human papillomaviruses (HPV) are responsible for these lesions. The types of HPV most commonly encountered are 6 and 11, considered as non-oncogenic HPV, but types 16, 18, 31, 33, 35 and 39 are also observed (Puy-Montbrun et al., 1992). Generally condylomata acuminata appear as benign lesions with good prognosis, but in 7 to 20% of these condylomas, dysplastic changes are described and carcinomas may develop (Law et al., 1991; Puy-Montbrun et al., 1992). Moreover a significant association between a reported past history of condyloma acuminatum and squamous cell anal cancer has been observed in most patients (Daling et al., 1987). In these anal carcinomas, various studies have suggested that HPV may also be an etiological factor as reported in cervical lesions (Beckmann et al., 1989; Gal et al., 1989; Duggan et al., 1991; Higgins et al., 1991; Melbye and Sprogel, 1991; Palefsky et al., 1991; Noffsinger et al., 1992, 1995; Zaki et al., 1992; Heino et al., 1993; Surawicz et al., 1993; Holm et al., 1994; Schroyer et al., 1995; Vincent-Salomon et al., 1996; Tilston, 1997). Indeed in one series, HPV DNA was found in 85% of anal carcinomas with the use of dot blot hybridization, HPV type 16 being the specific subtype in 82% of the positive cases (Duggan et al., 1991). In the same way, Holm et al. (1994) have detected HPV DNA in 81% of their anal carcinomas with Polymerase Chain Reaction (PCR) with a high prevalence of HPV type 16. The presence of HPV in tumor cells of these cancers is significantly associated with an increased proliferative rate and an aneuploid status (Noffsinger et al., 1995). All these observations emphasize the role of HPV in the development of premalignant and malignant squamous cell lesions of the anus.

In a previous study on cervical lesions, we have shown that aneuploidy is strongly suggestive of the presence of oncogenic HPV types. Moreover, combining the detection of HPV DNA with DNA image cytometry, we have suggested that a low grade cervical lesion with a multiploid DNA profile harbouring an oncogenic HPV type may progress to cancer or highlights the presence of a high-grade lesion elsewhere (Rihet et al., 1996). Thus

DNA aneuploidy and especially DNA multiploidy, and the presence of an oncogenic HPV may both be used as prognostic factors in these low grade cervical lesions. In a similar approach, the aim of the present work was to address the eventual relationship between DNA ploidy, HPV type, and p53 tumor suppressor protein expression in anal condylomata acuminata. For this, we have used image cytometry after Feulgen staining which selects the DNA profile of epithelial cells and immunohistochemistry on tissue sections analyzed with *in situ* hybridisation and PCR for the detection of HPV. Such a study would eventually find out parameters which may be considered as predictive risk factors in these lesions of uncertain evolution.

Materials and methods

The study population comprised 45 patients (33 men and 12 women; mean age 33 years) with typical anal condylomata acuminata without any dysplastic lesions. In one patient, condylomata acuminata was close to a squamous cell anal carcinoma. Three patients were human immunodeficiency virus-infected. Serial sections of each specimen were used as follows: the first section was for conventional diagnosis, five for *in situ* hybridization (ISH), one for Feulgen staining and DNA quantification, two for PCR; two for p53 immunohistochemical detection; and the last to confirm that the entire series was still within the initial lesion.

HPV detection

HPV was detected by ISH using digoxigenin-labelled DNA probes applied to formalin-fixed, paraffin-embedded tissue sections as described previously (Clavel et al., 1991). With this technique we have detected the presence of HPV types 6, 11, 16, 18 and 33.

For PCR analysis, we chose to extract DNA from a few sections of embedded tissues. To avoid DNA contaminations, all sections were cut on a microtome with disposable blades. A new blade was used for each paraffin-embedded block. In brief, one to a maximum of three 3 μ m-thick sections were quickly deparaffinized (10 min) in xylene followed by absolute ethanol. Samples were spun down and dried. Then we rehydrated samples and followed the QIAamp Tissue Kit procedure (QIAGEN S.A., Cat. N^o. 29304, Courtaboeuf, France) using proteinase K for digestion overnight and different elutions through QIAamp spin column. At the end DNA was eluted with a buffer of the kit.

In all our DNA samples, we performed PCR using the specific primers described by Baay et al. (1996), allowing the detection of the four main mucosal oncogenic HPV types 16, 18, 31 and 33. Following the protocol of these authors, we have used the same primers but with slightly different conditions. Thus PCR buffer was 10 mM Tris HCl pH 9, 50 mM KCl and 1.5 mM MgCl₂, without Triton and otherwise, after heat denaturation (5 min 95 °C), each of 40 cycles of

amplification consisted in 1 min 95 °C, 1 min (60 °C for HPV 16, 18 and 57 °C for HPV 31 and 33), 2 min at 72 °C followed by the final extension, 10 min at 72 °C. Amplimers were small: about 100 base pairs. After PCR, 25 μ l of all samples was run on a 2% agarose gel; gels were blotted (Hybond N⁺, Amersham) and hybridized with appropriated probes described by Baay et al. (1996).

Positive HPV controls (HPV plasmids, cervical lesions containing the various HPV types) and negative controls (10 samples of normal skin provided from plastic surgery) were also amplified using the same procedure. As an internal positive control, amplification of a 100 bp region of exon 10 of CFTR gene was performed on each sample.

DNA quantification

DNA was quantified using image cytometry using the CAS 200 image analysis system (Becton Dickinson, Leiden, The Netherlands) with the ploidy measurement software set at the "tissue section" option. One contiguous 6 μ m paraffin wax section of each specimen was analysed. The wax was dissolved and tissue sections were rehydrated, hydrolysed for 60 min (5 N HCl) and stained with Feulgen stain.

The calibration slides were those recommended by the CAS system - that is, imprints of fresh rat liver. For the ploidy measurement software, at least 20 calibration cells were required to proceed to the quantification section. The cells were chosen by the computer and the user could accept or reject each cell. The coefficient of variation for the calibration histograms was always less than 3%.

Other reference cells to control for DNA diploidy were chosen systematically outside the lesion but within the same tissue section (40 normal fibroblasts or normal epithelial cells at distance from the lesion). To quantify DNA in the condylomata acuminata cell nuclei, at least 200 cells were evaluated as possible.

The results are given with the DNA index (DI) which represents the ratio of the DNA content of the analysed nuclei to the DNA content of the reference cells in G0/G1 phase. By definition, the DI of a DNA diploid population is 1. The DNA tetraploid pattern (DI = 2) was grouped with the DNA diploid cases. When the index was different from 1 or 2, the cell was regarded as DNA aneuploid. In the study, we have defined two DNA aneuploid profiles: single peak DNA aneuploidy and several DNA aneuploid peaks considered as the DNA multiploid profile (Fig. 1).

p53 immunohistochemical detection

Dewaxed 5 μ m formalin-fixed paraffin-embedded tissue sections were immersed in citrate buffer (0.01M sodium citrate, pH 6) and boiled in a microwave oven at 600 W for 10 min. Endogenous peroxidase activity was blocked with 0.3% H₂O₂ in methanol for 30 min. Then

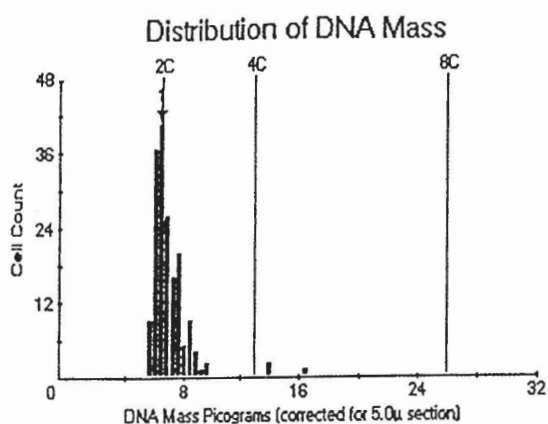


FIGURE 1 A

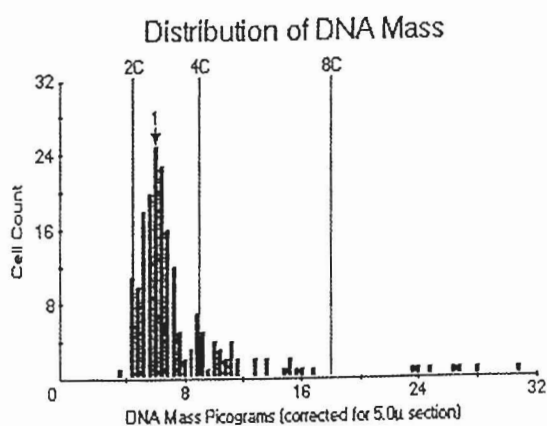


FIGURE 1 B

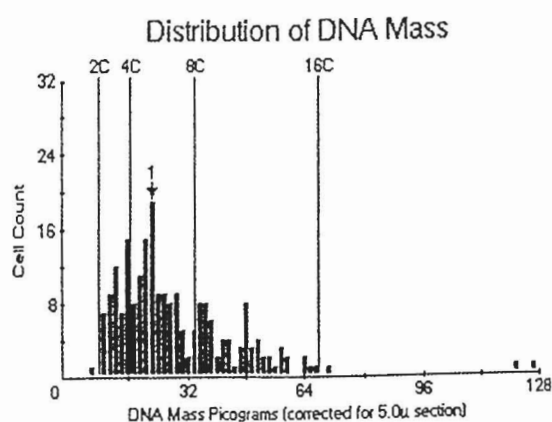


FIGURE 1 C

Fig. 1. DNA quantification on 6 µm sections. A. DNA diploid profile. B. Single-peak DNA aneuploid profile. C. Multiploid DNA profile.

sections were incubated for an hour at room temperature with the monoclonal antibody (clone DO-7, Dako, Golstrup, Denmark, diluted 1:50) against wild type and mutant forms of p53. The avidin-biotin complex procedure was used according to the manufacturer's directions (Dako, Golstrup, Denmark). The cases were considered as positive when 10 cells or more were stained with the antibody.

For negative control purposes, the same procedure was followed except that the primary antibody was replaced by phosphate-buffered saline. A breast cancer sample with a known p53 mutation was used as a positive control for immunoreactivity.

Statistical analysis

In bivariate analyses, the association between DNA ploidy and HPV detection and p53 immunoreactivity were analyzed using the χ^2 test or a corrected χ^2 test (Yates' correction for small samples).

Results

All results are summarized in table 1.

HPV detection

ISH demonstrated the presence of low risk HPV type 6 and/or 11 principally in the nuclei of koilocytes with a diffuse pattern of the labelling, in all cases (Fig. 2). PCR detected the presence of HPV type 18 associated with HPV type 11 in two cases including the lesion close to the squamous cell anal carcinoma, and HPV type 33 was associated with types 6 and 11 in another case. The 3 human immunodeficiency virus-infected patients were infected with HPV types 6 and 11.

Evaluation of DNA content

According to our criteria, twenty-one cases (46.7%) were considered as DNA diploid. All these cases contained HPV types 6 and/or 11 and one also lesion contained HPV type 33. Twenty-four cases out of 45 (53.3%) expressed a DNA aneuploid profile, with a single peak DNA aneuploidy in 17 cases (37.8%) and DNA multiploidy in 7 cases (15.5%). Twenty-two DNA aneuploid anal condylomata acuminata (48.9%)

Table 1. Detection of HPV and immunoreactivity for p53 protein in anal condylomata acuminata with DNA diploid and aneuploid profiles.

	HPV DETECTION			p53 IMMUNO-POSITIVITY
	6 and/or 11	11 and 18	6, 11 and 33	
Diploidy	20	-	1	5
Aneuploidy				
Single peak	15	2	-	4
Multiploidy	7	-	-	4

HPV, ploidy and anal condylomas

contained HPV types 6 and/or 11 and two lesions with single peak DNA aneuploidy (4.4%) harboured HPV type 11 and oncogenic type 18. There was no significant association between DNA diploidy or aneuploidy and the presence of HPV (oncogenic and non oncogenic).

p53 detection

p53 was principally detected in the nuclei and

occasionally in the cytoplasm of scattered keratinocytes in 13 cases (28.9%) (Fig. 3). Five of these cases were DNA diploid, 4 with a single peak DNA aneuploidy and 4 with DNA multiploidy. The absence of p53 immunoreactivity was found in 32 cases including 16 DNA diploid, 13 single peak DNA aneuploid and 3 DNA multiploid lesions. The cells labeled were not always positive with in situ hybridization. There was not any significant correlation between the detection of DNA

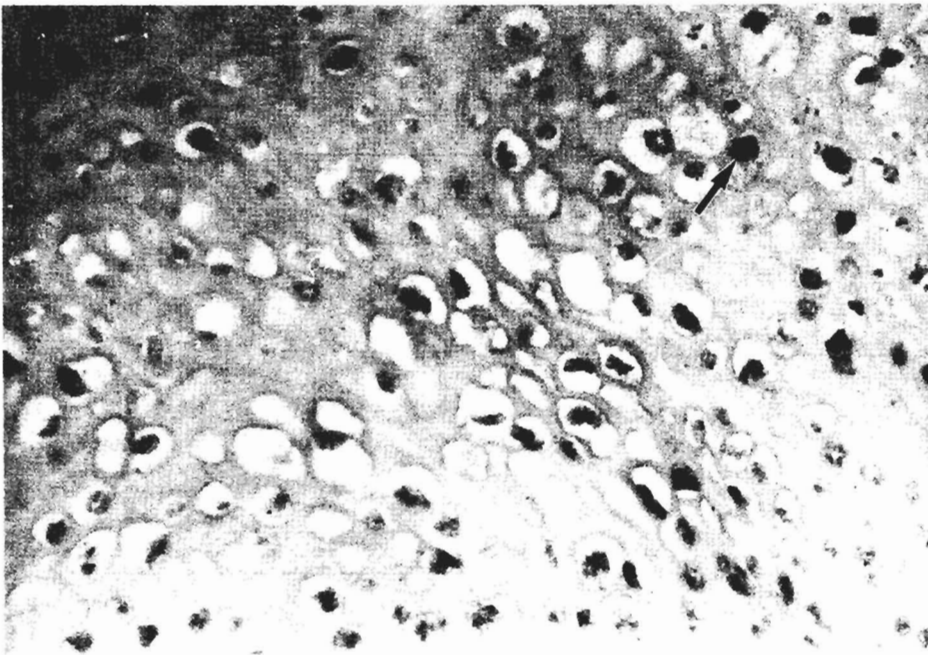


Fig. 2. HPV type 6 is detected in numerous koilocytes on this anal condylomata acuminata, with a diffuse labeling of the nuclei (arrow). x 250

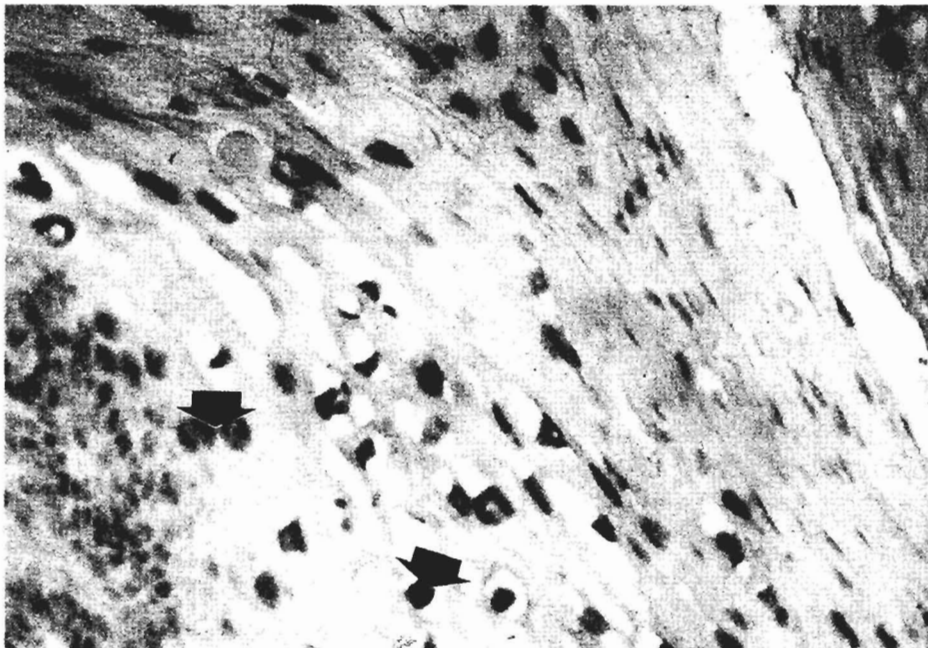


Fig. 3. Numerous nuclei of koilocytes and basal cells are immunolabeled with anti-p53 antibody in this anal condylomata acuminata (arrow). x 250

aneuploidy and especially DNA multiploidy and the presence of immunodetected p53 signalling an overexpression or more frequently a mutated form of the p53. Moreover no significant association of aberrant p53 expression with any specific HPV type (oncogenic and non oncogenic) was observed.

Discussion

Few studies have examined the relationship between DNA ploidy and HPV types in condylomata acuminata (Del Mistro et al., 1988; Chacho et al., 1990). In the most important series, Chacho et al. (1990) using DNA image cytometry after Feulgen staining, have reported a DNA aneuploid profile in 6 cases out of 7 condylomata acuminata of the urinary bladder containing HPV types 6 and 11. Our experience clearly demonstrates that DNA aneuploidy is present in 53.3% of our anal condylomata acuminata all harbouring non oncogenic HPV types 6 and 11. Two single peak DNA aneuploidy and one DNA diploid profile were found in the three positive cases for oncogenic HPV types 18 and 33 respectively. Thus, DNA aneuploidy is not significantly related to a specific type of HPV (oncogenic or non oncogenic). There is an apparent discrepancy between these observations and our previous findings on cervical lesions. Indeed, DNA aneuploidy and especially DNA multiploidy were strongly associated with cervical lesions containing oncogenic HPV (Rihet et al., 1996). Moreover, in their study on ploidy and HPV in anal carcinomas, Noffsinger et al. (1995) have also reported a significant association between the detection of oncogenic HPV type 16 and the presence of a DNA aneuploidy detected by flow cytometry. In these cancers, 81.8% of the aneuploid tumors contained HPV type 16. Thus, contrary to cervical intraepithelial lesions and anal carcinomas, DNA aneuploidy is not necessarily related to the presence of an oncogenic HPV in anal condylomata acuminata.

The role of HPV in the development of DNA aneuploidy has yet to be defined. Viral oncogenic proteins binding and inhibiting functional tumor suppressor gene proteins such as p53 and pRB (retinoblastoma protein) can deregulate the cell cycle and lead to genomic instability in lesions harbouring oncogenic HPV types. However, this mechanism cannot be proposed to explain DNA aneuploidy in anal condylomata acuminata which are principally associated and/or related to non oncogenic HPV. Trusal et al. (1975) and Simard et al. (1986) have emphasized the role of viral replication in nuclear matrix remodeling in Herpes virus-infected cells, which produces qualitative and quantitative modifications of the DNA measurement after Feulgen stain. So non oncogenic HPV may act in the same way on host cell DNA. In another way, DNA aneuploidy could be related to functional disturbance of tumor suppressor protein expression. p53 abnormalities have been previously described by Ranki et al. (1995) who found nuclear and cytoplasmic immunostaining for

p53 in 41% of their condylomata acuminata with no atypia. p53 has been also detected by immunohistochemistry in 28.9% of our cases, signalling an overexpression or more likely a mutated form of this tumor suppressor protein. However we did not find any statistically significant correlation between DNA aneuploidy and the p53 immunopositivity. Thus the mechanism of DNA aneuploidy in anal condylomata acuminata does not seem to implicate p53 mutation and is yet undetermined.

The progression of anal condylomata acuminata to squamous cell carcinomas is infrequent and not well defined. Dysplastic changes have been described in 7 to 20% of anal condylomas (Law et al., 1991; Puy-Montbrun et al., 1992), and Chuang et al. (1984) found 0.4% of male patients with condylomata acuminata to have carcinoma in situ after a limited follow-up. In our series, one condylomata acuminata was close to an invasive squamous cell carcinoma. All these anal lesions are associated with HPV but, if oncogenic HPV are rarely detected in condylomata acuminata, their prevalence is important in HPV-positive carcinomas, in up to 92% of invasive squamous cell tumours (Noffsinger et al., 1995). On the other hand, non oncogenic types 6 and 11 are the most common HPV types found in condylomata acuminata and their detection, in the absence of any of the commonly encountered oncogenic genotypes, is infrequent in anal cancers when sensitive methods such as PCR are used for HPV detection. In the study of Noffsinger et al. (1995), only one case out of 26 squamous cell carcinomas was positive for HPV type 6. All these data plead in favor of the role of oncogenic HPV types in the pathogenesis of squamous cell anal cancers. Thus their detection in low grade lesions could select patients at risk for the development of anal carcinoma (6.7% in our series). In another way, contrary to cervical lesions, DNA aneuploidy is frequently observed in anal condylomata acuminata and especially in lesions with non oncogenic HPV (48.9% in our series). So it cannot be considered by itself as a prognostic factor. In contrast, patients with DNA aneuploid anal condylomata acuminata containing oncogenic HPV represent a limited population that could be considered to be at higher risk (4.4% in our series). We have to emphasize that in our experience, one of these patients had an invasive squamous cell carcinoma. Thus a more intensive clinical follow-up should be proposed in such patients.

In conclusion, DNA aneuploidy is not related to the presence of oncogenic HPV in anal condylomata acuminata. The DNA aneuploid profiles frequently encountered in these lesions are not yet well explained. They cannot be considered as a reliable prognostic factor when they are associated with non oncogenic HPV. The prognostic significance of a DNA aneuploidy associated with oncogenic HPV remains to be established by prospective studies with follow-up of a larger number of patients.

Acknowledgements. We thank Mrs Isabelle Putaud for technical help. This work was supported by grants from the Lions' Club of Soissons, the A.R.C. (Association de Recherche contre le cancer) and the C.H.U. of Reims, France.

References

- Baay M.D., Quint W.V., Koudstaal J., Hollema H., Duk J.M., Burger M.P.M., Stoltz E. and Herbrink P. (1996). Comprehensive study of several general and type-specific primer pairs for detection of human papillomavirus DNA by PCR in paraffin-embedded cervical carcinomas. *J. Clin. Microbiol.* 34, 745-747.
- Beckmann A.M., Daling J.R., Sherman K.J., Maden C., Miller B.A., Coates R.J., Kiviat N.B., Myerson D., Weiss N.S., Hislop G., Beagrie M. and McDougall J.K. (1989). Human papillomavirus infection and anal cancer. *Int. J. Cancer* 43, 1042-1049.
- Chacho M.S., Eppich E., Wersto R. and Koss L.G. (1990). Influence of the papillomavirus on DNA ploidy determination in genital condylomas. *Cancer* 65, 2291-2294.
- Chuang T., Perry H.P., Kurland L.T. and Ilstrup D.M. (1984). Condylomatum acuminatum in Rochester Minn. 1950-1978, II anaplasias and unfavorable outcomes. *Arch. Dermatol.* 120, 476-483.
- Clavel C., Binnering I., Bouterin M.C., Polette M. and Birembaut P. (1991). Comparison of four non-radioactive and ³⁵S based methodologies for the detection of human papillomavirus DNA by in situ hybridization. *J. Virol. Methods* 33, 253-266.
- Daling J.R., Weiss N.D., Hislop T.G., Maden C.M., Coates R.J., Sherman K.J., Ashley R.L., Beagrie M., Ryan J.A. and Corey L. (1987). Sexual practices, sexually transmitted diseases and the incidence of anal cancer. *N. Engl. J. Med.* 317, 973-977.
- Del Mistro A., Koss L.G., Braunstein J., Bennett B., Saccomano G. and Simmons K.M. (1988). Condylomata acuminata of the urinary bladder. *Am. J. Surg. Pathol.* 12, 205-215.
- Duggan M.A., Boras V.F., Inoue M. and McGregor S.E. (1991). Human papillomavirus DNA in anal carcinomas. Comparison of in situ and dot blot hybridization. *Am. J. Clin. Pathol.* 96, 318-325.
- Gal A.A., Saul S.H. and Stoler M.H. (1989). In situ hybridization analysis of human papillomavirus in anal squamous cell carcinoma. *Mod. Pathol.* 2, 439-443.
- Heino P., Goldman S., Lagerstedt U. and Dillner J. (1993). Molecular and serological studies of human papillomavirus among patients with anal epidermoid carcinoma. *Int. J. Cancer* 53, 377-381.
- Higgins G.D., Uzelin D.M., Phillips G.E., Pieterse A.S. and Burrell C.J. (1991). Differing characteristics of human papillomavirus RNA-positive and RNA-negative anal carcinomas. *Cancer* 68, 561-567.
- Holm R., Tanum G., Karlsen F. and Nesland J.M. (1994). Prevalence and physical state of human papillomavirus DNA in anal carcinomas. *Mod. Pathol.* 7, 449-453.
- Law C.L., Qassim M., Thompson C.H., Rose B.R., Grace J., Morris B.J., and Cossart Y.E. (1991). Factors associated with clinical and sub-clinical anal human papillomavirus in homosexual men. *Genitourin. Med.* 67, 92-98.
- Melbye M. and Sprogel P. (1991). Aetiological parallel between anal and cervical cancer. *Lancet* 338, 657-659.
- Noffsinger A., Witte D. and Fenoglio-Preiser C.M. (1992). The relationship of human papillomavirus to anorectal neoplasia. *Cancer* 70, 1276-1287.
- Noffsinger A.E., Hui Y.Z., Suzuk L., Yochman L.K., Miller M.A., Hurtubise P., Gal A.A. and Fenoglio-Preiser C.M. (1995). The relationship of human papillomavirus to proliferation and ploidy in carcinoma of the anus. *Cancer* 75, 958-967.
- Palefsky J.M., Holly E.A., Gonzales J., Berline J., Ahn D.K. and Greenspan J.S. (1991). Detection of human papillomavirus DNA in anal intraepithelial neoplasia and anal cancer. *Cancer Res.* 51, 1014-1019.
- Puy-Montbrun T., Denis J., Ganansia R., Mathonière F., Lemarchand N. and Arnoux-Dubois N. (1992). Anorectal lesions in human immunodeficiency virus-infected individuals. *Int. J. Colorect. Dis.* 7, 26-30.
- Ranki A., Lassus J. and Niemi K.M. (1995). Relation of p53 tumor suppressor protein expression to human papillomavirus (HPV) DNA and to cellular atypia in male genital warts and in premalignant lesions. *Arch. Derm. Venereol. (Stockh)* 75, 180-186.
- Rihet S., Lorenzato M. and Clavel C. (1996). Oncogenic human papillomaviruses and ploidy in cervical lesions. *J. Clin. Pathol.* 49, 892-896.
- Schroyer K.R., Brookes C.G., Markham N.E. and Schroyer A.L. (1995). Detection of human papillomavirus in anorectal squamous cell carcinoma. Correlation with basaloid pattern of differentiation. *Am. J. Clin. Pathol.* 104, 299-305.
- Simard R., Bibor-Hardy V., Dagenais A., Bernard M. and Pinard M.F. (1986). Role of the nuclear matrix during viral replication. *Methods Achiev. Exp. Pathol.* 12, 172-199.
- Surawicz C.M., Kirby P., Critchlow C., Sayer J., Dunphy C. and Kiviat N. (1993). Anal dysplasia in homosexual men. Role of anoscopy and biopsy. *Gastroenterology* 105, 658-666.
- Tilston P. (1997). Anal human papillomavirus and anal cancer. *J. Clin. Pathol.* 50, 625-634.
- Trusal L.R., Anthony A. and Docherty J.J. (1975). Differential Feulgen-deoxyribonucleic acid hydrolysis patterns of herpes simplex virus type 1 and 2 infected cells. *J. Histochem. Cytochem.* 23, 283-288.
- Vincent-Salomon A., de la Rochefordière A., Salmon R., Validire P., Zafrani B. and Sastre-Garau X. (1996). Frequent association of human papillomavirus 16 and 18 DNA with anal squamous cell and basaloid carcinoma. *Mod. Pathol.* 9, 614-620.
- Zaki S.R., Judd R., Coffield L.M., Greer P., Rolston F. and Evatt B.L. (1992). Human papillomavirus infection and anal carcinoma. Retrospective analysis by in situ hybridization and the polymerase chain reaction. *Am. J. Pathol.* 140, 1345-1355.

Accepted July 29, 1999