

Vascular endothelial growth factor (VEGF), transforming growth factor- β (TGF β), and interleukin-6 (IL-6) in experimental herpesvirus retinopathy: association with inflammation and viral infection

S.A. Vinoses¹, N.L. Derevjanik¹, A. Shi¹, M.A. Vinoses¹, D.A. Klein¹ and J.A. Whittum-Hudson²

¹The Wilmer Eye Institute, Johns Hopkins University School of Medicine, Baltimore, Maryland and ²Departments of Internal Medicine, Immunology and Microbiology, and Ophthalmology, Wayne State University School of Medicine, Detroit, Michigan, USA

Summary. Experimental herpesvirus retinopathy presents a unique model of a transient inflammatory response in the virus-injected eye and subsequent acute retinal necrosis and chronic inflammation in the contralateral eye. For 6 days after infection, VEGF, TGF β_1 , and TGF β_2 were associated only with inflammatory cells in the injected eye. By 6 days (after viral antigens were no longer detected), VEGF and TGF β_2 were upregulated in retinas of injected eyes until 8-10 days. In contralateral eyes, VEGF was first demonstrated in the retina at 6-7 days (prior to the appearance of viral antigens) and TGF β_2 at 7-8 days. Staining for these factors was also evident around areas of necrosis. The VEGF receptor, flt-1, was associated with ganglion cells and the inner nuclear layer of normal and experimental mice and it was also demonstrated around areas of necrosis. Another VEGF receptor, flk-1, was localized to Müller cell processes and the outer plexiform layer in normal and experimental mice. Coincident with VEGF upregulation in the retinas of herpesvirus-1 injected mice, there was increased flk-1 in ganglion cells and the inner and outer nuclear layers. IL-6 was associated with Müller cell endfeet in normal mice. Following unilateral intraocular inoculation, IL-6 spread along the Müller cell processes and some astrocytes demonstrated IL-6 in both eyes at 6-8 days. The present study demonstrates that intraocular inoculation of herpesvirus is sufficient to induce VEGF, flk-1, TGF β_2 , and IL-6 in the retinas of injected and contralateral eyes. Further investigation of common signaling pathways for these factors during responses to viral infection and the development of acute retinal necrosis could provide information useful for therapeutic intervention in human herpesvirus retinopathy.

Key words: Vascular endothelial growth factor, Transforming growth factor β , interleukin 6, Herpesvirus, retinopathy

Introduction

Vascular endothelial growth factor (VEGF) is induced by hypoxia (Plate et al., 1992; Shweiki et al., 1992; Goldberg and Schneider, 1994; Hashimoto et al., 1994; Minchenko, et al., 1994a,b; Levy et al., 1995; Pierce et al., 1995) and its induction is associated with angiogenesis in hypoxic tissues (Miller et al., 1994; Stone et al., 1995; Murata et al., 1996). In some cases, however, VEGF induction occurs in tissues in which hypoxia does not appear to be a feature and angiogenesis does not occur. Inflammatory ocular disorders that do not present with apparent pathological evidence of hypoxia include autoimmune disorders, such as experimental autoimmune uveoretinitis (EAU), infections, and aphakic or pseudophakic macular edema (Vinoses et al., 1997). These findings suggest that factors other than hypoxia may be capable of inducing VEGF in the retina in pathological conditions, as has been demonstrated in other systems. A number of other factors, such as interleukin-1 β (Ben-Av et al., 1995; Li et al., 1995; Jackson et al., 1997; Ristimaki et al., 1998) prostaglandins E1 and E2 (Harada et al., 1994), tumor necrosis factor- α (Ryuto et al., 1996), epidermal growth factor, platelet-derived growth factor-BB, basic fibroblast growth factor (Tsai et al., 1995), and inflammatory cytokines from activated T-cells (Samaniego et al., 1998) have been shown to stimulate the production and secretion of VEGF in other systems and this is also likely to occur in the eye. In disorders that do not involve hypoxia, VEGF may be produced by resident cells and thereby contribute to a pro-inflammatory cascade via recruitment and activation of

Offprint requests to: Stanley A. Vinoses, Ph.D., 825 Maumenee Bldg., Johns Hopkins Univ. Sch. Med., 600 N. Wolfe Street, Baltimore, MD 21287-9289. Fax: 410-502-5382. e-mail: svinoses@jhmi.edu

inflammatory cells and their adhesion to the vascular endothelium (Barleon et al., 1996; Clauss et al., 1996; Melder et al., 1996; Lu et al., 1999).

It is likely that VEGF may contribute to an inflammatory reaction without induction of neovascularization (NV) due to the presence of one or more angiogenesis inhibitors. TGF β 1 and TGF β 2 suppress proliferation of vascular endothelial cells (Jennings et al., 1988; McAvoy and Chamberlain, 1990; Chakravarthy and Archer, 1992; Pertovaara et al., 1994; Behzadian et al., 1995; Kulkarni et al., 1995; Yoshimura et al., 1995) and may inhibit NV in experimental herpesvirus retinopathy. We have provided evidence that TGF β performs this function in the EAU model (Vinores et al., 1998) and this may occur in other ocular disorders in which TGF β is upregulated. TGF β has been demonstrated *in vitro* to suppress vascular endothelial cell growth by a down-regulation of the VEGF receptor, flk-1 (Mandriota et al., 1996).

Interleukin-6 (IL-6) is a pro-inflammatory cytokine that is associated with ocular inflammatory conditions including human and experimental uveitis (Murray and Martens, 1990; DeBoer et al., 1992; De Vos et al., 1992; Franks et al., 1992; Hoekzema et al., 1992; Planck et al., 1992; Yoshida et al., 1994; Kuppner et al., 1995) and it may act in conjunction with VEGF to promote an inflammatory response. IL-6 can be produced constitutively or in response to a variety of stimuli, such as interleukin-1 β , tumor necrosis factor- α , or TGF β (Van Snick, 1990; Benson et al., 1992; Planck et al., 1992; Kishimoto, et al., 1994; DeVos et al., 1995; Kuppner et al., 1995). IL-6 overexpression is associated with breakdown of the blood-brain barrier (BBB) and recruitment of inflammatory cells (Brett et al., 1995; Watson et al., 1996), which are potential mechanisms for fostering an inflammatory response. Since VEGF promotes blood-retinal barrier (BRB) breakdown (Connolly et al., 1989; Luna et al., 1997; Ozaki et al., 1997) and also participates in the recruitment of inflammatory cells (Barleon et al., 1996; Clauss et al., 1996; Melder et al., 1996; Lu et al., 1999), VEGF and IL-6 may act synergistically.

Experimental herpesvirus retinopathy presents a unique model in which there is a transient inflammatory response in the anterior segment of one eye and a viral infection leading to acute retinal necrosis and chronic inflammation in the opposite eye (Whittum et al., 1983, 1984). This model facilitates the investigation of both processes in the same animal. Inoculation of herpes simplex virus type 1 (HSV-1) into the anterior chamber of one eye of a BALB/c mouse results in a rapid, transient inflammatory reaction, which subsides with the loss of viral protein at about day 5, post-inoculation. There is no residual damage in the retina of the injected eye. The contralateral eye develops a delayed retinal necrosis beginning at 7 days post-inoculation with inflammatory cell infiltration, coincident with the appearance of virus, and leading to complete retinal necrosis by day 14. The present report describes our studies of expression of VEGF and its receptors and of

TGF β and IL-6 during the course of these processes.

Materials and methods

A total of 31 adult BALB/c mice received 2×10^4 plaque-forming units (pfu) of the KOS strain of HSV-1 in a volume of 4 μ l, into the anterior chamber, as previously described (Dix et al., 1987; Whittum et al., 1984). Twenty-one of the mice were injected unilaterally and the remainder were injected bilaterally. Of the mice receiving a unilateral inoculation, 2 each were sacrificed at 1, 2, 6, 7, 8, 12, and 13 days and 4 were sacrificed at 3 and 11 days. Of the bilaterally-injected mice, 3 were sacrificed at 1 and 2 days, and 2 were sacrificed at 6 and 12 days. The retinas of injected eyes from unilaterally- or bilaterally-injected mice were found to be phenotypically identical (Whittum et al., 1984), and thus were grouped together. As controls for nonspecific inflammation induced by injection alone, 10 mice received intraocular injections of the same volume of Hank's Balanced Salt Solution (HBSS). Half of the mice were inoculated unilaterally and the other half were inoculated bilaterally. HBSS-injected control mice were sacrificed at 3 days (3 unilaterally and 2 bilaterally injected) and at 7 days post-inoculation (2 unilaterally- and 3 bilaterally-injected). Eyes from normal, untreated mice were similarly processed. When the mice were sacrificed, the eyes were enucleated, immediately snap-embedded in OCT compound (Miles, Elkhart, IN), and stored at -80 °C. One eye from each of the following was cryopreserved: 3 mice that were sacrificed 2 days after receiving bilateral injections, one of the mice receiving a unilateral injection (contralateral eye was frozen), and the 5 normal mice. Both eyes from all other mice were frozen. Cryosections were cut for immunohistochemistry and post-fixed in -20 °C methanol. Immunohistochemical staining for VEGF, the VEGF receptors, flt-1 and flk-1, TGF β 1, and TGF β 2 was then performed, as previously described (Chen et al., 1997). To verify the specificity of the antibodies, VEGF and VEGF receptor antibodies were pre-incubated for 2 hours at room temperature with a tenfold excess of the appropriate control peptide (Santa Cruz Biotechnology, Santa Cruz, CA) prior to applying it to the tissue sections as previously described (Vinores et al., 1997). IL-6 staining was performed using a 1:25 dilution of a monoclonal rat anti-mouse IL-6 antibody (PharMingen, San Diego, CA) with the HistoMark Streptavidin-AP System goat-anti-rat IgG (H+L) kit (Kirkegaard & Perry, Gaithersburg, MD). Immunoreactivity for IL-6 was visualized with HistoMark Red (Kirkegaard & Perry). The other antigens were visualized with 3-amino-9-ethylcarbazole (Sigma, St. Louis, MO).

Results

VEGF

VEGF was not demonstrated in any of the normal mice or in injected or uninjected eyes of mice within 2

days after receiving HSV-1 inoculations. At 3 days post-inoculation, VEGF positivity was associated with sparse inflammatory cells in the vitreous of 2 of 3 HSV-1 inoculated eyes, but the retinas of injected and uninjected eyes were negative. VEGF was first evident in the retinas of injected eyes at 6 days post-inoculation (Table 1), where 5 of 6 eyes demonstrated patchy staining, primarily in the inner retina (Fig. 1A). At 7-8 days post-inoculation, patchy VEGF staining persisted in the injected eyes of 6 of 9 mice with positivity in the subretinal space in 2 mice that corresponds to areas of inflammatory cell infiltration (Figs. 1B-D). Most of the VEGF protein was eliminated by 8-10 days, when viral antigens were no longer present in the anterior segments of injected eyes (Whittum-Hudson and Pepose, 1987). By 10-13 days post-inoculation, 50% of the mice still demonstrated VEGF positivity, which was largely confined to sparse inflammatory cells present on the inner surface of the ipsilateral retina (Fig. 1E) and in perivascular areas surrounding inner retinal vessels (Fig. 1F). At 3 days post-inoculation, in the retinas of mice injected intraocularly with HBSS, 1 of 7 injected eyes showed some VEGF staining in the intercellular spaces from the outer nuclear layer to the inner nuclear layer. By 7 days post-inoculation, similar extracellular staining was observed in 5 of 8 injected eyes, with one eye also showing staining in the retinal pigment epithelium (RPE) and around the inner segments of the photoreceptors. None of the other retinas from HBSS-injected mice showed cytoplasmic staining for VEGF.

Weak, focal VEGF staining was first demonstrated in the anterior retina of the contralateral eye of 1 of 4 unilaterally-infected mice at 6 days post-inoculation (Table 1). By 7 days post-inoculation, all contralateral uninfected eyes demonstrated intraretinal VEGF staining. The staining appeared patchy and was primarily localized to the inner nuclear and ganglion cell layers

Table 1. VEGF localization in retinas of mice receiving intracameral injections of HSV-1

DAYS Post-inoculation	INJECTED EYE (Positively stained/total)	CONTRALATERAL EYE (Positively stained/total)
0	0/5	0/5
1-3	0/14	0/7
6	5/6	1/4
7-8	6/9	6/7
10-13	6/12	7/8

(Fig. 1G). By 8 days post-inoculation, the VEGF staining intensified and as cell destruction occurred in the retinas of uninjected eyes, prominent VEGF staining could be seen in areas of necrosis (Fig. 1H). At 8 days post-inoculation, contralateral retinas from 3 of 4 mice unilaterally-injected with HSV-1 expressed VEGF immunoreactivity. The VEGF-negative retina, unlike the others, showed normal morphology and could represent a case of model failure. As retinal cell destruction progressed, VEGF expression persisted in a patchy distribution in 7 of 8 retinas (Fig. 2A), primarily in the inner retina and in areas where cellular destruction has occurred. Pre-incubation of VEGF antibodies with control peptide eliminated all immunostaining (Fig. 2B).

Flt-1


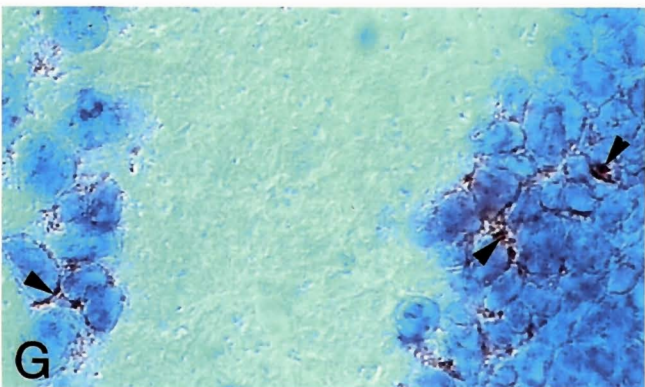
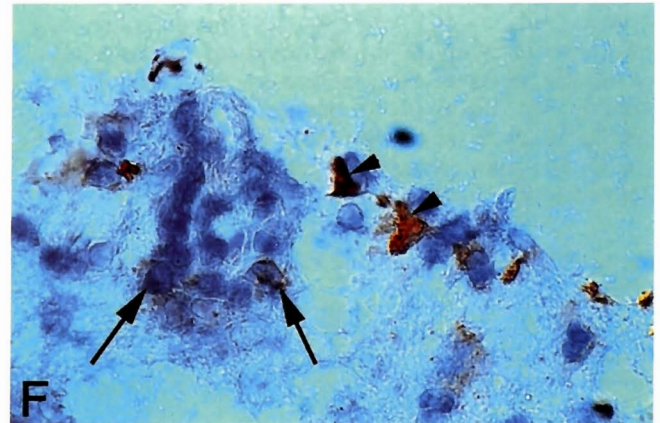
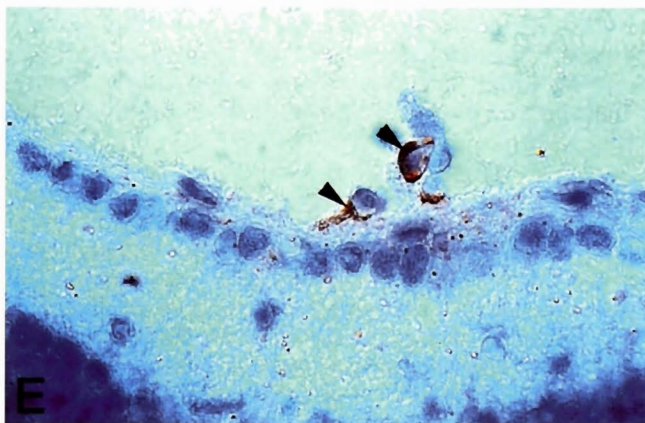
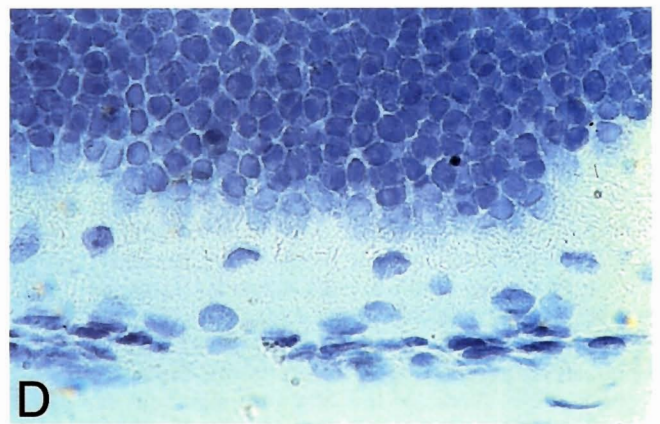
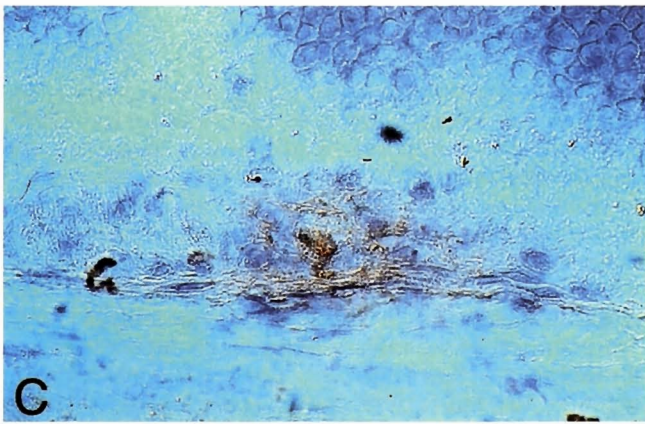
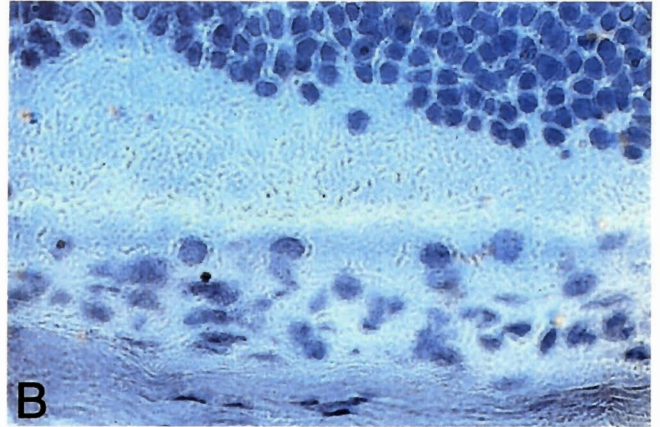
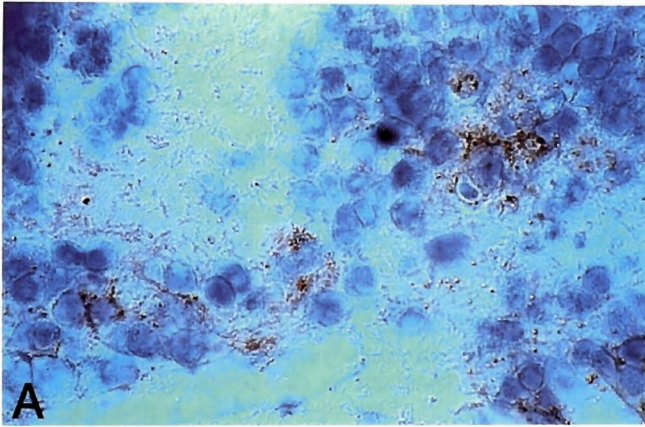
Weak positivity for the VEGF receptor, *flt-1*, was seen in the retinas of normal, uninjected mice, HSV-1 injected eyes, contralateral eyes of mice injected unilaterally with HSV-1 examined prior to the onset of inflammation, and all HBSS-injected eyes (Fig. 2C). *Flt-1* staining was localized to the ganglion cells and the inner nuclear layer in all treatment groups and controls. In the uninjected eyes of mice receiving unilateral HSV-1 inoculations, more intense staining was seen in parallel with the onset of inflammatory cell infiltration and retinal destruction (Fig. 2E). Clusters of inflammatory cells in the subretinal space, resembling those that stained positively for VEGF (see Fig. 1B), were positive for *flt-1* (Fig. 2F). Pre-incubation of *flt-1* antibodies with control peptide eliminated all immunostaining on comparable sections from the same animal, demonstrating the specificity of *flt-1* immunostaining (Fig. 2D).

Flk-1

Most mice, regardless of treatment, showed weak, patchy *flk-1* staining associated with Müller cell processes and the outer plexiform layer or an absence of *flk-1* staining in the retina (Table 2). Retinal positivity for *flk-1*, that was above baseline levels, was first observed in HSV-1 injected eyes 6 days post-inoculation, the same time that VEGF upregulation was first observed. *Flk-1* continued to be upregulated in approximately 50% of the retinas of HSV-1 injected eyes from days 7-13 (Fig. 3A,B), even though the tissues

Fig. 1. Immunolocalization of VEGF in the ipsilateral (A-F) and contralateral (G, H) retinas of mice receiving intraocular injections of HSV-1 into one anterior chamber. **A.** Focal positivity for VEGF is first demonstrated (red reaction product) in the retina of a HSV-1 injected eye at 6 days post-inoculation. **B.** Hematoxylin and eosin stained section of the retina from a HSV-1 injected eye, 8 days post-inoculation, showing subretinal inflammatory cell infiltration (bottom). **C.** A comparable area from the same retina shown in 1B (HSV-1 injected eye, 8 days post-inoculation) showing VEGF staining in the area of inflammatory cell infiltration in the outer retina. **D.** A comparable area to that shown in B and C, in which the VEGF antibodies were pre-incubated with control peptide, reveals no positive staining, demonstrating the specificity of the antibodies. **E.** VEGF staining is largely restricted to sparse inflammatory cells (arrowheads) on the inner surface of the retina in a HSV-1 injected eye, 12 days post-inoculation. **F.** Perivascular staining (arrows) for VEGF in the inner retina of a HSV-1 injected eye, 12 days post-inoculation. Inflammatory cells on the inner surface of the retina (arrowheads) are also positive. **G.** Weak, focal VEGF staining (arrowheads) in the retina of the uninjected eye of a mouse receiving a unilateral HSV-1 injection 7 days prior. **H.** More prominent VEGF staining is associated with areas of retinal necrosis 8 days post-inoculation in the contralateral eye of a mouse receiving HSV-1 injection. x 650

VEGF, TGF β and IL-6 in HSV-1 retinopathy



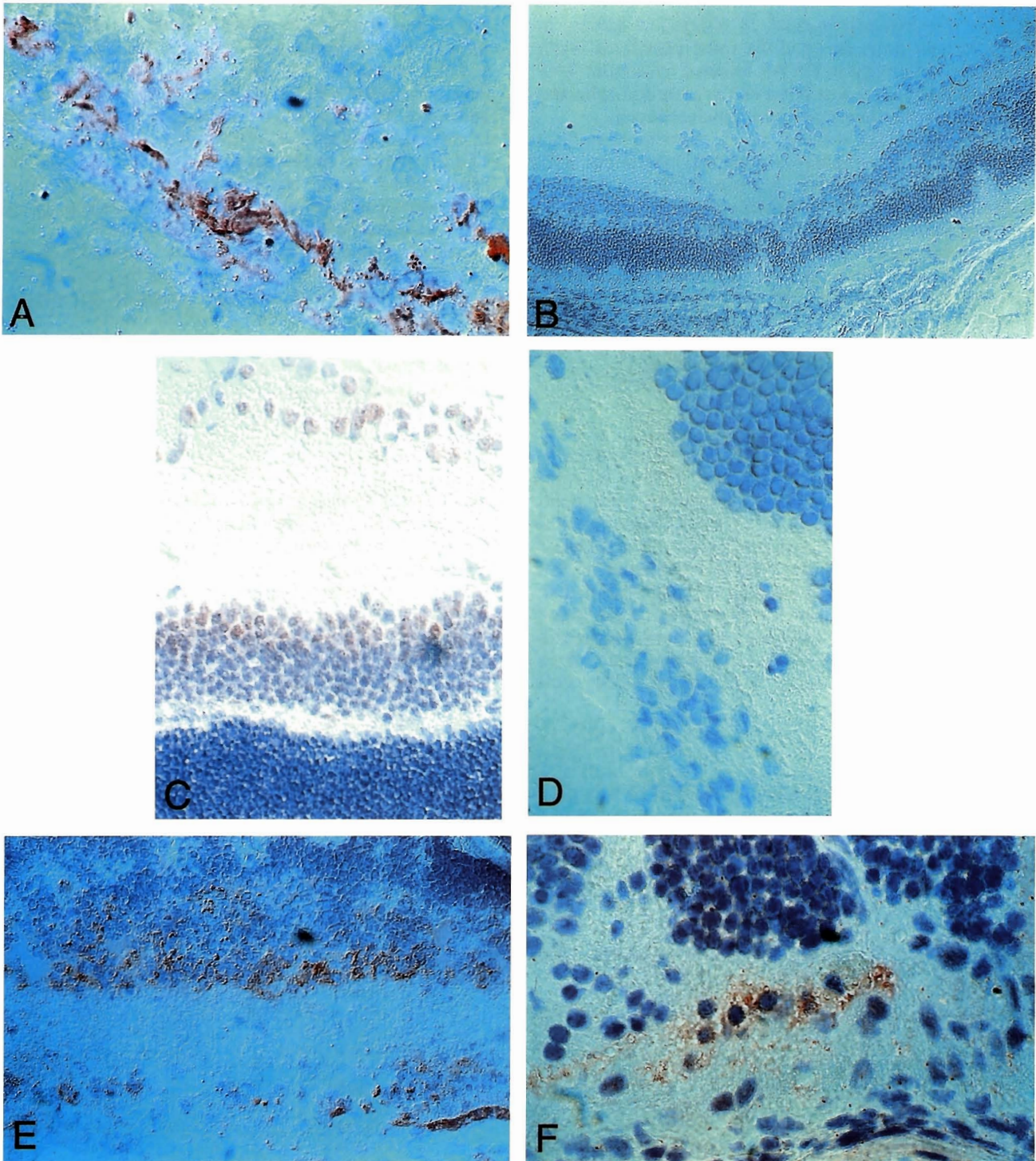
VEGF, TGF β and IL-6 in HSV-1 retinopathy

Fig. 2. Differential localization of VEGF (A-C) and its receptor, flt-1 (D-G), in the retina. **A.** VEGF staining (red reaction product) associated with retinal necrosis 12 days after HSV-1 inoculation in the opposite eye. x 650. **B.** Pre-incubation of anti-VEGF antibodies with VEGF peptide eliminates staining in the retina taken from a mouse 12 days after receiving HSV-1 inoculation in the opposite eye, demonstrating the specificity of the antibodies. This section is from the same animal as illustrated in Fig. 1E, F. x 130. **C.** Weak flt-1 staining (red) associated with the ganglion cells (top) and inner nuclear layer (middle) in the retina of a HSV-1 injected eye, 1 day post-inoculation. x 260. **D.** Pre-incubation of flt-1 antibodies with control peptide shows an absence of immunostaining in a comparable area from the same retina shown in 1B (compare to E and F), demonstrating the specificity of the antibodies. x 650. **E.** Flt-1 staining (red) associated with the onset of inflammatory cell infiltration in the retina of a mouse, 7 days after receiving HSV-1 injection in the opposite eye. x 260. **F.** A subretinal cluster of inflammatory cells comparable to those illustrated in 1B-D demonstrates flt-1 positivity (red), 11 days after receiving HSV-1 injection in the opposite eye. x 650

remained histologically normal. In addition to staining in the Müller cell processes and the outer plexiform layer, retinal flk-1 positivity in HSV-1 injected eyes from 7-13 days post-inoculation was observed in ganglion cells and occasionally in the inner and outer nuclear layers.

In contralateral retinas, flk-1 staining was first observed at 7-8 days post-inoculation, consistent with the upregulation of VEGF. Staining was localized to additional areas other than Müller cell processes and the outer plexiform layer as increased staining of Müller cell processes was observed (Fig. 3C). In these animals, flt-1 staining was also seen in ganglion cells and around areas of necrosis. Only Müller cell processes and the outer plexiform layer expressed flk-1 in retinas of buffer-injected or contralateral uninjected eyes of control mice at earlier times (3 or 7 days) post-inoculation.

TGF β ₁

TGF β ₁ was associated with inflammatory cells in experimental herpesvirus retinopathy. TGF β ₁ was not demonstrated in normal retinas or in retinas 1 day post-inoculation, but it was first localized in the retinas of HSV-1 injected eyes at 2 days post-inoculation, where it was detected in inflammatory cells in the vitreous of 3 of 5 eyes (Fig. 3E). Some inflammatory cells persisted in the vitreous through 13 days and these cells were found to be TGF β ₁-positive. TGF β ₁ was first demonstrated in the contralateral retinas of HSV-1 injected eyes at 7 days post-inoculation, coincident with inflammatory cell infiltration.

TGF β ₂

Weak, patchy or spotty staining for TGF β ₂ was seen in the retinas of control mice and of most HSV-1 injected and contralateral eyes at all time points, thus representing constitutive levels. The weak staining was primarily localized to the inner plexiform layer. By 2

days after inoculation, some clusters of inflammatory cells in the vitreous were labelled for TGF β ₂ and the staining associated with these cells intensified by day 3 (Fig. 3F). Some weak staining of ganglion cells was also observed. By day 6, retinal staining for TGF β ₂ increased in intensity and spread to the outer retina (Fig. 3D,G). TGF β ₂ staining in the retinas of HSV-1 injected mice diminished to normal levels by 8-10 days, as the inflammation subsided. Residual inflammatory cells were decorated with TGF β ₂ antibodies.

In the eyes contralateral to those injected with HSV-1, TGF β ₂ staining above baseline was first evident at 7-8 days, coincident with the infiltration of inflammatory cells and the onset of retinal cell destruction. As acute retinal necrosis progressed, widespread TGF β ₂ staining was demonstrated throughout the retina (Fig. 4A). The staining was particularly intense at the edges of areas of necrosis (Fig. 4C,D).

IL-6

Normal BALB/c mice showed focal staining of Müller cell processes for IL-6 along the inner surface of the retina. Following intraocular injection of HSV-1, retinas demonstrated intermittent staining of Müller cell processes, some extracellular positivity between the cells in the inner nuclear layer, and staining at the interface between the inner nuclear layer and the outer plexiform layer and around vessels (Fig. 4B,E). Some astrocyte processes also stained for IL-6 at 8 days post-inoculation in the HSV-1 injected eye and at 6-8 days post-inoculation in the contralateral eye. Additional intracellular IL-6 staining was seen surrounding areas of retinal cell destruction in the contralateral eyes.

Discussion

Following the inoculation of HSV-1 into the anterior chamber of BALB/c mouse eyes, a transient

Table 2. Flk-1 localization in retinas of mice receiving intraocular injections of HSV-1.

DAY POST-INOCULATION	INOCULUM	INJECTED EYE OR CONTRALATERAL EYE	N	Flk-1 NEGATIVE	Flk-1 STAINING LIMITED TO MÜLLER CELL PROCESSES AND THE OUTER PLEXIFORM LAYER	Flk-1 STAINING INVOLVING RETINAL CELLS OTHER THAN MÜLLER CELLS (Ex: ganglion cells, inner nuclear layer, etc.)
0	HSV-1	Injected	7	5 (71%)	2 (29%)	0 (0%)
0	HSV-1	Contralateral	3	0 (0%)	3 (100%)	0 (0%)
1-3	HSV-1	Injected	15	4 (27%)	11 (73%)	0 (0%)
1-3	HSV-1	Contralateral	5	1 (20%)	4 (80%)	0 (0%)
6	HSV-1	Injected	6	0 (0%)	1 (17%)	5 (83%)
6	HSV-1	Contralateral	4	3 (75%)	1 (25%)	0 (0%)
7-8	HSV-1	Injected	8	1 (12%)	3 (37%)	4 (50%)
7-8	HSV-1	Contralateral	7	1 (14%)	1 (14%)	5 (71%)
10-13	HSV-1	Injected	11	1 (9%)	5 (45%)	5 (45%)
10-13	HSV-1	Contralateral	9	2 (18%)	2 (18%)	5 (56%)
3	HBSS	Injected	7	5 (71%)	2 (29%)	0 (0%)
3	HBSS	Contralateral	3	3 (100%)	0 (0%)	0 (0%)
7	HBSS	Injected	8	2 (25%)	6 (75%)	0 (0%)
7	HBSS	Contralateral	2	0 (0%)	2 (100%)	0 (0%)

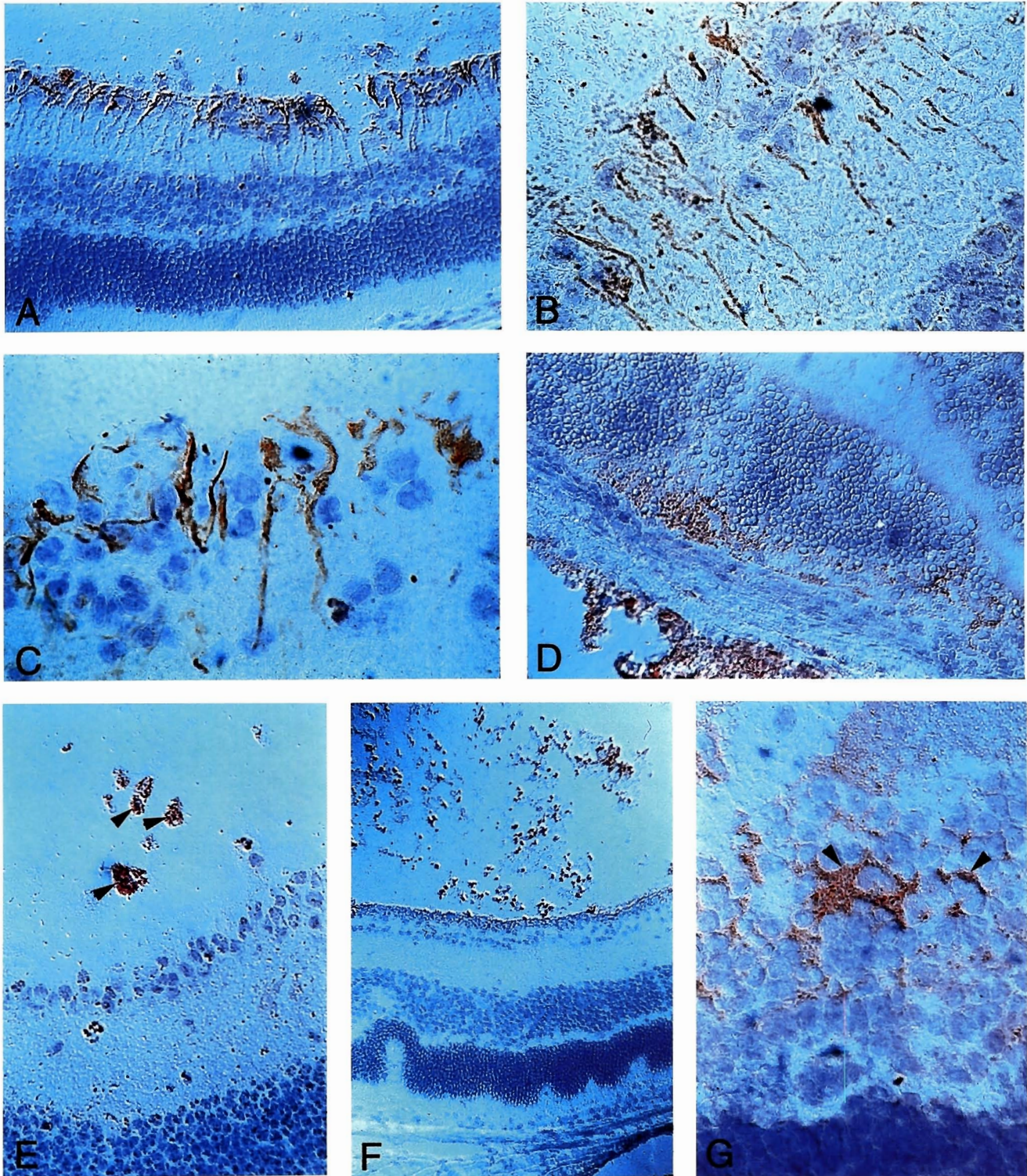


Fig. 3. Immunohistochemical staining for the VEGF receptor, flk-1, (A-C), TGF β ₁ (E), and TGF β ₂ (D,F,G) in the retinas of mice receiving HSV-1 injections into one anterior chamber. x 260. **A.** Flk-1 staining (red) in Müller cell processes along the inner retinal surface in the retina of an HSV-1 injected eye, 7 days post-inoculation. x 260. **B.** Higher magnification shows flk-1 staining of Müller cell processes in the retina of an HSV-1 injected eye, 6 days post-inoculation. x 650. **C.** Flk-1 staining of Müller cell processes in the retina of a mouse, 12 days after receiving HSV-1 injection in the opposite eye. x 260. **D.** TGF β ₂ positivity in the outer retina (red) in an HSV-1 injected eye, 6 days post-inoculation. x 650. **E.** TGF β ₁ staining of inflammatory cells in the vitreous (arrowheads) in an HSV-1 injected eye, 3 days post-inoculation. x 260. **F.** TGF β ₂ staining of inflammatory cells in the vitreous (top) of an HSV-1 injected eye, 3 days post-inoculation. x 130. **G.** Higher magnification showing intraretinal staining for TGF β ₂ (arrowheads) in an HSV-1 injected eye, 6 days post-inoculation. x 650

VEGF, TGF β and IL-6 in HSV-1 retinopathy

inflammatory response was generated in the anterior segment (Whittum et al., 1983; Dix et al., 1987). By 3 days, some inflammatory cells had entered the vitreous. These inflammatory cells provided a source for VEGF in the vitreous of virus injected eyes, but VEGF was not detected within the retina until 6 days post-inoculation, at which time viral antigens were no longer detectable (Whittum-Hudson and Pepose, 1987). Within the contralateral retina, VEGF was first demonstrated at 6 days post-inoculation, which was 1 day prior to the initial detection of viral antigens and inflammatory cell infiltration. VEGF was detectable at 7 days post-inoculation in all contralateral retinas, coincident with the arrival of virus into the retina of uninjected eyes. The

retina in only 1 of 4 eyes at 8 days post-inoculation was entirely negative for VEGF and this retina showed normal morphology, suggesting that model failure may have occurred in this animal. It is possible that even sub-threshold levels of virus present in the contralateral, uninjected eye triggers the production of VEGF. The experimental HSV retinitis model will allow the study of the details of inflammatory responses both at the level of VEGF transcription and translation. This information may help in the development of new therapeutic targets that could interrupt this process earlier in the pathogenesis of ocular infection.

VEGF (Plate et al., 1992; Schweiki et al., 1992; Goldberg and Schneider, 1994; Hashimoto et al., 1994;

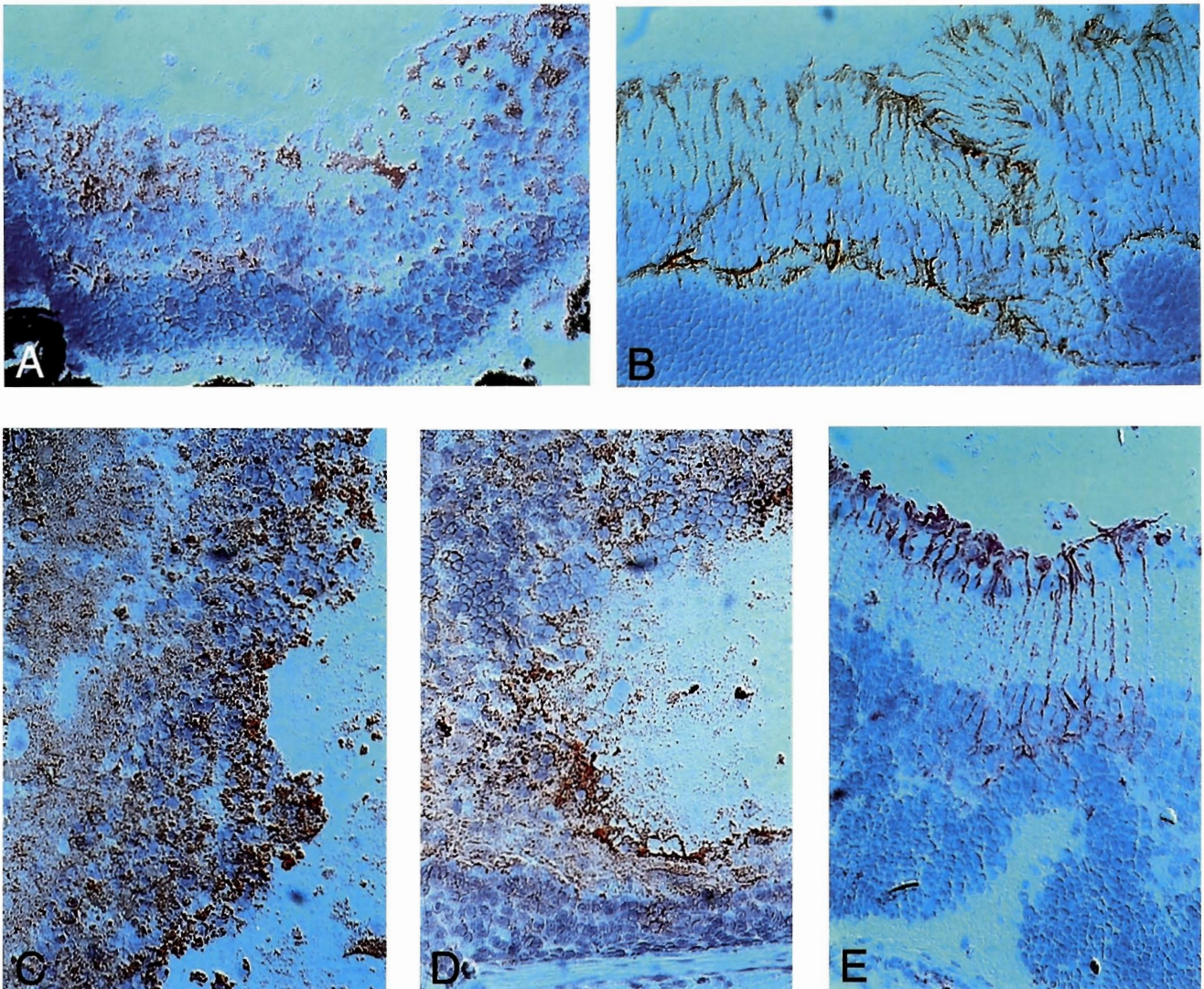


Fig. 4. Immunohistochemical staining for TGF β 2 (A, C, D) and IL-6 (B,E) in the retinas of mice receiving a unilateral injection of HSV-1 in the anterior chamber. **A.** Widespread TGF β 2 staining (red) is demonstrated throughout the retina of a mouse 11 days after HSV-1 injection in the opposite eye. **B.** Seven days after intraocular injection of HSV-1, prominent staining for IL-6 is evident in Müller cell processes. **C.** Widespread retinal TGF β 2 staining is visualized along the edges of necrotic areas in an eye contralateral to the eye receiving HSV-1, 12 days previously. **D.** Another area of widespread retinal TGF β 2 showing particularly intense staining bordering areas of necrosis in mice that received HSV-1 inoculation in the opposite eye 12 days previously. **E.** Conspicuous IL-6 staining of Müller cell processes in the retina of an HSV-1 injected eye, 1 day post-inoculation. x 260

Minchenko, et al., 1994a,b; Levy et al., 1995; Pierce et al., 1995) and its receptors (Tuder et al., 1995; Brogi et al., 1996) are induced under hypoxic conditions, but in herpesvirus induced retinopathy there is no evidence of hypoxia. This presents the likelihood that VEGF is induced by other factors associated with ocular disease, as has been previously suggested (Vinores et al., 1995). Herpesvirus infection has been shown to alter intracerebral and intraocular cytokine production. Among the major cytokine transcripts found in the brains of mice infected with HSV-1 via intraocular injection are TNF α and IL-1 β , which are abundantly expressed by 5 days post-infection (Lewandowski et al., 1994). In the anterior chamber infection model, transcript levels for TNF α , IL-6 (Drescher and Whittum-Hudson, 1996a), and Type I interferons (Drescher and Whittum-Hudson, 1997) are increased 4.5-fold in retinas within 2-3 days post-infection. Both TNF α (Ryuto et al., 1996) and IL- β (Ben-Av et al., 1995; Li et al., 1995; Jackson et al., 1997; Ristimaki et al., 1998) have been shown to be capable of inducing VEGF and the upregulation of these factors occurs with a shorter time interval following the introduction of HSV-1 than is required for intraretinal VEGF induction. Therefore, it is likely that VEGF is indirectly induced by one of these factors or an alternative cytokine whose regulation is altered by HSV-1 infection. Following its upregulation, VEGF may augment the inflammatory response to the virus.

VEGF can promote ocular neovascularization (Adamis et al., 1994; Aiello et al., 1994; Miller et al., 1994; Pierce et al., 1995; Stone et al., 1995; Murata et al., 1996; Ozaki et al., 1997), but in some cases, VEGF is upregulated without neovascularization occurring (Vinores et al., 1997). One possible explanation for this is the presence of an angiogenesis inhibitor. TGF β appears to serve this function in EAU, where it is upregulated concurrently with VEGF (Vinores et al., 1998). TGF β is similarly upregulated prior to VEGF in the retinas of HSV-1 injected eyes and their contralateral counterparts, thus potentially preventing VEGF from exerting its angiogenic activity on the retinal vasculature. The anti-angiogenic activity may be accomplished by a down-regulation of VEGF receptors, as has been reported for vascular endothelial cells (Mandriota et al., 1996).

IL-6 is a multifunctional cytokine that is associated with ocular inflammatory conditions. Müller cells respond rapidly to ocular inflammation or infection and studies using cultured retinal glia and isolated retinas from HSV-1 injected eyes showed that transcript levels of IL-6 are rapidly upregulated and there is secretion of IL-6 from cultured Müller cells upon exposure to HSV-1 or other inflammatory mediators (Drescher and Whittum-Hudson, 1996a,b). Immunohistochemical staining for IL-6 in the retinas of mice receiving intraocular HSV-1 injections showed the localization of IL-6 to Müller cells coincident with the marked upregulation of glial fibrillary acidic protein that occurs

in the same cells during the first 3 days after intraocular injection of HSV-1 (Drescher and Whittum-Hudson, 1996b). Since the earliest induction of IL-6 is observed in retinas that do not undergo necrosis nor become highly inflamed, IL-6 is likely to be immunomodulatory or provide antiviral protection. IL-6 may downregulate IL-1 β and/or TNF α expression to mute the potentially destructive inflammation in ipsilaterally injected eyes. IL-6 expression in the retinas of HSV-1 injected eyes persists to at least 13 days post-injection and it becomes more widespread with the onset of retinal necrosis in the contralateral eye. The present study demonstrates that the intraocular injection of live virus into the anterior chamber is sufficient for the induction of VEGF, flk-1, TGF β ₂, and IL-6 in the retina of the injected eye, as well as the contralateral, uninjected eye.

The experimental model of herpesvirus retinopathy appears to share relevant features with the human disease including anti-herpes antibodies (DeBoer et al., 1994) and acute retinal necrosis (Thompson et al., 1994). Therefore, the information derived from the study of this experimental model, which provides the setting of a transient inflammatory response in one eye and subsequent virus-mediated acute retinal necrosis in the opposite eye, should be applicable to human herpesvirus retinopathy and is likely to provide information regarding the interaction of cytokines and inflammatory mediators in the pathogenesis of the disease. Based on the results of this study, strategies that modulate the induction of VEGF, flk-1, TGF β ₂, or IL-6 may have a beneficial effect on the course of herpesvirus retinopathy and acute retinal necrosis.

Acknowledgments. Supported by grants EY 10017 and EY 05951 (SAV), and EY 05475 (JWH), from the National Eye Institute, Fight for Sight, Inc. (JWH), and by a Lew R. Wasserman Merit Award (SAV) and an unrestricted grant from Research to Prevent Blindness.

References

- Adamis A.P., Miller J.W., Bernal M.-T., D'Amico D.J., Folkman J., Yeo T.-K. and Yeo K.T. (1994). Increased vascular endothelial growth factor levels in the vitreous of eyes with proliferative diabetic retinopathy. *Am. J. Ophthalmol.* 118, 445-450.
- Aiello L.P., Avery R.L., Arrigg P.G., Keyt B.A., Jampel H.D., Shah S.T., Pasquale L.R., Thieme H., Iwamoto M.A., Park J.E., Nguyen H.V., Aiello L.M., Ferrara N. and King G.L. (1994). Vascular endothelial growth factor in ocular fluid of patients with diabetic retinopathy and other retinal disorders. *New Engl. J. Med.* 331, 1480-1487.
- Barleon B., Sozzani S., Zhou D., Weich H.A., Mantovani A. and Marme D. (1996). Migration of human monocytes in response to vascular endothelial growth factor (VEGF) is mediated via the VEGF receptor flt-1. *Blood* 87, 3336-3343.
- Behzadian M.A., Wang X.-L., Jiang B. and Caldwell R.B. (1995). Angiostatic role of astrocytes: Suppression of vascular endothelial cell growth by TGF- β and other inhibitory factor(s). *Glia* 15, 480-490.
- Ben-Av P., Crofford L.J., Wilder R.L. and Hla T. (1995). Induction of vascular endothelial growth factor expression in synovial fibroblasts

VEGF, TGF β and IL-6 in HSV-1 retinopathy

- by prostaglandin E and interleukin-1: A potential mechanism for inflammatory angiogenesis. *FEBS Lett.* 372, 82-87.
- Benson M.T., Shepherd L., Rees R.C. and Rennie I.G. (1992). Production of interleukin-6 by human retinal pigment epithelium in vitro and its regulation by other cytokines. *Curr. Eye Res.* 11 (suppl), 173-179.
- Brett F.M., Mizisin A.P., Powell H.C. and Campbell I.L. (1995). Evolution of neuropathologic abnormalities associated with blood-brain barrier breakdown in transgenic mice expressing interleukin-6 in astrocytes. *J. Neuropathol. Exp. Neurol.* 54, 766-775.
- Broggi E., Schatteman G., Wu T., Kim E.A., Varticovski L., Keyt B. and Isner J.M. (1996). Hypoxia-induced paracrine regulation of vascular endothelial growth factor receptor expression. *J. Clin. Invest.* 97, 469-476.
- Chakravarthy U. and Archer B.D. (1992). Endothelin: A new vasoactive ocular peptide. *Br. J. Ophthalmol.* 76, 107-108.
- Chen Y.-S., Hackett S.F., Schoenfeld C.-L., Viores M.A., Viores S.A. and Campochiaro P.A. (1997). Localization of vascular endothelial growth factor and its receptors to cells of vascular and avascular epiretinal membranes. *Br. J. Ophthalmol.* 81, 919-926.
- Clauss M., Weich H., Breier G., Knies U., Rockl W., Waltenberger J. and Risau W. (1996). The vascular endothelial growth factor receptor Flt-1 mediates biological activities. Implications for a functional role of placenta growth factor in monocyte and chemotaxis. *J. Biol. Chem.* 271, 17629-17634.
- Connolly D.T., Olander J.V., Heuvelman D., Nelson R., Monsell R., Siegel N., Haymore B.L., Leimgruber R. and Feder J. (1989). Human vascular permeability factor. *J. Biol. Chem.* 264, 20017-20024.
- DeBoer J.H., Luyendijk L., Rothova A., Baarsma G.S., deJong P.T.V.M., Bolemeijer J.-G., Rademakers A.J.J.M., Van der Lelij A., Zaai M.J.W. and Kijlstra A. (1994). Detection of intraocular antibody production to herpesviruses in acute retinal necrosis syndrome. *Am. J. Ophthalmol.* 17, 201-210.
- DeBoer J.H., van Haren M.A.C., deVries-Knoppert W.A.E.J., Baarsma G.S., deJong P.V.T.M., Postema F.J., Rademakers A.J.J.M. and Kijlstra A. (1992). Analysis of IL-6 levels in human vitreous fluid obtained from uveitis patients, patients with proliferative intraocular disorders and eye bank eyes. *Curr. Eye Res.* 11 (suppl), 181-186.
- DeVos A.F., Hoekzema R. and Kijlstra A. (1992). Cytokines and uveitis, A review. *Curr. Eye Res.* 6, 581-599.
- DeVos A.F., van Haren M.A.C., Verhagen C., Hoekzema R. and Kijlstra A. (1995). Tumor necrosis factor-induced uveitis in the Lewis rat is associated with intraocular interleukin-6 production. *Exp. Eye Res.* 60, 199-207.
- Dix R.D., Streilein J.W., Cousins S. and Atherton S.S. (1987). Histopathologic characteristics of two forms of experimental herpes simplex virus retinitis. *Curr. Eye Res.* 6, 47-52.
- Drescher K.M. and Whittum-Hudson J.A. (1996a). Modulation of immune-associated surface markers and cytokine production by murine retinal glial cells. *J. Neuroimmunol.* 64, 71-81.
- Drescher K.M. and Whittum-Hudson J.A. (1996b). HSV-1 alters transcript levels of TNF and IL-6 in retinal glial cells. *Invest. Ophthalmol. Vis. Sci.* 37, 2302-2312.
- Drescher K.M. and Whittum-Hudson J.A. (1997). Evidence for induction of interferon-alpha and interferon-beta in retinal glial cells of Müller. *Virology* 234, 309-316.
- Franks W.A., Limb G.A., Stanford M.R., Ogilvie J., Wolstencroft R.A. and Chignell A.H. (1992). Cytokines in human intraocular inflammation. *Curr. Eye Res.* 1 (suppl), 187-191.
- Goldberg M.A. and Schneider T.J. (1994). Similarities between the oxygen-sensing mechanisms regulating the expression of vascular endothelial growth factor and erythropoietin. *J. Biol. Chem.* 269, 4355-4359.
- Harada S., Nagy J.A., Sullivan K.A., Thomas K.A., Endo N., Rodan G.A. and Rodan S.B. (1994). Induction of vascular endothelial growth factor expression by prostaglandin E2 and E1 in osteoblasts. *J. Clin. Invest.* 93, 2490-2496.
- Hashimoto E., Kage K., Ogita T., Nakaoka T., Matsuoka R. and Kira Y. (1994). Adenosine as an endogenous mediator of hypoxia for induction of vascular endothelial growth factor mRNA in U-937 cells. *Biochem. Biophys. Res. Commun.* 204, 318-324.
- Hoekzema R., Verhagen C., van Haren M. and Kijlstra A. (1992). Endotoxin-induced uveitis in the rat: The significance of intraocular interleukin-6. *Invest. Ophthalmol. Vis. Sci.* 33, 532-539.
- Jackson J.R., Minton J.A., Ho M.L., Wei N. and Winkler J.D. (1997). Expression of vascular endothelial growth factor in synovial fibroblasts is induced by hypoxia and interleukin 1beta. *J. Rheumatol.* 24, 1253-1259.
- Jennings J.C., Mohan S., Linkhart T.A., Widstrom R. and Bayling K.J. (1988). Comparison of the biological activities of TGF-beta 1 and TGF-beta 2: Differential activity in endothelial cells. *J. Cell. Physiol.* 137, 167-172.
- Kishimoto T., Taga T. and Akira S. (1994). Cytokine signal transduction. *Cell* 76, 253-263.
- Kulkarni A.B., Ward J.M., Yaswen L., Mackall C.L., Bauer S.R., Huh C.-G., Gress R.E. and Karlsson S. (1995). Transforming growth factor-beta 1 null mice. An animal model for inflammatory disorders. *Am. J. Pathol.* 46, 264-275.
- Kuppner M.C., McKillop-Smith S. and Forrester J.V. (1995). TGF- β and IL-1 β act in synergy to enhance IL-6 and IL-8 mRNA levels and IL-6 production by human retinal pigment epithelial cells. *Immunology* 84, 265-271.
- Levy A.P., Levy N.S., Wegner S. and Goldberg M.S. (1995). Transcriptional regulation of the rat vascular endothelial growth factor gene by hypoxia. *J. Biol. Chem.* 270, 13333-13340.
- Lewandowski G., Hobbs M.V. and Bloom F.E. (1994). Alteration of intracerebral cytokine production in mice infected with herpes simplex virus types 1 and 2. *J. Neuroimmunol.* 55, 23-34.
- Li J., Perrella M.A., Tsai J.-C., Yet S.F., Hsieh C.M., Yoshizuma M., Patterson C., Endege W.O., Schlegel R. and Lee M.E. (1995). Induction of vascular endothelial growth factor gene expression by interleukin-1 β in rat aortic smooth muscle cells. *J. Biol. Chem.* 270, 308-312.
- Lu M., Perez V.L., Ma N., Miyamoto K., Peng H.-B., Liao J.K. and Adams A.P. (1999). VEGF increases retinal vascular ICAM-1 expression in vivo. *Invest. Ophthalmol. Vis. Sci.* 40, 1808-1812.
- Luna J.D., Chan C.-C., Derevanik N.L., Mahlow J., Chiu C., Peng B., Tobe T., Campochiaro P.A. and Viores S.A. (1997). Blood-retinal barrier (BRB) breakdown in experimental autoimmune uveoretinitis: Comparison with vascular endothelial growth factor, tumor necrosis factor α , and interleukin-1 β -mediated breakdown. *J. Neurosci. Res.* 49, 268-280.
- Mandriota S.J., Menoud P.-A. and Pepper M.S. (1996). Transforming growth factor β 1 down-regulates vascular endothelial growth factor receptor 2/flk-1 expression in vascular endothelial cells. *J. Biol. Chem.* 271, 1500-1505.
- McAvoy J. and Chamberlain C.G. (1990). Growth factors in the eye. *Prog. Growth Factor Research* 2, 29-43.

- Melder R.J., Koenig C.G., Witwer B.P., Safabakhsh N., Munn L.L. and Jain R.K. (1996). During angiogenesis, vascular endothelial growth factor and basic fibroblast growth factor regulate natural killer cell adhesion to tumor endothelium. *Nature Med.* 2, 992-997.
- Miller J.W., Adamis A.P., Shima D.T., D'Amore P.A., Moulton R.S., O'Reilly M.S., Folkman J., Dvorak H.F., Brown L.F., Berse B., Yeo T.-K. and Yeo K.-T. (1994). Vascular endothelial growth factor/vascular permeability factor is temporally and spatially correlated with ocular angiogenesis in a primate model. *Am. J. Pathol.* 145, 574-584.
- Minchenko A., Salceda S. and Caro J. (1994a). Hypoxic stimulation of vascular endothelial growth factor expression in vitro and in vivo. *Lab. Invest.* 71, 374-379.
- Minchenko A., Salceda S., Bauer T. and Caro J. (1994b). Hypoxia regulatory elements of the human vascular endothelial growth factor gene. *Cell. Mol. Biol. Res.* 40, 35-39.
- Murata T., Nakagawa K., Khalil A., Ishibashi T., Inomata H. and Sueishi K. (1996). The relation between expression of vascular endothelial growth factor and breakdown of the blood-retinal barrier in diabetic rat retinas. *Lab. Invest.* 74, 819-825.
- Murray L. and Martens C. (1990). Abnormal T cells from Ips mice down-regulate transcription of interferon- γ and tumor necrosis factor- α in vitro. *Cell. Immunol.* 126, 367-376.
- Ozaki H., Hayashi H., Viores S.A., Moromizato Y., Campochiaro P.A. and Oshima K. (1997). Intravitreal sustained release of VEGF causes neovascularization in rabbits and breakdown of the blood-retinal barrier in rabbits and primates. *Exp. Eye Res.* 64, 505-517.
- Pertovaara L., Kaipainen A., Mustonen T., Orpana A., Ferrara N., Saksela O. and Alitalo K. (1994). Vascular endothelial growth factor is induced in response to transforming growth factor- β in fibroblastic and epithelial cells. *J. Biol. Chem.* 269, 6271-6274.
- Pierce E.A., Avery R.L., Foley E.D., Aiello L.P. and Smith L.E.H. (1995). Vascular endothelial growth factor/vascular permeability factor expression in a mouse model of retinal neovascularization. *Proc. Natl. Acad. Sci. USA* 92, 905-909.
- Plate K.H., Breier G., Weich H.A. and Risau W. (1992). Vascular endothelial growth factor is a potential tumor angiogenesis factor in human gliomas in vivo. *Nature* 359, 845-848.
- Planck S.R., Dang T.T., Graves D., Tara D., Ansel J.C. and Rosenbaum J.T. (1992). Retinal pigment epithelial cells secrete interleukin-6 in response to interleukin-1. *Invest. Ophthalmol. Vis. Sci.* 33, 78-82.
- Ristimaki A., Narko K., Enholm B., Joukov V. and Alitalo K. (1998). Proinflammatory cytokines regulate expression of the lymphatic endothelial growth factor-C. *J. Biol. Chem.* 273, 8413-8418.
- Ryuto M., Ono M., Izumi H., Yoshida S., Weich H.A., Kohno K. and Kuwano M. (1996). Induction of vascular endothelial growth factor by tumor necrosis factor alpha in human glioma cells. Possible roles of SP-1. *J. Biol. Chem.* 271, 28220-28228.
- Samaniego F., Markham P.D., Gendelman R., Watanaabe Y., Kao V., Kowalski K., Sonnabend J.A., Pintus A., Gallo R.C. and Ensoli B. (1998). Vascular endothelial growth factor and basic fibroblast growth factor present in Kaposi's sarcoma (KS) are induced by inflammatory cytokines and synergize to promote vascular permeability and KS lesion development. *Am. J. Pathol.* 152, 1433-1443.
- Shweiki D., Itin A., Soffer D. and Keshet E. (1992). Vascular endothelial growth factor induced by hypoxia may mediate hypoxia-initiated angiogenesis. *Nature* 359, 843-845.
- Stone J., Itin A., Alon T., Pe'er J., Gnessin H., Chan-Ling T. and Keshet E. (1995). Development of retinal vasculature is mediated by hypoxia-induced vascular endothelial growth factor (VEGF) expression by neuroglia. *J. Neurosci.* 15, 4738-4747.
- Thompson W.S., Culbertson W.W., Smiddy W.E., Robertson J.E. and Rosenbaum J.T. (1994). Acute retinal necrosis caused by reactivation of herpes simplex virus type 2. *Am. J. Ophthalmol.* 118, 205-211.
- Tsai J.-C., Goldman C.K. and Gillespie G.Y. (1995). Vascular endothelial growth factor in human glioma cell lines: induced secretion by EGF, PDGF-BB, and bFGF. *J. Neurosurg.* 82, 864-873.
- Tuder R.M., Flook B.E. and Voelkel N.F. (1995). Increased gene expression for VEGF and the VEGF receptors KDR/FLK and FLT in lungs exposed to acute or to chronic hypoxia - modulation of gene expression by nitric oxide. *J. Clin. Invest.* 95, 1798-1807.
- Van Snick J. (1990). Interleukin-6: An overview. *Annu. Rev. Immunol.* 8, 253-278.
- Viores S.A., Kuchle M., Mahlow J., Chiu C., Green W.R. and Campochiaro P.A. (1995). Blood-retinal barrier breakdown in eyes with ocular melanoma: A potential role for vascular endothelial growth factor. *Am. J. Pathol.* 147, 1289-1297.
- Viores S.A., Youssri A.I., Luna J.D., Chen Y.-S., Bhargava S., Viores M.A., Schoenfeld C.-L., Peng B., Chan C.-C., LaRochelle W., Green W.R. and Campochiaro P.A. (1997). Upregulation of vascular endothelial growth factor in ischemic and non-ischemic human and experimental retinal disease. *Histol. Histopathol.* 12, 99-109.
- Viores S.A., Chan C.-C., Viores M.A., Mateson D.M., Chen Y.-S., Klein D.A., Shi A., Ozaki H. and Campochiaro P.A. (1998). Increased vascular endothelial growth factor (VEGF) and transforming growth factor β (TGF β) in experimental autoimmune uveoretinitis: Upregulation of VEGF without neovascularization. *J. Neuroimmunol.* 89, 43-50.
- Watson C., Whittaker S., Smith N., Vora A.J., Dumonde D.C. and Brown K.A. (1996). IL-6 acts on endothelial cells to preferentially increase their adherence for lymphocytes. *Clin. Exp. Immunol.* 105, 112-119.
- Whittum J.A., McCulley J.P., Niederkorn J.Y. and Streilein J.W. (1984). Ocular disease induced in mice by anterior chamber inoculation of herpes simplex virus. *Invest. Ophthalmol. Vis. Sci.* 25, 1065-1073.
- Whittum J.A., Niederkorn J.Y., McCulley J.P. and Streilein J.W. (1983). Intracameral inoculation of herpes simplex virus type I induces anterior chamber associated immune deviation. *Curr. Eye Res.* 2, 691-697.
- Whittum-Hudson J.A. and Pepose J.S. (1987). Immunologic modulation of virus-induced pathology in a murine model of acute herpetic retinal necrosis. *Invest. Ophthalmol. Vis. Sci.* 28, 1541-1548.
- Yoshimura N., Matsumoto M., Shimizu H., Mandai M., Hata Y. and Ishibashi T. (1995). Photocoagulated human retinal pigment epithelial cells produce an inhibitor of vascular endothelial cell proliferation. *Invest. Ophthalmol. Vis. Sci.* 36, 1686-1691.
- Yoshida M., Yoshimura N., Hangai M., Tanihara H. and Honda Y. (1994). Interleukin-1 α , interleukin-1 β , and tumor necrosis factor gene expression in endotoxin-induced uveitis. *Invest. Ophthalmol. Vis. Sci.* 35, 1107-1113.