

# Feasibility of early removal of chest tube in the operating room for spontaneous pneumothorax : A prospective randomized controlled study.

著者	KAWAGUCHI Yo, HANAOKA Jun, HAYASHI Kazuki
journal or publication title	Asian journal of surgery
year	2020-09-10
URL	<a href="http://hdl.handle.net/10422/00012806">http://hdl.handle.net/10422/00012806</a>

doi: 10.1016/j.asjsur.2020.08.009(<https://doi.org/10.1016/j.asjsur.2020.08.009>)



Contents lists available at ScienceDirect

Asian Journal of Surgery

journal homepage: [www.e-asianjournalsurgery.com](http://www.e-asianjournalsurgery.com)

## Original Article

# Feasibility of early removal of chest tube in the operating room for spontaneous pneumothorax: A prospective randomized controlled study

Yo Kawaguchi <sup>a, b, \*</sup>, Jun Hanaoka <sup>a</sup>, Kazuki Hayashi <sup>a, b</sup><sup>a</sup> Division of General Thoracic Surgery, Department of Surgery, Shiga University of Medical Science, Shiga, Japan<sup>b</sup> Division of General Thoracic Surgery, Kusatsu General Hospital, Shiga, Japan

## ARTICLE INFO

## Article history:

Received 8 April 2020

Received in revised form

16 July 2020

Accepted 20 August 2020

Available online xxx

## Keywords:

Bullectomy

Chest tube

Drainage tube placement

Spontaneous pneumothorax

## ABSTRACT

**Background/Objective:** Chest drainage tube after surgery causes pain and prolonged length of hospital stay. Especially, young patients tend to experience greater postoperative pain than elderly patients. Therefore, we needed to discuss the indication of chest tube placement. The purpose of this study was to demonstrate the safety and advantages of post-operative management without drainage tube placement, by comparing cases with and without drainage tube placement.

**Methods:** Patients who underwent bullectomy for spontaneous pneumothorax were enrolled in this prospective randomized controlled study and randomized into two groups: group with a post-operative chest tube and group without a chest tube. Surgery and post-operative management were performed according to our protocol.

**Results:** Among the 42 patients, pneumothorax occurred in 1 patient with a chest tube a day after tube removal. Patients without chest tube had significantly lower post-operative pain ( $P = 0.107$ – $P < 0.001$ ), despite their reduced use of rescue drugs. The mean length of post-operative hospital stay was 2.5 days in patients with chest tube, which was significantly longer than that of patients without chest tube (1.2 days;  $P < 0.001$ ).

**Conclusions:** Our patient selection and surgical protocols may be feasible and contribute to post-operative pain control.

© 2020 Asian Surgical Association and Taiwan Robotic Surgery Association. Publishing services by Elsevier B.V. This is an open access article under the CC BY-NC-ND license (<http://creativecommons.org/licenses/by-nc-nd/4.0/>).

## 1. Introduction

Although a chest drainage tube is placed routinely after lung resection, the indication of chest tube placement is rarely discussed. Chest drainage tubes often cause pain and prolonged length of hospital stay. Especially, young patients tend to experience greater post-operative pain than elderly patients,<sup>1</sup> and chest tube-associated pain is the main cause of post-operative pain. Moreover, most young patients prefer to be discharged earlier because they want to return to work or school.

Prolonged post-operative air leakage rarely occurs and post-operative bleeding does not occur in patients undergone bullectomy.<sup>2,3</sup> placement of a drainage tube might have more

disadvantages such as pain control or prolonged hospital stay, than disadvantages such as early detection of air leakage or bleeding. We think that chest tube placement is not always necessary in patients who have undergone bullectomy for the purpose of pain control or reducing the duration of hospitalization. However, there are no reports on the management of patients who had undergone surgery for spontaneous pneumothorax without post-operative drainage tube placement. Judging whether placement of drainage tube after surgery was needed or not might be difficult because many clinical and surgical factors are related to post-operative air leakage. Therefore, simple and safe criteria are needed.

The purpose of this study was to demonstrate the safety and advantages of the post-operative management of patients without chest tube placement, by comparing with cases with and without chest tube placement, under the specific criteria.

\* Corresponding author. Tsukinowacho, Seta, Otsu, Shiga, 520-2192, Japan.

E-mail address: [kawaguchi1228@yahoo.co.jp](mailto:kawaguchi1228@yahoo.co.jp) (Y. Kawaguchi).

<https://doi.org/10.1016/j.asjsur.2020.08.009>

1015-9584/© 2020 Asian Surgical Association and Taiwan Robotic Surgery Association. Publishing services by Elsevier B.V. This is an open access article under the CC BY-NC-ND license (<http://creativecommons.org/licenses/by-nc-nd/4.0/>).

## 2. Methods

We obtained institutional review board approval for this study (Number: 2017-0317-06). All patients provided written informed consent prior to study participation.

### 2.1. Study design

This was a single center, stratified, controlled study conducted in Japan. Patients who underwent bullectomy for spontaneous pneumothorax were enrolled between September 2016 and December 2019 in this study. The inclusion criteria were as follows: spontaneous pneumothorax with bulla revealed on computed tomography scans, ages ranging from 15 to 40 years, American Society of Anesthesiologist performance status class 1 or 2, and written informed consent for participation in this study (Table 1). Spontaneous pneumothorax was diagnosed in the absence of clinically apparent underlying lung disease on computed tomography scans. The exclusion criteria were as follows: secondary spontaneous pneumothorax, difficulty of intubation judged by an anesthesiologist, dense and broad adhesions ( $\geq 30\%$ ) of the lung surface by thoracoscopic observation, and air leakage during an intraoperative sealing test (Table 1). To simplify the criteria, we did not exclude the following clinical and surgical factors; tension pneumothorax, recurrent pneumothorax, and number or size of blebs.

The patients were randomized into two groups using a random number list in EXEL: a group with a chest tube after bullectomy, comprising 21 patients; and a group without a chest tube after bullectomy, comprising 21 patients. The following data were evaluated and compared between the two groups: patient's characteristics, surgical time, post-operative pain, length of hospital stay, post-operative morbidity, cost of surgery, and post-operative management. The primary endpoint was post-operative morbidity, by which we could judge the feasibility of post-operative management without drainage tube placement. The secondary endpoints were post-operative pain, length of hospital stay, and cost of surgery.

### 2.2. Surgical protocol

Patients were operated under general anesthesia with single-lung ventilation, utilizing a double-lumen intubation. Surgical access of the lung was established via the 6th intercostal spaces at the anterior-axillary line, and the 7th intercostal spaces at the posterior-axillary line, using a 2-cm incision. One access port was placed via the 4th intercostal spaces at the mid-axillary line using a 1-cm incision. We observed the whole pulmonary pleura to locate the bulla or bleb, and if an adhesion was present, we detached it. Bullectomy was performed using an Endo GIA tri-stapler (Covidien, USA). A sealing test of the staple line was performed under bilateral

ventilation at 20 cmH<sub>2</sub>O of the maximum intrabronchial pressure. At this sealing test, we confirmed that the lung flexibly expanded by thoracoscope. If the lung did not sufficiently expand, anesthesiologists removed airway secretion by bronchoscope and lung re-expanded by 20 cmH<sub>2</sub>O of the maximum intrabronchial pressure. After the sealing test, the staple stump was covered with a polyglycolic acid sheet. A chest drainage tube with 16-Fr W lumen trocar catheter (Covidien, Japan) was inserted at the top of the pleural cavity from the wound of the 6th intercostal spaces at the anterior-axillary line. After the other wounds were closed, the chest tube was connected to a portable suction drainage system (Chest Drain Bag; Sumitomo Bakelite), and continuous suction was applied at  $-15$  cmH<sub>2</sub>O in the operating room. In the head-up position at 15°, we once again performed a sealing test at 20 cmH<sub>2</sub>O of maximum intrabronchial pressure by observing the portable suction drainage system. When the air leakage was identified in each sealing test, the patients were excluded from the study.

Lung expansion was identified by a routine portable chest roentgenogram, which was performed within 5 min after surgery completion and before the patients awoke from anesthesia. If the patient was assigned to the group without a chest tube placement, the tube was removed immediately after extubation. We did not use thoracic epidural block or intercostal nerve block for post-operative pain control. However, about 10 min before the surgery finished (at the time when we started to close incisions), the patients were administered intravenously 1000-mg acetaminophen.

### 2.3. Post-operative management

Within the 24 postoperative hours, patients can use rescue drugs of 50-mg flurbiprofen axetil, 15-mg pentazocine, or 1000-mg acetaminophen intravenously every 6 h, if requested. All patients were administered roxoprofen sodium hydrate three times a day after a meal from 1 day post-operatively.

In the group without a chest tube, a portable chest roentgenogram was taken on post-operative day 1. If the chest roentgenogram showed no signs of pneumothorax or no pleural effusion which requires thoracic drainage, the patient was permitted to discharge. In the group with a chest tube, a portable chest roentgenogram was taken on post-operative day 1. If the chest roentgenogram revealed lung expansion, absence of air leakage, and minimal amount of drainage, the chest tube was removed. If the chest roentgenogram at post-operative day 2 does not show signs of pneumothorax or no pleural effusion, which requires thoracic drainage, the patient was permitted to discharge. Patients in both groups underwent the same monitoring protocol after the chest tube removal, wherein patients were closely observed while in the hospital until the following day of chest tube removal. No further roentgenogram was taken after the patients in both groups were discharged, unless chest abnormalities were observed.

**Table 1**  
The inclusion and exclusion criteria for this study.

Inclusion criteria for this study
Spontaneous pneumothorax with bulla
Ages ranging from 15 to 40 years old
ASA PS: 1 or 2
Written informed consent was obtained
Exclusion criteria for this study
Secondary spontaneous pneumothorax
Difficulty of intubation
Dense and broad adhesions ( $\geq 30\%$ ) of lung surface
Air leaks during an intraoperative sealing test

#### 2.4. Evaluation of post-operative pain

We classified post-operative pain into wound pain (patients expressed pain on the chest side with the wound) and chest tube-associated pain (patients expressed intrathoracic pain). These pains were assessed at 0.5 h, 4 h, the next morning after the patients come back to ordinary ward from operation room, and at post-operative days 7 or 9 during outpatient visits using a numeric rating scale (NRS; 0–10: 0 = no pain, 10 = worst imaginable pain).

#### 2.5. Statistical analysis

Statistical analysis was performed using SPSS Statistics for Windows, version 25 (SPSS Inc., Chicago, IL, USA). The  $\chi^2$  test was used to compare categorical variables. Differences in the characteristics, post-operative NRS intensity, and cumulative incidence rate of use of rescue drugs for post-operative pain between the two groups were assessed with Student's t-test. Statistically significant differences were defined as  $p < 0.05$ .

### 3. Results

#### 3.1. Clinical characteristics

In this study period, 48 patients underwent surgery for spontaneous pneumothorax; of these, four patients were excluded because they did not provide consent. Thus, 44 patients underwent bullectomy according to our surgical protocol, but two patients were further excluded because of broad adhesion (one patient) and existence of air leakage by sealing test (one patient), which were found during the operation (Fig. 1). The groups with and without a chest tube comprised 21 patients each.

The patients' characteristics are summarized in Table 2. There were no significant differences in age, sex, smoking history, and side of pneumothorax between the two groups. Based on the operative findings, pleural adhesions and number of stapler cartridges required for bullectomy were not significantly different, but the operative time was slightly longer in the group with a chest tube than in the group without a chest tube. Three cases needed more than 50 min operative time in chest tube group. Of three cases, two cases had adhesions in apex area which required some time to detach. In one case, anesthesiologists took long time in

sealing test because lung did not expand due to airway secretion and they removed it by bronchoscopy. Operative times were less than 50 min for the group without chest tube.

#### 3.2. Post-operative chest pain

In both groups, pain intensity was the highest within the 0.5-h postoperative period, which then decreased with time. Regarding wound pain, patients without a chest tube had a significantly lower pain score at 4 h postoperatively and the next morning after the surgery than those with a chest tube (Fig. 2). Regarding the chest tube-associated pain, patients without a chest tube had significantly lower pain score at 0.5 h postoperatively, 4 h postoperatively, and the next morning after the surgery postoperative pain than patients with a chest tube (Fig. 3). Furthermore, patients with a chest tube (2.2 times) frequently requested for post-operative rescue drugs than those without a chest tube (1.1 times), showing a statistically significant difference (Fig. 4).

#### 3.3. Post-operative course

The post-operative courses are shown in Table 3. The mean duration of chest tube placement was 1.0 and 0 day in patients with and without a chest tube, respectively. Post-operative day 1 chest X ray revealed a slightly collapsed lung (apex of the lung exists in supraclavicular) in one patient without a chest tube, and post-operative day 2 chest X ray revealed a slightly collapsed lung in two patients with a chest tube. In all of these cases, the lung expanded spontaneously without any treatments. One patient with a chest tube had minor air leakage at post-operative day 1 but it spontaneously disappeared, and the chest tube was removed at post-operative day 2. One patient with a chest tube required thoracic drainage for pneumothorax at a day after removing the chest tube. There were minor air leaks, which disappeared the following day after performing a re-drainage. At 3 days after re-drainage, the chest tube was removed.

The mean length of post-operative hospital stay was 2.5 days in patients with a chest tube, which was significantly longer than that of patients without a chest tube (1.2 days). The average hospital costs from the day of surgery were 718,141 Yen and 687,162 Yen for the chest tube and without chest tube groups, respectively. These low costs might simply be a result of the short duration of hospital

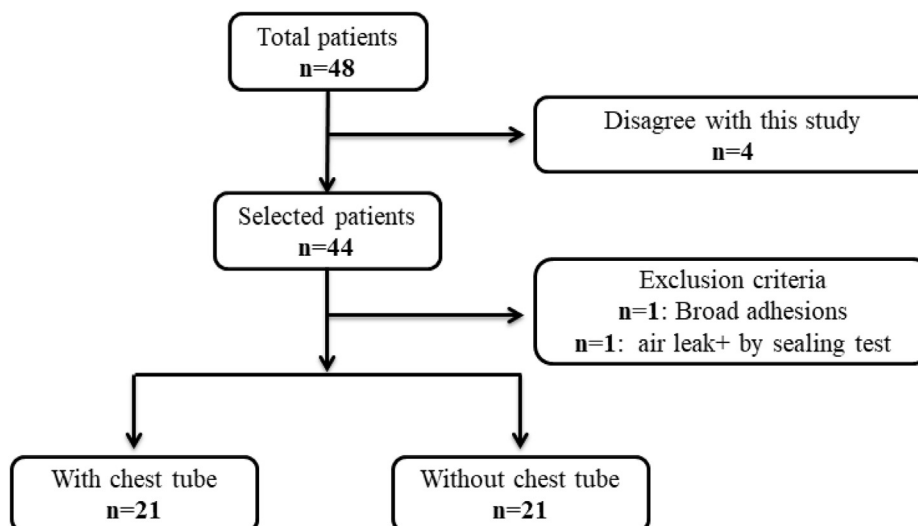
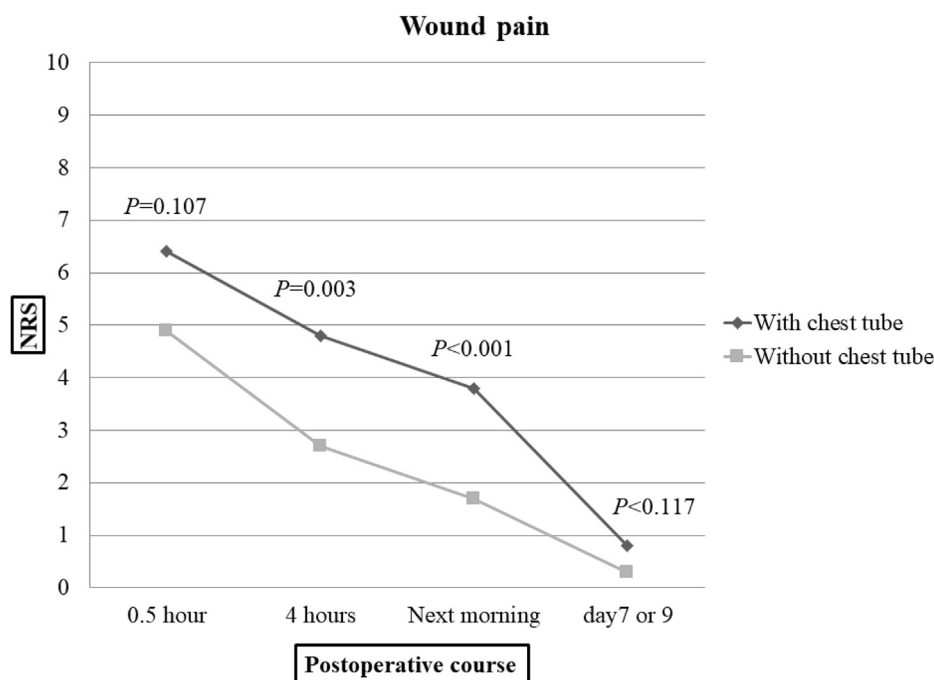


Fig. 1. Flowchart indicating patient selection and exclusion criteria.

**Table 2**  
Characteristics of 42 patients enrolled in this study. SD: standard deviation.

Variables	With chest tube (n = 21)	SD	Without chest tube (n = 21)	SD	P value
<b>Age (years)</b>	24.7 (17–37)	6.85	22.7 (15–37)	5.58	0.107
<b>Gender</b>		–		–	0.538
Male	18		20		
Female	3		1		
<b>Smoking history</b>		–		–	0.739
Yes	6		6		
No	15		15		
<b>Side of pneumothorax</b>		–		–	0.355
Right	9		12		
Left	12		9		
<b>Pleural adhesions</b>		–		–	0.707
Yes	5		4		
No	16		17		
<b>Number of stapler cartridges used</b>	2.0 (1–3)	0.78	1.9 (1–3)	0.79	0.575
<b>Operative time (min)</b>	40.8 (28–63)	10.7	36.6 (29–49)	4.92	0.009

**Fig. 2.** Numeric rating scale for post-operative wound pain.

stay. There were no patients readmitted within 72 h after discharge.

#### 4. Discussion

In the present study, we demonstrated the safety and advantages of post-operative management without chest tube placement, by comparing cases with and without chest tube placement.

The advances in equipment and surgical technique seem to have reduced the rate of post-operative events requiring chest drainage. However, removing the chest drainage tube on the next day of surgery for spontaneous pneumothorax seems to be the standard procedure. In the surgery for spontaneous pneumothorax, some reports have shown that post-operative prolonged air leakage rarely occurs (0.8%–1.8%) and post-operative bleeding does not happen.<sup>2,3</sup> Thus, the placement of drainage tube might have more disadvantages, such as post-operative pain or prolonged hospital stay, than advantages of early detection of air leakage or blood.

Previous studies have described the omission of chest drainage tubes after wedge resection,<sup>4–6</sup> segmentectomy, or lobectomy.<sup>7</sup> All

of these studies were retrospective, and some biases existed. For example, in these studies, every surgeon judged the indication for omission of chest drainage during the operation. The group with chest tube placement had more lung problems, such as chronic obstructive pulmonary disease than the group without chest tube placement. Given that their background characteristics were different, we could not precisely compare the safety and advantages of the two approaches. To avoid this problem, we conducted this prospective randomized controlled study.

Regarding safety, the cases of postoperative complications did not increase in patients without a chest tube. To avoid complications such as post-operative pneumothorax, we established the criteria in our surgical protocol; if these criteria were met, we removed the chest tube. However, one patient without a chest tube had a slightly collapsed lung a day after chest tube removal. Similarly, two patients with a chest tube had a slightly collapsed lung a day after chest tube removal and one patient had persistent minor leakage at post-operative day 1. We thought that this might have occurred due to the minor air leaks from the staple stump or

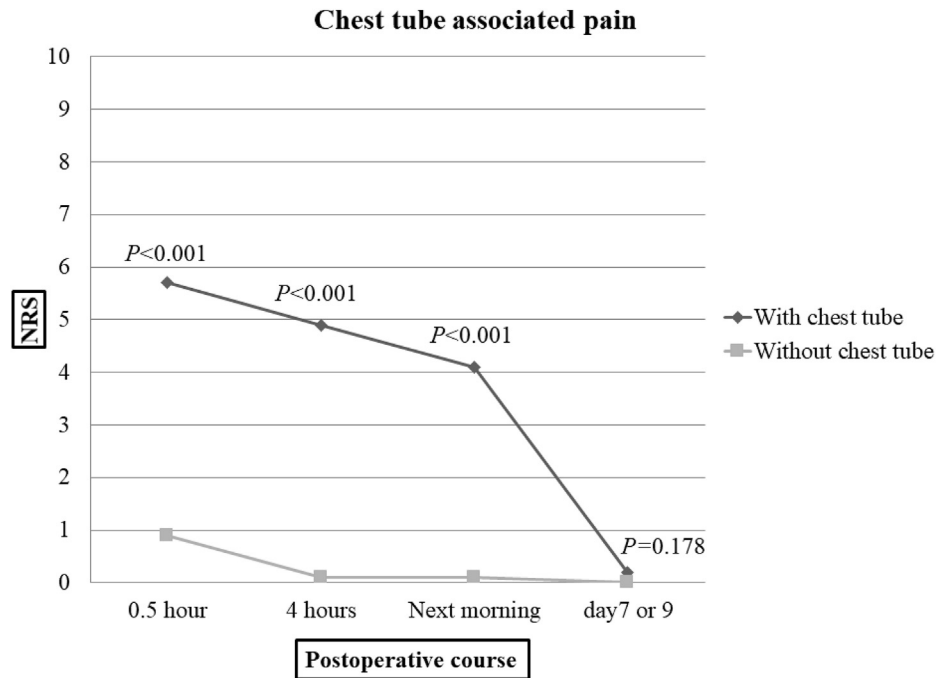


Fig. 3. Numeric rating scale for post-operative chest tube-associated pain.

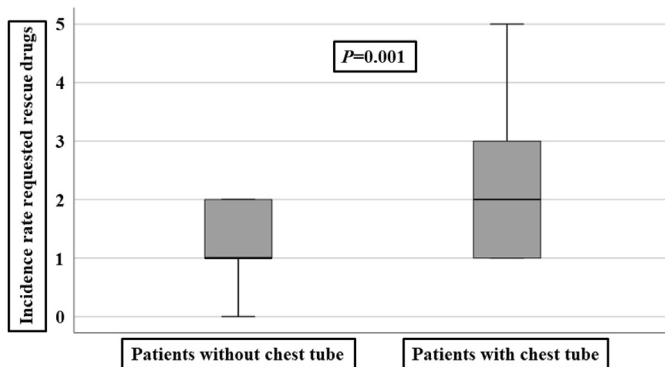


Fig. 4. The incidence rate of using rescue drugs for post-operative pain.

suctioned air into the thoracic cavity when removing the chest tube. Such minor air leakage or air suction may not be clinically important, because the air disappeared and the lung expanded spontaneously. One patient with a chest tube needed re-drainage for pneumothorax after removing the chest tube. The incident rate of pneumothorax after removing a chest tube or persistent air leakage after bullectomy was reported to be 1.0%–5.6%.<sup>2,3</sup> The incident rate in our study ranged within these previously reported rates. Our protocol defined the timing of removing the chest tube

should be shortly after extubation. Extubation also can entail a risk of air leakage because of bucking and severe coughing.<sup>2</sup> It is safer to assess the presence or absence of air leakage after the patients have fully recovered from anesthesia after extubation than completely omitting chest tube placement.

As for the advantages, patients without a chest tube had less pain and reduced length of post-operative hospital stay. We classified pains into wound and chest tube-associated pains. Because patients often described intrathoracic pain, which often disappears after chest tube removal. We defined this intrathoracic pain as chest tube-associated pain in this study. There were only two reports comparing post-operative pains between patients with and without chest tube placement. One report showed that the omission of chest tube placement was associated with a reduction of post-operative pain<sup>7</sup>, which was comparable to our study findings. The other report showed that there were no differences in the post-operative pain between the two groups,<sup>6</sup> which contradicted our results. There might be two reasons for this difference. First, the mean age of the patients in this study was much higher (53 or 55 years) than that of our patients (22 or 24 years). Elderly patients tend to experience lower post-operative pain intensity than younger patients<sup>1</sup>; thus, chest tube placement might not have much affected the post-operative pain. Second, the previous report might have assessed only wound pain. We showed that chest tube-associated pain intensity was much greater in patients with a chest

Table 3

Post-operative courses in patients with and without a chest tube. SD: standard deviation.

	With chest tube (n = 21)	SD	Without chest tube (n = 21)	SD	P value
<b>Duration of chest tube placement (days)</b>	1.0	1.05	0	0.00	<0.001
<b>Post-operative complications</b>					
Slightly collapsed lung	2	–	1	–	0.549
Persistent air leak ( $\geq 2$ day)	1	–	–	–	–
Pneumothorax requiring chest tube	1	–	0	–	0.311
<b>Post-operative hospital stay (days)</b>	2.5 (2–8)	1.33	1.2 (1–3)	0.63	<0.001
<b>Hospital costs since the day of surgery (Yen)</b>	718141	21389	687162	42675	0.006

tube than in those without a chest tube.

Wound pain was not significantly lower in patients without chest tube than those with chest tube at 0.5 h. However, the wound pain significantly decreased in patients without chest tube at 4 h and next morning. It might indicate that even in patients without chest tube, the wound pain at 0.5 h did not improve because temporally chest tube placement in the operation room might affect the wound pain. Despite frequent use of post-operative rescue drugs, patients with a chest tube had more pain than those without a chest tube. We thought that chest tube associated pain which might cause direct stimulation to pleura reacted poorly to rescue drugs. On the other hand, patients without chest tube reacted easily to rescue drugs, and had very good pain tolerance. Thus, for young patients, the chest tube should be removed shortly after the completion of surgery to reduce post-operative pain and facilitate early discharge.

The main limitation of this study is the small number of cases. However, in this study, we proposed the indication and protocol for post-operative management without drainage tube replacement in detail. In the future, we expect to perform studies in larger sample size, and we believe that our study is useful as a pilot study to demonstrate the feasibility of post-operative management without drainage tube placement for spontaneous pneumothorax. Second, the intensity of pain was difficult to quantify and could have been influenced by emotions as well as by educational and socioeconomic backgrounds. Third, our protocol of post-operative management needs one-day hospitalization to monitor conditions after removal of drainage tube. If our protocol permit group with chest tube to discharge at the day of tube removal, the length of post-operative hospital stay might not change between two groups.

In conclusion, chest drainage tube placement causes greater post-operative pain in patients who underwent bullectomy for spontaneous pneumothorax. Our patient selection and surgical

protocols may be feasible and contributed to post-operative pain control.

#### Declaration of competing interest

The authors have no conflicts of interest that exist with any companies/organizations whose products or services may be discussed in this article.

#### Acknowledgements

None.

#### References

1. Koh JC, Song Y, Kim SY, Park S, Ko SH, Han DW. Postoperative pain and patient-controlled epidural analgesia-related adverse effects in young and elderly patients: a retrospective analysis of 2,435 patients. *J Pain Res.* 2017;10:897–904.
2. Furuya T, Li T, Yanada M, Toda S. Early chest tube removal after surgery for primary spontaneous pneumothorax. *Gen Thorac Cardiovasc Surg.* 2019;67(9):794–799.
3. Wang BY, Chang YC, Wang KM, Lin CH, Lin SH, Lin WC. Thoracoscopic surgery via a single-incision subxiphoid approach is associated with less postoperative pain than single-incision transthoracic or three-incision transthoracic approaches for spontaneous pneumothorax. *J Thorac Dis.* 2016;8(suppl 3), 2072–1439.
4. Holbek BL, Hansen HJ, Kehlet H, Petersen RH. Thoracoscopic pulmonary wedge resection without post-operative chest drain: an observational study. *Gen Thorac Cardiovasc Surg.* 2016;64(10):612–617.
5. Nakashima S, Watanabe A, Mishina T, Obama T, Mawatari T, Higami T. Feasibility and safety of postoperative management without chest tube placement after thoracoscopic wedge resection of the lung. *Surg Today.* 2011;41(6):774–779.
6. Watanabe A, Watanabe T, Ohsawa H, et al. Avoiding chest tube placement after video-assisted thoracoscopic wedge resection of the lung. *Eur J Cardio Thorac Surg.* 2004;25(5):872–876.
7. Ueda K, Haruki T, Murakami J, Tanaka T, Hayashi M, Hamano K. No drain after thoracoscopic major lung resection for cancer helps preserve the physical function. *Ann Thorac Surg.* 2019;108(2):399–404.