

Histomorphological Effect of *Centella Asiatica* on Swiss Albino Mice Brain upon Ketamine Anesthetic Induced Memory Impairment

Mohammad Asaduzzaman¹ Md. Alauddin² Farha Matin Juliana³ Mohammad Johirul Islam⁴
Farzana Hafiz⁵ Aradhan Sarkar*⁶

1.Department of Biochemistry, Primeasia University, Banani, Dhaka, Bangladesh

2.Department of Biotechnology and Genetic Engineering, University of Development Alternative, Bangladesh

3.Department of Biochemistry and Molecular Biology, Jahangirnagar University, Savar, Dhaka, Bangladesh

4.Department of Biochemistry and Molecular Biology, Mawlana Bhashani Science and Technology University, Tangail, Bangladesh

5.Pathology and Laboratory Medicine, Square Hospital, Dhaka, Bangladesh

6.Department of Biotechnology and Genetic Engineering, Noakhali Science and Technology University, Noakhali, Bangladesh

Abstract

Introduction: Ketamine is a medication mainly used for starting and maintaining anesthesia. It induces a trance-like state while providing pain relief, sedation and memory loss. Ketamine causes morphological changes in the neuronal cells of growing rodent. *Centella asiatica* is used for memory enhancement in the ayurvedic system of medicine. It has been shown to be useful in improving learning and memory. *Centella asiatica* leaf extract treatment enhances neuronal dendritic arborization in hippocampus of growing rodent. **Materials and Methods:** Swiss albino mice were used for our experiment. Ketamine was administered subcutaneously and *Centella-asiatica* leaf extract was administered orally. Mice brain collected, grossed, processed and finally stained by Hematoxylin and Eosin (H&E) staining process for viewing cellular and tissue structure detail by pathologists. **Results:** Focal cellular damage was seen in CA2 and CA4 area of cornu ammonis (CA), expanded cytoplasmic eosinophilia was seen in the pyramidal cell layers (PY) of CA2, expanded cytoplasmic eosinophilia found with obliteration of neurofibrillary components (NFE), typical pyramidal cell (NPY) in the CA4, ordinary engineering of dentate granule layers (DG) and hardly any cells were found with diminished size in regards to granule layer cells (GC) in the brain hippocampus of the high ketamine prompted mice. In the mouse brain hippocampus for high ketamine-*Centella asiatica* summed up cell destruction found in the CA1 to CA4 of CA. Expanded cytoplasmic eosinophilia found in the pyramidal cell layers of CA2 than high dose ketamine group. The vast majority of the pyramidal cells were necrotic (PYN) with annihilation of neurofibrillary components (NFE) in the pyramidal cell layers of CA4.

Keywords: *Centella asiatica*, Ketamine and memory impairment.

DOI: 10.7176/ALST/82-02

Publication date: October 31st 2020

Introduction

Anesthetics activate memory-loss receptors in the brain, ensuring that patients don't remember traumatic events during surgery. The central nervous system has many parts. Hippocampus belongs to the limbic system and plays important role in the integration of information from short term memory to long term memory.[1] The dentate gyrus is part of a brain region known as the hippocampus (part of the hippocampal formation). The dentate gyrus is thought to contribute to the formation of new episodic memories,[2, 3] the spontaneous exploration of novel environments,[3] and other functions.[4] It is notable as being one of a select few brain structures currently known to have significant rates of adult neurogenesis in many species of mammals, from rodents to primates[5] (other sites include the subventricular zone of the striatum,[6] and cerebellum[7]). However, whether neurogenesis exists in the adult human dentate gyrus is currently a matter of debate.[8, 9]

Ketamine is a medication mainly used for starting and maintaining anesthesia.[10] It induces a trance-like state while providing pain relief, sedation, and memory loss.[11] Other uses include for chronic pain, sedation in intensive care, and depression.[12-15] Heart function, breathing, and airway reflexes generally remain functional.[11] Effects typically begin within five minutes when given by injection, and last up to about 25 minutes.[10] ketamine is used in medicine as an anesthetic;[16] however, due to the hallucinations it may cause, it is not typically used as a primary anesthetic, although it is the anesthetic of choice when reliable ventilation equipment is not available.

Ketamine is frequently used in severely injured people and appears to be safe in this group.[17] A 2011 clinical practice guideline supports the use of ketamine as a dissociative sedative in emergency medicine.[11] It is the drug of choice for people in traumatic shock who are at risk of hypotension.[18] Low blood pressure is harmful in people with severe head injury[19] and ketamine is least likely to cause low blood pressure, often even able to

prevent it.[20, 21]

The effect of ketamine on the respiratory and circulatory systems is different from that of other anesthetics. When used at anesthetic doses, it will usually stimulate rather than depress the circulatory system.[22] It is sometimes possible to perform ketamine anesthesia without protective measures to the airways.[23] Ketamine is considered relatively safe because protective airway reflexes are preserved.[24]

Ketamine is used as a bronchodilator in the treatment of severe asthma.[25] However, evidence of clinical benefit is limited.[25, 26]

Antagonism of the NMDA receptor is thought to be responsible for the anesthetic, amnesic, dissociative, and hallucinogenic effects of ketamine.[27] The mechanism(s) of action for the antidepressant effects of ketamine at lower doses have yet to be fully elucidated.[28] NMDA receptor antagonism results in analgesia by preventing central sensitization in dorsal horn neurons; in other words, ketamine's actions interfere with pain transmission in the spinal cord.[28] Inhibition of nitric oxide synthase lowers the production of nitric oxide— a neurotransmitter involved in pain perception, hence further contributing to analgesia.[29]

Ketamine produces measurable changes in peripheral organ systems, including the cardiovascular, gastrointestinal, and respiratory systems:[29]

- Cardiovascular: Ketamine stimulates the sympathetic nervous system, resulting in cardiovascular changes.
- Gastrointestinal: Ketamine produces nausea and vomiting in 15 to 25% of individuals at anesthetic doses.[29]
- Respiratory: Ketamine causes bronchodilation.[30] Several mechanisms have been hypothesized to explain this effect.[30]

Drowsiness, dissociation, and psychosis-like effects (e.g., hallucinations, delirium) are reported in patients treated with ketamine starting at circulating concentrations of around 50 to 200 ng/mL (210–841 nM), while analgesia begins at levels of approximately 100 to 200 ng/mL (421–841 nM).[31, 32] The typical intravenous antidepressant dosage of ketamine used to treat depression is low and results in maximal plasma concentrations of 70 to 200 ng/mL (294–841 nM).[33] Circulating concentrations of around 2,000 to 3,000 ng/mL (8,413–12,620 nM) are employed during anesthesia, and patients may start to awaken once levels of ketamine have decreased to about 500 to 1,000 ng/mL (2,103–4,207 nM).[31, 32] There is wide variation in the peak concentrations of ketamine that have been reported in association with anesthesia in the literature, with values ranging from 2,211–3,447 ng/mL (9,300–14,500 nM) to as high as 22,370 ng/mL (94,100 nM).[34, 35] Bioactive concentrations of ketamine are lower than total plasma levels due to plasma protein binding,[34] although plasma protein binding is relatively low with ketamine (approximately 12 to 47% protein-bound).[36] Concentrations of ketamine in the brain have been reported to be several-fold higher than in plasma.[35]

An increasing number of in vitro and in vivo studies suggest that anesthesia and surgery could be risk factors for later cognitive impairment in the young and aged brain. General anesthesia has been shown to impair spatial memory in rats and this performance is dependent on hippocampal function and postnatal hippocampal neurogenesis. Anesthetic induced alteration of one or more stages of postnatal hippocampal neurogenesis may in part explain this cognitive impairment following anesthesia.[37]

Centella asiatica is common herbaceous forest plant. It is used as vegetable and medicine. It is small size plant. Its leaves are green and flower is white and pinkish. It is indigenous to the Indian subcontinent.[38, 39] *Centella asiatica* used to treat various diseases.[40] It is used in headaches, nausea cold fever and drowsiness. Another important use of it is for memory enhancement which used in the ayurvedic system of medicine. It has been shown to be useful in improving learning and memory.[40] In addition the plant is also used in mentally retarded children to improve general mental ability and in people suffering from cognitive disorders.[41] The fresh leaf juice (extract) of *Centella asiatica* has been claimed to improved learning and memory in different clinical studies.[42]

Excessive stress causes neuronal degeneration. Stress like prolong and repeated use of anesthetic drug. Ketamine causes morphological changes in the neuronal cells of growing rodent.[43] On the other hand, *Centella asiatica* leaf extract treatment enhances neuronal dendritic arborization in hippocampus of growing rodent.[43] But the cytoprotective property of *Centella asiatica* on the morphology of the hippocampal neuron has not been reported.[44] In this study numbers of mice were selected to receive high dose ketamine to induce anesthesia which is considered as stress, repeatedly for seven days in one group. In other group of mice received high dose ketamine with extract of *Centella asiatica*. Our aim was to observe types of morphological changes occurs in neurons of mice's hippocampus after using high dose ketamine and high dose ketamine with high dose extract of *Centella asiatica*.

MATERIALS AND METHODS

Animal model

15 Swiss albino mice were collected from animal resource department of ICDDR,B, Mohakhali Dhaka-1212. The mice were stored in metallic cage (5mice / cage) and given corn and water. Nearly identical weight mice were randomly divided in the three groups. Group A became control group, groups B changed into for high dose of

ketamine and group C was for high dose ketamine with *Centella asiatica* extract. Mice are most typically used animal models for reading human disease for plenty proper reasons. Mice are biologically very just like human.

Preparation of extract powder of *Centella asiatica*

Green *Centella asiatica* sample was collected from Mohammadpur Town Hall Kacha Bazar Dhaka, Bangladesh and this was certified by National Herbarium, Mirpur-2, Dhaka, Bangladesh. The sample was cleaned and washed by water to remove dirty parts. Then the sample was dried under sunlight and converted to powder by mechanical blender and preserved in an air tight container at room temperature until extraction. 50gram dried powder was put into a glass beaker and added 250 ml methanol. Slow stirring was continued with a glass rod for one hour to mix up methanol and fine dried powder. The beaker was covered with aluminum foil and left for 48 hours. The mixture was filtered with thin cloth (white color) and the extract was taken to the water bath till dried extracts (crude drug) were obtained. The Temperature was always maintained at 40°C and finally the extract was collected by spatula in a marked glass vial. A total of 4gram dry powder extract was found and put into glass vial. The extract vial was kept in a refrigerator at 4°C temperature.

Oral preparation of *Centella asiatica* powder extract and dosage form

4gram extract powder was dissolved in 4ml 1% DMSO. Final concentration of *Centella asiatica* powder was 1µg/µl. This solution was administered orally. 2µl solution per gram body weight was administered for each mouse those were dedicated for *Centella asiatica*. Same dosage form of *Centella asiatica* was used for the mice those were subjected for combined action of *Centella asiatica* and ketamine.

Injectable preparation of Ketamine and dosage form

Ketalar injection (ketamine 50mg/ml) of Popular Pharmaceutical Limited, Bangladesh was used as general anesthetics. Ketamine is a noncompetitive N-methyl-D-aspartate receptor antagonist that blocks glutamate. It has a direct action on the cortex and limbic system. It produces a cataleptic-like state wherein the patient is withdrawn from the surrounding environment. 2µl ketamine injection per gram body weight was administered subcutaneously for each mouse those were dedicated for ketamine. Like *Centella asiatica* same dosage form of ketamine was used for the mice those were subjected for combined action of *Centella asiatica* and ketamine.

Mice brain collection

At fast the Swiss albino mice were slaughtered with a sharp knife. Then removed the upper skin from the head and removed the skull by forceps and separated the brain. Separated brains then dipped into 10% buffer formalin fixative and sent to the laboratory for grossing.

Brain grossing

Control group: Brain sample was received in 10% buffer formalin fixative container with identification number. Brain weight was 10gm and dimension was 1.5x1.2x0.6cm. Brain was sectioned into seven parts A1 to A7. At A3 hippocampus was identified.

High dose ketamine: Brain sample was received in 10% buffer formalin fixative container with identification number. Brain weight was 11gm and dimension was 1.5x1.4x0.6cm. Brain was sectioned into seven parts A1 to A7. At A3 hippocampus was identified.

Ketamine with extract: Brain sample received in 10% buffer formalin fixative container with identification number. Brain weight was 9gm and dimension was 1.3x1.0x0.6cm. Brain was sectioned into seven parts A1 to A7. At A3 hippocampus was identified.

Brain tissue processing

Brain tissue processing was accomplished by following a well known procedure written by Geoffrey Rolls for Leica Biosystems, Wetzlar, Germany.[55][56][57][58] (Source: <https://www.leicabiosystems.com/knowledge-pathway/an-introduction-to-specimen-processing/>)

Brain tissue staining

Hematoxylin and Eosin (H&E) staining process was used for viewing cellular and tissue structure detail by pathologists. Brain tissue staining was accomplished by following a well known protocol written by Cindy Sampias and Geoffrey Rolls for Leica Biosystems, Wetzlar, Germany. (Source: <https://www.leicabiosystems.com/knowledge-pathway/he-staining-overview-a-guide-to-best-practices/>)

Results

In our study we set three groups of Swiss albino mice of similar weight. One group was considered as control, one group was considered for high dose ketamine subcutaneous administration and last group was selected for high

dose ketamine subcutaneous administration with high dose *Centella asiatica* oral administration.

We found dimension change in the brain of the three mice groups. High dose ketamine with high dose *Centella asiatica* administered mice group found with reduced dimension, 1.3x1.0x0.6cm, then followed control group, 1.5x1.4x0.6cm, and high dose ketamine group, 1.5x1.2x0.6cm.

Starting at the dentate gyrus and working inward along the S-curve of the hippocampus means traversing a series of narrow zones. The first of these, the dentate gyrus (DG), is actually a separate structure, a tightly packed layer of small granule cells wrapped around the end of the hippocampus proper, forming a pointed wedge in some cross-sections, a semicircle in others. Next come a series of Cornu Ammonis (CA) areas: first CA4 (which underlies the dentate gyrus), then CA3, then a very small zone called CA2, then CA1. The CA areas are all filled with densely packed Pyramidal cells similar to those found in the neocortex. After CA1 comes an area called the subiculum. After this comes a pair of ill-defined areas called the presubiculum and parasubiculum, then a transition to the cortex proper (mostly the entorhinal area of the cortex). Most anatomists use the term "hippocampus proper" to refer to the four CA fields, and hippocampal formation to refer to the hippocampus proper plus dentate gyrus and subiculum.[59]

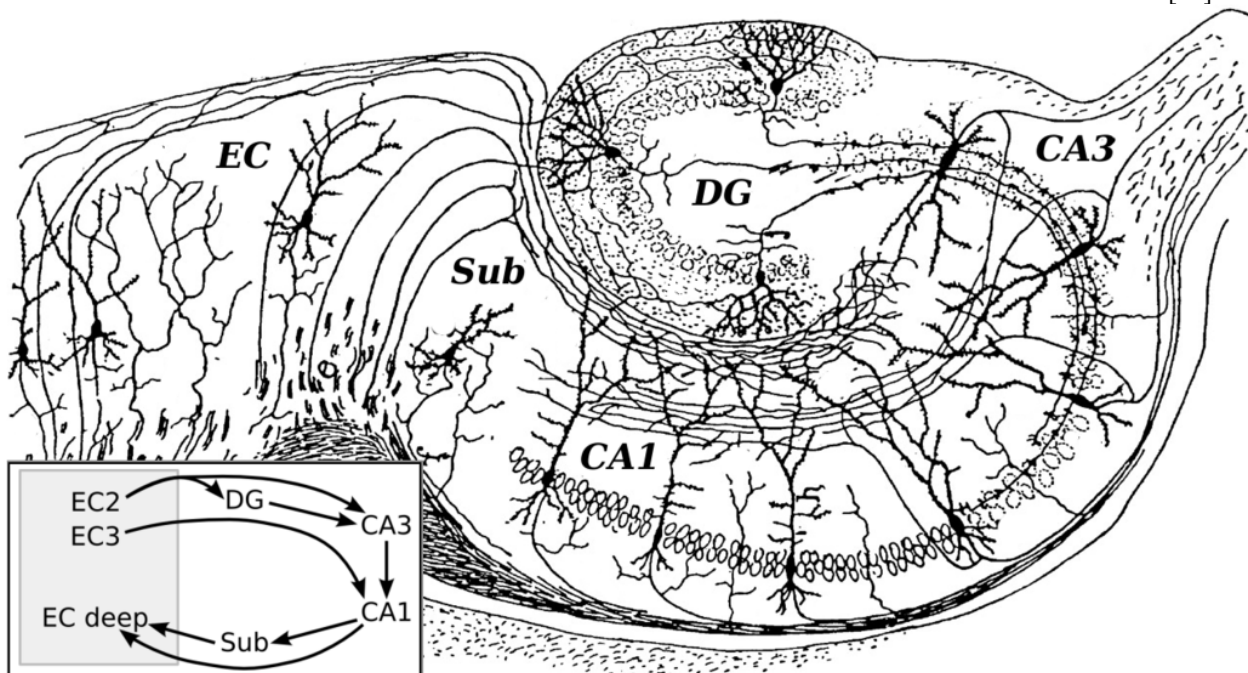


Figure-1: Basic circuit of the hippocampus, shown using a modified drawing by Ramon y Cajal. DG: dentate gyrus. Sub: subiculum. EC: entorhinal cortex

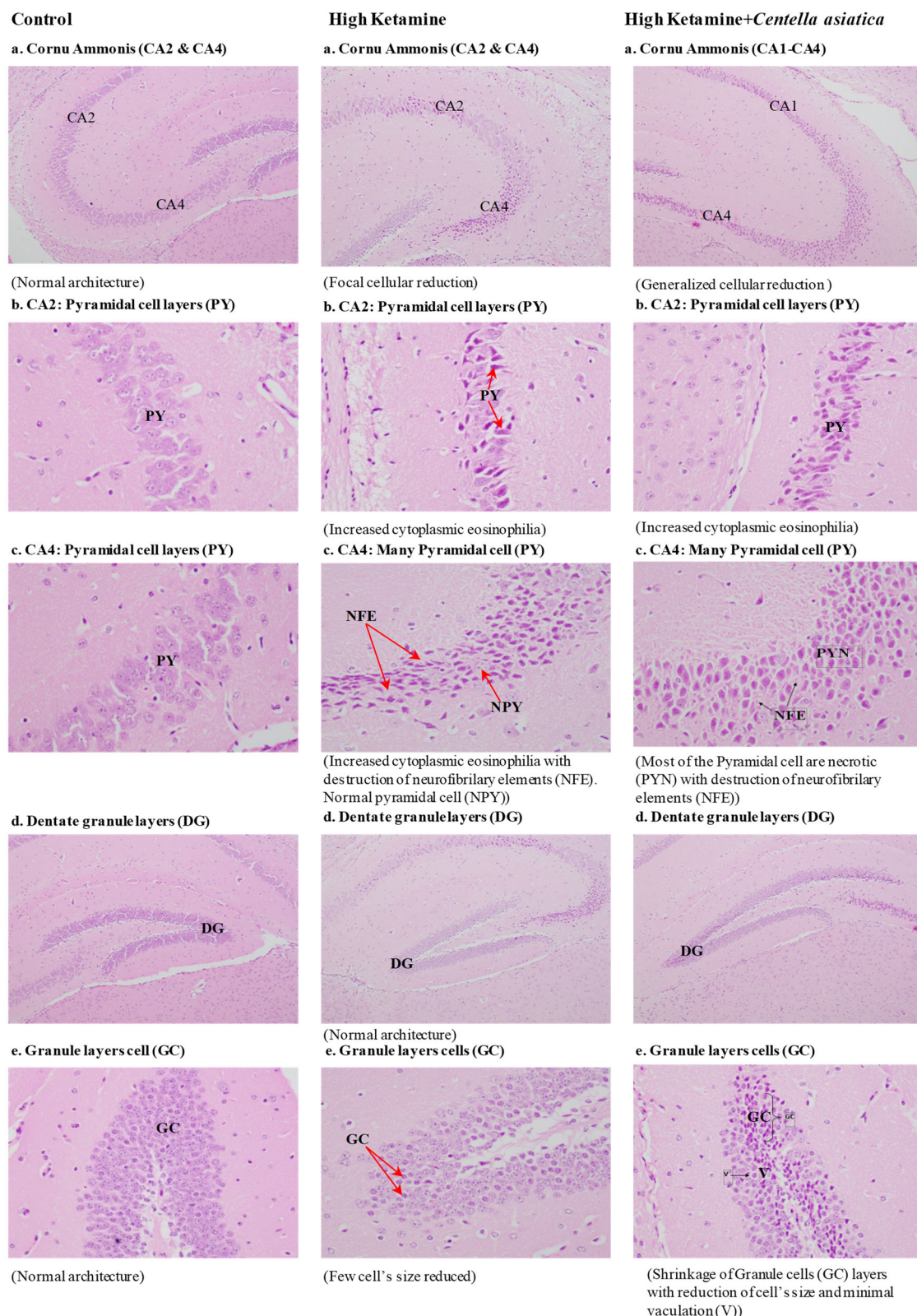


Figure 2-Effect of high dose ketamine and high dose ketamine plus high dose *Centella asiatica* on mice brain
 Figure-2 showed the morphological effect of high dose ketamine and high dose ketamine with *Centella asiatica* on dentate gyrus.

We observed focal cellular reduction in CA2 and CA4 region of cornu ammonis (CA), increased cytoplasmic eosinophilia observed in the pyramidal cell layers (PY) of CA2, increased cytoplasmic eosinophilia found with destruction of neurofibrillary elements (NFE), normal pyramidal cell (NPY) in the CA4, normal architecture of

dentate granule layers (DG) and few cells were found with reduced size regarding granule layer cells (GC) in the brain of the high ketamine induced mice.

For high ketamine-*Centella asiatica* mice group generalized cellular reduction found in the CA1 to CA4 region of cornu ammonius. Increased cytoplasmic eosinophilia found in the pyramidal cell layers of CA2 than high dose ketamine. Most of the pyramidal cells were necrotic (PYN) with destruction of neurofibrillary elements (NFE) in the pyramidal cell layers of CA4.

Discussion

As manufactured medications can prompt lung and kidney lethality, numerous clinicians and researchers have looked enthusiastically for different choices to treat their patients. Home grown plants which are normally wealthy in remedial worth, more eco-accommodating and have lesser symptoms have been consequently read for usage in therapeutic applications. This has brought *Centella asiatica*, which is known to have memory and subjective improvement, into logical examinations for nerve recovery and neurological capacities before helpful use.

Research on the neuroregenerative limit of *Centella asiatica* on the focal sensory system has been broadly directed, concentrating on synapses. Soumyanath et al. [45] uncovered the capacity of asiatic acid (AA) to advance the lengthening of neurites utilizing an in vitro test model. They additionally saw that this activity could be co-activated with the other dynamic mixes found in the herb that have synergistic impacts with AA. In parallel with this, Rao et al. [42] announced that crisp *Centella asiatica* leaf separate fundamentally expands the dendritic arborisation of hippocampal CA3 neurons in vivo. In perspective on *Centella asiatica* as a nerve tonic [46], it is accepted to effectsly affect the fringe sensory system as well. Nonetheless, further examinations are expected to bring it into proof, as the writing on such sensory system benefits is excessively constrained to date.

Since variation of extract constituents can lead to various complications, scientists from Thailand have recently established a standardized extract of *Centella asiatica* known as ECa 233 [47]. The extract was clearly demonstrated to have stimulatory effects on the elongation of neuroblastoma cell neurites at a maximum dose of 100 µg/mL [48]. In spite of dendritic arborisation, this particular herb also exhibits neuroprotective properties. Zhang and his colleagues [49] have recently disclosed that AA ameliorates the action of C2-ceramide in inducing neuronal cell death in a concentration-dependent manner.

Despite the fact that the fundamental mechanisms whereby the herb applies its belongings are ineffectively comprehended, the previously mentioned properties synchronize with the dominance of this herb to phosphorylate a few flagging pathways to intercede its capacities. In fact, the components associated with neurite advancement are very mind boggling, yet the MEK/ERK and PI3/Akt signaling pathways have increased noteworthy consideration [50]. A past report explained that AA in *Centella asiatica* evokes its neuroregenerative impact by means of the MAP kinase pathway [45]. In concurrence with this, Wanakhachornkrai et al. [48] additionally uncovered that ECa 233 is MEK/ERK-and PI3K/AKT-subordinate in advancing the extension of neurites.

Other than that, Omar et al. [51] as of late uncovered the guideline of the caspase-9 pathway by *Centella asiatica* in adjusting neuron cell endurance against apoptosis. In this investigation, l-buthionine-(S,R)- sulfoximine (BSO)- incited human neuron cell demise was treated with ethanolic concentrate of *Centella asiatica* in the scope of 5–500 µg/mL. They found that, at low concentrations, this extract can ensure neuron cells against oxidative pressure. This may point to the limit of this herb in restraining the caspase-9 pathway by blocking the creation of proapoptotic proteins, advancing antiapoptotic proteins and copying the last mentioned [43, 44]. Despite the fact that this mechanism is evidently centered around neuroprotective impacts against apoptosis, such a system could be a subset in the recovery and upgrade of nerve cell wounds. All the previously mentioned mechanisms cover each other in keeping up nerve cell development.

In the above discussion we found beneficiary role of *Centella asiatica* regarding neuroprotection, neuroregeneration, dendritic arborisation, antiapoptosis. We did not find any data regarding co-administration of *Centella asiatica* with ketamine or any other anesthetics. In our study we found no positive role of *Centella asiatica* with ketamine. In the ketamine induced brain we found increased cytoplasmic eosinophilia in the pyramidal cell layers of CA2. Most of the pyramidal cells were found necrotic (PYN) with destruction of neurofibrillary elements (NFE) in the pyramidal cell layers of CA4.

Conclusion

In the combined action of ketamine and *Centella asiatica*, *Centella asiatica* exerted no physiologically positive impact in the mice brain hippocampus. Hippocampus found with increased cytoplasmic eosinophilia, necrosis with decreased neurofibrillary elements (NFE) .

References

1. Torricco TJ, Abdijadid S: **Neuroanatomy, Limbic System**. In: *StatPearls [Internet]*. StatPearls Publishing; 2019.
2. Amaral DG, Scharfman HE, Lavenex P: **The dentate gyrus: fundamental neuroanatomical organization**

- (dentate gyrus for dummies). *Progress in brain research* 2007, **163**:3-790.
3. Saab BJ, Georgiou J, Nath A, Lee FJ, Wang M, Michalon A, Liu F, Mansuy IM, Roder JC: **NCS-1 in the dentate gyrus promotes exploration, synaptic plasticity, and rapid acquisition of spatial memory.** *Neuron* 2009, **63**(5):643-656.
 4. Scharfman HE: **The dentate gyrus: a comprehensive guide to structure, function, and clinical implications**, vol. 163: Elsevier; 2011.
 5. Cameron HA, McKay RD: **Adult neurogenesis produces a large pool of new granule cells in the dentate gyrus.** *Journal of Comparative Neurology* 2001, **435**(4):406-417.
 6. Ernst A, Alkass K, Bernard S, Salehpour M, Perl S, Tisdale J, Possnert G, Druid H, Frisén J: **Neurogenesis in the striatum of the adult human brain.** *Cell* 2014, **156**(5):1072-1083.
 7. Ponti G, Peretto P, Bonfanti L: **Genesis of neuronal and glial progenitors in the cerebellar cortex of peripuberal and adult rabbits.** *PLoS One* 2008, **3**(6):e2366.
 8. Sorrells SF, Paredes MF, Cebrian-Silla A, Sandoval K, Qi D, Kelley KW, James D, Mayer S, Chang J, Augustine KI: **Human hippocampal neurogenesis drops sharply in children to undetectable levels in adults.** *Nature* 2018, **555**(7696):377.
 9. Boldrini M, Fulmore CA, Tartt AN, Simeon LR, Pavlova I, Poposka V, Rosoklija GB, Stankov A, Arango V, Dworkin AJ: **Human hippocampal neurogenesis persists throughout aging.** *Cell stem cell* 2018, **22**(4):589-599. e585.
 10. Das B, Kumar US, Aditya AK, Mishra D: **Comparative administration of ketamine-dexmedetomidine & Ketamine: Propofol for sedation during upper gastrointestinal endoscopy in children.**
 11. Green SM, Roback MG, Kennedy RM, Krauss B: **Clinical practice guideline for emergency department ketamine dissociative sedation: 2011 update.** *Annals of emergency medicine* 2011, **57**(5):449-461.
 12. Zgaia AO, Irimie A, Sandesc D, Vlad C, Lisencu C, Rogobete A, Achimas-Cadariu P: **The role of ketamine in the treatment of chronic cancer pain.** *Chujul Medical* 2015, **88**(4):457.
 13. Zapantis A, Leung S: **Tolerance and withdrawal issues with sedation.** *Critical Care Nursing Clinics* 2005, **17**(3):211-223.
 14. Zhang K, Hashimoto K: **An update on ketamine and its two enantiomers as rapid-acting antidepressants.** *Expert review of neurotherapeutics* 2019, **19**(1):83-92.
 15. Kraus C, Rabl U, Vanicek T, Carlberg L, Popovic A, Spies M, Bartova L, Gryglewski G, Papageorgiou K, Lanzenberger R: **Administration of ketamine for unipolar and bipolar depression.** *International journal of psychiatry in clinical practice* 2017, **21**(1):2-12.
 16. Heshmati F, ZEYNALI M, NOUROUZINIA H, ABBASIVASH R, MAHOURI A: **Use of ketamine in severe status asthmaticus in intensive care unit.** 2003.
 17. Cohen L, Athaide V, Wickham ME, Doyle-Waters MM, Rose NG, Hohl CM: **The effect of ketamine on intracranial and cerebral perfusion pressure and health outcomes: a systematic review.** *Annals of emergency medicine* 2015, **65**(1):43-51. e42.
 18. Kurdi MS, Theerth KA, Deva RS: **Ketamine: current applications in anesthesia, pain, and critical care.** *Anesthesia, essays and researches* 2014, **8**(3):283.
 19. Manley G, Knudson MM, Morabito D, Damron S, Erickson V, Pitts L: **Hypotension, hypoxia, and head injury: frequency, duration, and consequences.** *Archives of Surgery* 2001, **136**(10):1118-1123.
 20. Hemmingsen C, Nielsen JK: **Intravenous ketamine for prevention of severe hypotension during spinal anaesthesia.** *Acta anaesthesiologica scandinavica* 1991, **35**(8):755-757.
 21. Wong DH, Jenkins LC: **The cardiovascular effects of ketamine in hypotensive states.** *Canadian Anaesthetists' Society Journal* 1975, **22**(3):339-348.
 22. Adams H: **S-(+)-Ketamin Kreislaufinteraktionen bei totaler intravenöser Anästhesie und Analgosedierung.** *Der Anaesthetist* 1997, **46**(12):1081-1087.
 23. Adriani J: **The Pharmacology of Anesthetic Drugs.** *Anesthesia & Analgesia* 1941, **20**(5):105.
 24. Wong JJ, Lee JH, Turner DA, Rehder KJ: **A review of the use of adjunctive therapies in severe acute asthma exacerbation in critically ill children.** *Expert review of respiratory medicine* 2014, **8**(4):423-441.
 25. Goyal S, Agrawal A: **Ketamine in status asthmaticus: a review.** *Indian journal of critical care medicine: peer-reviewed, official publication of Indian Society of Critical Care Medicine* 2013, **17**(3):154.
 26. Jat KR, Chawla D: **Ketamine for management of acute exacerbations of asthma in children.** *Cochrane Database of Systematic Reviews* 2012(11).
 27. Kohrs R, Durieux ME: **Ketamine: teaching an old drug new tricks.** *Anesthesia & Analgesia* 1998, **87**(5):1186-1193.
 28. Browne CA, Lucki I: **Antidepressant effects of ketamine: mechanisms underlying fast-acting novel antidepressants.** *Frontiers in pharmacology* 2013, **4**:161.
 29. Aroni F, Iacovidou N, Dontas I, Pourzitaki C, Xanthos T: **Pharmacological aspects and potential new clinical applications of ketamine: reevaluation of an old drug.** *The Journal of Clinical Pharmacology*

- 2009, **49**(8):957-964.
30. Xu J, Lei H: **Ketamine-An Update on Its Clinical Uses and Abuses**. *CNS neuroscience & therapeutics* 2014, **20**(12):1015-1020.
 31. Sleigh J, Harvey M, Voss L, Denny B: **Ketamine—More mechanisms of action than just NMDA blockade**. *Trends in anaesthesia and critical care* 2014, **4**(2-3):76-81.
 32. Schüttler J, Schwilden H: **Modern Anesthetics**. *Handbook of Experimental Pharmacology*: Springer; 2008.
 33. Sanacora G, Frye MA, McDonald W, Mathew SJ, Turner MS, Schatzberg AF, Summergrad P, Nemeroff CB: **A consensus statement on the use of ketamine in the treatment of mood disorders**. *JAMA psychiatry* 2017, **74**(4):399-405.
 34. Hirota K, Okawa H, Appadu BL, Grandy D, Devi LA, Lambert DG: **Stereoselective interaction of ketamine with recombinant mu, kappa, and delta opioid receptors expressed in Chinese hamster ovary cells**. *Anesthesiology* 1999, **90**(1):174-182.
 35. Kapur S, Seeman P: **NMDA receptor antagonists ketamine and PCP have direct effects on the dopamine D 2 and serotonin 5-HT 2 receptors—implications for models of schizophrenia**. *Molecular psychiatry* 2002, **7**(8):837.
 36. Yagiela JA, Dowd FJ, Johnson B, Mariotti A, Neidle EA: **Pharmacology and Therapeutics for Dentistry-E-Book**: Elsevier Health Sciences; 2010.
 37. Erasso DM, Camporesi EM, Mangar D, Saporta S: **Effects of isoflurane or propofol on postnatal hippocampal neurogenesis in young and aged rats**. *Brain research* 2013, **1530**:1-12.
 38. Bylka W, Znajdek-Awiżeń P, Studzińska-Sroka E, Brzezińska M: **Centella asiatica in cosmetology**. *Postepy Dermatol Alergol* 2013, **30**(1):46-49.
 39. Mukherjee S, Dugad S, Bhandare R, Pawar N, Jagtap S, Pawar PK, Kulkarni O: **Evaluation of comparative free-radical quenching potential of Brahmi (Bacopa monnieri) and Mandookparni (Centella asiatica)**. *Ayu* 2011, **32**(2):258.
 40. Gohil KJ, Patel JA, Gajjar AK: **Pharmacological review on Centella asiatica: a potential herbal cure-all**. *Indian journal of pharmaceutical sciences* 2010, **72**(5):546.
 41. Appa Rao M, Srinivasan K, Rao K: **The effect of Mandookaparni (Centella asiatica) on the general mental ability (Medhya) of mentally retarded children**. *J Res Indian Med* 1973, **8**(9):16.
 42. Mohandas Rao K, Muddanna Rao S, Gurumadhva Rao S: **Centella asiatica (L.) leaf extract treatment during the growth spurt period enhances hippocampal CA3 neuronal dendritic arborization in rats**. *Evidence-Based Complementary and Alternative Medicine* 2006, **3**(3):349-357.
 43. Cheung HM, Yew TW: **Effects of perinatal exposure to ketamine on the developing brain**. *Frontiers in neuroscience* 2019, **13**:138.
 44. Hemamalini RM: **Anti stress effect of Centella asiatica leaf extract on hippocampal CA3 neurons—a quantitative study**. *Int J Pharmacol Clin Sci* 2013, **2**:25-32.
 45. Soumyanath A, Zhong YP, Yu X, Bourdette D, Koop DR, Gold SA, Gold BG: **Centella asiatica accelerates nerve regeneration upon oral administration and contains multiple active fractions increasing neurite elongation in-vitro**. *Journal of Pharmacy and Pharmacology* 2005, **57**(9):1221-1229.
 46. Chivapat S, Chavalittumrong P, Tantisira MH: **Acute and sub-chronic toxicity studies of a standardized extract of Centella asiatica ECa 233**. *Thai J Pharm Sci* 2011, **35**:55-64.
 47. Wanasuntronwong A, Tantisira MH, Tantisira B, Watanabe H: **Anxiolytic effects of standardized extract of Centella asiatica (ECa 233) after chronic immobilization stress in mice**. *Journal of ethnopharmacology* 2012, **143**(2):579-585.
 48. Wanakhachornkrai O, Pongrakhananon V, Chunhacha P, Wanasuntronwong A, Vattanajun A, Tantisira B, Chanvorachote P, Tantisira MH: **Neuritogenic effect of standardized extract of Centella asiatica ECa233 on human neuroblastoma cells**. *BMC complementary and alternative medicine* 2013, **13**(1):204.
 49. Zhang X, Wu J, Dou Y, Xia B, Rong W, Rimbach G, Lou Y: **Asiatic acid protects primary neurons against C2-ceramide-induced apoptosis**. *European journal of pharmacology* 2012, **679**(1-3):51-59.
 50. Chao MV, Rajagopal R, Lee FS: **Neurotrophin signalling in health and disease**. *Clinical science* 2006, **110**(2):167-173.
 51. Omar NS, Zakaria ZAC, Mian TS, Ngah WZW, Mazlan M: **Centella asiatica modulates neuron cell survival by altering caspase-9 pathway**. *Journal of Medicinal Plants Research* 2011, **5**(11):2201-2209.