

Philadelphia College of Osteopathic Medicine

DigitalCommons@PCOM

---

Ophthalmology Resident Research

Graduate Medical Education Research

---

12-1-2020

## BOTOX injection to treat strabismus after infant botulism type B infection

Sarah G Bonaffini

*Philadelphia College of Osteopathic Medicine*

Victoria Coccozza

Jing Jin

Follow this and additional works at: [https://digitalcommons.pcom.edu/ophthalmology\\_residents](https://digitalcommons.pcom.edu/ophthalmology_residents)



Part of the [Ophthalmology Commons](#)


---

### Recommended Citation

Bonaffini, Sarah G; Coccozza, Victoria; and Jin, Jing, "BOTOX injection to treat strabismus after infant botulism type B infection" (2020). *Ophthalmology Resident Research*. 1.

[https://digitalcommons.pcom.edu/ophthalmology\\_residents/1](https://digitalcommons.pcom.edu/ophthalmology_residents/1)

This Article is brought to you for free and open access by the Graduate Medical Education Research at DigitalCommons@PCOM. It has been accepted for inclusion in Ophthalmology Resident Research by an authorized administrator of DigitalCommons@PCOM. For more information, please contact [library@pcom.edu](mailto:library@pcom.edu).



## BOTOX injection to treat strabismus after infant botulism type B infection<sup>☆</sup>

Sarah G. Bonaffini<sup>a</sup>, Victoria Coccozza<sup>a</sup>, Jing Jin<sup>b,\*</sup>

<sup>a</sup> Philadelphia College of Osteopathic Medicine, Philadelphia, PA, USA

<sup>b</sup> Nemours/Alfred I. duPont Hospital for Children, Wilmington, DE, USA

### ARTICLE INFO

#### Keywords:

Botulism  
Botulinum toxin  
Botulinum immunoglobulin  
Strabismus

### ABSTRACT

**Purpose:** The significance of botulinum toxin to ophthalmologists is twofold. Botulism, a medical emergency, frequently presents with ocular findings including blurred vision, diplopia, ptosis, and photophobia as a result of the neurotoxin produced by *Clostridium botulinum*. However, botulinum toxins also have therapeutic uses for medical conditions including strabismus. The safety and efficacy of Botulinum toxin A in patients with a history of botulism has not been reported.

**Observations:** We report a 9-week-old infant, diagnosed with type B toxin positive infant botulism treated with human botulism immune globulin, who developed a large angle exotropia. The infant was treated with intramuscular injections of botulinum toxin A to the extraocular muscles resulting in a favorable initial response but ultimately required strabismus surgery. Clinical manifestations and management of botulism are reviewed and botulinum toxin in the treatment of pediatric strabismus is discussed.

**Conclusions and importance:** This case demonstrates safe administration of onabotulinumtoxinA to an infant with a history of antitoxin-treated botulism, resulting in a transient improvement in control of infantile exotropia.

### Case report

A 9-week-old previously healthy, full-term white female presented with a two-week history of increased irritability, constipation, decreased feeding, intermittent vomiting, and lethargy. The parents reported that her cry became weak and shrill. The patient resided with her parents and 5-year-old sister in a neighborhood with extensive construction nearby. She was initially breast-fed, but transitioned to bottle feedings four weeks before presentation. The parents denied canned food and honey consumption, and neither parent worked in construction.

Neurologic examination revealed bilateral reactive but sluggish pupils constricting from 5 to 3 mm, full extraocular movements, and ptosis obscuring the corneal reflex. No ocular misalignment was noted. Her face was hypomimic, with minimal furrowing of the glabella and minimal creasing of the perioral region. Her suck was weak. She was diffusely hypotonic and had difficulty holding her head upright on pull-to-sit. Deep tendon reflexes were difficult to elicit. She was diagnosed with infant botulism, admitted to the intensive care unit, and received human botulism immune globulin (BIG-IV, California Department of Public Health, Richmond, CA).<sup>1</sup> A stool specimen tested positive for

*Clostridium botulinum* toxin type B. She was discharged from the hospital seven days after admission and continued to receive physical therapy at home. An ophthalmologic examination was performed at age 13 weeks, three weeks after discharge, during which the patient demonstrated central, steady, and maintained fixation with either eye. Additionally, no evidence of ocular misalignment was noted.

At 4 months of age, the child's pediatrician noticed a "left lazy eye." Repeat ophthalmologic examination showed a greater than 40 prism diopter intermittent alternating exotropia for both distance and near. Her cycloplegic refraction showed right eye:  $-2.00 + 2.00$  at 105° and left eye:  $-2.00 + 2.00$  at 75°. Her left eye showed poorer fixation and more frequent deviation than the right eye. She was treated with patching of the right eye 1–2 hours daily. At 6 months of age, both eyes fixated and followed well; however, an intermittent exotropia with poor control persisted. The alignment failed to improve after an additional two months of patching (Fig. 1A). After discussing treatment options, the family elected to proceed with botulinum toxin A injection (BTX-A). At 7 months of age, she received transconjunctival, intramuscular injections of onabotulinumtoxinA (Botox, Allergan Inc., Madison, NJ) without electromyographic guidance, with 2.5 units to the right lateral

<sup>☆</sup> Study was conducted at Nemours/Alfred I. duPont Hospital for Children.

\* Corresponding author. Department of Pediatric Ophthalmology, Nemours/Alfred I. duPont Hospital for Children, 1600 Rockland Rd., Wilmington, DE 19803, USA.

E-mail address: [jing.jin@nemours.org](mailto:jing.jin@nemours.org) (J. Jin).

<https://doi.org/10.1016/j.ajoc.2020.100895>

Received 7 January 2020; Received in revised form 22 April 2020; Accepted 16 August 2020

Available online 28 August 2020

2451-9936/© 2020 The Authors.

Published by Elsevier Inc.

This is an open access article under the CC BY-NC-ND license

(<http://creativecommons.org/licenses/by-nc-nd/4.0/>).

rectus muscle and 5 units to the left lateral rectus muscle while under general anesthesia.

One week following the procedure, she displayed a flick exotropia in the primary position (Fig. 1B). Three months after the initial injection, alignment was adequate under binocular viewing (Fig. 1C); however, with cross cover testing she demonstrated a poorly-controlled exophoria of 30 prism diopters. The decision was made to again proceed with intramuscular injections of onabotulinumtoxinA. At 1 year of age, the patient underwent transconjunctival, intramuscular injections of 10 units onabotulinumtoxinA to the left lateral rectus muscle without electromyographic guidance. Her exotropia decreased to 20 prism diopters in the first month following injection, and subsequently returned to 40 prism diopters three months later. At 16 months of age, she underwent bilateral lateral rectus muscle recession of 10 mm. Seven weeks postoperatively, she displayed a 15 prism diopter intermittent exotropia by cross cover testing.

## Discussion

*Clostridium botulinum*, a gram-positive obligate anaerobic rod commonly found in the soil, produces heat-resistant endospores and is able to survive under adverse conditions. The bacterium produces a neurotoxic protein, botulinum toxin, during sporulation in an anaerobic environment. Patients may contract botulism when *C. botulinum* spores enter a wound, grow in intestines, or the toxin may also enter the body through contaminated food or injection. There have also been reported cases in which iatrogenic botulism has occurred.<sup>2</sup> Infant botulism or

intestinal toxemia botulism is the most common form of human botulism in the United States.<sup>3</sup>

A total of 182 confirmed cases were reported to the CDC in 2017.<sup>4</sup> Among these, 141 cases (77%) were infant botulism from 26 states and the District of Columbia, with California reporting 48 cases (34%). The median age of patients was 4 months (range: 0–12 months) and 72 (51%) were girls. There are four distinct phenotypic *C. botulinum* groups (I–IV), producing seven serotypes (A–G) of botulinum toxin.<sup>5</sup> The predominant toxin types identified in infant botulism were B (n = 88, 62%) and A (n = 52, 37%).<sup>4</sup> Most cases of infant botulism are thought to be caused by acquiring the spores from the natural environment. Patients often live near a construction site or an area of soil disturbance.<sup>4</sup>

Botulinum toxin selectively blocks neurotransmitter release by preventing fusion of vesicles containing acetylcholine with the presynaptic membrane. The upper cranial nerves are affected first, resulting in ocular signs due to intraocular and extraocular ophthalmoplegias. Later, damage to the lower cranial nerves leads to bulbar signs: paralysis of the lips, tongue, pharynx, larynx, and facial muscles. Progression over the next 1–3 days due to involvement of motor neurons to the somatic muscles results in loss of head control, hypotonia, and constipation. Death can result from respiratory failure or as a consequence of extended paralysis. Recovery often takes weeks to months.<sup>6–8</sup>

Ocular findings in botulism are limited in the ophthalmologic literature due to ophthalmologists not usually being involved in evaluating presenting botulism cases. “Blurred vision” is reported in almost every adult patient. Ptosis followed by an abnormal pupillary reaction to light, in addition to mydriasis, dominate the most common ophthalmologic

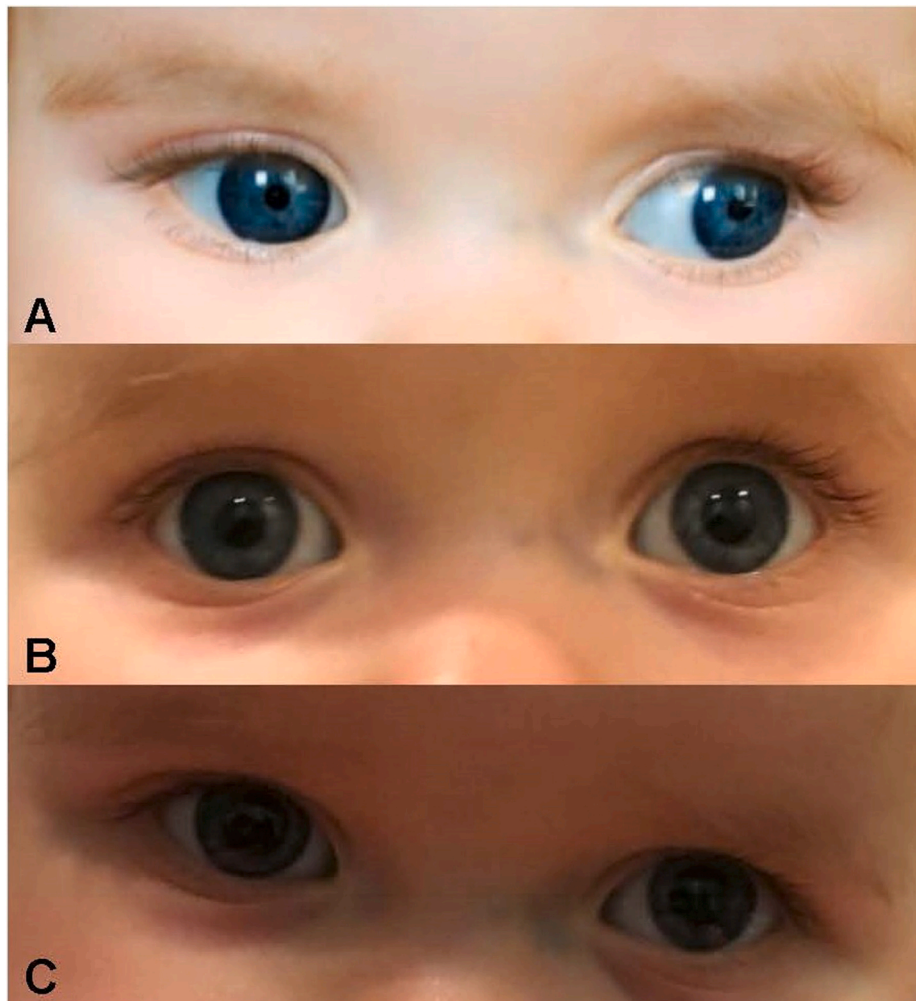


Fig. 1. Ocular alignment before (A) and after botulinum toxin A injection: (B) 1 week after and (C) 3 months after.

abnormalities in infant botulism.<sup>9,10</sup> In a report on six-month or longer follow-up, the ocular and bulbar symptoms were no longer a major complaint and likely resolved.<sup>11</sup>

The purpose of treatment for botulism is meticulous supportive care with attention to breathing through respiratory support and monitored feeding, in addition to prompt administration of human antitoxin in order to neutralize the circulating toxin. Antitoxins provide acquired passive immunity by neutralizing free toxin before it binds to the receptor on the presynaptic membrane, thus, early administration is critical. Two types of antitoxin are available: 1) heptavalent botulism antitoxin is derived from equine IgG that can neutralize toxins A through G; 2) BIG-IV contains IgG derived from immunized adult donors who contributed to the plasma pool specific for toxins A and B.<sup>3,12–14</sup> People may also gain acquired active immunity to botulinum toxin following infection.

The neuromuscular junction blockade of botulinum toxins provides therapeutic uses. Two toxin preparations are commercially available in the United States: type-A (onabotulinumtoxinA [Botox®], abobotulinumtoxinA [Dysport®], and incobotulinumtoxinA [XEOMIN®]) and type-B (rimabotulinumtoxinB [Myobloc®]). Currently, the Food and Drug Administration approves both toxins for cervical dystonia; toxin A is also approved for strabismus, blepharospasm, hemifacial spasm, and glabellar wrinkles.<sup>15</sup> BTX-A injection has been a treatment option for strabismus for decades.<sup>16</sup> In comparison to incisional strabismus surgery, BTX-A treatment is less invasive and offers easier postprocedural recovery. Adults may receive injections in outpatient clinics. For children, BTX-A treatment has the advantages of less general anesthesia time, reduced overcorrections, muscle preservation, and no post procedure topical medication. For certain types of esotropia, BTX-A injection has reported success rates comparable to extraocular muscle surgeries. The effect is less predictable for exotropia correction.<sup>17</sup>

To our knowledge, there are no reported cases of infantile exotropia developing two months following recovery from infant botulism, as well as a lack of information on BTX-A use in a patient with a history of botulism and antitoxin treatment. Our patient had no adverse reactions to onabotulinumtoxinA. The first injection was performed five months after BIG-IV treatment and resulted in a greater than 30 prism diopter exotropia angle reduction and improved alignment control shortly following the injection. This suggests sufficient half-life elimination or decay of acquired passive immunity. The half-life of infused BIG-IV is approximately 28 days.<sup>3</sup> Given this half-life, we calculate that at the time of onabotulinumtoxinA injection, more than five half-lives had passed and the residual antitoxin in our patient would have been less than 3% of the administered dose. Additionally, our patient had *C. botulinum* type B illness, and her acquired active immunity may have produced antitoxin B antibodies with no effect on toxin A as anti-type B antibodies do not cross-neutralize toxin type A. The onabotulinumtoxinA injections might have been ineffective after toxin A, producing *C. botulinum* infection. Although onabotulinumtoxinA showed only short-term effect in this case of exotropia, the injections postponed the surgical procedure until after the patient's first birthday. In conclusion, onabotulinumtoxinA is a viable treatment option for infantile exotropia in a patient with a history of infant botulism type B treated with human antitoxin.

#### Patient consent

The patient's legal guardian verbally consented to publication of the

case.

#### Funding

No funding or grant support.

#### Authorship

All authors attest that they meet the current ICMJE criteria for authorship.

#### Declaration of competing interest

None.

#### Acknowledgments

The authors thank Jessica M. Khouri, MD and Alan B. Scott, MD for providing information on infant botulism and offering valuable opinions on earlier drafts of this manuscript.

#### References

1. Infant Botulism Treatment and Prevention Program. *Division of Communicable Disease Control*. California Department of Public Health; 2015. Package Insert for BabyBIG®.
2. Rashid EAMA, El-Mahdy NM, Kharoub HS, Gouda AS, ElNabarawy NA, Megarbane B. Iatrogenic botulism outbreak in Egypt due to a counterfeit botulinum toxin A preparation - a descriptive series of patient features and outcome. *Basic Clin Pharmacol Toxicol*. 2018;123(5):622–627.
3. Arnon SS, Schechter R, Maslanka SE, Jewell NP, Hatheway CL. Human botulism immune globulin for the treatment of infant botulism. *N Engl J Med*. 2006;354(5):462–471.
4. Centers for Disease Control and Prevention (CDC). National botulism surveillance summary 2017. Available at: <http://www.cdc.gov/botulism/surveillance.html>. Accessed June 6, 2019.
5. Dong M, Stenmark P. The structure and classification of botulinum toxins. *Handb Exp Pharmacol*. 2019 Dec 3. [https://doi.org/10.1007/164\\_2019\\_342](https://doi.org/10.1007/164_2019_342) (Epub ahead of print).
6. Terranova WJ, Breman G, Locey RP, Speck S. Botulism type B: epidemiologic aspects of an extensive outbreak. *Am J Epidemiol*. 1978;108(2):150–156.
7. Schreiner MS, Field E, Ruddy R. Infant botulism: a review of 12 years' experience at the Children's Hospital of Philadelphia. *Pediatrics*. 1991;87(2):159–165.
8. Caya JG. Clostridium botulinum and the ophthalmologist: a review of botulism, including biological warfare ramifications of botulinum toxin. *Surv Ophthalmol*. 2001;46(1):25–34.
9. Terranova WJ, Palumbo N, Breman JG. Ocular findings in botulism type B. *J Am Med Assoc*. 1979;241(5):475–477.
10. Penas SC, Faria OM, Serrão R, Capão-Filipe JA, Mota-Miranda A, Falcão-Reis F. Ophthalmic manifestations in 18 patients with botulism diagnosed in Porto, Portugal between 1998 and 2003. *J Neuro Ophthalmol*. 2005;25(4):262–267.
11. Gottlieb SL, Kretsinger K, Tarkhashvili N, et al. Long-term outcomes of 217 botulism cases in the Republic of Georgia. *Clin Infect Dis*. 2007;45(2):174–180.
12. Vanella de Cuetos EE, Fernandez RA, Bianco MI, et al. Equine botulinum antitoxin for the treatment of infant botulism. *Clin Vaccine Immunol*. 2011;18(11):1845–1849.
13. Rosow LK, Strober JB. Infant botulism: review and clinical update. *Pediatr Neurol*. 2015;52(5):487–492.
14. Payne JR, Khouri JM, Jewell NP, Arnon SS. Efficacy of human botulism immune globulin for the treatment of infant botulism: the first 12 years post licensure. *J Pediatr*. 2018;193:172–177.
15. Lew MF. Review of the FDA-approved uses of botulinum toxins, including data suggesting efficacy in pain reduction. *Clin J Pain*. 2002;18(6 Suppl):S142–S146.
16. Scott AB. Botulinum toxin injection into extraocular muscles as an alternative to strabismus surgery. *Ophthalmology*. 1980;87(10):1044–1049.
17. Mahan M, Engel JM. The resurgence of botulinum toxin injection for strabismus in children. *Curr Opin Ophthalmol*. 2017;28(5):460–464.