

Malignant Hypertension: Damaging Disease of the Eye and Beyond – A Case Report

Emily R. Carr, OD, FAAO
Wilmington VA Medical
Center

Abstract

Case review follows a 49-year-old patient with malignant hypertension with retinopathy and resultant visual decline.

CASE REPORT

Severely uncontrolled hypertension manifested as malignant hypertensive retinopathy. The patient presented with substantial retinal and visual changes and was monitored over 6 months. While the patient experienced marked improvement in visual acuity, significant retinal damage occurred and the patient experienced persistent qualitative vision and visual field loss.

DISCUSSION

Observed fundus changes are consistent with advanced risk for morbidity and mortality associated with hypertension. Management of systemic disease is a critical step in reversing retinal manifestations and minimizing the risk for permanent vision loss. The criticality of systemic treatment also applies to lowered risk for systemic vascular events that may compromise quality of life. This case demonstrates that improvement in Snellen acuity does not always parallel functional visual improvement. Eye care providers managing these cases should consider both systemic risks and visual outcome.

KEY WORDS: Malignant Hypertension, Visual Field Loss, Hypertensive Retinopathy

INTRODUCTION:

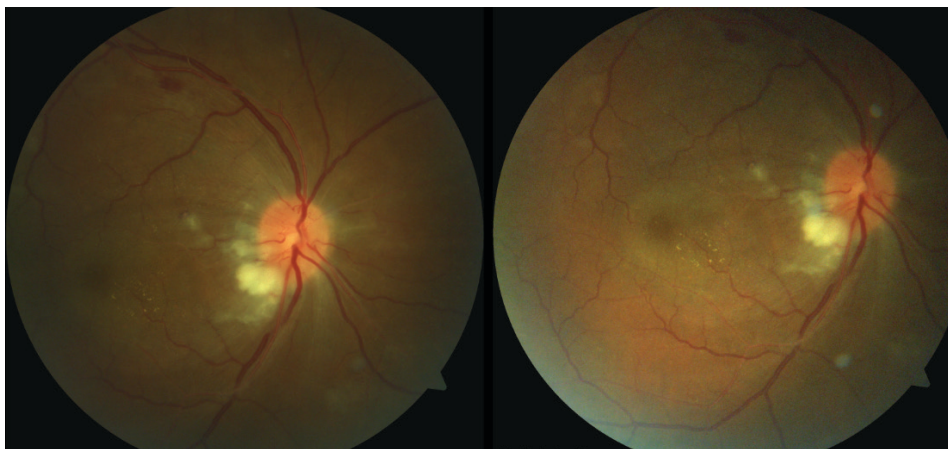
In 2017, the American Heart Association re-classified the definition of hypertension, thereby lowering the threshold to $\geq 130/\geq 80$ and increasing the global incidence of hypertension to roughly 1.8 billion adults.¹ Hypertension is the underlying cause of nearly half of stroke (51%) and heart disease (45%) related deaths.² Considering its prevalence, it is important that eye care providers remain mindful of the potential life threatening systemic implications indicated by ocular manifestations of hypertension. Hypertension is a precipitating factor in a multitude of acute and chronic fundus changes, as well as vascular occlusions and ischemic optic neuropathies. Malignant hypertension is classified by a significant elevation in systemic blood pressure accompanied by specific retinal findings including retinal hemorrhages, exudation from retinal vessels and/or micro-infarcts or cotton-wool spots (CWS), and potentially, optic nerve edema.³ Although less common than benign hypertension, malignant hypertension can cause severe impacts on visual and systemic health. This case highlights the fundus changes, visual outcomes, and systemic manifestations that accompany malignant hypertensive retinopathy.

CASE REPORT:

A 49-year-old African American male presented as an inpatient on consult for examination based on his complaint of new onset visual loss. The patient reported visual changes after admission to the hospital the previous day for hypertensive urgency with a blood pressure of 226/154. Systemic history was remarkable for hypertension complicated by cocaine abuse. Upon presentation to the eye clinic the patient continued to have severely elevated blood pressure measuring 197/109 with multiple interventions, including an oral beta-blocker, diuretic, vasodilator, and calcium channel blocker. During the first attempt at an ocular examination, the patient was unresponsive to subjective testing and refused to speak.

The patient returned three days later and agreed to cooperate with the ocular exam. He reported that his vision had been poor since he was first hospitalized for hypertensive urgency and severe hypokalemia 3 months prior at a neighboring hospital. Blood pressure remained elevated at 197/110. Visual acuity assessment was 20/40 in the right eye, 20/80 in the left eye. Posterior segment fundus examination revealed reduced arterial/venous caliper ratio (A/V ratio) with multiple prominent superficial flame shaped retinal hemorrhages and micro-infarcts of retinal nerve fiber layer (RNFL) in both eyes. Additionally, significant retinal exudates in and around the macula (in the form of a hypertensive macular star in the left eye) with associated retinal edema, and compounding optic nerve head edema in both eyes was noted (Figures 1A, 1B, 1C, and 1D). Macular and optic nerve head edema were confirmed with Optical Coherence Tomography (OCT) testing (Figures 1E and 1F). These findings supported the diagnosis of malignant hypertension. The patient remained in the hospital for another week, during which time it was determined that he had suffered from an acute ischemic stroke of the fronto-temporal lobe based on magnetic resonance imaging (MRI) studies.

Figure 1A and 1B: optic nerve and macula fundus photography of right eye at initial evaluation demonstrating CWS, flame hemorrhage, retinal exudation, and optic nerve head edema.



Figures 1C and 1D: optic nerve and macula fundus photography of left eye at initial evaluation demonstrating CWS, flame hemorrhage, retinal exudation, and optic nerve head edema.

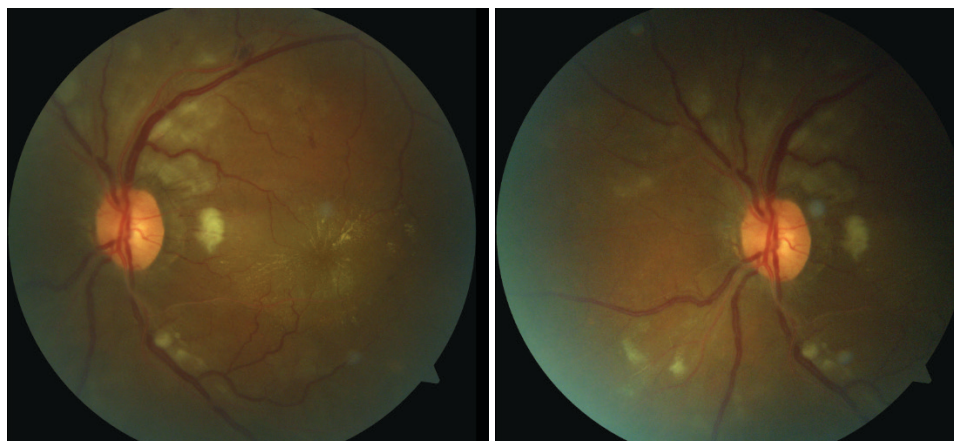
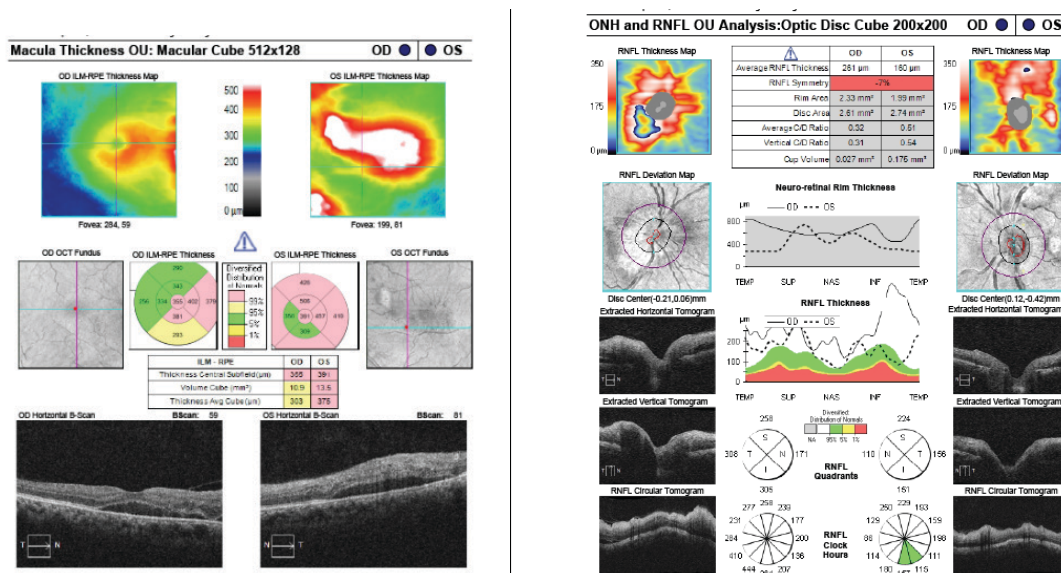
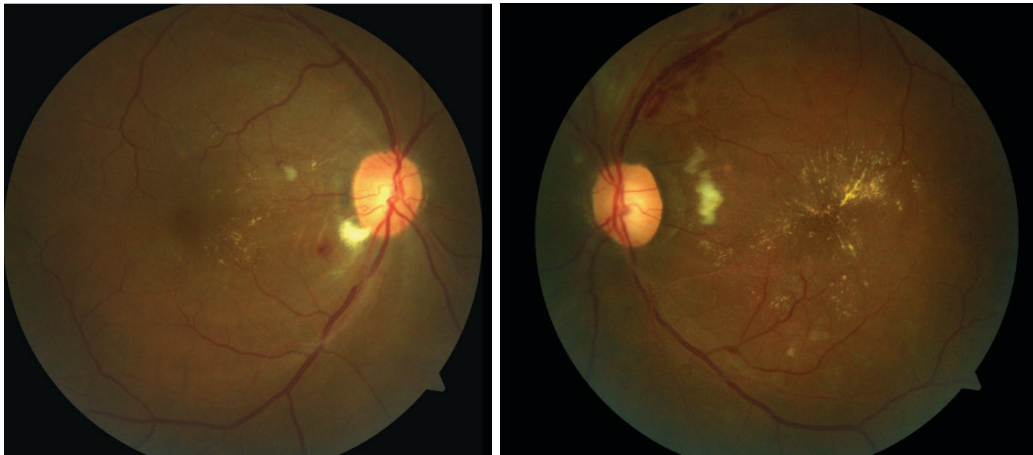


Figure 1E and 1F: Figure 1E, Macula OCT of right and left eye, Figure 1F Optic Nerve OCT of right and left eye, demonstrating macular and optic nerve head edema bilaterally. The presence of central macular edema, left eye greater than the right, accounts for the significantly reduced visual acuity in both eyes.



At 1 month follow up, the patient complained that his vision seemed dim and that he was experiencing difficulty reading. Blood pressure was measured at 144/85 by hospital staff. Best corrected visual acuity (BCVA) was documented at 20/40 right eye and 20/60+2 left eye with no evidence of afferent pupillary defect, peripheral visual evaluation was not performed at this visit. Fundus examination showed persistent micro-infarcts with flame shaped hemorrhages (Figures 2A and 2B). As resolution of some acute hypertensive fundus changes started to occur, chronic hypertensive changes were becoming more evident. These changes included significant narrowing of the retinal arterioles and venous dilation, as well as vascular sheathing, peripapillary intraretinal microvascular abnormalities (IRMA), and RNFL defects extending along superior and inferior arcades in both eyes. Clinical appearance of optic nerve head edema resolved and mild pallor was noted of the left optic nerve.

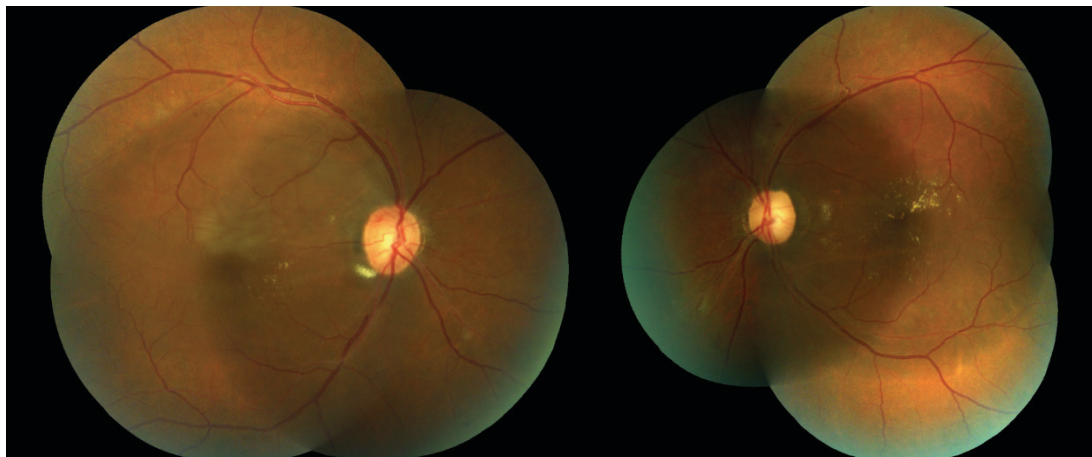
Figures 2A and 2B: demonstrating microinfarcts, hemorrhaging, and retinal exudate bilaterally at 1 month post initial presentation. Also, clearly visible are chronic hypertensive changes including reduced A/V ratio, crossing changes, arteriolar narrowing, vessel sclerosis, and visible RNFL defects caused by previous retinal microinfarcts.



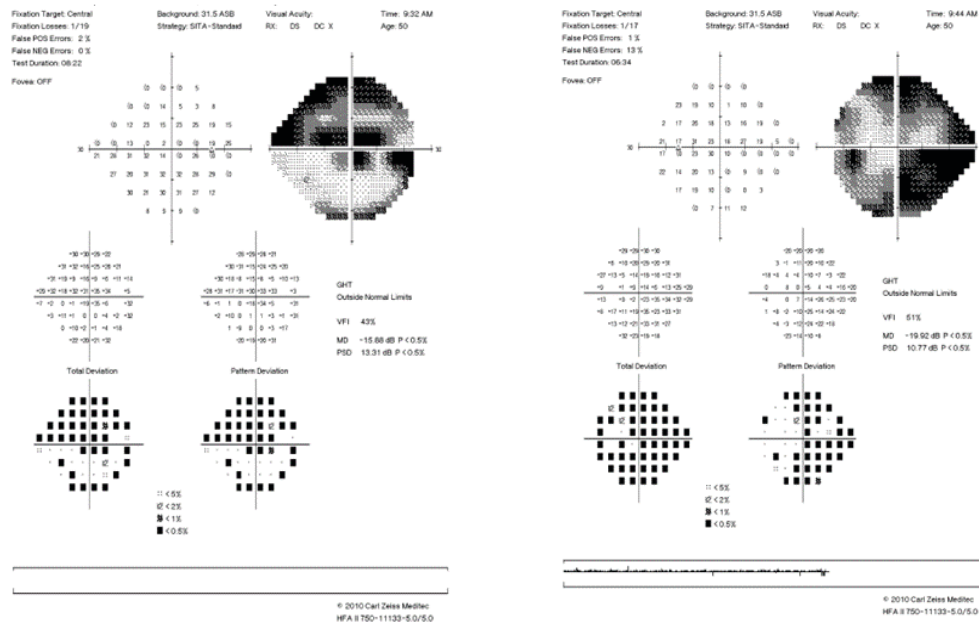
3 months following initial presentation, the patient reported noticing that his “side vision” seemed to be missing in both eyes. BCVA improved to 20/20- in the right eye and 20/25 in the left eye. Fundus findings showed continued improvement in acute hypertensive appearance (Figures 3A and 3B). Residual macular exudate remained bilaterally without evidence of retinal or optic nerve head edema on clinical exam. Threshold Humphrey visual field testing preformed at this visit revealed a superior arcuate/hemispheric defect in the right eye and superior and inferior arcuate defects in the left eye (Figures 3C and 3D).

The patient returned at 4 month follow up with stable Snellen acuity bilaterally. At this time, functional visual field loss was reflected by peripheral loss on confrontation visual field testing in both eyes. Fundus examination showed stable, chronic hypertensive retinopathy with improving but persistent posterior pole exudate bilaterally (Figure 4A and 4B). OCT showed generalized, diffuse ischemic atrophy of the macula in both eyes and diffuse RNFL loss, greatest inferiorly in the right eye and superiorly in the left which correspond appropriately to visual field loss noted on Humphrey visual field testing (Figure 4C and 4D). The patient was referred to low vision services and visual rehabilitation program due to his functional visual loss despite Snellen acuity recovery.

Figures 3A and 3B: Right and Left fundus imaging at 3 months post initial presentation showing improvement of acute hypertensive changes with residual exudate and evidence of chronic hypertensive retinopathy including reduced A/V ratio with arteriolar narrowing, vessel sclerosis, and visible RNFL defects.



Figures 3C and 3D: Right and Left (respectively) Humphrey visual field results demonstrating superior arcuate/hemispheric defect in the right eye and inferior and superior arcuate defects, densest inferiorly, in the left eye.



Figures 4A and 4B: Right and Left fundus imaging at 4 months post initial presentation showing resolution of the majority of acute hypertensive retinopathy and some improvement in residual exudate bilaterally. Persistent chronic retinopathy is visible in both eyes in the form of vessel sclerosis, arteriole attenuation, and RNFL defects.

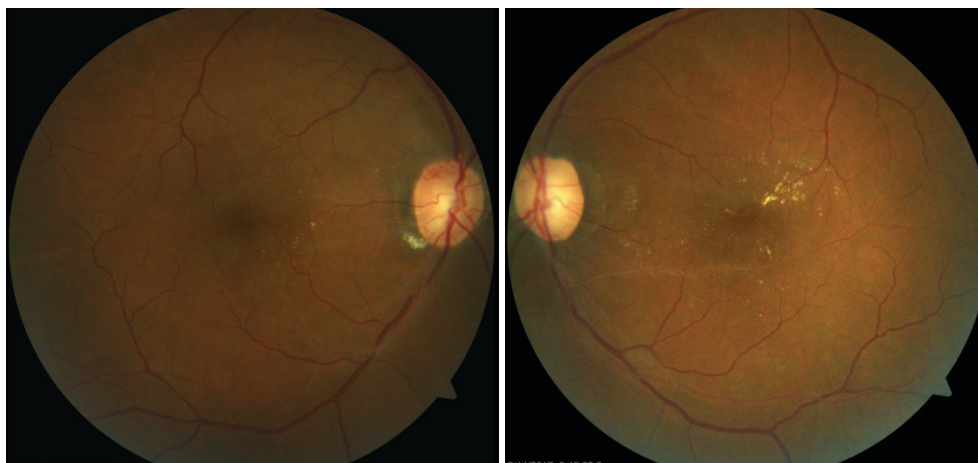
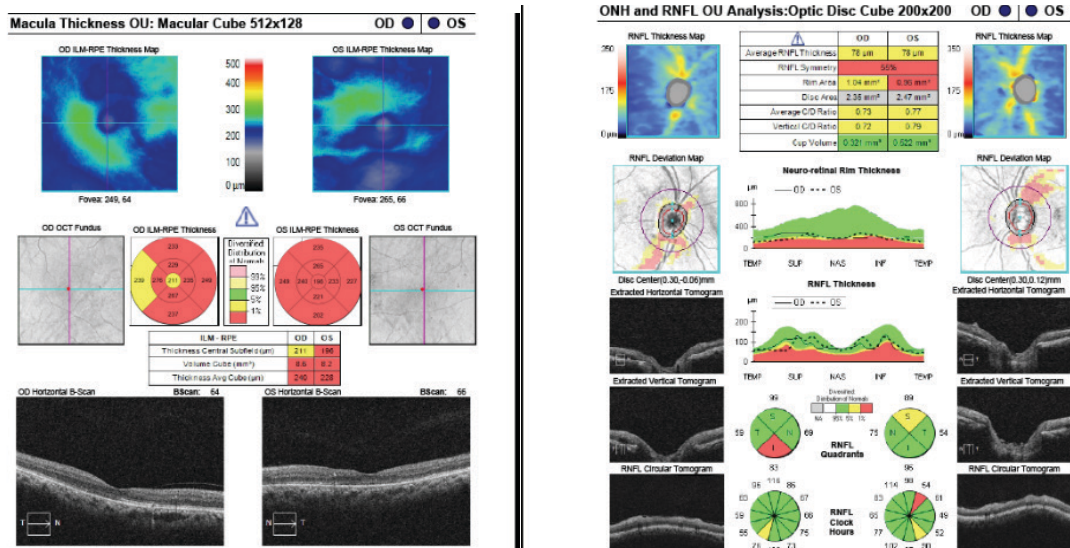


Figure 4C: Macular OCT testing showing bilateral inner retinal macular atrophy.



DISCUSSION:

For patients presenting with known elevations in blood pressure, it is important to consider all possible manifestations of hypertension that could contribute to both changes in fundus appearance and visual decline. Generally, even well-controlled hypertension can be expected to cause chronic fundus changes. These changes include arterial narrowing (focal or general), compression of retinal veins where retinal arteries cross and the vessels share a common adventitial sheath (crossing changes), changes in vessel appearance (copper or silver wiring), and manifestation of retinal micro-aneurysms.⁴ Fundus findings more commonly caused by acutely elevated blood pressure are micro-infarcts (cotton wool spots), superficial retinal hemorrhages, and exudation of lipid material from retinal blood vessels.⁴ While not specifically noted in this case, multiple retinal pathologies, all of which can cause transient or permanent visual decline, are caused by underlying hypertensive disease. These manifestations include retinal vein or artery occlusion, retinal arterial macro-aneurysm, and both anterior and posterior forms of non-arteritic ischemic optic neuropathy.⁴

Hypertensive retinopathy fundus changes result from failure of the autoregulation, autonomic nerve supply, and blood-retinal barrier systems.^{5,6,7} In cases of malignant hypertension as discussed here, changes can be subdivided into three categories: hypertensive retinopathy, hypertensive choroidopathy, and hypertensive optic neuropathy.^{5,6} Some retinal findings in hypertensive retinopathy are frequently overlooked due to the lack of associated retinal hemorrhages. These findings include focal arteriolar constrictions and smooth muscle necrosis of the retinal arteries (which present prior to the more commonly observed retinal hemorrhages), infarctions, and exudations.^{5,6} Early morphological changes are implicated in compromised retinal autoregulation, perpetuating the later manifestations of malignant hypertension.⁶ Hypertensive choroidopathy is caused by functional loss of the choroid, resulting from fibrinoid necrosis of the choroid and ischemic necrosis of the retinal pigment epithelium (RPE).⁸ These physiologic alterations, which are caused in part by hyalinization of the short and long posterior ciliary arteries supplying the choroid, result in breakdown of the blood-retinal barrier and cause accumulation of sub-retinal fluid.^{4,8} Severe choroidal dysfunction leads to RPE pump failure and resultant subretinal fluid accumulation with choroidal detachment and non-rhegmatogenous retinal detachment.⁴ Optic nerve head swelling from hypertensive optic neuropathy manifests in the later stages of hypertensive retinopathy, with implications for high risk mortality if treatment is not initiated urgently and effectively.⁶ Suggested etiologies include ischemia of the optic nerve head resulting in fluid accumulation and/or a result of significantly elevated systemic hypertension causing an increase in cerebrospinal fluid pressure and intracranial pressure leading to the appearance of hypertensive papilledema.⁶ There is a documented association between optic disc swelling and high risk of patient death.⁷ The three entities of retinopathy, choroidopathy, and optic neuropathy, are all manifestations of the hypertensive disease process. Coexisting involvement of these three tissue layers comprises the characteristic fundus changes of advanced malignant hypertension, with implications that extend beyond the eye and warrant evaluation for acute intervention and possible hospital admission.

Treatment of malignant hypertension and its ophthalmic sequelae typically centers around management of the systemic disease. Extreme elevations in blood pressure often require hospitalization to treat. Additionally, malignant hypertension is commonly accompanied by multiple organ failure such as renal failure, acute myocardial infarction, intracranial hemorrhage, and pulmonary edema.⁶ The presented case illustrates this point well, as the patient was diagnosed with an acute ischemic stroke involving the frontal lobe at the initial hospital admission, possibly accounting for his erratic/uncooperative behavior upon initial presentation. Supplementary interventions specific to the ocular manifestations of malignant hypertension may be needed if retinal findings do not adequately improve. In these cases of persistent macular edema and/or optic nerve head edema, intravitreal anti-VEGF treatments are shown to be very effective in reducing vascular permeability and promoting resolution of edema, thereby resulting in better visual outcomes.⁹ Substantial visual acuity improvement was noted in this case, with a return of BCVA at distance to 20/20 and 20/25 in the right and left eyes respectively, using systemic management only. As in this case presentation, persistence of poor subjective visual function was experienced despite dramatically improved Snellen acuity. This was attributed to the observed loss of nerve fiber layer and visual field defects warranting referral for low vision management.

While the most common forms of low vision management often center around magnification, patients with visual field loss may be less than successful with this approach. Instead, patients with peripheral loss often benefit from Peli prisms, reverse telescopes, and devices that increase illumination. These tools aid patients by increasing the functional visual field, improving scanning abilities, and increasing contrast. Furthermore, visual rehabilitation training is often useful in both teaching patients to properly use these devices and providing services like orientation and mobility training to assist in navigating their surroundings safely.

Although this case presented with a known hypertensive crisis, not all cases of malignant hypertension will present with a previously identified cause. Fundus examination may be the precipitating factor that suggests the diagnosis of malignant hypertension and leads to the determination of an underlying etiology.¹⁰ This becomes even more critical when you consider that the prognosis of malignant hypertension tends to be very poor, with a 5-year survival rate of only 1%.^{3,10} Visual function will, of course, be a significant concern of any patient that has been diagnosed with malignant hypertension. As an eye-care provider it is important to understand that in many cases, especially with malignant hypertension, you are playing a pivotal role in not only visual and ocular health, but on preserving the overall quality of life and mortality of these patients. ●

REFERENCES

1. Basile J, Bloch M. "Overview of Hypertension in Adults." *UpToDate*. 2020. https://www.uptodate.com/contents/overview-of-hypertension-in-adults?search=hypertension&source=search_result&selectedTitle=1-150&usage_type=default&display_rank=1
2. World Health Organization. *A Global Brief on Hypertension*. 2013;1-40. <http://ish-world.com/news/a/World-Health-Organization-A-Global-Brief-on-Hypertension/>
3. Edmunds E, Beevers DG, Lip GYH. "What Has Happened to Malignant Hypertension? A Disease No Longer Vanishing." *J Hum Hypertens* 2000;14:159-161. <https://rdcu.be/bHI3C>
4. Fraser-Bell S, Symes R, Vaze A. "Hypertensive Eye Disease: A Review." *Clin Exp Ophthalmol* 2016 Dec;45(1):45-53. <https://onlinelibrary.wiley.com/doi/full/10.1111/ceo.12905>
5. Hayreh SS. "Hypertensive Retinopathy." *Ophthalmologica* 1989;198:173-177.
6. Hammond S MD, Wells JR MD, Marcus DM MD, Prisant LM DM. "Ophthalmoscopic Findings in Malignant Hypertension." *J Clin Hypertens* 2007 Jan;8(3):221-223. <https://onlinelibrary.wiley.com/doi/full/10.1111/j.1524-6175.2005.04147.x?sid=nlm%3Apubmed>
7. Hayreh SS. "Classification of Hypertensive Fundus Changes and Their Order of Appearance." *Ophthalmologica* 1989;198:247-260.
8. Ahn SJ, Woo SJ, Park KH. "Retinal and Choroidal Changes With Severe Hypertension and Their Association With Visual Outcome." *Invest Ophthalmol Vis Sci* 2014 Dec; 55(12):7775-7785. <https://iovs.arvojournals.org/article.aspx?articleid=2212632>
9. Al-Halafi AM. "Tremendous Result of Bevacizumab in Malignant Hypertensive Retinopathy." *Oman J Ophthalmol* 2015 Jan-Apr;8(1):61-63. <https://www.ncbi.nlm.nih.gov/pmc/articles/PMC4333549/>
10. Tajunisah I, Patel DK. "Malignant Hypertension with Papilledema." *The J Emerg Med* 2013 Jan;44(1):164-165. <https://www.clinicalkey.com/#!/content/journal/1-s2.0-S073646791100552X>