

QR CODE



Non-Syndromic Hypodontia: A Case Report

PARUL UPPAL MALHOTRA¹, YAGYESHWAR MALHOTRA^{*2}, NEERA OHRI³, ANINDITA MALLIK⁴A
B
S
T
R
A
C
T

Hypodontia is the most common dentofacial anomaly observed in humans. It can be syndromic or an isolated trait. Missing teeth not only affects functionality of dentition but also aesthetically looks unpleasing. In this case report, a 12 year old girl is presented with agenesis of four permanent teeth. On examination, patient was found to be suffering from non syndromic hypodontia. Restorative and Prosthetic treatment was done to rehabilitate the case

KEYWORDS: Hypodontia, Non-syndromic, Agenesis

INTRODUCTION

Hypodontia refers to the developmental failure of six or fewer teeth.¹ Hypodontia is the most prevalent dentofacial malformation in humans.² It can be associated with a recognised genetic syndrome or may occur as a nonsyndromic isolated trait.³ Tooth agenesis affects the maxilla and the mandible with similar prevalence,⁴ whereas Wisth et al. (1974) suggested that the mandible is more frequently affected than the maxilla.⁵ Polder et al. (2004) in a metaanalysis on agenesis of tooth found that bilateral agenesis of maxillary lateral incisors occurs more often than unilateral agenesis. He too found that hypodontia affects females 1.4 times higher than males.⁴

Hypodontia causes deep bite and spacing in dentition. Missing posterior teeth also leads to nonworking interferences, overeruption of the opposing teeth and poor gingival contours. Laing et al. (2010) in a cross-sectional study concluded that if deciduous teeth are exfoliated which are associated with the missing permanent teeth, such patients with hypodontia will have more chewing difficulties.⁶ It is therefore plausible that hypodontia causes functional as well as esthetic limitations that affect an individual's general well-being and quality of life in the process, although presently, evidence to support this is limited.

CASE REPORT

A 12-year-old girl reported in the dental clinic with chief complaint of non-eruption of teeth. Her past

medical history was non-contributory and family history revealed that she was born to non-consanguineous marriage with normal delivery and no one in her family have congenitally missing teeth. The patient had no history of trauma or extractions. Extra oral examination revealed a face with normal facial profile and normal skeletal dental base relations (figure 1). Intra oral examination revealed, enamel hypoplasia in maxillary left central incisor and screw shaped left maxillary lateral incisor, retained right and left deciduous canines, right and left first deciduous molars, right and left deciduous second molars and right & left permanent first molars in maxillary arch. In mandibular arch, both permanent central incisors were missing. Permanent right & left lateral incisors and first molars were fully erupted. Deciduous right and left canines and deciduous left second molar were present. Permanent mandibular molars and deciduous left second molar were carious (figure 2 and 3). An orthopantomogram was advised which revealed missing tooth buds of tooth number 15, 35, 31 and 41 (figure 4). Due to prolonged absence of deciduous molars on right side and carious deciduous molar on left side in mandibular arch, there was deepening of occlusal bite as seen in figure 2.

A provisional diagnosis of non-syndromic oligodontia was given with differential diagnosis of Ectodermal Dysplasia; Rieger syndrome and



© Parul Uppal Malhotra et al. This is an open access article distributed under the terms of the Creative Commons Attribution License CC-BY-NC 4.0, which permits unrestricted use, distribution and reproduction in any medium, provided the use is not commercial and the original author(s) and source are cited.



Figure 1. Pre-Treatment Extra-Oral Radiographs

Van der Woude syndrome. Complete set of investigations were done which included routine examination of blood including serum calcium, alkaline phosphate, TSH, T₃, T₄. The findings of these investigations were normal. During physical examination, no abnormality was observed with nails, perspiration and thickness of hairs, which ruled out ectodermal dysplasia; on ocular examination, no signs of glaucoma was seen ruling out Rieger syndrome and lastly there was no mucosal cysts in lips or cleft palate which ruled out Van Der Woude syndrome too. Finally based on above findings non syndromic Oligodontia as final diagnosis was justified.

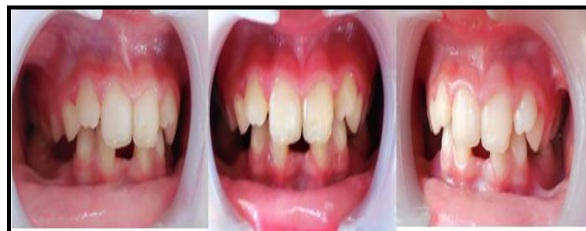

Figure 2. Pre-treatment Intraoral photographs showing deepening of occlusal bite and enamel hypoplasia w.r.t 21

The treatment plan considered for the patient included restoration of carious teeth and preservation of the space till eruption of all permanent teeth. Permanent teeth were restored with tooth coloured restoration. Stainless steel crown was given on left mandibular restored deciduous second molar (figure 5). Removable partial denture was given as functional space maintainer in mandibular arch to restore function and esthetics (figure 6).

DISCUSSION

Hypodontia carries an aesthetic, functional, psychosocial, and financial burden for affected

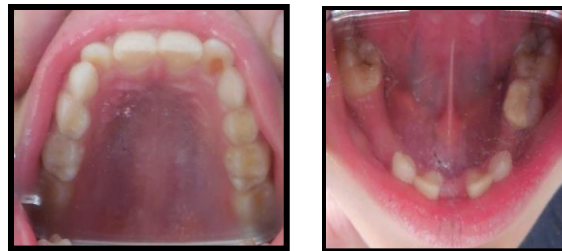

Figure 3. Pre-treatment Intraoral photographs showing missing teeth w.r.t mandibular arch (occlusal view).

individuals.¹ For these patients, hypodontia is a lifetime problem, which requires careful treatment planning in order to ensure best treatment outcomes. Treatment plans also involve longterm maintenance and family counselling.⁷

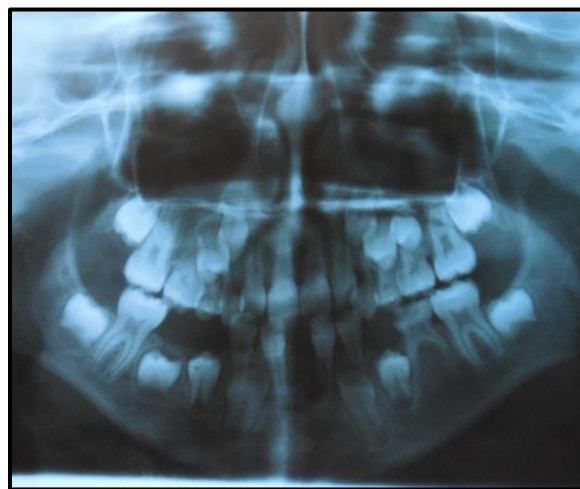


Figure 4. Pre-treatment orthopantomogram showing missing tooth buds of 15, 35, 31 and 41

Common issues faced in treating hypodontia patients include space management, uprighting and aligning teeth, management of the deep overbite, and retention.⁸ Space issues within the dental arch are multifactorial in origin. The amount of spacing is influenced by the presence of microdontia, retention of the primary teeth, and the abnormal eruptive paths and drifting of the successional teeth.⁷ The decision on whether the treatment plan involves space closure or opening of the spaces of the missing mandibular second premolar depends on factors such as age of the patient; degree of inherent crowding; state of the deciduous teeth; type of malocclusion; and the circumstances of the patient (finances, attitude towards treatment, etc.). In hypodontia patients,

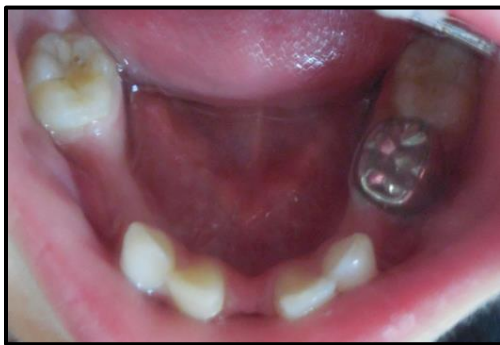

Figure 5. Intraoral photograph of mandibular arch showing restoration w.r.t 36,46 and stainless steel crown w.r.t 75

dental development is often delayed, as is orthodontic treatment.⁹

In present case space maintenance was required till the permanent teeth erupts. Restoration of permanent teeth as well as stainless steel crown was given on deciduous second molar so that space maintenance can be done. Functional space maintainer was given to establish esthetics, function and for the preservation of space till all permanent teeth erupts.

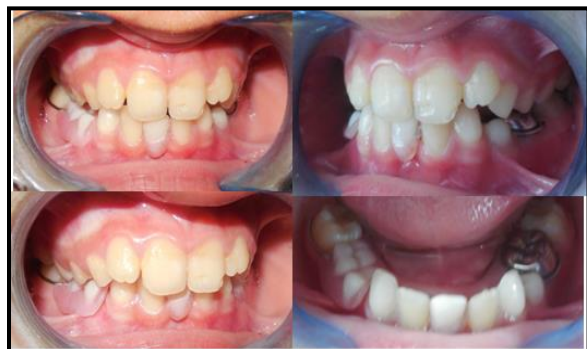

Figure 6. Post treatment Intraoral photographs showing insertion of functional space maintainer

Therefore early diagnosis is important in such conditions. Case of tooth agenesis should be recorded with complete clinical history including medical and radiological investigations to rule out any syndrome.¹⁰

In conclusion, even though hypodontia is mostly considered to be associated with several syndromes but non syndromic aspect of hypodontia should also be taken into

consideration. Also, this condition should be treated as early as possible to prosthetic and aesthetic functionality of teeth.

REFERENCES

1. Nunn JH, Carter NE, Gillgrass TJ, et al, The interdisciplinary management of hypodontia: background and role of paediatric dentistry. *British Dental Journal* 2003;194(5):245-51.
2. Matalova E, Fleischmannova J, Sharpe PT, Tucker AS. Tooth agenesis: from molecular genetics to molecular dentistry, *Journal of Dental Research* 2008;87(7):617-23.
3. Cobourne MT, Sharpe PT. Diseases of the tooth: the genetic and molecular basis of inherited anomalies affecting the dentition. *Wiley Interdisciplinary Reviews: Developmental Biology* 2013;2(2):183-212.
4. Polder BJ, Van't Hof MA, Van Der Linden FPGM, Kuijpers-Jagtman AM. A meta-analysis of the prevalence of dental agenesis of permanent teeth. *Community Dentistry and Oral Epidemiology* 2004;32(3):217-26.
5. Wisth PJ, Thunold K, B"oe OE. Frequency of hypodontia in relation to tooth size and dental arch width. *Acta Odontologica Scandinavica* 1974;32(3):201-6.
6. Laing E, Cunningham SJ, Jones S, Moles D, Gill D. Psychosocial impact of hypodontia in children. *AJODO*. 2010; 137(1):35-41.
7. Pinho T, Ciriaco C, Faber J, Lenza MA. Impact of dental asymmetries on the perception of smile aesthetics. *AJODO*. 2007; 27(5):443-9.
8. Carter NE, Gillgrass TJ, Hobson RS, et al. The interdisciplinary management of hypodontia: orthodontics. *British Dental Journal* 2003; 194(7):361-6.
9. Dharmo B, Vucic S, Kuijpers MAR, et al. The association between hypodontia and dental development. *Clinical Oral Investigations* 2016; 20(6):1347-54.
10. Singh AP, Boruah LC. Nonsyndromic oligodontia in Permanent Dentition of three siblings: A case report. *JIDA*. 2009;3:117-9.

Cite this article as:

Malhotra PU, Malhotra Y, Ohri N, Mallik A. Non-Syndromic Hypodontia: A Case Report. Int Healthc Res J. 2020;4(7):CR3-CR6. <https://doi.org/10.26440/IHRJ/0407.10287>

Source of support: Nil, **Conflict of interest:** None declared

AUTHOR AFFILIATIONS: (*: Corresponding Author)

1. MDS (Paediatric and Preventive Dentistry), Medical officer (Dental), Community Health Centre, Nalagarh, Solan, HP, India
2. MDS (Orthodontics and Dentofacial Orthopedics), Consultant Orthodontist, Kangra, HP, India
3. MDS (Oral Medicine and Maxillofacial Radiology), Senior Resident, Department of Dentistry, Dr RPGMC, Tanda at Kangra, HP, India
4. MDS (Orthodontics and Dentofacial Orthopedics), Consultant Orthodontist, Siliguri, WB, India

Contact Corresponding Author at: y9417804155[at]gmail[dot]com