

This is the accepted manuscript of:

Pignatti, M, Pinto, V, Giorgini, FA, et al. *Meta-analysis of the effects of venous super-drainage in deep inferior epigastric artery perforator flaps for breast reconstruction*. *Microsurgery*. 2020; 1– 10.

Final version available: <https://doi.org/10.1002/micr.30682>

Rights / License:

The terms and conditions for the reuse of this version of the manuscript are specified in the publishing policy. For all terms of use and more information see the publisher's website.

This item was downloaded from IRIS Università di Bologna (<https://cris.unibo.it/>)

**When citing, please refer to the published version.**

1  
2  
3  
4  
5  
6 **A meta-analysis of the effects of Venous super-drainage in Deep Inferior Epigastric**  
7 **Perforator flaps for breast reconstruction.**  
8  
9

10 Marco Pignatti <sup>a</sup>, Valentina Pinto <sup>b</sup>, Federico A. Giorgini <sup>b,e</sup>, Maria Elisa Lozano Miralles <sup>b,e</sup>, Giacomo  
11 Cannamela <sup>c</sup>, Salvatore D'Arpa <sup>d</sup>, Riccardo Cipriani <sup>b</sup>, Giorgio De Santis <sup>e</sup>  
12  
13  
14

15  
16 **M. Pignatti, MD, FEBOPRAS**

17 Plastic Surgery, Policlinico di Sant'Orsola - DIMES, University of Bologna, Italy  
18  
19

20 V. Pinto, MD, PhD

21 Plastic Surgery, Policlinico di Sant'Orsola - Bologna, Italy  
22  
23

24 F. A. Giorgini, MD

25 Plastic Surgery, Policlinico di Sant'Orsola - Bologna, Italy  
26

27 &

28 Plastic Surgery, Policlinico di Modena, University of Modena and Reggio Emilia, Italy  
29  
30

31 M. E. Lozano Miralles, MD

32 Plastic Surgery, Policlinico di Sant'Orsola - Bologna, Italy  
33

34 &

35 Plastic Surgery, Policlinico di Modena, University of Modena and Reggio Emilia, Italy  
36  
37

38 G. Cannamela, Data scientist.

39 Milan. Italy  
40  
41

42 S. D'Arpa, MD, PhD

43 Plastic and Reconstructive Surgery, Department of Surgical, Oncological and Oral Sciences  
44 (DICHIORONS). University of Palermo, Palermo, Italy  
45  
46  
47

48 R. Cipriani, MD

49 Plastic Surgery, Policlinico di Sant'Orsola - Bologna, Italy  
50  
51

52 G. De Santis, MD

53 Plastic Surgery, Policlinico di Modena, University of Modena and Reggio Emilia, Italy  
54  
55  
56  
57

58 Corresponding author

59 Marco Pignatti, MD, FEBOPRAS

60 Via Massarenti, 9

1  
2  
3  
4  
5  
6  
7  
8  
9  
10  
11  
12  
13  
14  
15  
16  
17  
18  
19  
20  
21  
22  
23  
24  
25  
26  
27  
28  
29  
30  
31  
32  
33  
34  
35  
36  
37  
38  
39  
40  
41  
42  
43  
44  
45  
46  
47  
48  
49  
50  
51  
52  
53  
54  
55  
56  
57  
58  
59  
60

40138 Bologna, Italy  
mrpignatti@gmail.com

1  
2  
3 **A meta-analysis of the effects of Venous super-drainage in Deep Inferior Epigastric artery**  
4 **Perforator flaps for breast reconstruction.**  
5  
6  
7

8 **Abstract**  
9

10 Introduction

11  
12  
13 Venous congestion is the most common vascular complication of the Deep Inferior Epigastric  
14 artery Perforator (DIEP) flaps. Adding a second venous drainage by anastomosing a flap vein and a  
15 recipient vein (super-drainage) is considered the solution of choice. Evidence to support this  
16 procedure, had not yet been confirmed by an analysis of the literature. We aimed to provide this  
17 evidence.  
18  
19  
20  
21  
22  
23  
24

25 Materials and Methods

26  
27  
28 We searched the literature (MedLine, Scopus, EMBASE, Cochrane Library, and Google Scholar), for  
29 studies discussing venous congestion and venous super-drainage in DIEP flap for breast  
30 reconstruction. 13/35 articles compared results between one or two venous anastomoses. Meta-  
31 analysis was performed following PRISMA guidelines . Pooled risk ratio (RRs) for congestion, fat  
32 necrosis, partial necrosis, and total necrosis with corresponding 95% confidence intervals (CI) were  
33 calculated using a fixed-effect model with the Mantel–Haenszel method. The need to return to  
34 surgery (95% CI) was estimated with a random effect model using the DerSimonian & Liard  
35 method.  
36  
37  
38  
39  
40  
41  
42  
43  
44  
45  
46

47 Results

48  
49  
50 We showed a statistically significant advantage of super-drainage to reduce the venous  
51 congestion of the flap (RR: 0.12, 95% CI: 0.04 – 0.34,  $p$ -value < 0,001), partial flap necrosis (RR:  
52 0.50, 95% CI: 0.30 - 0.84,  $p$ -value 0,008), total flap necrosis (RR: 0.31, 95% CI: 0.11 - 0.85,  $p$ -value  
53 0.023), and the need to take the patient back to surgery for perfusion-related complications (RR:  
54 0,45, 95% CI: 0.21 - 0.99,  $p$  value 0.048).  
55  
56  
57  
58  
59  
60

1  
2  
3 **Conclusions**  
4

5 Performing a second venous anastomosis between the SIEV and a recipient vein (venous  
6  
7  
8 superdrainage) reduces venous congestion and related complications in DIEP flaps for breast  
9  
10 reconstruction.  
11  
12  
13  
14  
15  
16  
17  
18  
19

20 **Keywords:** DIEP, venous congestion, meta-analysis, super-charging, super-drainage  
21  
22  
23  
24  
25  
26  
27  
28  
29  
30  
31  
32  
33  
34  
35  
36  
37  
38  
39  
40  
41  
42  
43  
44  
45  
46  
47  
48  
49  
50  
51  
52  
53  
54  
55  
56  
57  
58  
59  
60

1  
2  
3 **INTRODUCTION**  
4  
5  
6  
7

8 The Deep Inferior Epigastric artery Perforator (DIEP) flap, is considered the gold standard for  
9 autologous breast reconstruction.<sup>1</sup> Flap failure is reported to occur in 1 to 5 % of cases.<sup>2</sup> However,  
10 the frequency of partial failures and their consequences is higher.<sup>3</sup> The unsatisfactory results are  
11 frequently due to perfusion-related complications, developing in up to 17% of DIEP flaps.<sup>4</sup> Venous  
12 congestion is the most common of the above-mentioned perfusion-related complications, with a  
13 reported incidence ranging from 2% to 20%<sup>5,6</sup> representing one of the main causes of fat necrosis,  
14 partial flap necrosis and, less frequently, complete necrosis of the flap.<sup>3</sup> The etiology of venous  
15 congestion is multifactorial<sup>7-12</sup> with reversible and non-reversible causes.

16  
17  
18  
19  
20  
21  
22  
23  
24  
25  
26  
27  
28  
29  
30  
31  
32  
33  
34  
35  
36  
37  
38  
39  
40  
41  
42  
43  
44  
45  
46  
47  
48  
49  
50  
51  
52  
53  
54  
55  
56  
57  
58  
59  
60

When the causes of venous congestion are not reversible intraoperatively, treatment of the  
congestion itself is necessary and usually consists in increasing venous drainage of the flap by  
adding a second venous anastomosis between the flap and a recipient vein. The term flap  
supercharge or, semantically more correctly, venous super-drainage is usually employed.

Several papers have been published highlighting the problem of DIEP's venous congestion, and  
describing the surgical solutions available. **Although there is no controversy regarding the use of  
flap super-drainage, which is the standard solution in case of venous congestion, evidence of the  
efficacy of this procedure on flap necrosis and vascular complications had not yet been  
reported.**

To try to clarify the matter, we conducted a literature search statistically evaluating with a meta-  
analysis the relevant studies looking for evidence on the role of DIEP flap's venous super-drainage  
in decreasing flap complications.

**MATERIALS AND METHODS**

1  
2  
3  
4  
5 We performed a meta-analysis of the literature evaluating the role of a second venous  
6 anastomosis to prevent the complications of DIEP flap's congestion. A literature search was  
7 conducted using MedLine, Scopus, EMBASE, Cochrane Library, and Google Scholar to identify and  
8 include all citations from 1994 to June 2019. To reduce inclusion bias, two of the Authors (VP and  
9 FG) performed, separately, the initial article search and selection with pertinent keywords ("Deep  
10 inferior epigastric perforator" OR "DIEP" AND "flap" [All Fields] AND venous congestion [All Fields]  
11 AND ("additional anastomosis"[Subheading] AND "superficial inferior epigastric vein"[All Fields]  
12 OR "SIEV"[All Fields] AND "supercharging" OR "superdrain" OR "super-drainage") (Figure 1)  
13  
14

15 Duplicated articles, isolated abstracts, case reports, correspondence and letters were excluded  
16 and only full-text articles in English regarding DIEP flaps and venous congestion were considered.  
17  
18

19 We followed the guidelines of the Preferred Reporting Items for Systematic Reviews and Meta-  
20 Analysis (PRISMA statement)<sup>13</sup> .  
21  
22

23 We considered eligible the retrieved publications based on PICOS criteria (Patients, Interventions,  
24 Control/comparison, Outcomes, and Study Design), and analyzed by meta-analysis the incidence  
25 of perfusion-related complications: venous congestion, flap necrosis (total and partial), fat  
26 necrosis and need to take the patient back to surgery for perfusion-related complications. The  
27 most relevant data collected from the publications found were: first author, year of publication,  
28 number of patients and events, type of the second anastomosis and recipient vein, and operative  
29 time.  
30  
31

### 32 **Statistical Analysis**

33 The Mantel-Haenszel test in R was used to calculate Pooled RRs and corresponding 95%  
34 confidence intervals (CI) for perfusion-related complications. The heterogeneity among studies  
35  
36  
37  
38  
39  
40  
41  
42  
43  
44  
45  
46  
47  
48  
49  
50  
51

1  
2  
3 was analyzed by using the I<sup>2</sup>test. We used a fixed-effects model for I<sup>2</sup> ranging from 0 to 30%; in the  
4  
5 case of I<sup>2</sup>> 30%, we applied a random effect model using the DerSimonian & Liard method.  
6  
7

8 For each test p value ≤ 0,05 was set for significance  
9

## 10 11 **RESULTS** 12 13 14 15

16 After exclusion of non-relevant papers, we identified 35 eligible articles and performed a  
17  
18 qualitative evaluation following the guidelines of the Preferred Reporting Items for Systematic  
19  
20 Reviews and Meta-Analysis (PRISMA statement). <sup>13</sup>Of these articles, 13 compared results between  
21  
22 one or two venous anastomoses in DIEP flaps for breast reconstruction <sup>3,14-25</sup> and were included in  
23  
24 our study. All the studies that we reviewed were retrospective, except the one by Ayestaray, <sup>16</sup>  
25  
26 which is prospective and randomized.  
27  
28  
29

30  
31 Overall, our study analyzed 3094 DIEPs, of which, 1279 received a second venous anastomosis  
32  
33 (“case group”); and 1815 received only one venous anastomosis (“control group”). Venous  
34  
35 congestion occurred in 38 out of 1121 flaps, with an overall mean rate of 3.4%. The venous  
36  
37 congestion rate in each study ranged from 0.9% to 36.5%. Regarding other perfusion-related  
38  
39 complications, our literature review revealed 1.5 % total flap loss (34/2278) (ranging from 0% to  
40  
41 9.6%), 6% partial flap loss (78/1294) (0% to 28.8%), 11.9% fat necrosis (217/1824) (7.2% to 34.6%),  
42  
43 11.1% take back to surgery for perfusion-related complications (187/1678) (0.9% to 21.2%).  
44  
45  
46  
47

48 Of the 13 articles <sup>3,14-25</sup> included in our meta-analysis, 12 <sup>3,14-18,20-25</sup> reported the second  
49  
50 anastomosis to have been performed between the SIEV and a recipient vein of the thorax, while in  
51  
52 one study <sup>19</sup> the second anastomosis was done using as flap vein the SIEV or a second DIEV,  
53  
54 without additional information being provided. In all the articles included in our systematic  
55  
56 review, performing an adjunctive anastomosis variably increased the operation time from no  
57  
58 difference to 105 minutes (TABLE 1 ).  
59  
60



1  
2  
3 In more detail we found that anastomosing the SIEV of the flap with a recipient vein provided a  
4 statistically significant advantage in terms of venous congestion (RR: 0.12, 95% CI: 0.04 – 0.34) *p*-  
5 value < 0,001) (Figure 2) and to prevent flap necrosis both partial (RR: 0.50, 95% CI: 0.30 - 0.84, *p*-  
6 value 0,008) (Figure 3) and total (RR: 0.31, 95% CI: 0.11 - 0.85, *p*-value 0.023) (Figure 4). A second  
7 venous drainage showed a statistically significant advantage also regarding the need to take the  
8 patient back to surgery for perfusion-related complications (RR: 0,45, 95% CI: 0.21 - 0.99, *p* value  
9 0.048) (Figure 5). Conversely, the advantage of a second venous anastomosis was not significantly  
10 beneficial to prevent fat necrosis RR: 0.83, 95% CI: 0.63 - 1.10 reporting a *p*-value 0.19). (Figure 6)  
11  
12  
13  
14  
15  
16  
17  
18  
19  
20  
21  
22  
23  
24

## 25 **DISCUSSION**

26  
27  
28  
29  
30 Although the DIEP flap is considered the gold standard for breast reconstruction, venous  
31 congestion can cause complete or partial flap failure and several other complications.  
32

33  
34 Our work, by reviewing the updated pertinent literature, aimed to provide evidence on  
35 the effect of super-drainage in terms of venous congestion and related complications. In case of  
36 intraoperative venous congestion, the reversible causes can be identified and corrected. In  
37 particular, anastomotic failure requires resection of the anastomotic site, removal of any  
38 thrombus present, rinsing of the donor and recipient vessels with a heparinized solution (and,  
39 depending on the clinical situation, time since the beginning of occlusion and kind of flap, flap  
40 perfusion with thrombolytic agents), and vessels' re-anastomosis. Vessel kinking can be solved by  
41 repositioning the entire pedicle of the flap by supporting it with a piece of fat or muscle, by  
42 stabilizing it with fibrin glue or by applying a stitch between the kinked vessel and the surrounding  
43 tissue to straighten its course. A mild to moderate torsion of a long pedicle can be solved simply  
44 by repositioning of the pedicle and therefore redistributing the torsion on its entire length. In  
45  
46  
47  
48  
49  
50  
51  
52  
53  
54  
55  
56  
57  
58  
59  
60

1  
2  
3 more severe cases the anastomosis will need to be redone. If, in a large flap, the venous  
4  
5 congestion is stable and only involves the distal portion of the flap, because of insufficient  
6  
7 drainage despite effective outflow through the pedicle, resection of that area may be sufficient.  
8  
9

10 The second venous anastomosis, aimed to obtain a super-drainage of the flap, can be performed

11  
12 a) between the deep venous system of the flap and a comitant vein of the recipient vessels  
13  
14 (comitant DIEV-IMV)<sup>19,26</sup>, b) between the deep venous system of the flap and a vein of the thorax  
15  
16 (comitant DIEV-vein of thorax)<sup>27</sup>, c) between the SIEV and the DIEV or to one of its side-branches  
17  
18 (SIEV-DIEV)<sup>1,5,17,28,29</sup>

19  
20  
21  
22 d) between SIEV and a vein of the thorax<sup>3,14-22,24</sup> .

23  
24  
25 In physiologic conditions, the dominant venous drainage to the lower abdominal skin and fat is  
26  
27 provided by the superficial venous system through the inferior epigastric vein (SIEV).<sup>5, 15</sup> All the  
28  
29 papers included in our meta-analysis used the SIEV as a second vein of the flap to increase venous  
30  
31 output. Table 1. The SIEV can be anastomosed, as said, to a vein of the deep venous system of the  
32  
33 flap (intra-flap anastomosis) 1,5 or a vein of the patient's chest (extra-flap anastomosis).<sup>14</sup>

34  
35  
36  
37 Unfavorable anatomy of the venous system is considered among the most important, not-  
38  
39 reversible, causes of venous congestion. Several studies<sup>5,6,10,30</sup> attribute the clinical manifestations  
40  
41 of venous congestion and the so-called perfusion-related complications to the lack of sufficient  
42  
43 venous drainage from all areas of the flap (superficial, deep, ipsilateral, contralateral). Not all the  
44  
45 factors related to the flap's venous anatomy can be modified by the surgeon. Therefore accurate  
46  
47 planning based on vascular anatomy is of utmost importance to prevent venous congestion of the  
48  
49 flap. Computed tomographic angiography and magnetic resonance angiography permit to visualize  
50  
51 the arterial system and, even more importantly, the venous connections between the deep and  
52  
53 superficial systems, allowing to choose the most favorable perforators for optimal perfusion and  
54  
55  
56  
57  
58  
59  
60

1  
2  
3 drainage. <sup>7,10</sup> The ideal perforator will have a large caliber, a central position in the flap and  
4  
5 numerous connections between the deep and superficial venous systems. <sup>31</sup>  
6  
7

8 Once venous congestion occurs, and intraoperatively the reversible causes have been excluded, it  
9  
10 is necessary to treat the venous congestion itself, by venous super-drainage.  
11  
12

13 One previously published meta-analysis, from Lee et al <sup>32</sup> showed that the use of super-drainage  
14  
15 has a statistical advantage over venous congestion but only a trend toward a decreased risk of  
16  
17 congestion-related complications. Further studies were, therefore, suggested. A detailed  
18  
19 comparison with that previous meta-analysis <sup>32</sup>, is presented in TABLE 2. Our analysis includes the  
20  
21 six articles examined by Lee and seven additional ones, reporting on large groups of patients<sup>22,23</sup>  
22  
23 and on a prospective randomized study<sup>16</sup>. (TABLE 1). Statistical methods were comparable but the  
24  
25 larger amount of data, allowed us to achieve statistical evidence that the use of super-drainage,  
26  
27 employing a second venous anastomosis between the SIEV and a recipient vein, reduces venous  
28  
29 congestion, prevents partial and total flap necrosis, and the need to take the patient back to  
30  
31 surgery. Unfortunately, the available data did not show a statistically significant advantage of a  
32  
33 second venous anastomosis to prevent fat necrosis, a common complication (6% to 17.4%) in DIEP  
34  
35 flaps.  
36  
37  
38  
39  
40

41  
42 However, from the results of our meta-analysis, there seems to be an advantage also in  
43  
44 performing a second venous anastomosis in flaps without venous congestion. Therefore, the  
45  
46 choice of performing routinely a second venous anastomosis should be considered.  
47  
48  
49  
50

51  
52 A comparison between the super-drainage technique consisting in anastomosis of the SIEV to a  
53  
54 recipient vein (the only one for which we have demonstrated a statistical advantage), and other  
55  
56 techniques, such as DIEV to recipient vein, intermittent SIEV catheter drainage, or the application  
57  
58  
59  
60

1  
2  
3 of leeches, was not feasible, based on the data available in the literature. The same problem exists  
4  
5 regarding which vein the SIEV was anastomosed (e.g., retrograde IMV vs cephalic turndown).  
6  
7

8 A limitation of our study consists in the difficulty to achieve solid conclusions when working on  
9  
10 mainly retrospective articles , none of which with an evidence level I or II (TABLE 1). However, our  
11  
12 study follows the PRISMA guidelines <sup>13</sup>, which warrant the quality of a meta-analysis.  
13  
14

15 Our study is the first to report statistically significant results on the subject of super-drainage. Our  
16  
17 meta-analysis of the literature demonstrated the usefulness of venous superdrainage when  
18  
19 performing DIEP flaps in postmastectomy breast reconstruction, an elective surgery burdened  
20  
21 with relevant emotional implications for the patient. The use of an adjunctive venous anastomosis  
22  
23 as a preventive measure could be considered.  
24  
25  
26  
27  
28  
29

## 30 **CONCLUSIONS**

31  
32 In conclusion, our meta-analysis shows that venous super-drainage, i.e. performing a second  
33  
34 venous anastomosis between the superficial venous system and a recipient vein, provides a  
35  
36 statistically significant advantage in terms of venous congestion and related complications in DIEP  
37  
38 flaps for breast reconstruction.  
39  
40  
41  
42  
43  
44  
45  
46

## 47 **REFERENCES**

48  
49  
50  
51  
52  
53  
54 1) Bartlett EL, Zavlin D, Menn ZK, Spiegel AJ. Algorithmic Approach for Intraoperative Salvage of  
55  
56 Venous Congestion in DIEP Flaps. J Reconstr Microsurg. 2018; 34(06): 404–412.  
57  
58  
59  
60

1  
2  
3 2) Lie KH, Barker AS, Ashton MW. A classification system for partial and complete DIEP flap  
4  
5 necrosis based on a review of 17,096 DIEP flaps in 693 articles including analysis of 152 total flap  
6  
7 failures. *Plast Reconstr Surg.* 2013;132:1401–1408  
8  
9

10  
11  
12  
13 3) Santanelli F, Longo B, Cagli B, Pugliese P, Sorotos M, Paolini G. Predictive and protective factors  
14  
15 for partial necrosis in DIEP flap breast reconstruction: does nulliparity bias flap viability? *Ann Plast*  
16  
17 *Surg.* 2015; 74(1): 47-51.  
18  
19

20  
21  
22  
23 4) Peeters WJ, Nanhekhan L, Van Ongeval C, Fabrè G, Vandervoort M. Fat necrosis in deep inferior  
24  
25 epigastric perforator flaps: an ultrasound-based review of 202 cases. *Plast Reconstr Surg.* 2009;  
26  
27 124(6):1754-1758.  
28  
29

30  
31  
32  
33 5) Sbitany H, Mirzabeigi MN, Kovach SJ, Wu LC, Serletti JM. Strategies for recognizing and  
34  
35 managing intraoperative venous congestion in abdominally based autologous breast  
36  
37 reconstruction. *Plast Reconstr Surg.* 2012; 129(04):809–815.  
38  
39

40  
41  
42  
43 6) Kim DY, Lee TJ, Kim EK, Yun J, Eom JS. Intraoperative venous congestion in free transverse  
44  
45 rectus abdominis musculocutaneous and deep inferior epigastric artery perforator flaps during  
46  
47 breast reconstruction: a systematic review. *Plast Surg (Oakv).* 2015; 23(04):255–259.  
48  
49

50  
51  
52  
53  
54 7) Schaverien MV, Ludman CN, Neil-Dwyer J et al. Relationship between venous congestion and  
55  
56 intraflap venous anatomy in DIEP flaps using contrast-enhanced magnetic resonance angiography.  
57  
58 *Plast Reconstr Surg.* 2010; 126(2):385-392.  
59  
60

1  
2  
3  
4  
5  
6 8) Blondeel PN, Arnstein M, Verstraete K, et al. Venous congestion and blood flow in free  
7  
8 transverse rectus abdominis myocutaneous and deep inferior epigastric perforator flaps. *Plast*  
9  
10 *Reconstr Surg.* 2000; 106(6):1295–1299.

11  
12  
13  
14  
15 9) Tran NV, Buchel EW, Convery PA. Microvascular complications of DIEP flaps. *Plast Reconstr*  
16  
17 *Surg.* 2007; 119(5):1397–1405; discussion 1406-1408.

18  
19  
20  
21  
22 10) Rozen WM, Pan WR, Le Roux CM, Taylor GI, Ashton MW. The venous anatomy of the anterior  
23  
24 abdominal wall: An anatomical and clinical study. *Plast Reconstr Surg.* 2009;124(3): 848–853.

25  
26  
27  
28  
29 11) Lundberg J, Mark H. Avoidance of complications after the use of deep inferior epigastric  
30  
31 perforator flaps for reconstruction of the breast. *Scand J Plast Reconstr Surg Hand Surg.* 2006;  
32  
33 40(2):79–81.

34  
35  
36  
37  
38 12) Nahabedian MY, Tsangaris T, Momen B. Breast reconstruction with the DIEP flap or the  
39  
40 muscle-sparing (MS-2) free TRAM flap: is there a difference? *Plast Reconstr Surg.* 2005;  
41  
42 115(2):436–444-discussion 445-446.

43  
44  
45  
46  
47 13) Moher D, Liberati A, Tetzlaff J, Altman DG, PRISMA Group. Preferred reporting items for  
48  
49 systematic reviews and metanalyses: the PRISMA statement. *PLoS Med.* 2009; 21; 6(7): e1000097.

50  
51  
52  
53  
54 14) Eom JS, Sun SH, Lee TJ. Selection of the recipient veins for additional anastomosis of the  
55  
56 superficial inferior epigastric vein in breast reconstruction with free transverse rectus abdominis  
57  
58  
59  
60

1  
2  
3 musculocutaneous or deep inferior epigastric artery perforator flaps. Ann Plast Surg. 2011; 67(5):  
4  
5 505-509.  
6  
7  
8  
9

10 15) Enajat M, Rozen WM, Whitaker IS, Smith JM, Acosta R. A single center comparison of one  
11  
12 versus two venous anastomoses in 564 consecutive DIEP flaps: investigating the effect on venous  
13  
14 congestion and flap survival. Microsurgery. 2010; 30(3):185-191.  
15  
16  
17  
18  
19

20 16) Ayestaray B, Yonekura K, Motomura H, Ziade M. A Comparative Study Between Deep Inferior  
21  
22 Epigastric Artery Perforator and Thoracoacromial Venous Supercharged Deep Inferior Epigastric  
23  
24 Artery Perforator Flaps. Ann Plast Surg. 2016; 76(1):78-82.  
25  
26  
27  
28  
29

30 17) Xin Q, Luan J, Mu H, Mu L. Augmentation of venous drainage in deep inferior epigastric  
31  
32 perforator flap breast reconstruction: efficacy and advancement. J Reconstr Microsurg. 2012  
33  
34 Jun;28(5):313-8  
35  
36  
37  
38  
39  
40  
41

42 18) Ali R, Bernier C, Lin YT, Ching WC, Rodriguez EP, Cardenas-Mejia A et al. Surgical strategies to  
43  
44 salvage the venous compromised deep inferior epigastric perforator flap. Ann Plast Surg. 2010  
45  
46 Oct;65(4):398-406.  
47  
48  
49  
50  
51  
52  
53

54 19) La Padula S, Hersant B, Noel W, Niddam J, Hermeziu O, Bouhassira J et al. Use of the  
55  
56 retrograde limb of the internal mammary vein to avoid venous congestion un DIEP flap breast  
57  
58  
59  
60

1  
2  
3 reconstruction. Further evidences of a reliable and time-sparing procedure. *Microsurgery*. 2016;  
4  
5 36(6):4476-452.  
6  
7  
8  
9

10 20) Boutros SG. Double venous system drainage in deep inferior epigastric perforator flap breast  
11  
12 reconstruction: a single-surgeon experience. *Plast Reconstr Surg*. 2013;131(4): 671-676.  
13  
14  
15  
16

17 21) Al Hindi A, Ozil C, Rem K, Rausky J, Moris V, Guillier D, Binder JP, Revol M, Cristofari S.  
18  
19 Intraoperative superficial inferior epigastric vein preservation for venous compromise prevention  
20  
21 in breast reconstruction by deep inferior epigastric perforator flap. *Ann Chir Plast Esthet*. 2019  
22  
23 Jun;64(3):245-250.  
24  
25  
26  
27

28 22) Ochoa O, Pisano S, Chrysopoulo M, Ledoux P, Arishita G, Nastala C. Salvage of intraoperative  
29  
30 deep inferior epigastric perforator flap venous congestion with augmentation of venous outflow:  
31  
32 flap morbidity and review of the literature. *Plast Reconstr Surg Glob Open*. 2013 Nov 7;1(7):e52.  
33  
34  
35  
36  
37

38 23) Unukovych D, Gallego CH, Aineskog H, Rodriguez-Lorenzo A1, Mani M. Predictors of  
39  
40 Reoperations in Deep Inferior Epigastric Perforator Flap Breast Reconstruction. *Plast Reconstr Surg*  
41  
42 *Glob Open*. 2016 Aug 29;4(8):e1016. doi: 10.1097/GOX.0000000000001016. eCollection 2016 Aug.  
43  
44  
45  
46  
47

48 24) Al-Dhamin A, Bissell MB, Prasad V, Morris SF. The use of retrograde limb of internal mammary  
49  
50 vein in autologous breast reconstruction with DIEAP flap: anatomical and clinical study. *Ann Plast*  
51  
52 *Surg*. 2014 Mar;72(3):281-4.  
53  
54  
55  
56  
57  
58  
59  
60



- 1  
2  
3 25) Lee KT, Lee JE, Nam SJ, Mun GH. Ischaemic time and fat necrosis in breast reconstruction with  
4 a free deep inferior epigastric perforator flap. *J Plast Reconstr Aesthet Surg*. 2013 Feb;66(2):174-  
5  
6 81.  
7  
8  
9  
10  
11  
12 26) Marck KW, van der Biezen JJ, Dol JA. Internal mammary artery and vein supercharge in TRAM  
13 flap breast reconstruction. *Microsurgery*. 1996;17(7):371-4.  
14  
15  
16  
17  
18  
19 27) Fansa H. Internal Mammary Artery and Vein Perforator Vessels as Troubleshooter Recipient  
20 Vessels. *Plast Reconstr Surg Glob Open*. 2019; 20;7(3):e2148.  
21  
22  
23  
24  
25  
26  
27 28) Rohde C, Keller A. Novel technique for venous augmentation in a free deep inferior epigastric  
28 perforator flap. *Ann Plast Surg*. 2005 Nov;55(5):528-30.  
29  
30  
31  
32  
33  
34 29) Liu TS, Ashjian P, Festekjian J. Salvage of congested deep inferior epigastric perforator flap  
35 with a reverse flow venous anastomosis. *Ann Plast Surg*. 2007 Aug;59(2):214-7.  
36  
37  
38  
39  
40  
41  
42 30) Schaverien M, Saint-Cyr M, Arbique G, Brown SA. Arterial and venous anatomies of the deep  
43 inferior epigastric perforator and superficial inferior epigastric artery flaps. *Plast Reconstr Surg*.  
44 2008; 121(6):1909–1919.  
45  
46  
47  
48  
49  
50  
51 31) Davis CR, Jones L, Tillett RL, Richards H, Wilson SM. Predicting venous congestion before DIEP  
52 breast reconstruction by identifying atypical venous connections on preoperative CTA imaging.  
53  
54  
55  
56  
57  
58  
59  
60

1  
2  
3 32) Lee KT, Mun GH. Benefits of super-drainage using SIEV in DIEP flap breast reconstruction: A  
4 systematic review and meta-analysis. *Microsurgery*. 2017; 37(1):75-83.  
5  
6  
7  
8  
9  
10  
11  
12

13 CRediT authorship contribution statement

14  
15 Marco Pignatti: Conceptualization, Data curation, Formal analysis, Writing - original draft, Writing -  
16 review & editing. Valentina Pinto: Conceptualization, Data curation, Formal analysis, Writing -  
17 original draft.  
18  
19  
20  
21

22 Federico A. Giorgini: Conceptualization, Data curation.  
23  
24

25 Maria Elisa Lozano Miralles: Conceptualization, Data curation, Formal analysis. Salvatore D'Arpa:  
26 Conceptualization, Data curation Writing - original draft, review and editing.  
27  
28  
29

30 Riccardo Cipriani: Conceptualization, Formal analysis, Writing - review & editing.  
31  
32

33 Giorgio De Santis: Conceptualization, Formal analysis, Writing - original draft, Writing - review &  
34 editing.  
35  
36  
37  
38  
39

40 Disclosure statement:

41  
42 The authors do not have any conflict of interest to disclose  
43  
44  
45  
46

47 Funding

48  
49 This research did not receive any specific grant from funding agencies in the public, commercial,  
50 or not-for-profit sectors.  
51  
52  
53  
54  
55  
56  
57  
58  
59  
60

1  
2  
3  
4  
5  
6  
7  
8  
9  
10  
11  
12  
13  
14  
15  
16  
17  
18  
19  
20  
21  
22  
23  
24  
25  
26  
27  
28  
29  
30  
31  
32  
33  
34  
35  
36  
37  
38  
39  
40  
41  
42  
43  
44  
45  
46  
47  
48  
49  
50  
51  
52  
53  
54  
55  
56  
57  
58  
59  
60

1  
2  
3 **LEGENDS to Figures and Tables**  
4  
5  
6  
7  
8  
9

10  
11 **Figure 1**

12  
13 Flow diagram that shows selection of articles.  
14  
15

16  
17  
18 **Figure 2**

19  
20 Venous congestion in DIEP flaps.

21  
22 Articles and related forest plots dealing with the complication

23  
24 VC: number of flaps presenting Venous Congestion

25  
26  
27 The column "Cases" represents the total number of flaps where an adjunctive second vein  
28 anastomosis (SIEV-recipient vein) was performed. The column "Controls" represents the total  
29 number of flaps where a single vein anastomosis (DIEV-main vein) was performed  
30  
31  
32  
33  
34  
35

36  
37  
38 **Figure 3**

39  
40 Partial necrosis in DIEP flaps.

41  
42 Articles and related forest plots dealing with the complication

43  
44 PN: number of flaps presenting Partial Necrosis  
45  
46  
47  
48  
49

50 **Figure 4**

51  
52 Total necrosis in DIEP flaps.

53  
54 Articles and related forest plots dealing with the complication

55  
56 TN: number of flaps presenting Total Necrosis  
57  
58  
59  
60

1  
2  
3  
4  
5 **Figure5**  
6  
7

8 Need to take back to surgery for perfusion-related complications in DIEP flaps.  
9

10 Articles and related forest plots dealing with each complication  
11

12  
13 TB: number of flaps needing Take Back to surgery  
14  
15  
16

17  
18 **Figure 6**  
19

20 Fat necrosis  
21

22 Articles and related forest plots dealing with the complication  
23

24  
25 FN: number of flaps presenting Fat Necrosis  
26  
27  
28  
29  
30  
31  
32  
33

34  
35 **TABLE 1.**  
36

37 **Studies included in our meta-analysis**  
38

39  
40 OT: operating time, NA: not available, TAV: thoracoacromial vein, TDV: thoracodorsal vein, ICV:  
41  
42 intercostal vein, IMV: internal mammary vein, LTV: lateral thoracic vein, IMVr: internal mammary  
43  
44 vein retrograde branch, IMVp: internal mammary vein perforator, SCV: scapular circumflex vein,  
45  
46 SUV: subscapular vein, AV: axillary vein  
47  
48

49 "Cases": flaps with a second venous anastomosis. "Controls": flaps with a single venous  
50  
51 anastomosis  
52  
53

54 In bold are the 7 studies that were not analyzed in the previously published meta-analysis by  
55  
56 Lee<sup>32</sup>,  
57  
58  
59  
60

1  
2  
3  
4  
5  
6  
7  
8  
9  
10  
11  
12  
13  
14  
15  
16  
17  
18  
19  
20  
21  
22  
23  
24  
25  
26  
27  
28  
29  
30  
31  
32  
33  
34  
35  
36  
37  
38  
39  
40  
41  
42  
43  
44  
45  
46  
47  
48  
49  
50  
51  
52  
53  
54  
55  
56  
57  
58  
59  
60

**TABLE 2.**

**Comparison between our meta-analysis and the one from Lee and Mun**

RR: Risk Ratio. Cases: flaps with a second venous anastomosis. Controls: only one venous anastomosis

In bold are the 7 studies that were not analyzed in the previously published meta-analysis by Lee<sup>32</sup>, “Cases”: flaps with a second venous anastomosis. “Controls”: flaps with a single venous anastomosis

1  
2  
3  
4  
5  
6  
7  
8  
9  
10  
11  
12  
13  
14  
15  
16  
17  
18  
19  
20  
21  
22  
23  
24  
25  
26  
27  
28  
29  
30  
31  
32  
33  
34  
35  
36  
37  
38  
39  
40  
41  
42  
43  
44  
45  
46  
47  
48  
49  
50  
51  
52  
53  
54  
55  
56  
57  
58  
59  
60

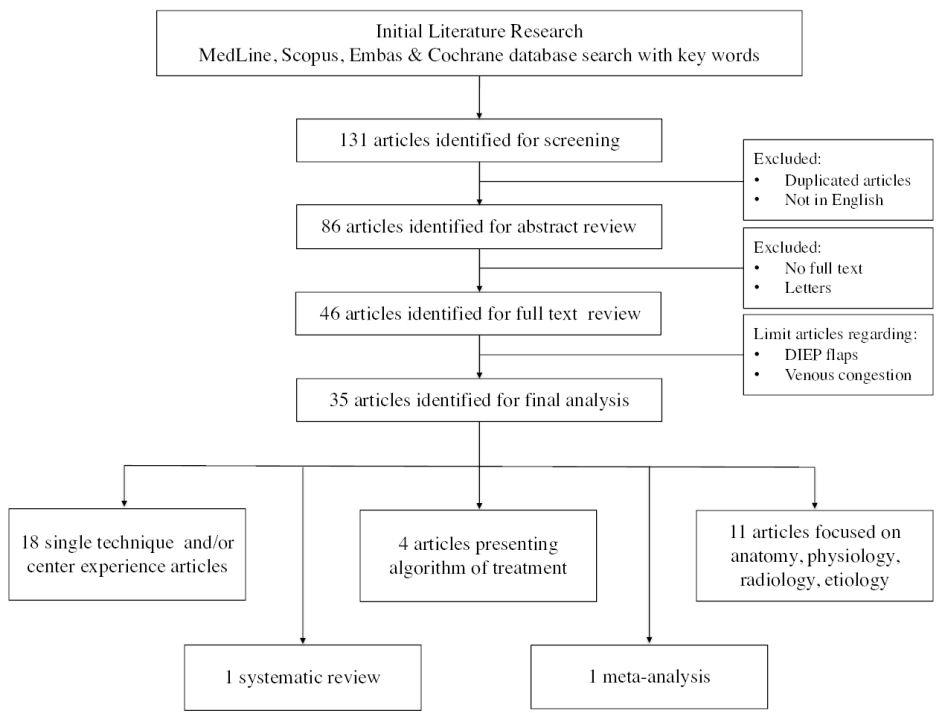


Figure 1

355x266mm (96 x 96 DPI)

1  
2  
3  
4  
5  
6  
7  
8  
9  
10  
11  
12  
13  
14  
15  
16  
17  
18  
19  
20  
21  
22  
23  
24  
25  
26  
27  
28  
29  
30  
31  
32  
33  
34  
35  
36  
37  
38  
39  
40  
41  
42  
43  
44  
45  
46  
47  
48  
49  
50  
51  
52  
53  
54  
55  
56  
57  
58  
59  
60

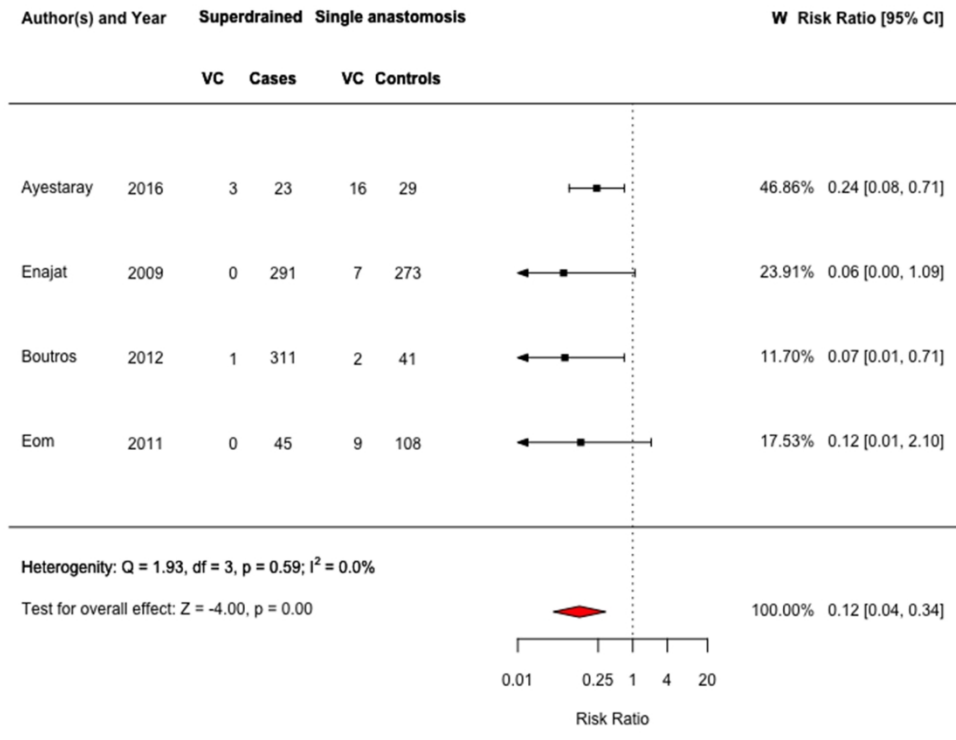


Figure 2



1  
2  
3  
4  
5  
6  
7  
8  
9  
10  
11  
12  
13  
14  
15  
16  
17  
18  
19  
20  
21  
22  
23  
24  
25  
26  
27  
28  
29  
30  
31  
32  
33  
34  
35  
36  
37  
38  
39  
40  
41  
42  
43  
44  
45  
46  
47  
48  
49  
50  
51  
52  
53  
54  
55  
56  
57  
58  
59  
60

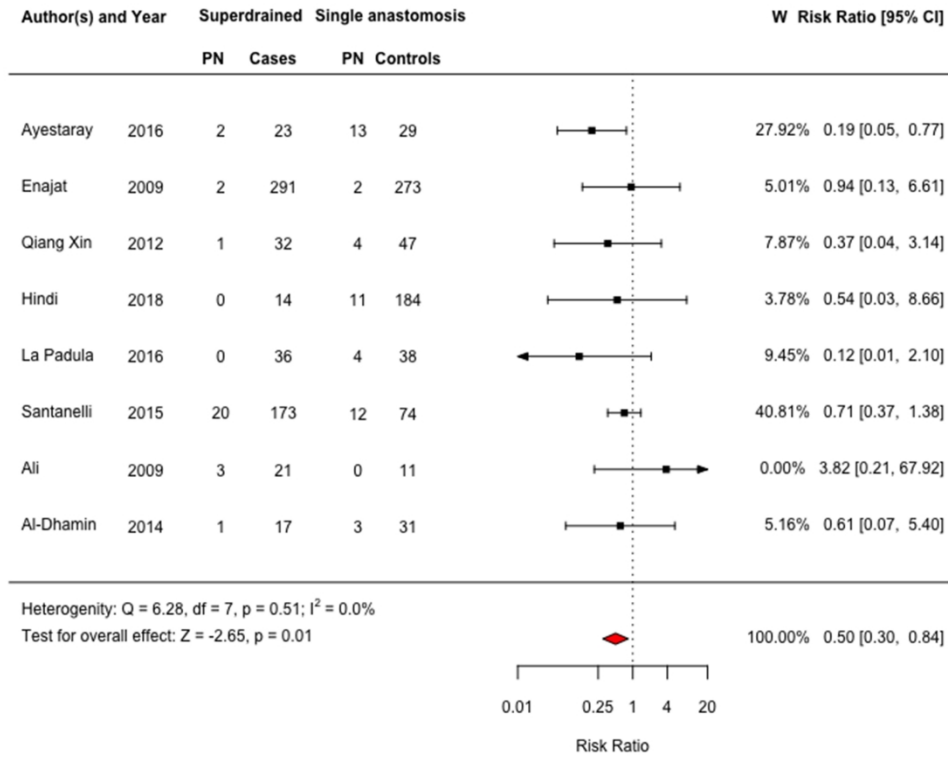


Figure 3

1  
2  
3  
4  
5  
6  
7  
8  
9  
10  
11  
12  
13  
14  
15  
16  
17  
18  
19  
20  
21  
22  
23  
24  
25  
26  
27  
28  
29  
30  
31  
32  
33  
34  
35  
36  
37  
38  
39  
40  
41  
42  
43  
44  
45  
46  
47  
48  
49  
50  
51  
52  
53  
54  
55  
56  
57  
58  
59  
60

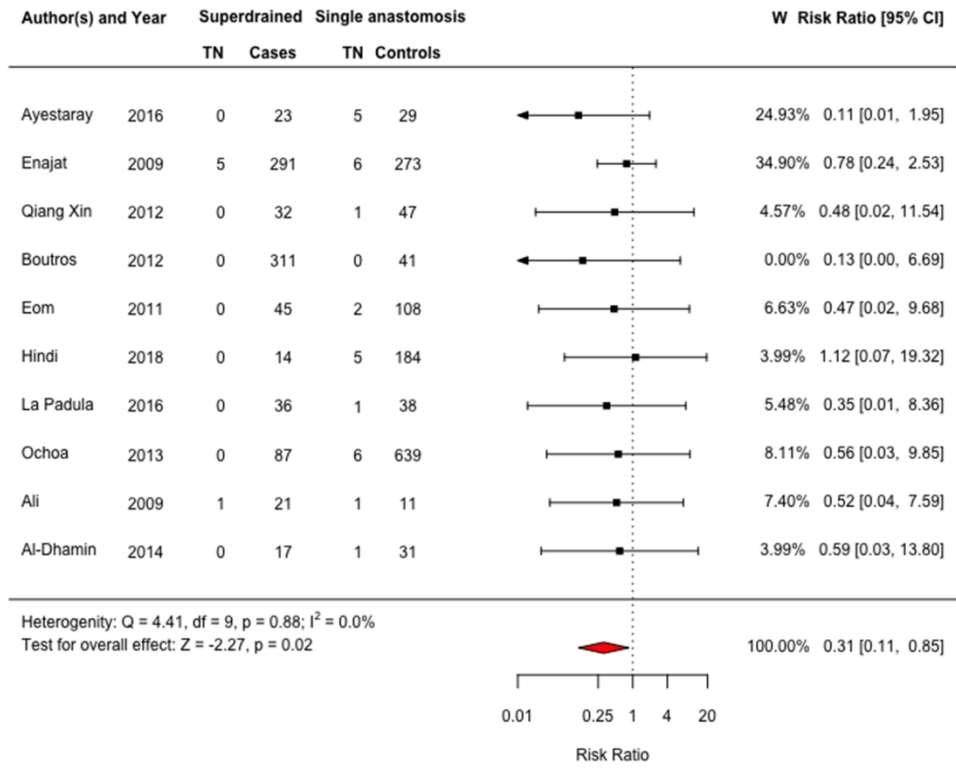


Figure 4

1  
2  
3  
4  
5  
6  
7  
8  
9  
10  
11  
12  
13  
14  
15  
16  
17  
18  
19  
20  
21  
22  
23  
24  
25  
26  
27  
28  
29  
30  
31  
32  
33  
34  
35  
36  
37  
38  
39  
40  
41  
42  
43  
44  
45  
46  
47  
48  
49  
50  
51  
52  
53  
54  
55  
56  
57  
58  
59  
60

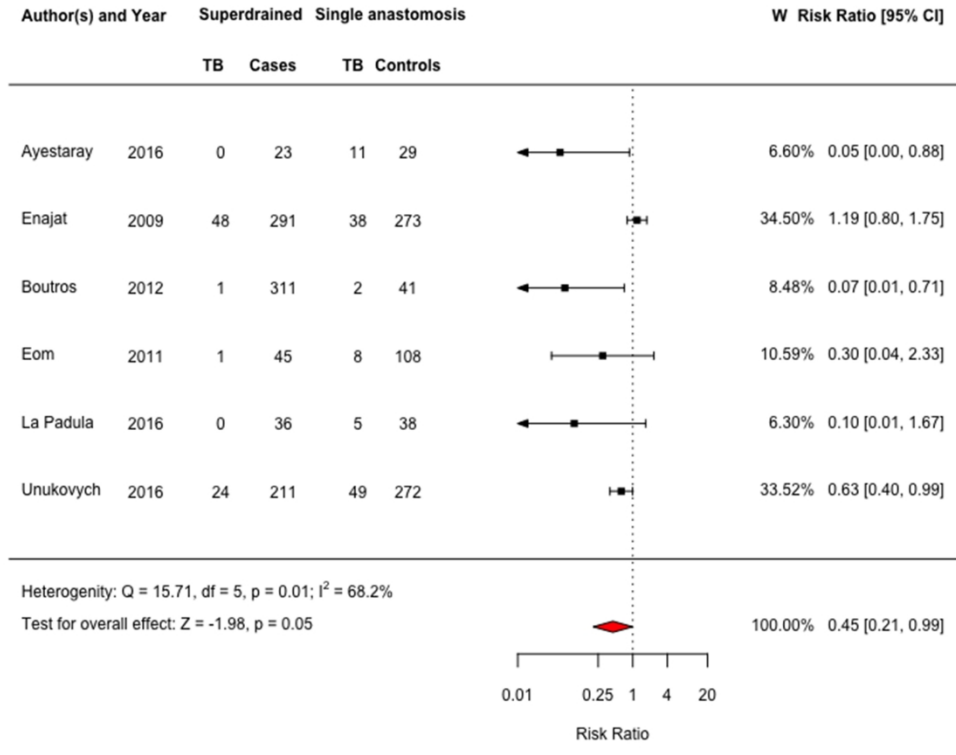


Figure 5

1  
2  
3  
4  
5  
6  
7  
8  
9  
10  
11  
12  
13  
14  
15  
16  
17  
18  
19  
20  
21  
22  
23  
24  
25  
26  
27  
28  
29  
30  
31  
32  
33  
34  
35  
36  
37  
38  
39  
40  
41  
42  
43  
44  
45  
46  
47  
48  
49  
50  
51  
52  
53  
54  
55  
56  
57  
58  
59  
60

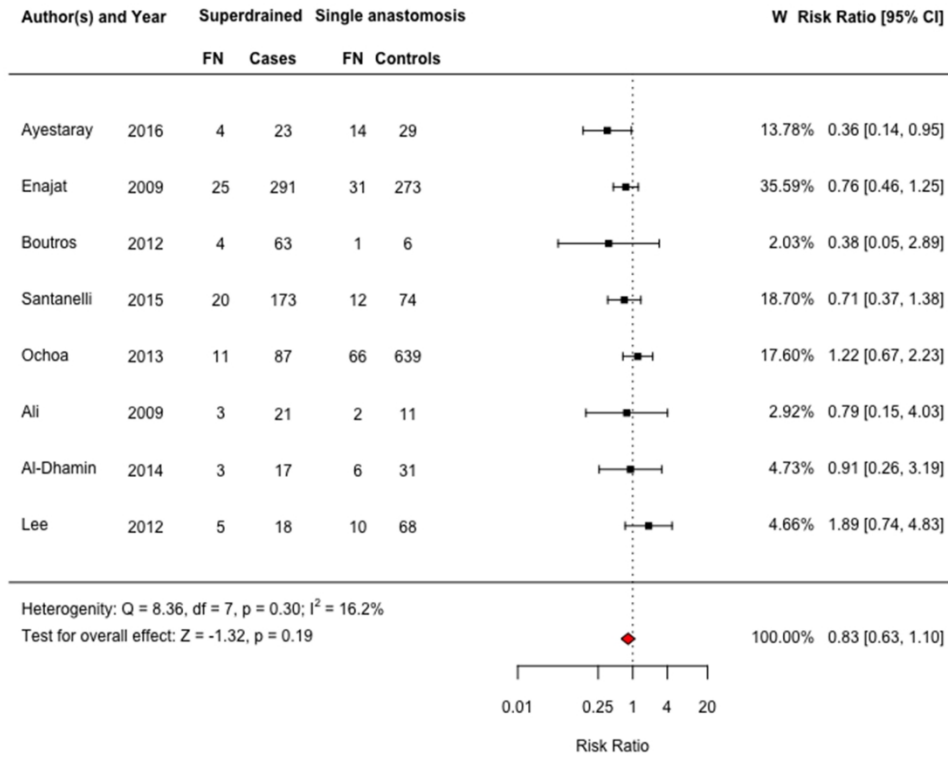


Figure 6

TABLE 1. Studies included in our meta-analysis

Study	Study type	Flap 2° vein	Recipient vein	N. cases	N. controls	Mean OT cases (minutes)	Mean OT controls (minutes)	Difference in OT (minutes)
Ali, 2010	Retrospective cohort	SIEV	IMV	21	11	Na	Na	Na
Enajat, 2010	Retrospective cohort	SIEV	Cephalic vein	291	273	383	385	- 2
Eom, 2011	Retrospective cohort	SIEV	LTV, branch of the TAV, IMVp	45	108	Na	Na	Na
Lee, 2012	Retrospective cohort	SIEV	Na	18	68	Na	Na	Na
Xin, 2012	Retrospective cohort	SIEV	TDV, LTV, ICV, SIEV, DIEV	32	47	396	366	+ 30
Boutros, 2013	Retrospective cohort	SIEV	IMVp, IMV	311	41	Na	Na	Na
Ochoa, 2013	Retrospective cohort	SIEV	IMV	87	639	314	253	+ 61
Al-Dhamin, 2014	Retrospective cohort	SIEV	IMVr	31	17	Na	Na	Na
Santanelli, 2015	Retrospective cohort	SIEV	SCV, TDV, IMV, SUV, LTV	173	74	Na	Na	Na
Ayestaray, 2016	Prospective cohort, randomized	SIEV	TAV	23	29	510	405	+ 105
La Padula, 2016	Retrospective cohort	SIEV or 2 <sup>nd</sup> DIEV	IMVr	36	38	Na	Na	Na
Unukovych, 2016	Retrospective cohort	SIEV	Na	211	272	Na	Na	Na
Al Hindi, 2019	Retrospective cohort	SIEV	Cephalic vein	14	184	461	356	+ 105

1 OT: operating time, Na: not available, TAV: thoracoacromial vein, TDV: thoracodorsal vein, ICV: intercostal vein, IMV: internal mammary vein, LTV: lateral  
2 thoracic vein, IMVr: internal mammary vein retrograde branch, IMVp: internal mammary vein perforator, SCV: scapular circumflex vein, SUV: subscapular  
3 vein, AV: axillary vein  
4

5 "Cases": flaps with a second venous anastomosis. "Controls": flaps with a single venous anastomosis  
6

7 In bold are the 7 studies that were not analyzed in the previous published metanalysis by Lee, 2017  
8  
9  
10  
11  
12  
13  
14  
15  
16  
17  
18  
19  
20  
21  
22  
23  
24  
25  
26  
27  
28  
29  
30  
31  
32  
33  
34  
35  
36  
37  
38  
39  
40  
41  
42  
43  
44  
45  
46

	<b>Lee and Mun, 2017</b>	<b>Pignatti et al, 2020</b>
<i>Articles included</i>	Enajat, 2010 Lee, 2012 Xin, 2012 Santanelli, 2015 Boutros, 2013 Al-Dhamin, 2014	Ali, 2010 Enajat, 2010 <b>Eom, 2011</b> Lee, 2012 Xin, 2012 Boutros, 2013 <b>Ochoa, 2013</b> Al-Dhamin, 2014 Santanelli, 2015 <b>Ayestaray, 2016</b> <b>La Padula, 2016</b> <b>Unukovich, 2016</b> <b>Al Hindi, 2019</b>
<i>Statistical Analysis</i>	Pooled RRs and corresponding 95% confidence intervals (CI) for perfusion-related complications were calculated by the Mantel–Haenszel test in RevMan 5.3. The heterogeneity among studies was evaluated with the I2 test. When I2 ranged from 0 to 30% a fixed- effects model was used. When the value of I2 exceeded 30%, a random effect model was used.	The Mantel-Haenszel test in R was used to calculate Pooled RRs and corresponding 95% confidence intervals (CI) for perfusion-related complications. The heterogeneity among studies was analyzed by using the I2 test. We used a fixed-effects model for I2 ranging from 0 to 30%; in the case of I2> 30%, we applied a random effect model using the DerSimonian & Liard method.
<i>N. of flaps. TOTAL</i> - <i>N. of cases</i> - <i>N. of controls</i>	1376 - 842 - 534	3094 - 1279 - 1815
<i>Total flap loss</i>	RR: 0.97, 95% CI: 0.36-2.57; p = 0.94	<b>RR: 0.31, 95% CI: 0.11-0.85; p = 0.023</b>
<i>Partial flap lost</i>	RR: 0.59, 95% CI: 0.18-1.94; p = 0.39	<b>RR: 0.50, 95% CI: 0.30-0.84; p = 0,008</b>
<i>Fat necrosis</i>	RR: 0.87, 95% CI: 0.58-1.30; p = 0.49	RR: 0.83, 95% CI: 0.63-1.10; p = 0.19
<i>Venous congestion</i>	<b>RR: 0.06, 95% CI: 0.01-0.51; p = 0.01</b>	<b>RR: 0.12, 95% CI: 0.04-0.34; p &lt; 0,001</b>
<i>Conclusion</i>	“The present review demonstrated that superdrainage using SIEV reduces the risk of flap congestion notably, while having little influence on flap survival. With regard to partial flap necrosis including partial flap loss and fat necrosis, general trends toward decreased risks were observed.	“In conclusion, our meta-analysis shows, that venous super-drainage, i.e. performing a second venous anastomosis between the superficial venous system and a recipient vein, provides a statistical advantage in terms of venous congestion and related complications in DIEP flaps

1  
2  
3  
4  
5  
6  
7  
8  
9  
10  
11  
12  
13  
14  
15  
16  
17  
18  
19  
20  
21  
22  
23  
24  
25  
26  
27  
28  
29  
30  
31  
32  
33  
34  
35  
36  
37  
38  
39  
40  
41  
42  
43  
44  
45  
46  
47  
48  
49  
50  
51  
52  
53  
54  
55  
56  
57  
58  
59  
60

	However, statistical significance was not achieved and further studies would be needed."	for breast reconstruction."
--	--	-----------------------------

TABLE 2. Comparison between our meta-analysis and the one from Lee and Mun

RR: Risk Ratio. Cases: flaps with a second venous anastomosis. Controls: only one venous anastomosis  
The 7 studies that were not analyzed in the previous published metanalysis by Lee, 2017 appear in **bold**.  
In the fourth row, the results with statistical evidence appear in **bold**.