

The 14th Nordic Conference
on Reindeer and Reindeer Husbandry Research
Vantaa, Finland, 20th -22nd March 2006

Rangifer Report No. 12 (2007): 91-94

Extended abstract¹

Setaria tundra outbreak in reindeer in Finland²

Sauli Laaksonen & Antti Oksanen

National Veterinary and Food Research Institute EELA, Oulu Regional Department (FINPAR), P.O.Box 517, FIN-90101 Oulu, Finland (Sauli.Laaksonen@evira.fi).

Introduction

Setaria tundra was first described in semi-domesticated reindeer in Arkhangelsk area, Russia in 1928. *Setaria* sp. infections appear to have emerged in Scandinavian cervids in the late 1960s. In 1973, *S. tundra* was observed for the first time in northern Norway where there was an outbreak of peritonitis in reindeer. Also in 1973, tens of thousands of reindeer died in the northern part of the Finnish reindeer husbandry area. Severe peritonitis and large numbers of *Setaria* sp. worms were commonly found. Following this, the incidence of *Setaria* sp. in reindeer in Scandinavia diminished.

Outbreaks in the 2000s

According to meat inspection data and clinical reports from practising veterinarians, an outbreak of peritonitis in reindeer in the southern and middle part of the Finnish reindeer herding area emerged in 2003. The outbreak was caused by the filarioid nematode *Setaria* sp. In the province of Oulu, the proportion of reindeer viscera condemned due to parasitic lesions in meat inspection increased from 4.9% in 2001 to 40.1% in 2003. In 2004 the focus of the outbreak moved approximately 100 km north and in the year 2005 the spreading continued to the north about 100 km so that only the reindeer in the northernmost small part of Finland were free of changes. In the same time the outbreak seems to have settled in the southern area (Fig. 1, Tab. 1; all figures in appendix).

Table 1. Number of reindeer inspected and viscera condemned because of parasite lesions according to meat inspectors' monthly reports from the northern part of Lapland (8 slaughterhouses) and from southern part (4 slaughterhouses) in 2003, 2004 and preliminary data 2005.

Area	Year	Reindeer inspected	Viscera condemned	%
Northern part of Lapland	2003	35 638	86	0.2
	2004	27 175	1013	4
	2005	10 931	2171	20
Southern part of Lapland	2003	15 354	1943	13
	2004	14 238	5721	40
	2005	5 856	3716	63

Studies in Kuusamo

In Kuusamo, 2511 and 2103 slaughtered reindeer were clinically examined both *ante* and *post mortem* in 2003 and 2004, respectively. *Setaria* sp. nematodes were counted and the degree of peritonitis was evaluated. Tissue, muscle and peritoneal fluid samples for histological and bacteriological studies and for meat hygiene analyses were collected. A total of 260 adult and pre-adult *Setaria* nematodes were collected for morphological and molecular studies. The parasite was morphologically and molecular biologically indistinguishable from *Setaria tundra*.

Clinical findings

Peritonitis (Fig. 2) was common both in adults and calves but the degree of peritonitis was much more severe in calves. The habitus of heavily infected calves expressed decreased welfare; low body condition and undeveloped winter coat (Fig. 3). The meat inspection findings of peritonitic reindeer carcasses included ascites fluid, green fibrin deposits, adhesions and live and dead *S. tundra* nematodes (Fig. 4).

¹ Abstract in Finnish entitled *Setaria tundra* – sukkulamadon aiheuttama porojen vatsakalvon tulehdus Suomessa, see – *Rangifer* Report No. 11 (2006): 80

² This presentation is based on manuscript: Laaksonen, S., Kuusela, J., Nikander, S., Nylund, M. & Oksanen, A. 2006. Parasitic peritonitis outbreak in reindeer (*Rangifer tarandus tarandus*) in Finland. – *Vet. Rec.*, accepted 2006.

Other results

Histopathologically, changes indicated granulomatous peritonitis with lymphoplasmacytic and eosinophilic infiltration (Fig. 5). No specific bacterial growth was found. No significant impact on meat pH values nor on organoleptic evaluation of meat was found. There was a significant positive correlation between worm count and the degree of peritonitis and a negative correlation between the degree of peritonitis and back fat layer.

Studies of wild cervids

In order to monitor the parasite dynamics in nature, parasite samples from wild cervids were also collected (moose, white-tailed deer, roe deer and wild forest reindeer). In moose only few cases of pre adult encapsulated *S. tundra* nematodes on the surface of the liver but no peritonitis were detected. Two roe deer examined fresh in the field had *S. tundra* nematodes in abdomen but no peritonitis. Of 34 wild forest reindeer, 62% had changes associated with *S. tundra*. It is not known if the high percentage of wild forest reindeer shot in Kainuu with signs of peritonitis caused by *S. tundra* is connected to the decrease of the population from 1700 individuals in 2001 to 1000 in 2005.

Conclusion

The present study revealed that *S. tundra* can act as a significant pathogen for reindeer, which was evident at both *ante* and *post mortem* inspection and in histological examination

Manuscript received 20 June 2006

Appendix:

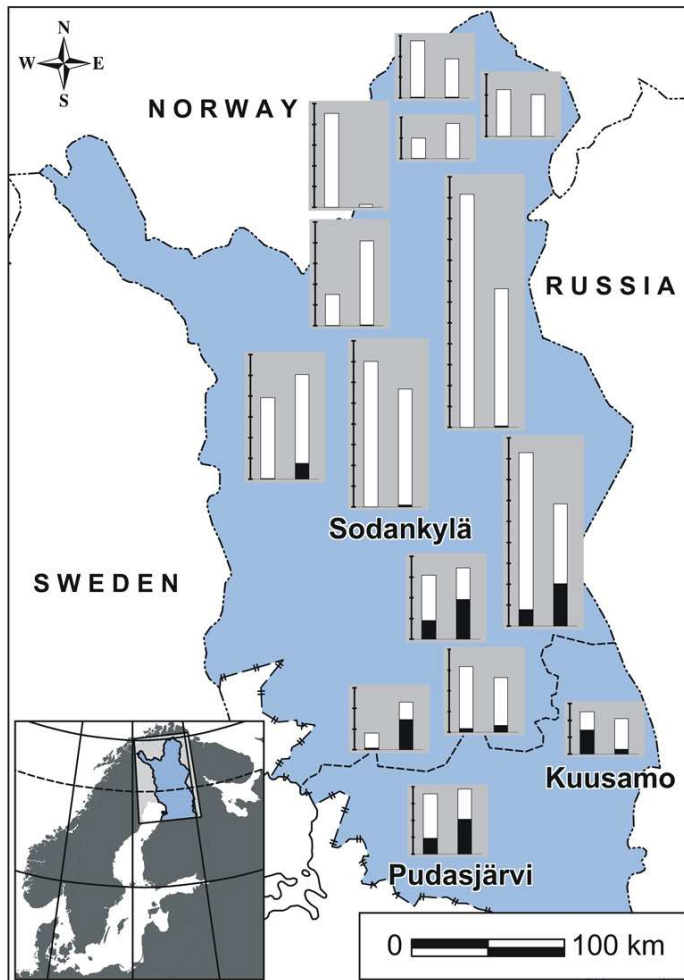


Fig. 1. Finnish reindeer herding area (grey shaded) and the number of reindeer slaughtered (tickmarks indicate 1000s) in different slaughterhouses in years 2003 (left) and 2004 (right). Visceral organs condemned (black). The province of Oulu below and province of Lapland above the dash line (---). The slaughterhouse of Rovaniemi, and two small slaughterhouses omitted because of not defined (not local) area of reindeer purchase.

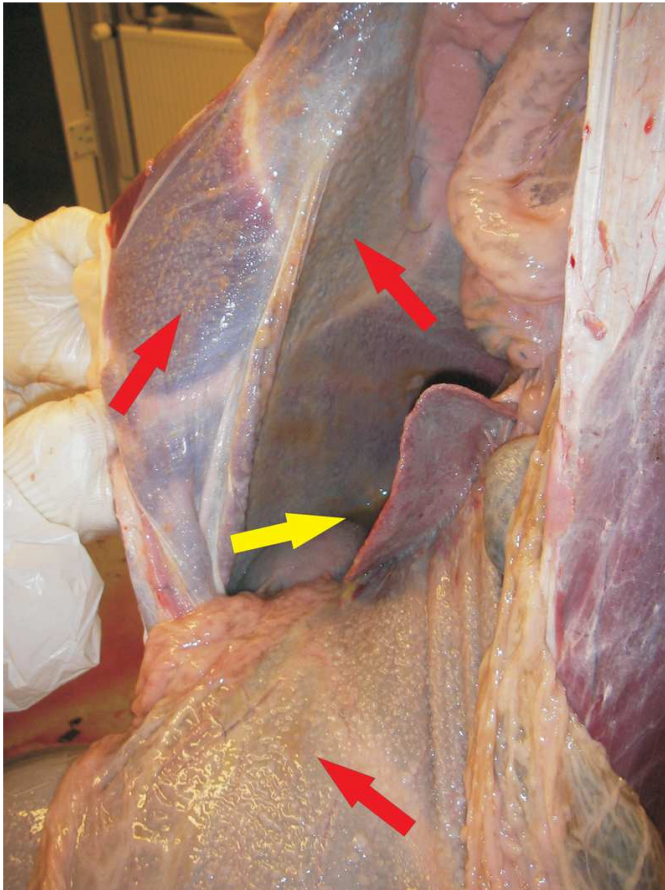


Fig. 2. Fibrin membranes covering the peritoneum and visceral organs (dark arrows) and straw coloured ascites fluid (pale arrow) giving an impression of purulent process.



Fig. 3. Reindeer calf suffering from heavy *Setaria tundra* infection. Note poor body condition with poor fur quality and distended abdomen.

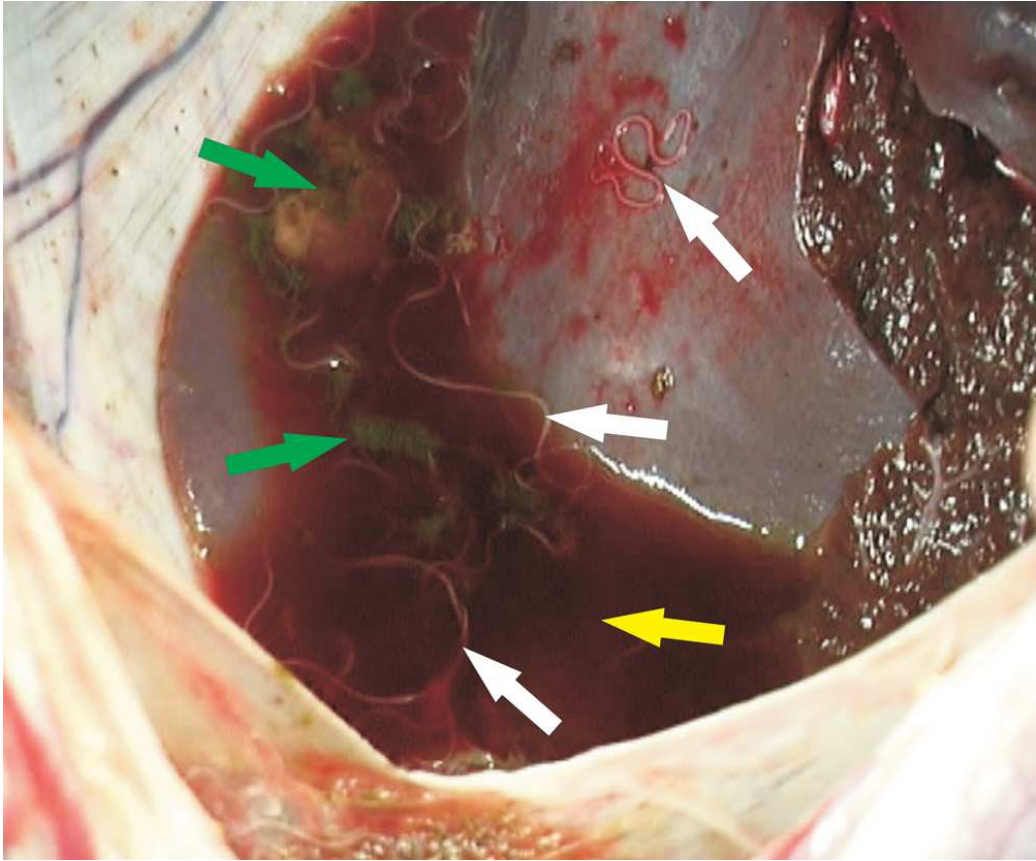


Fig. 4. Ascites fluid (pale arrow) in the peritoneal cavity of a reindeer calf with green fibrin formation (dark arrows) and *Setaria tundra* nematodes (white arrows).

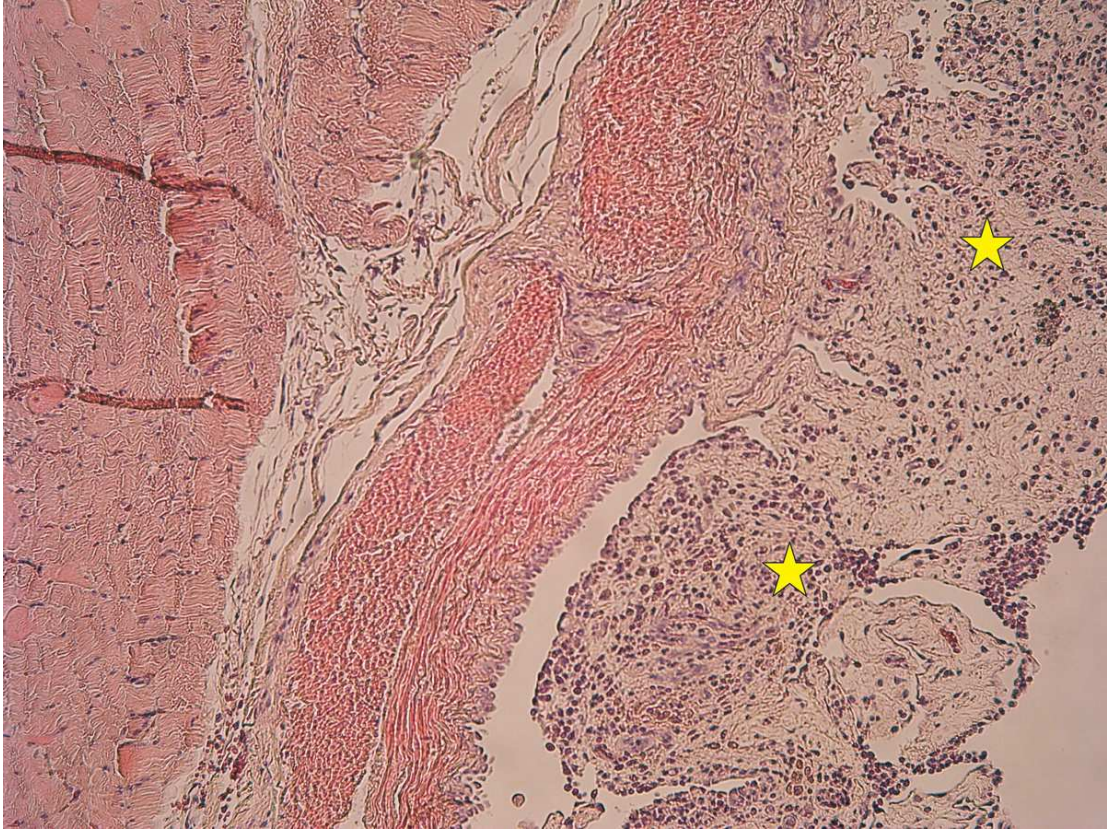


Fig. 5. Chronic granulomatous peritonitis caused by *Setaria tundra*. Fibrous thickening (stars) of the peritoneum with lymphoplasmacytic and eosinophilic infiltrations.