

Natural Infection by *Trypanosoma cruzi* in a Dog from Bahia State - Northeast of Brazil

Kaíque Pires Moura da Silva¹, Valquíria Tatiele da Silva Rodrigues¹, Gilmar José da Silva Ribeiro Junior²,
Ianei de Oliveira Carneiro³, Deusdete Conceição Gomes Júnior¹ & Layze Cilmara Alves da Silva Vieira¹

ABSTRACT

Background: Chagas Disease (CD) is a parasitic anthroponosis caused by the *Trypanosoma cruzi* (*T. cruzi*), a protozoan transmitted by insects from the Reduviidae family. Several species of wild and domestic animals, humans included, are susceptible, developing acute clinical signals (myocarditis and cardiac arrhythmias) or chronic signals (drop on the performance and syncope) of the disease. In Brazil, the disease in dogs shows variable indexes of occurrence. The present paper describes the natural infection by *T. cruzi* in a canine living in the city of Barra, in the state of Bahia, Brazil, a region classified as high risk of vulnerability for the CD in the northeast of Brazil.

Case: A 9-year-old male dog, non-specific breed, was referred to the clinic the Veterinary Clinic for Small Animals, at the Veterinary Medical Teaching Hospital), at the Federal University of the West of Bahia. Its owner reported the presence of bloody secretion in the penile region. During the physical exam it was possible to observe an increase in the volume of the penis base. All of the animal's physiological parameters were within normal levels. Blood samples and cytological laminas from the lesioned area were collected and sent to the Laboratory of Veterinary Clinical Pathology in the same institution. The cytological exam showed monomorphic population of great round cells with a round nucleus, condensed chromatin and one to two prominent nucleolus, abundant and slightly basophilic cytoplasm, with multiple stippled vacuoles, thus confirming a Transmissible venereal tumor (TVT) case. With the blood exam one observed a thrombocytopenia, neutrophilia with a deviation on the left and the presence of a trypomastigote form of *Trypanosoma* sp. in the blood smears. A complete blood sample was sent to the Laboratory of Pathology and Molecular Biology from the Fiocruz-BA (Oswaldo Cruz Foundation in the State of Bahia), being identified by the PCR technique, *T. cruzi*.

Discussion: During the complete blood count, specifically using the blood smear, the microscopic visualization of the trypomastigote form of the *Trypanosoma* sp., a hemoparasite of filiform aspect, with undulating membrane over the whole body and free flagellum, confirming a case of trypanosomiasis. Such diagnostics had not been considered up to this moment, as the animal did not present any clinic symptomatology that indicated the pathological condition. The high levels of parasitemia presented by the animal, confirmed by the presence of the protozoan in the blood smear, probably indicate the acute phase of the infection, period in which the multiplication and development of the agent is higher, consequently allowing the visualization of the hemoparasite in the lamina. Although the TVT had proved to be the main derogatory factor of sanity and wellbeing of the animal, one calls the attention in this case for the trypanosomiasis, a zoonosis that causes great risk to the sole health, highlighting that the canine species is taken as an important reservoir of *T. cruzi*, relevant for the maintenance and interaction among the domestic and wild cycles of the Chagas Disease. This is the first report of a canine naturally infected by *T. cruzi* in the west Region of the State of Bahia. It is, thus, important to emphasize its significance once dogs can be reservoirs of the protozoan, acting in their life cycle and epidemiological chain of the Chagas Disease, enabling the infection of triatomines and humans. Future studies should be done with the purpose of determining the predominance of the agent in the region of the city of Barra, in the State of Bahia.

Keywords: Chagas Disease, dogs, protozoan, reservoir.

DOI: 10.22456/1679-9216.103250

Received: 23 May 2020

Accepted: 30 October 2020

Published: 19 November 2020

¹Federal University of the West of Bahia (UFOB), Barra, BA, Brazil. ²Laboratory of Pathology and Molecular Biology from the Gonçalo Muniz Institute - Fiocruz, Salvador, BA. ³Salvador University (UNIFACS), Salvador BA. CORRESPONDENCE: L.C.A.S. Vieira [layze.cilmara@hotmail.com]. Federal University of the West of Bahia - UFOB. Av. 23 de Agosto n. 872. CEP 47100-000 Barra, BA, Brazil.

INTRODUCTION

The Chagas Disease (CD) is a parasite anthrozoosis, caused by *Trypanosoma cruzi* (*T. cruzi*) [17]. The CD, or American trypanosomiasis, affects approximately 7 million people around the planet [32]. Approximately 1.2 million documented people are infected in Brazil, which occupies the second place in the ranking of the countries with high levels of infected people, behind only Argentina [31]. The *Trypanosoma cruzi* can infect a wide range of mammal hosts, including domestic dogs. The natural infection of dogs living in the endemic areas, whether it is urban or rural, has been reported in Louisiana [7], Costa Rica [2] in regions of Colombia [15] and in the northeast of Brazil [18]. Papers have shown status indexes that vary from 0.3% to 22.7% all over Brazil [16,25,27,28]. The clinical course of the infection by *T. cruzi* in canines is like the pattern of cardiologic disease in humans. Young dogs may present an acute phase with signs of myocarditis, cardiac arrhythmias and respiratory difficulty. In the chronic phase, on the other hand, intolerance to exercises and syncope are found [26].

The diagnostic of the infection by *T. cruzi* in dogs may be by direct microscopy, making it possible to identify the flagellum in the blood, depending on the parasitisms [14], serological tests (isotopes detection of IgG and IgM) and molecular (polymerase chain reaction - PCR) [1,8,26].

The present study describes the natural infection by *T. cruzi* in a canine (*Canis lupus familiaris*) living in a region classified as in high vulnerability risk for CD in the northeast of Brazil [23,24].

CASE

A 9-year-old male dog, non-specific breed, and weighing 29 kg was attended at the Veterinary Medical Clinic for Small Animals (CMPA), at the University Veterinary Hospital (HVU), from the Federal University of the West of Bahia (UFOB). According to his owner, the animal presented a bloody secretion originating from the penis. When a physical examination was performed, an increase in the volume of the penis base was observed, which suggested a venereal transmissible tumor (TVT), a common affection among intact dogs which mate or have contact with contaminated animals. All of the physiological parameters of the animal were within the normality indexes – lymph nodes without reactivity, pink mucous membranes,

temperature, normal cardiac and respiratory frequency. Blood samples and cytological laminas from the lesioned area were collected and sent to the Laboratory of Veterinary Clinic Pathology in the same institution.

The cytological exam showed monomorphic population of large round cells with a round nuclei, condensed chromatin and between one and two prominent nucleolus, abundant and slightly basophilic cytoplasm with multiple stippled vacuoles, confirming thus a TVT case (Figure 1).

In the hematological test the following was observed: thrombocytopenia, neutrophilia with a deviation to the left and the presence of a flagellum in its trypomastigote evolutionary form in the direct microscopy (Figure 2). Taking into consideration the epidemiologic history in the region, a complete blood sample was sent to the Laboratory of Pathology and Molecular Biology from the Gonçalo Muniz Institute (LPBM - Fiocruz, BA) for the *T. cruzi* molecular diagnostic.

The extraction of the genetic material was carried out with 200 µL of total blood using the PureLink¹ Genomic DNA Mini Kit, following the manufacturers' instructions. A conventional PCR was conducted according to the protocol established by Ribeiro Jr. et al. [21], using specific primers for the region of Mini-exons (Mini-exon gene intergenic spacer, F: 5'- AAG GTG CGT CGA CAG TGT GG -3'; R: 5'- TTT TCA GAA TGG CCG AAC AGT -3', 150-200 pb) and the COII gene (Cytochrome oxidase subunit II, F: 5'- CCA TAT ATT GTT GCA TTA TT -3'; R: 5'- TTG TAA TAG GAG TCA TGT TT -3', 375 pb). The reagents used for the amplification were Qiagen²

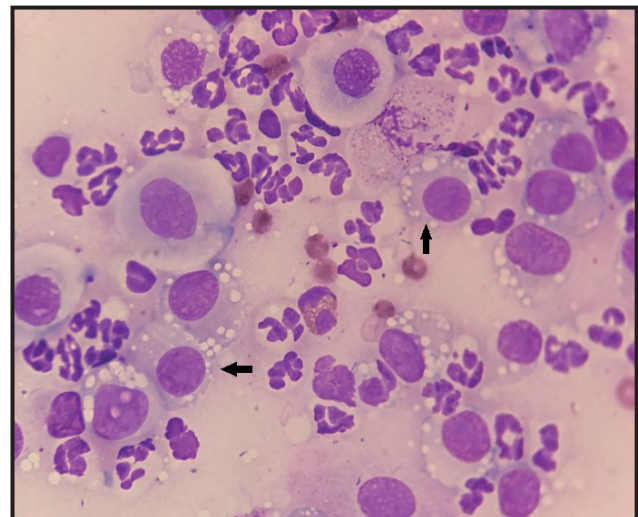


Figure 1. Cytology. Transmissible Venereal Tumor (TVT). One can observe the presence of round cells with round nuclei, abundant and slightly basophilic cytoplasm with multiple stippled vacuoles (black arrows) [Fast panoptic; Obj.100x].

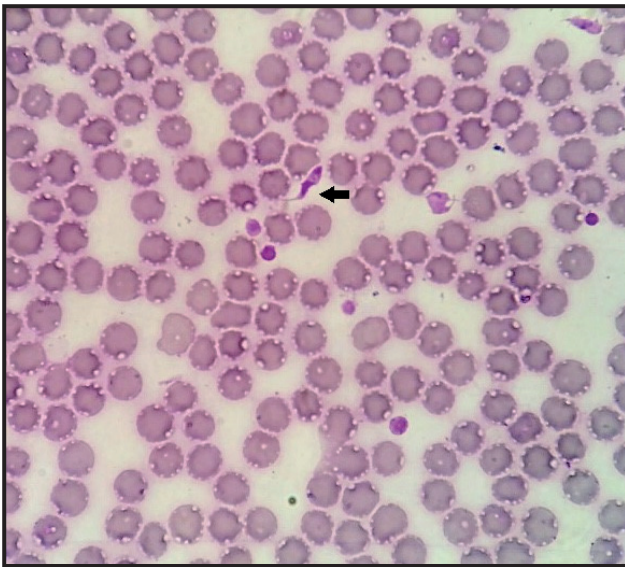


Figure 2. Blood Swab. One can observe the presence of the trypomastigote form of *Trypanosoma cruzi* (black arrow) [Fast panoptic; Obj.100x].

Master mix, 1X; primers, 0.1 μ M; H₂O (Qiagen²); DNA, 1 μ L (~100 ng/ μ L), in a final reaction volume of 25 μ L. The thermocycling occurred in the MasterCycle Gradiante³, with initial denaturation at 94° C for 3 min; 40 cycles of 94° C for 30 s, 60° C for 30 s and 72° C for 1 min; with final elongation of 72° C for 10 min. The amplicons produced were visualized in agarose gel 1.5%, through the conventional electrophoresis according to Ribeiro Jr. et al. [21]. A scale of 100 bp DNA (Invitrogen⁴) was used as a molecular size pattern. Through molecular technique, the identification of the *T. cruzi* was confirmed.

No compatible clinical sign with the Chagas Disease was detected. The execution of complementary image and electrocardiogram exams was not possible due to lack of resources. The guidance regarding the condition of the canine bearer of *T. cruzi* was given to his owner, as well as the explanations about the zoonotic potential of the disease. The subject did not return for the conduction of the medical therapy for the TVT regression.

DISCUSSION

Through the present report it is significant the importance of complementary diagnostic tests in the routine of veterinary clinics and hospitals. One could observe that the anamnesis and the physical state of the evaluated animal indicated signs of genital affection which was confirmed by cytological exams. Although the TVT constituted the main derogatory fact in the sanity and well-being of the animal, with the conduction of the hematologic exam, based on the

blood swab technique, the microscopic visualization of the trypomastigote form of the *Trypanosoma* sp. was possible. That is a hemoparasite with a filiform aspect, with a rippling membrane all over its body and free flagellum [3], thus confirming a case of trypanosomiasis. This diagnostic which had not been thought of up to that moment once the animal did not present any symptomatology which might have indicated the pathological frame, which corroborates with already proven studies, where dogs are seen as asymptomatic bearer of the protozoan [22].

One must emphasize that the canine species is seen as an important vessel of *T. cruzi*, with highlighted role in the maintenance and interaction between the domestic and wild cycles of the Chagas Disease [4,27]. Thus, one must call attention to this case of risk to the One Health, since the contact of this dog with triatomines, enables the perpetuation and transmission of the disease to other susceptible animals and humans.

In this case, similar to what had been mentioned by other authors, it was not possible through blood swab exam to differentiate between the species *Trypanosoma* sp. This is due to the great morphological similarity, which proves the necessity for the molecular diagnostic [5], the former carried out through PCR technique (which is as sensitive as the xenodiagnosis) [8], and in this case one confirmed the infection by *T. cruzi*. The high sensitivity of the molecular test is a strong complementary diagnostic tool to the serological test, providing the substitution of the xenodiagnosis or the blood culture in the laboratory analyses [8].

The hemogram reading revealed thrombocytopenia, associated in the literature to the reduction of the platelets survival in the animal organism, these lysed in the presence of protozoan in the blood circulation [5,22]. Neutrophilia with a when facing infectious processes [30].

The high levels of parasitemia presented by the animal, confirmed by the presence of the protozoan in the blood swab probably indicate the acute phase of the infection [17,3], period in which the multiplication and development of the agent is greater [11,27], consequently allowing the visualization of the hemiparasite more easily. One hypothesis that is raised is that due to the genital affection and the stress levels (chronic insinuation caused by the initial illness) a high release of cortisol, inflammatory mediators and catecholamines (among other stressful factors) provides conditions for immunosuppression of the organism defense cells [19,20,30] which

resulted in small and constant failures in the decrease of the illness (parasitosis) [13,19], even though the animal presented normal physiological parameters.

The TVT neof ormation cytological exam [9,10,29] corroborates with the cytological findings in the present report.

The epidemiologically TVT is associated with some predisposing factors (free access to the street without the owner's presence, agglomeration lack of control of the population of stray dogs in the cities) [9,10,12], which, according to the owner's report, were present in the animal's routine.

According to the State Health Department from the State of Bahia (SESAB), Brazil and the informal report from dwellers of the urban and rural areas of the municipality of Barra, region the West of the State of Bahia, there are frequent visualization of triatomines in coops and houses (both around in inside the houses). The macro-region of the West of the State of Bahia has high indexes of CD [23,24], presenting elevated risk of transmission of the vectorial infection, for susceptible humans and animals [22], which is possibly a major factor for the occurrence of the canine infection in the present report.

Taking into consideration the absence of clinical symptomatology of trypanosomiasis in the animal, one proposed that the owner of the canine should receive TVT treatment. Additionally, measures for the containment of the diseases were recommended having in mind its infectious potential either venereal (TVT) [12,29] or parasitic (Chagas Disease) [3,18].

This is the first report of a canine infected naturally by *T. cruzi* in the West region of the State of Bahia. It is important to highlight that these dogs can be reservoirs for the protozoan, acting in the life cycle and the epidemiological chain of the Chagas Disease, enabling the infection of triatomines, both by contact with animals and humans. Further studies should be carried out in order to determine the prevalence of the agent in the region of Barra, State of Bahia, Brazil.

MANUFACTURERS

¹Thermo Fisher Scientific Brasil Instrumentos de Processo Ltda.

Alto de Pinheiros, SP, Brazil.

²Qiagen. Hilden, NW, Germany.

³Eppendorf do Brasil Ltda. São Paulo, SP, Brazil.

⁴Thermo Fisher Scientific Inc. Carlsbad, CA, USA.

Declaration of interest. The authors report no conflicts of interest. The authors alone are responsible for the content and writing of the paper.

REFERENCES

- 1 Britto C., Silveira C., Cardoso M.A., Marques P., Luquetti A., Macêdo V. & Fernandes O. 2001. Parasite persistence in treated chagasic patients revealed by xenodiagnosis and polymerase chain reaction. *Memórias do Instituto Oswaldo Cruz*. 96(6): 823-826.
- 2 Bonilla M.C., Castro-Vásquez R.M., Herrero-Acosta M.V., Urbina-Villalobos A. & Dolz G. 2019. Canine trypanosomiasis in an endemic Costa Rican community: Demonstration of the active infection cycle. *Veterinary Parasitology: Regional Studies and Reports*. 17: 100307. [Available at: <<https://www.sciencedirect.com/science/article/abs/pii/S2405939018302119>>].
- 3 Carneiro M.E. 2017. Protozoário Flagelados. In: Monteiro S.G. (Ed). *Parasitologia na Medicina Veterinária*. 2.ed. Rio de Janeiro: Roca, pp.133-1441.
- 4 Crisante G., Rojas A., Teixeira M.M.G. & Añez N. 2006. Infected dogs as a risk factor in the transmission of human *Trypanosoma cruzi* infection in western Venezuela. *Acta Tropica*. 98(3): 247-254.
- 5 De Sá M.A.R., Ruschel M.L., De Jesus K.W.A., Santos P.O.M. & Rocha L.B. 2015. Infecção Canina por *Trypanosoma* sp. em Sergipe, Brasil. *Revista Enciclopédia Biosfera: Centro Científico Conhecer*. 11(21): 1-10.
- 6 Desquesnes M., Dargantes A., Lai D.H., Lun Z.R., Holzmuller P. & Jittapalpong S. 2013. *Trypanosoma evansi* and surra: a review and perspectives on transmission, epidemiology and control, impact, and zoonotic aspects. *BioMed Research International*. 2013: 321237. [Available at: <<https://www.ncbi.nlm.nih.gov/pmc/articles/PMC3789323/>>].
- 7 Elmayan A., Tu W., Duhon B., Marx P., Wolfson W., Balsamo G., Herrera C. & Dumonteil E. 2019. High prevalence of *Trypanosoma cruzi* infection in shelter dogs from Southern Louisiana, USA. *Parasites Vectors*. 12: 322. [Available at: <<https://parasitesandvectors.biomedcentral.com/articles/10.1186/s13071-019-3572-y>>].
- 8 Enriquez G.F., Cardeal M.V., Orozco M.M., Schijman A.G. & Gürtler R.E. 2013. Detection of *Trypanosoma cruzi* infection in naturally infected dogs and cats using serological, parasitological and molecular methods. *Acta Tropica*. 126(3): 211-217.

- 9 Ferreira M.A.Q.B., Teixeira M.N., Teixeira C.C.D., Paiva B.H.A., Silva V.C.L., Fukahori F.L.P, Rêgo M.S.A, Dias M.B.M.C. & Lima E.R. 2017. Aspectos clínicos, hematológicos, bioquímicos e citopatológicos do tumor venéreo transmissível em cães tratados com sulfato de vincristina. *Medicina Veterinária*. 11(1): 8-17.
- 10 Filgueira K.D., Peixoto G.C.X., Fonseca Z.A.A.S. & De Paiva A.L. C. 2013. Tumor venéreo transmissível canino com múltiplas localizações extragenitais. *Acta Scientiae Veterinariae*. 41(Suppl 1): 1-6.
- 11 Fiocruz (Portal da Doença de Chagas). Resposta Imune (Doença de Chagas). Available at: <http://chagas.fiocruz.br/resposta-imune/>. [Accessed online in April 2020].
- 12 Landi U.N., Borges T.B., Quessada A.M., Borges J.L., De Oliveira D. H., Zaniolo M.M., Sala P.L. & Ribeiro R.C.L. 2014. Obstrução uretral aguda causada por tumor venéreo transmissível em um cão. *Acta Scientiae Veterinariae*. 45(Suppl 1): 212.
- 13 Laurino F. 2009. Alterações hematológicas em cães e gatos sob estresse. 18f. São Paulo. Monografia (Bacharelado em Medicina Veterinária) - Faculdade de Medicina Veterinária e Zootecnia, Universidade Estadual Paulista.
- 14 Luchéis S.B. 2014. Tripanossomíases em rebanhos bovinos. *Pesquisa e Tecnologia*. 11(2): 1-4.
- 15 Mesa-Arciniegas P., Parra-Henao G., Carrión-Bonifacio Á., Casas-Cruz A., Patiño-Cuellar A., Díaz-Rodríguez K., Garzón-Jiménez S., Almansa-Manrique J., Bernal-Rosas Y., Hernández-Lamus C., Pedraza-Toscano A. & Torres-García O. 2018. *Trypanosoma cruzi* infection in naturally infected dogs from an endemic region of Cundinamarca, Colombia. *Veterinary Parasitology: Regional Studies and Reports*. 14: 212-216.
- 16 Mendes R.S., Santana V.L., Jansen A.N., Xavier S.C.C., Vidal I.F., Rotondano T.E.F. & Souza A.P. 2013. Aspectos epidemiológicos da Doença de Chagas canina no semiárido Paraibano. *Pesquisa Veterinária Brasileira*. 33(12):1459-1465.
- 17 Ministério da Saúde do Brasil. 2019. Doença de Chagas Aguda e distribuição espacial dos triatomíneos de importância epidemiológica, Brasil 2012 a 2016. *Boletim Epidemiológico*. 50(2): 1-10.
- 18 Neto-Araújo V.T., Honorato N.R.M., Santana R.O., Barbosa-Silva A.N., Guedes P.M.M., Chiari E., Galvão L.M.C. & Da Câmara A.C.J. 2019. *Trypanosoma cruzi* circulating among dogs and triatomines in the endemic countryside of the State of Rio Grande do Norte, Brazil. *Acta Tropica*. 200: 105067. [Available at: <<https://www.sciencedirect.com/science/article/abs/pii/S0001706X19301366?via%3Dihub>>].
- 19 Pagliarone A.C. & Sforcin J.M. 2009. Estresse: revisão sobre seus efeitos no sistema imunológico. *Biosaúde*. 11(1): 57-90.
- 20 Reiche E.M.V., Nunes S.O.V. & Morimoto H.K. 2005. Disfunções no Sistema Imune Induzidas pelo Estresse e Depressão: Implicações no Desenvolvimento e Progressão do Câncer. *Revista Brasileira de Oncologia Clínica*. 1(5): 19-28.
- 21 Ribeiro Junior G., Gurgel-Gonçalves R., Reis R.B., Santos C.G.S., Amorim A., Andrade S.G. & Reis M.G. 2015. Frequent House Invasion of *Trypanosoma cruzi*-Infected Triatomines in Suburban Area of Brazil. *Plos Neglected Tropical Diseases*. 9(4): 1-10.
- 22 Santana V.L., Souza A.P., Lima D.A.S.D., Araújo A.L., Justiniano S.V., Dantas R.P., Guedes P.M.M. & Melo M.A. 2012. Caracterização clínica e laboratorial de cães naturalmente infectados com *Trypanosoma cruzi* no semiárido nordestino. *Pesquisa Veterinária Brasileira*. 32(6): 536-541.
- 23 Secretaria de Saúde do Estado da Bahia (SESAB). 2018. Boletim epidemiológico da doença de Chagas. Available at: <http://www.saude.ba.gov.br/agravo/doenca-de-chagas/>. [Accessed online in August 2019].
- 24 Secretaria de Saúde do Estado da Bahia (SESAB). 2019. Boletim epidemiológico da doença de Chagas. Available at: <http://www.saude.ba.gov.br/agravo/doenca-de-chagas/>. [Accessed online in August 2019].
- 25 Silva P.B. & Fernandes J.I. 2013. Aspectos Clínicos Epidemiológicos da Infecção por *Trypanosoma cruzi* em Cães Naturalmente Infectados no Município de São Domingos do Capim Pará. In: *Resumos XXIV Seminário de Iniciação Científica da UFPA* (Belém, Brasil). p1.
- 26 Snowden K.F. & Kjos S.A. 2015. Tripanossomíase. In: Greene C.E (Ed). *Doenças Infeciosas em Cães e Gatos*. 4.ed. Rio de Janeiro: Guanabara Koogan, pp. 1581-1607.
- 27 Souza A.I. 2007. Estudo Clínico da Infecção Natural por *Trypanosoma cruzi* em Cães Residentes em uma Área Rural de Mato Grosso do Sul, Brasil. 78f. São Paulo. Dissertação (Mestrado em Ciências Agrárias e Veterinárias) - Programa de Pós Graduação em Ciências Agrária e Veterinária, Universidade Estadual Paulista.

- 28 **Souza A.I., Oliveira T.M.F.S., Machado R.Z. & Camacho A.A. 2009.** Soroprevalência da infecção por *Trypanosoma cruzi* em cães de uma área rural do Estado de Mato Grosso do Sul. *Pesquisa Veterinária Brasileira*. 29(2): 150-152.
- 29 **Veloso J.F., Oliveira T.N.A., Andrade L.P., Silva F.L., Sampaio K.M.O.R., Michel A.F.R.M., De Lavor M.S.L. & Carlos R.S.A. 2018.** Three Cases of Exclusively Extragenital Canine Transmissible Venereal Tumor (cTVT). *Acta Scientiae Veterinariae*. 46(Suppl 1): 295.
- 30 **Weiser G. 2015.** Interpretação da resposta leucocitária na doença In: Thrall M.A., Weiser G., Allison R.W. & Campbell T.W. (Eds). *Hematologia e Bioquímica Clínica Veterinária*. 2.ed. Rio de Janeiro: Guanabara Koogan, pp.276-305.
- 31 **World Health Organization (WHO). 2015.** Chagas Disease in Latin America: An Epidemiological Update Based on 2010 Estimates. *Weekly Epidemiological Record: World Health Organization*, Geneva. 90(6): 33-44. Available at: <https://www.who.int/wer/2015/wer9006/en/>. [Accessed online in February 2020].
- 32 **World Health Organization (WHO). 2020** Chagas disease (also known as American trypanosomiasis). Available at: [https://www.who.int/news-room/fact-sheets/detail/chagas-disease-\(american-trypanosomiasis\)](https://www.who.int/news-room/fact-sheets/detail/chagas-disease-(american-trypanosomiasis)). [Accessed online in February 2020].